

Distal phalanx replantation under local anesthesia and without venous anastomosis

Federico Paganini, Mariano Alberghini, Natalia Gutiérrez Olivera, Christian A. Allende Nores

Department of Hand Surgery and Limb Reconstructive Surgery, Sanatorio Allende (Córdoba, Argentina)

ABSTRACT

We present a patient who experienced a traumatic amputation of his left fifth finger distal phalanx, and was treated using replantation without venous anastomosis. The same surgical procedure also included a final arthrodesis with Kirschner wires. Surgery was performed with digital block anesthesia, which did not require the presence of an anesthesiologist nor fasting. The distal level of the amputation and the lack of viable options for dorsal vein anastomosis motivated our decision for venous drainage controlled by nail-plate removal, nail-bed scrubbing and periodic (every 3 hours during 7 days) dressing with heparine-impregnated gauze. In addition, the patient received anticoagulant therapy with aspirin and enoxaparin 40 mg every 24 hours for 21 days. The replantation procedure was a success.

Key words: Finger replantation; no venous anastomosis; local anesthesia.

Level of Evidence: IV

Reimplante de falange distal de dedo sin anastomosis venosa con anestesia local

RESUMEN

Presentamos a un paciente que sufrió una amputación traumática de la falange distal del 5^o dedo de su mano izquierda, y fue tratado mediante un reimplante sin anastomosis venosa. En el mismo acto quirúrgico, se le realizó una artrodesis definitiva con clavijas. La cirugía se efectuó con anestesia troncular del dedo, por lo cual no se requirió de un anestesista ni fue necesario un tiempo adecuado de ayuno. Debido a la localización distal de la amputación y a la ausencia de una vena dorsal viable para ser anastomosada, se optó por un drenaje venoso controlado mediante la extracción de la placa ungueal, el frotado del lecho ungueal y la colocación periódica (cada 3 h, por 7 días) de una gasa impregnada con heparina. Además, el paciente fue anticoagulado con enoxaparina 40 mg y ácido acetilsalicílico cada 24 h, por 21 días. El reimplante fue exitoso.

Palabras clave: Reimplante de dedo; sin anastomosis venosa; anestesia local.

Nivel de Evidencia: IV

INTRODUCTION

Advances in the microsurgical techniques and instrumentation coupled with better trained surgeons have led to fingertip replantation success rates involving artery and vein repair to range between 70% and 90%.¹

However, replantation at such a distal level poses a challenge even to the most skilled surgeons, as it requires a highly precise microsurgical technique. Of course, when performing a finger replantation, the goal is not only to achieve adequate hand function, but also a satisfactory aesthetic outcome. Restoration of the digital length bears as much significance as restoring the nail matrix and bed, as it provides the patient not only psychological wellness but a positive aesthetic response.^{2,3} It is also important to repair the digital collateral nerves in order to prevent any potential neuroma and to recover sensibility.

Venous anastomoses in amputations at the distal interphalangeal joint (DIPJ) or distal to the DIPJ are most difficult as they involve poor, trauma-related quality veins or even no veins at all.^{4,5} When no venous anastomosis is possible, alternative methods must be considered to provide continuous venous drainage and a constant blood flow to the replanted segment until normal venous drainage is restored through neovascularization. For this

Received on April 14th, 2019. Accepted after evaluation on June 20th, 2019 • FEDERICO PAGANINI, MD • federicopaganini@hotmail.com  <https://orcid.org/0000-0002-1162-0956>

How to cite this paper: Paganini F, Alberghini M, Gutiérrez Olivera N, Allende Nores CA. Distal phalanx replantation under local anesthesia and without venous anastomosis. *Rev Asoc Argent Ortop Traumatol* 2020;85(3):246-253. <https://doi.org/10.15417/issn.1852-7434.2020.85.3.981>

reason, there are several alternative options to venous anastomosis, with different success rates and the single goal of reducing venous congestion in replanted segments. The most frequently used techniques are based on external bleeding, including the use of medicinal leeches,⁶ controlled nail-bed bleeding,⁷ and controlled bleeding through paraungual incisions and applying heparin locally.⁸ In addition, some techniques do not involve external bleeding, such as arteriovenous^{9,10} and venocutaneous shunting.¹¹ The technique we used in our case was similar to that of Erken *et al.*,⁷ consisting of scrubbing with and placing heparin-impregnated gauze on the nail bed after removing the nail plate during surgery.

All these techniques are always applied together with anticoagulant protocols based on heparin sodium and platelet antiaggregation.

We present a case of a distal digital segment amputation that was replanted under local anesthesia and without venous anastomosis, which was replaced by a controlled ongoing bleeding associated with systemic anticoagulant therapy.

CLINICAL CASE REPORT

A 26-year-old, right-handed male who experienced a traumatic amputation at the left fifth finger DIPJ while using a circular saw. According to Tamai¹² and Ishikawa¹³ classifications, the amputation level corresponded to a Tamai level II amputation or an Ishikawa subzone IV (Figure 1).

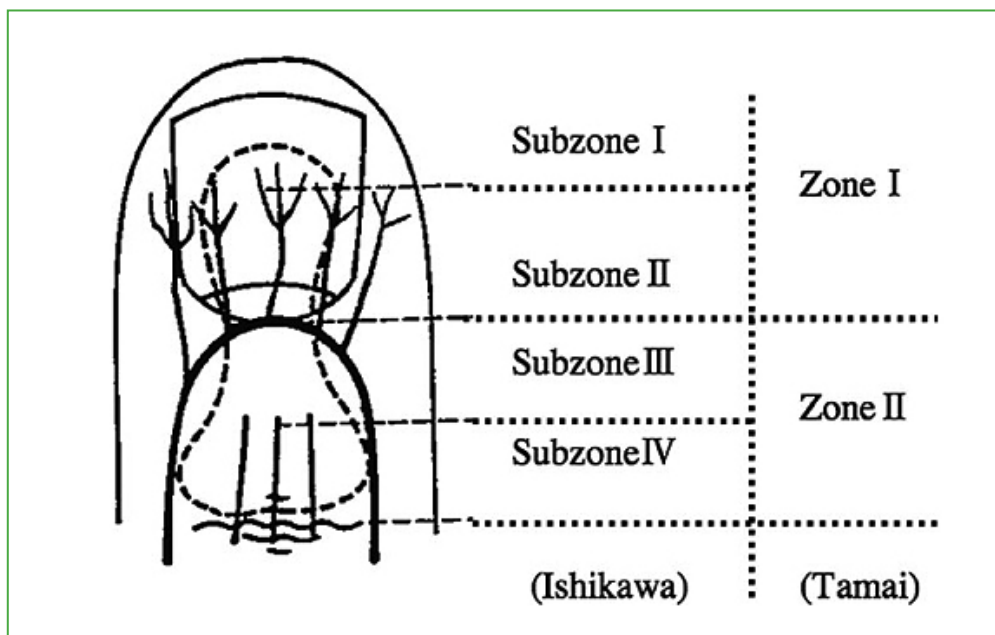


Figure 1. Ishikawa and Tamai Classifications.

The patient presented two hours after the accident with his amputated fingertip (Figure 2) correctly kept in a container cooled with ice and damp cloths. He stated that his hobby was playing the guitar and stressed his concern about preserving as much digital length as possible.

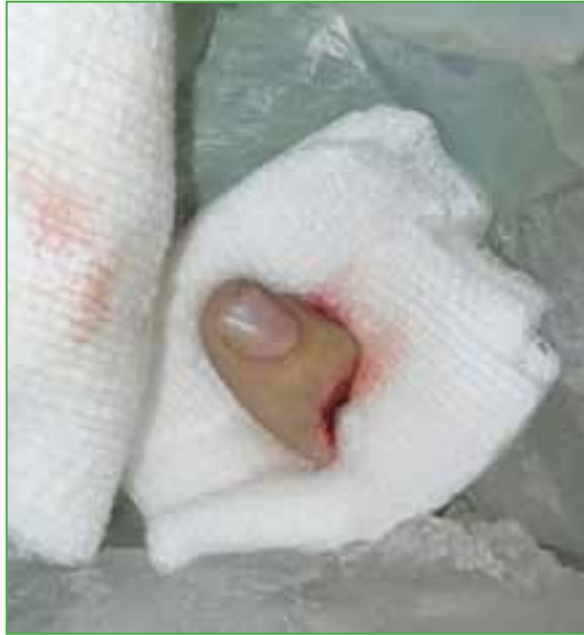

Figure 2. Amputated segment, correctly preserved in a container cooled with ice and damp cloths.

The patient was immediately transferred to the operating room for replantation (Figure 3). Digital block anesthesia (local) was administered, and surgical toilet and arthrodesis with two 1-mm intramedullary Kirschner wires were performed (Figure 4). Flexor tenorrhaphy and extensor tenorrhaphy were then performed, and, finally, neurovascular sutures were performed under microscopic magnification (3.5 times). Following the neurovascular sutures using Ethilon suture 9-0, arterial anastomosis was successfully performed using the same suture. Immediately after the arterial anastomosis, the patient received intravenous heparin sodium 70 U/kg of body weight. A venous anastomosis was then attempted, which was unsuccessful due to wound damage and small venous caliber. As a result, the decision was made to remove the nail plate and to place heparin-impregnated gauze (5000 IU heparin sodium) in the nail bed, with dressing changes at 3-hour intervals. No paraungual incisions were made for external bleeding. The total surgical time was 150 minutes.

Patient, relatives and nurses were instructed to stimulate the bleeding area by rubbing it with heparin-impregnated gauze during the early postoperative period. The patient received subcutaneous enoxaparin 40 mg/day and aspirin 100 mg/day for three weeks (Figure 5). The patient's hospital stay was 7 days, in the general ward at a room temperature of 24 degrees Celsius. The patient suffered from no postoperative complications, and blood transfusion was not necessary.

The DIPJ arthrodesis healed uneventfully, and the pins were removed 2 months after surgery (Figure 6). The healed arthrodesis resulted in 0° flexion and 10° pronation (the patient refused corrective surgery). Metacarpophalangeal and proximal interphalangeal joints recovered complete mobility 60 days after surgery (Figure 7).

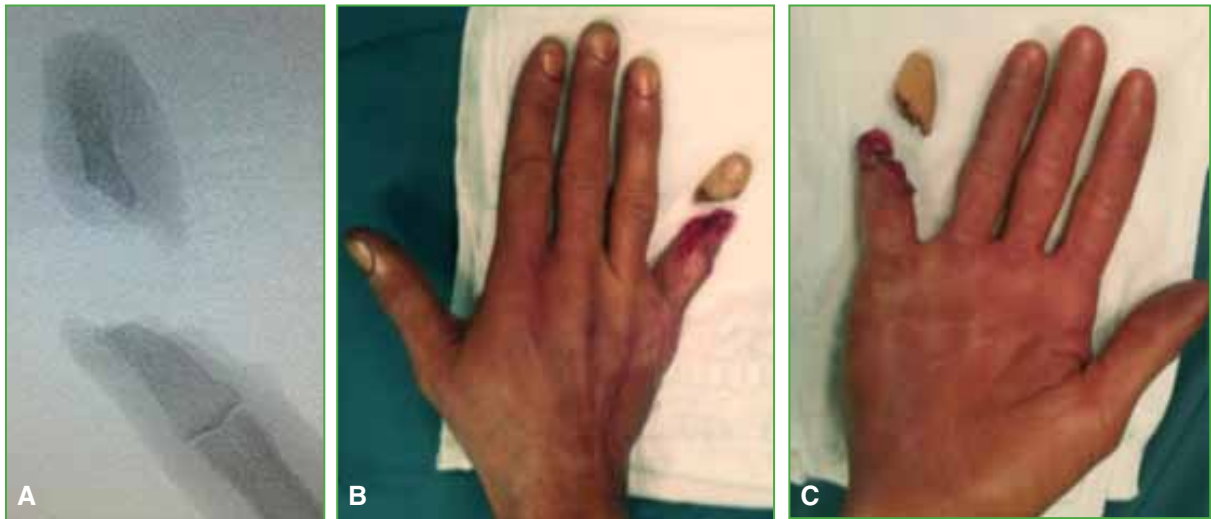


Figure 3. A. Intraoperative X-ray. Image shows the amputation bone level. B and C. Images of the part used for replantation.

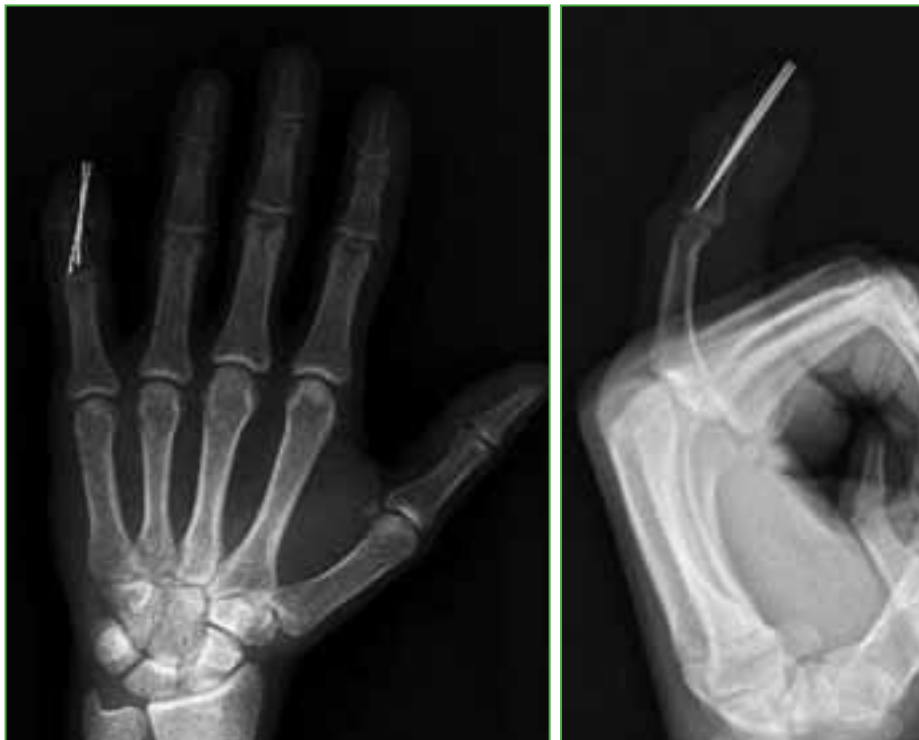

Figure 4. Temporary arthrodesis with two 1-mm intramedullary Kirschner pins.

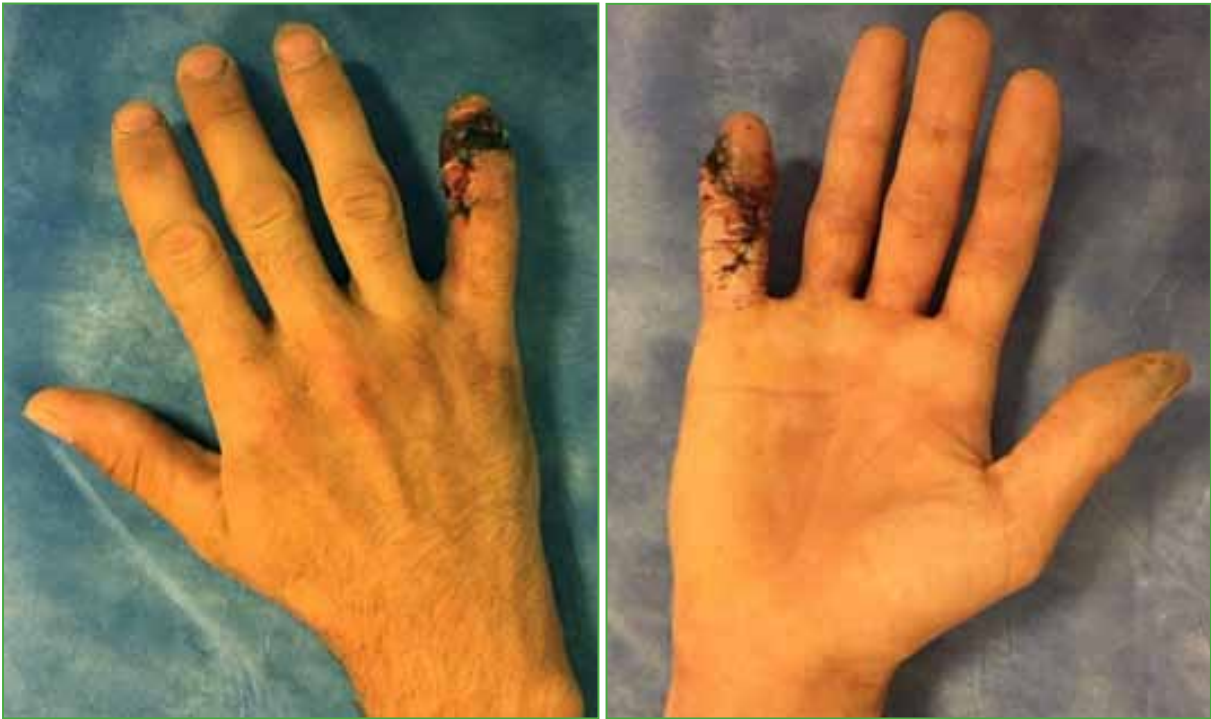

Figure 5. Replanted fifth digit tip, three weeks after surgery.

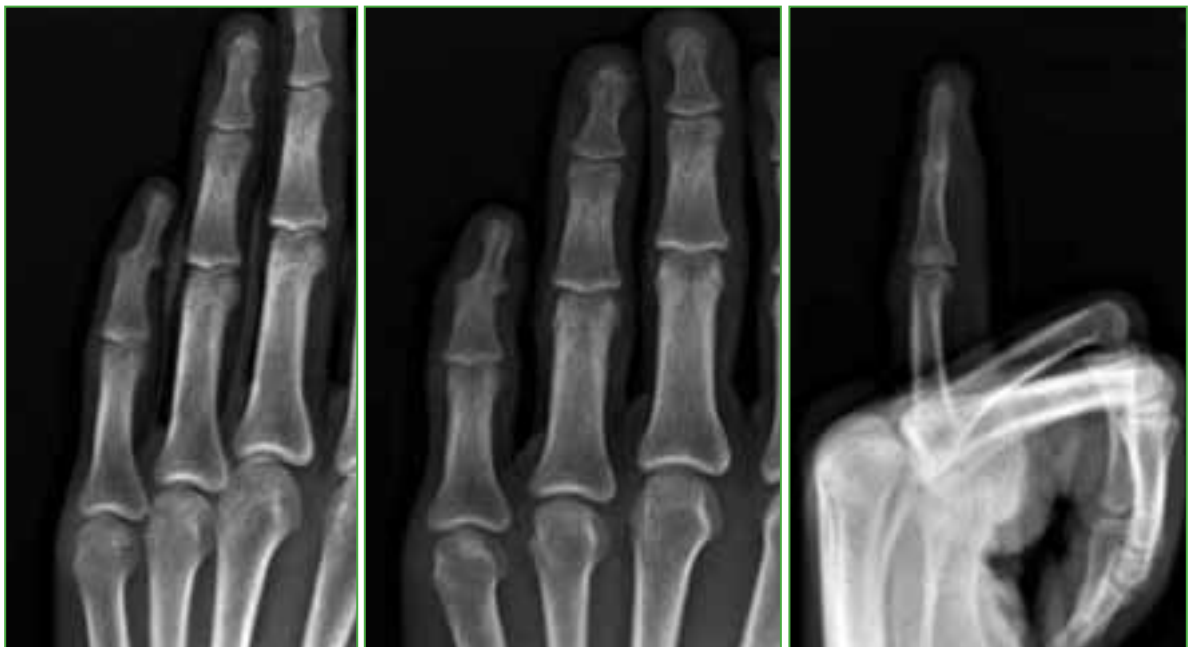

Figure 6. X-ray, 2 months after surgery. X-ray showing consolidation of the distal interphalangeal joint arthrodesis.

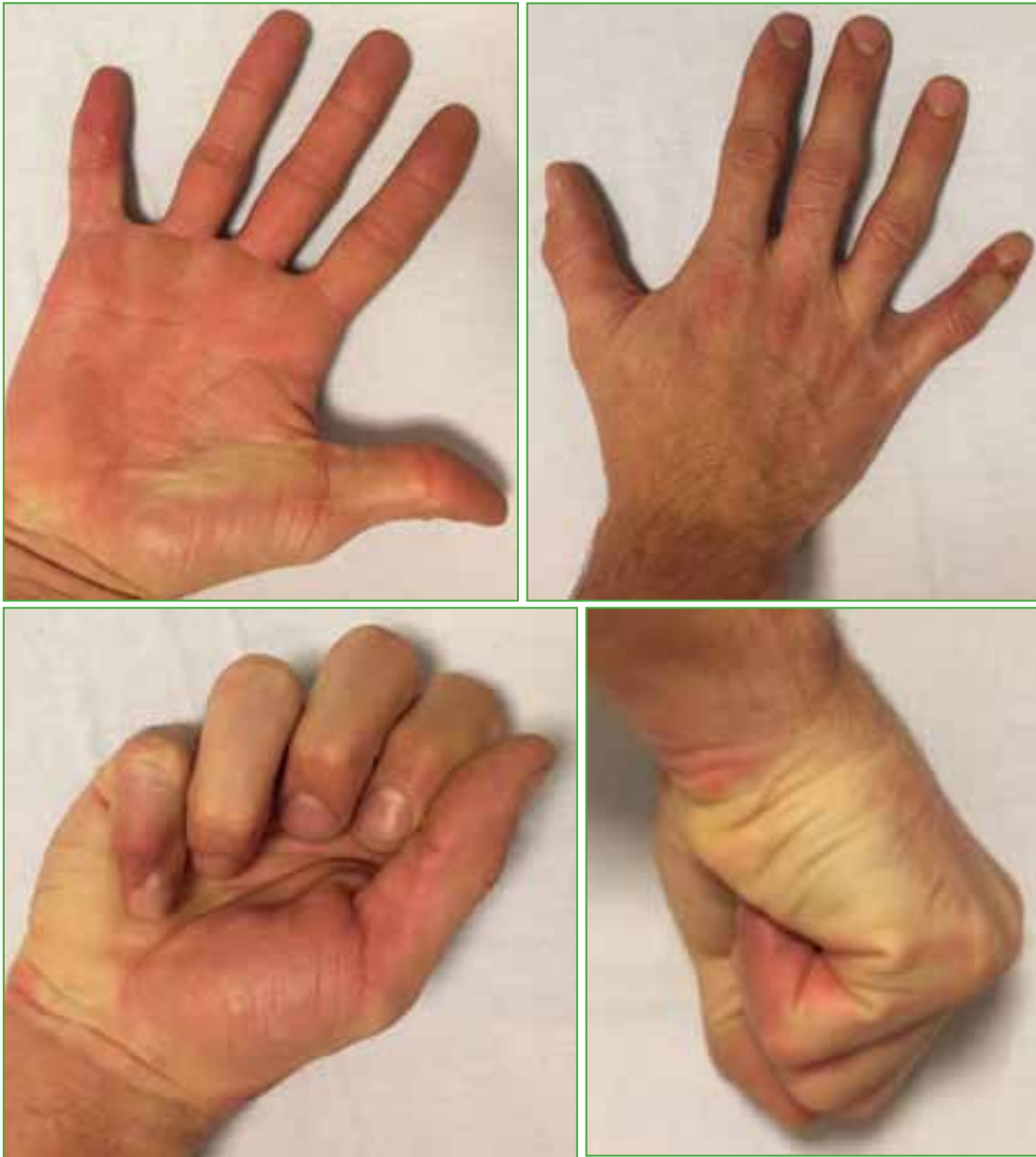

Figure 7. Sixty-day control. Complete recovery of the metacarpophalangeal and proximal interphalangeal joints, and mild deviation in pronated replanted segment.

DISCUSSION

Replantation of distal phalanx amputations require specialist training in microsurgery techniques; however, a successful outcome will not depend only on the microsurgeon's expertise but on extrinsic factors, as the amputation mechanism, time delay to surgery, and the proper preservation of the amputated part. In addition, the patient's intrinsic factors, including age, smoking history and conditions involving peripheral microcirculation (e.g., diabetes), also affect the surgical outcome. In sight of these factors, Hui-Fu Huang *et al.*¹⁴ stated that success in DIPJ replantations is not exclusively dependent on venous anastomosis.

In our case, we employed the technique described by Erken *et al.*,⁷ consisting of practicing arterial anastomoses, placing heparin-impregnated gauze on the nail bed, and implementing an anticoagulant treatment with heparin and aspirin. The patient's hospital stay was 7 days, in the general ward, same as reported by Erken *et al.* (mean hospital stay, 7 days); however, 15 out of 22 Erken *et al.* patients required blood transfusion (average, 1.2 U), while this procedure was not necessary in our case. It is worth noticing that these authors stated that recovery of sensibility at two years from surgery is similar whether digital neuroorrhaphy was performed or not. However, notwithstanding this statement, we decided to perform this procedure. Erken *et al.* achieved a 88% replantation success rate.

In another series, Buntic and Brooks⁶ achieved successful replantations in all the study cases. They performed 19 distal replantations in 17 patients, who underwent only venous anastomoses and received a dextran-40, intravenous heparin, and leech therapy. The hospital stay was longer (mean, 9 days), and 11 patients required blood transfusions.

Finally, considering what has been previously stated, we deem DIPJ amputations with no viable venous anastomosis to have several surgical techniques that achieve acceptable success rates.

CONCLUSIONS

We consider that our technique is adequate, easy to perform and reproduce, shortens replantation surgical duration, and enables to operate without an anesthesiologist in attendance. However, it requires a longer hospital stay, which increases costs and warrants the patient and relatives to be responsible and able to follow treatment. The main limitation of this technique is that it is specific for amputations at the distal interphalangeal joint (DIPJ) or distal to the DIPJ.

Conflict of interests: Authors claim they do not have any conflict of interests.

M. Alberghini ORCID ID: <https://orcid.org/0000-0001-6793-0550>

N. Gutiérrez Olivera ORCID ID: <https://orcid.org/0000-0002-3021-1277>

C. A. Allende Nores ORCID ID: <https://orcid.org/0000-0002-2336-2157>

REFERENCES

- Hattori Y, Doi K, Sakamoto S, Yamasaki H, Wahegaonkar A, Addosooki A. Fingertip replantation. *J Hand Surg Am* 2007;32(4):548-55. <https://doi.org/10.1016/j.jhsa.2007.01.019>
- Rush MD, Grunert BK, Sanger JR, Dzwierzynski WW, Matloub HS. Psychological adjustment in children after traumatic disfiguring injuries: a 12 month follow up. *Plast Reconstr Surg* 2000;106(7):1451-60. <https://doi.org/10.1097/00006534-200012000-00001>
- Matsuzaki H, Yoshizu T, Maki Y, Tsubokawa N. Functional and cosmetic results of fingertip replantation: anastomosing only the digital artery. *Ann Plast Surg* 2004;53(4):353-9. <https://doi.org/10.1097/01.sap.0000137136.09890.18>
- Patradul A, Ngarmukos C, Parkpian V. Distal digital replantations and revascularizations: 237 digits in 192 patients. *J Hand Surg Br* 1998;23(5):578-82. [https://doi.org/10.1016/s0266-7681\(98\)80005-3](https://doi.org/10.1016/s0266-7681(98)80005-3)
- Foucher G, Norris RW. Distal and very distal digital replantations. *Br J Plast Surg* 1992;45(3):199-203. [https://doi.org/10.1016/0007-1226\(92\)90076-a](https://doi.org/10.1016/0007-1226(92)90076-a)
- Buntic RF, Brooks D. Standardized protocol for artery-only fingertip replantation. *J Hand Surg Am* 2010;35(9):1491-6. <https://doi.org/10.1016/j.jhsa.2010.06.004>
- Erken HY, Takka S, Akmaz I. Artery-only fingertip replantations using a controlled nailbed bleeding protocol. *J Hand Surg Am* 2013;38(11):2173-9. <https://doi.org/10.1016/j.jhsa.2013.08.110>

8. Yi-Chieh Chen, Fuan Chiang Chan, Chung-Chen Hsu, Yu-Te Lin, Chien-Tzung Chen, Chih-Hung Lin. Fingertip replantation without venous anastomosis. *Ann Plast Surg* 2013;70(3):284-8. <https://doi.org/10.1097/SAP.0b013e3182321b81>
9. Slattery P. Distal digital replantation using a solitary digital artery for arterial inflow and venous drainage. *J Hand Surg Am* 1994;19(4):565-6. [https://doi.org/10.1016/0363-5023\(94\)90257-7](https://doi.org/10.1016/0363-5023(94)90257-7)
10. Fukui A, Maeda M, Inada Y, Tamai S, Sempuku T. Arteriovenous shunt in digit replantation. *J Hand Surg Am* 1990;15(1):160-5. [https://doi.org/10.1016/s0363-5023\(09\)91125-x](https://doi.org/10.1016/s0363-5023(09)91125-x)
11. Kamei K, Sinokawa Y, Kishibe M. The venocutaneous fistula. A new technique for reducing venous congestion in replanted fingertips. *Plast Reconstr Surg* 1997;99(6):1771-4. PMID: 9145156
12. Tamai S. Twenty years' experience of limb replantation: Review of 293 upper extremity replants. *J Hand Surg Am* 1982;7(6):549-56. [https://doi.org/10.1016/s0363-5023\(82\)80100-7](https://doi.org/10.1016/s0363-5023(82)80100-7)
13. Ishikawa K, Ogawa Y, Soeda H, Yoshida Y. A new classification of the amputation level for the distal part of the finger. *J Jpn Soc Microsurg* 1990;3:54-62.
14. Hui-Fu Huang, Eng-Kean Yeong. Surgical treatment of distal digit amputation: Success in distal digit replantation is not dependent on venous anastomosis. *Plast Reconstr Surg* 2015;135(1):174-8. <https://doi.org/10.1097/PRS.0000000000000796>