

Volar marginal fragment in distal radius fractures. Pin fixation in addition to volar plate

Ignacio Seré, Ezequiel Ortiz, Marcos Deimundo, Augusto Martínez, Marcos Meninato, Fernando Grandoli

Department of Orthopedics and Traumatology, Hospital Universitario CEMIC (Buenos Aires, Argentina)

ABSTRACT

Introduction: Wrist fracture management with volar locking plates may be insufficient in fractures with volar marginal fragments distal to the line insertion of the pronator quadratus, the insertion site of important ligaments. **Objective:** To evaluate the reproducibility and results for the treatment of volar marginal fragment in distal radius fractures with a technique of pin fixation, capturing the fragment and securing them under the distal radius volar locking plate. **Materials and Methods:** The surgical technique uses one or more pins for the fixation of the volar lunate facet fragment in the distal radius, securing the pins under the locking plate. We initially performed a cadaveric simulation. Then we conducted a retrospective study on 7 patients with distal radius intra-articular fractures and volar marginal fragments distal to the watershed line, treated between September 2014 and February 2015. The average age was 53 years, and the average follow-up was 16 months. Radiographs were obtained in successive controls. Range of motion, grip strength, and 2 functional scores were assessed at discharge. **Results:** All fractures healed successfully maintaining reduction of the volar marginal fragment. There were no cases of postoperative distal radioulnar joint instability. **Conclusion:** Additional fixation of volar marginal fragment in distal radius fractures with bent pins under the plate provides an easy, affordable and adequate alternative to supply the adequate fragment stabilization that plate-alone techniques do not achieve.

Key words: Volar marginal fractures; distal radius; fixation; pins; volar plates.

Level of Evidence: IV

Fracturas marginales volares de radio distal: fijación con clavijas adicionales a la placa volar

RESUMEN

Introducción: El tratamiento de las fracturas de muñeca con placas volares bloqueadas puede ser insuficiente para las fracturas con fragmentos volares marginales distales a la línea de inserción distal del pronador cuadrado, sitio de inserción de importantes ligamentos. **Objetivo:** Evaluar la reproducibilidad de la técnica y los resultados del tratamiento de fracturas marginales volares de radio distal con clavijas, capturando el fragmento volar y dejándolas debajo de la placa volar bloqueada de radio distal. **Materiales y Métodos:** La técnica quirúrgica utiliza una o varias clavijas para fijar el fragmento volar semilunar del radio distal, bloqueándolas debajo de la placa. Inicialmente efectuamos una simulación cadavérica. Luego, realizamos un estudio retrospectivo que incluyó a 7 pacientes con fracturas de radio distal intrarticular con un fragmento marginal volar distal a la línea de la orilla, tratados entre septiembre de 2014 y febrero de 2015. El promedio de edad era de 53 años, y el del seguimiento, de 16 meses. Se obtuvieron radiografías en sucesivos controles. Al alta se evaluaron el rango de movilidad, la fuerza de prensión y dos puntajes funcionales. **Resultados:** Todas las fracturas consolidaron satisfactoriamente manteniendo la reducción del fragmento marginal volar. No hubo casos con inestabilidad radiocubital inferior como secuela. **Conclusión:** La fijación adicional del fragmento marginal volar lunar del radio con clavijas dobladas por debajo de la placa ofrece una alternativa de estabilización sencilla, económica y adecuada para suplir la fijación de un fragmento que la placa sola no estabilizaría adecuadamente.

Palabras clave: Fractura marginal volar; radio distal; fijación; clavijas; placas volares.

Nivel de Evidencia: IV

Received on March 26th, 2019. Accepted after evaluation on December 29th, 2019 • IGNACIO SERÉ, MD • ignaciosere@gmail.com  <https://orcid.org/0000-0002-3267-8073>

How to cite this paper: Seré I, Ortiz E, Deimundo M, Martínez A, Meninato M, Grandoli F. Volar marginal fragment in distal radius fractures. Pin fixation in addition to volar plate. *Rev Asoc Argent Ortop Traumatol* 2020;85(3):197-203. <https://doi.org/10.15417/issn.1852-7434.2020.85.3.977>

INTRODUCTION

The development volar locking-plate systems for wrist fractures has revolutionized their treatment. Owing to their relatively few complications and their effectiveness to successfully treat most distal radius fractures, they have become the treatment of choice for numerous surgeons.^{1,2} However, in fractures involving volar marginal fragments distal to the line insertion of the pronator quadratus (the “watershed line”),³ fixation of the volar lunate facet fracture fragment may prove inadequate.⁴ The immense significance of this fragment lies on its role as bone limit to lunate translation (similar to that of the osseous anterior glenoid rim in the glenohumeral joint) and as insertion site of important radiocarpal (short radiolunate ligament) and radioulnar ligaments (volar distal radioulnar ligament). Unsuccessful fixation may result in instability or sub-dislocations at the radiocarpal and distal radioulnar joints.^{3,5} This fracture line may be part of an isolated fracture or a comminuted fracture. Several treatment options have been proposed, all of them with their own advantages and complications.⁶⁻⁸ Moore and Dennison have proposed using one or several pins to capture the distal volar marginal fragment and secured them under the volar locking plate.⁹

The purpose of this study is to assess the feasibility of Moore and Dennison’s technique and report our initial experience on its use in the treatment of distal radius fractures with volar marginal fragment distal to the radius.

MATERIALS AND METHODS

After the approval of the research protocol by the Research Commission of the University Institute CEMIC, we initially performed a cadaveric simulation. The used specimen was fixed in formalin and belonged to a 76-year male with no radiocarpal alterations. The fracture line was created using a thin osteotome, and then a polyaxial locking plate (Biokinnet, Argentina) was placed. The impossibility to perform fragment fixation without an inadequate plate placement was assessed and confirmed. Fixation was then performed using two 1 mm pins that were bent and secured under the plate, which resulted in a stable fixation.

Following this initial experience in a cadaveric model, we began using this technique in the operating room.

We conducted a retrospective review on 7 patients who had suffered a distal radius fracture associated with a volar marginal fragment, and had undergone surgery by the same surgeon between September 2014 and February 2015.

The inclusion criteria for this retrospective study included patients with distal radius intra-articular fractures and volar marginal fragments distal to the watershed line (Figure 1).

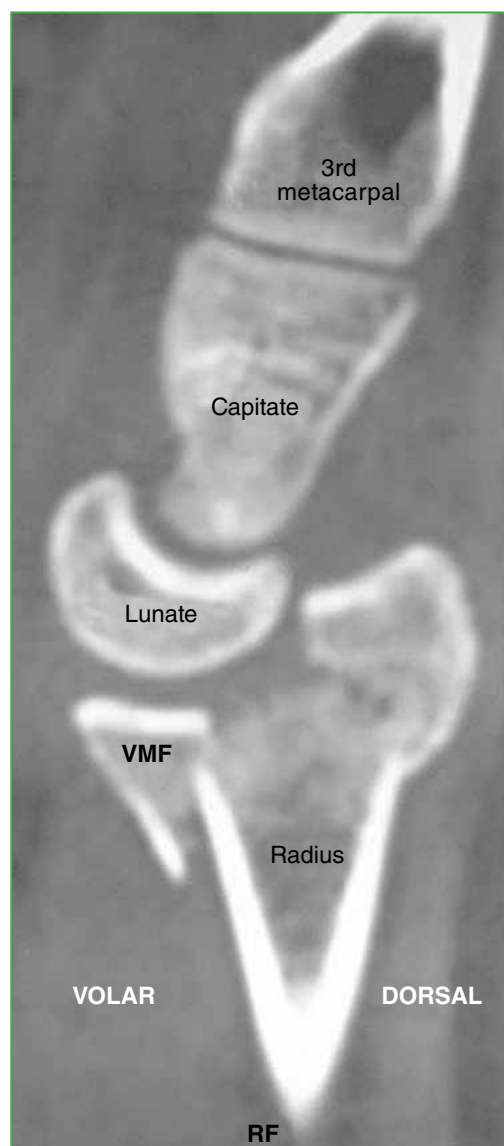


Figure 1. Wrist CT sagittal section. Image reveals distal radius intra-articular fracture and volar marginal fragment distal to the watershed line. VMF = volar marginal fragment.

Four patients were females and 3 were males. The average age was 53 years. Three cases involved the right wrist, and three cases involved the dominant side. All fractures were C3 fractures according to the AO classification.¹⁰ The average follow-up period was 8 months (Table 1).

Table 1. Study population data

¿Tendrá cabeza?	
Sex	4 females 3 males
Age	53 years (range, 31-76)
Fractured wrist	3 right 4 left
Dominant side	4 dominant side 3 non-dominant side
AO classification	C3
Average time to surgery	16 days (range, 7-29)
Average follow-up period	16 months (range, 12-18)

The number of pins used under the plate varied according to the management of the comminution associated to the volar marginal fragment: 4 pins (1 case); 2 pins (4 cases); 1 pin (2 cases). Three patients also presented with displaced distal ulnar fracture: 2 cases of ulnar styloid base fracture that were treated with Kirschner pin and compression screw, respectively; and 1 case of distal ulnar metaphyseal fracture that was treated with 2.7 mm locking T-plate.

Surgical technique

All patients underwent outpatient surgery, using plexus anesthesia with tourniquet (hemostatic cuff) and fluoroscopic assistance. The standard volar approach for distal radius, as described by Orbay and Fernandez,^{11,12} was used in three cases, and the minimally invasive, distal, transverse approach in the remaining four cases.¹³

Initially, an overall fracture reduction is performed, using ligamentotaxis supplemented by intra-focal pinning (Figures 2A and 2B).¹⁴ Volar lunate facet fragment reduction was then assessed (fragment size and comminution); fixation was supplemented by one or more 1 mm pins. Pins penetrated the distal volar lip of the reduced marginal fragment, angled in an approximately 45 degrees distal to proximal and dorsal to volar direction. The “teardrop” angle (between the radius axis and the volar lunate lip, approximately 70 degrees) was useful in cases involving major comminution (Figures 2C and 2D). After achieving adequate reduction and fixation, the pin was partially removed (approx. 1 cm) and bent as much as possible toward proximal direction, while firmly gripping it with pliers to secure the direction. The pin was then molded on to the volar surface of the radius (Figures 2E-I), and the distal radius volar locking plate was positioned, capturing the pins while securing the adequate “teardrop” angle (Figures 2J-M). Using two pins is preferred to control any rotation of the fragment; however, fragment size determines the maximum number of pins that may be used. After fixation was achieved, fragment and joint stability were assessed.

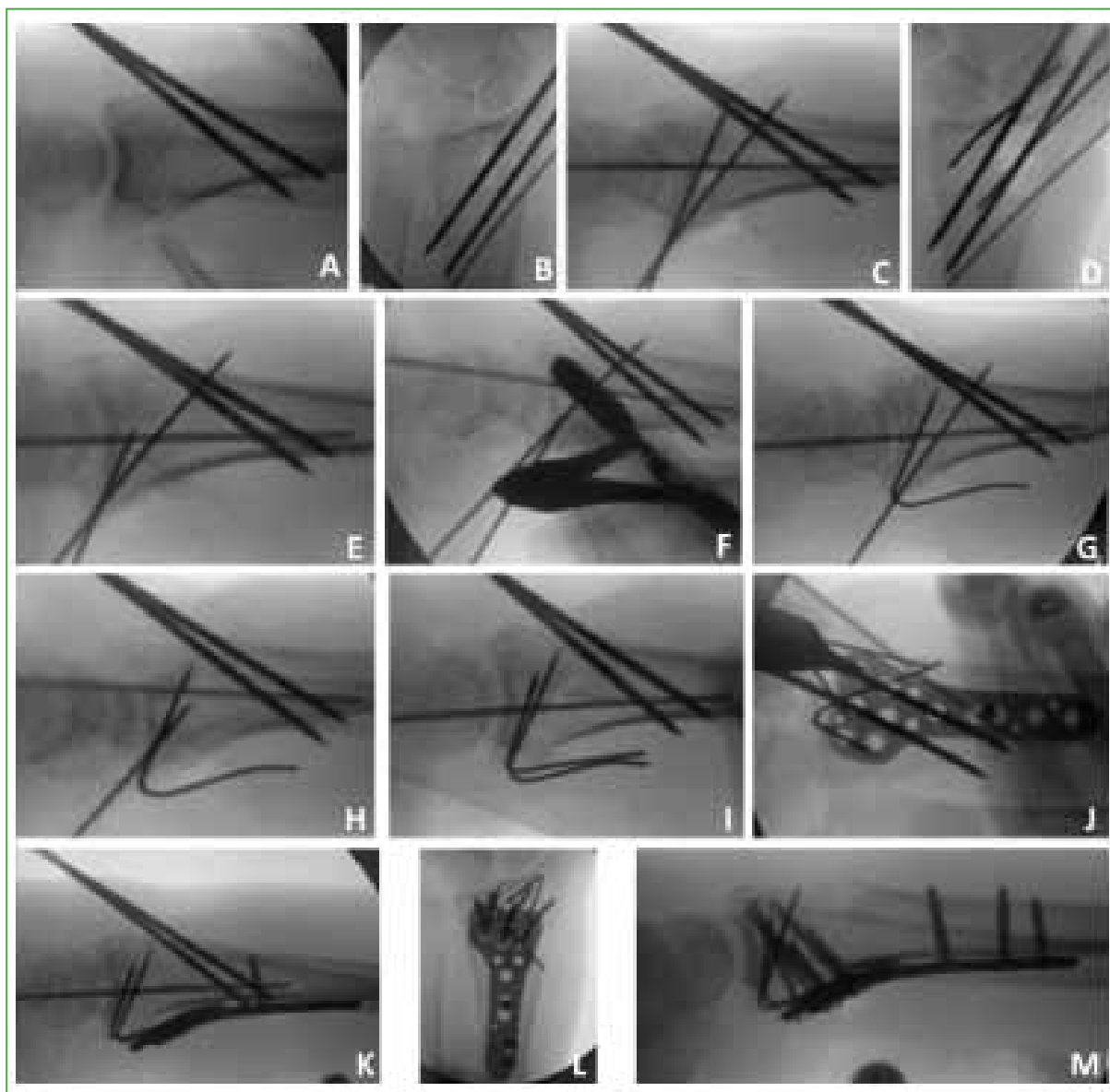

Figure 2. Fluoroscopic view during the procedure. **A and B.** Metaphyseal fracture per-cutaneous reduction using intra-focal pinning. **C and D.** Additional pins in the volar marginal fragment. **E-G.** Partial removal and bending of pin using a needle-holding forceps. **H and I.** Partial removal and bending of the additional pin using a needle-holding forceps. **J and K.** Metaphyseal volar plate fixation over the bent pins. **L and M.** Intra-focal pin removal and final fixation with all screws placed over the additional pins.

Postoperative management

Postoperative immobilization was performed considering the associated lesions: long-arm plaster casts for 4 weeks in patients with associated distal ulnar fractures; and short-arm plaster casts for 3 weeks in the other 4 patients. Physical therapy was instituted after the immobilization was removed and discontinued once complete mobility was achieved.

Evaluation

Anteroposterior and lateral radiographs were obtained at each postoperative visit, until complete radiographic healing was observed.

On discharge day, wrist range of motion was measured in flexion, extension, supination, and pronation using a goniometer, and grip strength was measured using a Jamar dynamometer.

Scores from the QuickDASH questionnaire and the Patient-Rated Wrist Evaluation questionnaire (PRWE) were studied.¹⁵⁻¹⁶

RESULTS

Table 2 shows the obtained wrist ranges of motion, grip strengths, and QuickDASH and PRWE scores. There were no cases of postoperative distal radioulnar joint instability.

Table 2. Clinical outcomes

	Average	Range
QuickDASH	14.29	5,26-36,7
PRWE	17.42	3-45
Fist strength	19.87 kgf	12-51.5 kgf
Flexion	62.42°	35-85°
Extension	69.43°	40-86°
Pronation	85.71°	75-90°
Supination	79.29°	30-95°

PRWE = Patient-Rated Wrist Evaluation

All distal radius fractures healed satisfactorily, maintaining the volar lunate facet fragment reduction with no articular alignment changes, hardware malfunction or pin migration.

One patient experienced a complication, postoperative regional pain syndrome Type 1, and had good evolution with medical treatment and rehabilitation. No patient required fixation hardware removal or had evidence of flexor or extensor tendon irritation.

DISCUSSION

The volar lunate facet fractures of the distal radius are difficult to treat, and postoperative loss of reduction has been reported.⁴ Standard volar-locked plating has proven limited in providing an effective solution for these cases, warranting a different type of additional fixation. Several authors have produced potential solutions for this fragment fixation: the fragment-specific fixation system involves specific plates to stabilize fracture fragments in each column. This distal radius fixation method requires multiple incisions and is known to be technically demanding, involving a significant learning curve for adequate fracture fixation. In addition, in our setting, plates must be ordered beforehand.^{7,8} Traction-absorbing wiring has been described in isolated volar lunate facet fractures. This is an effective technique, although hard to perform in cases requiring volar plates for the fixation of other fracture fragments or in cases involving significant volar metaphyseal fragmentation.⁶ Pins passed through the fragment from the volar side and protruding into the dorsal aspect may prove to be an easy solution, though providing relative stability and requiring a second procedure for their removal. Finally, suture fixation, used in avulsion fractures with minimum bone fragments, also fails to secure stability and may be challenging in some cases.¹⁷

This study technique offers several advantages: provides a stable fixation to the volar lunate facet fragment to resist volar displacement, is ease to perform, enables to stabilize the remaining fracture fragments using any type of locking plate, is inexpensive and easily available for any operating room, and results in no prominent hardware nor requires its removal. In our series, there were no cases of postoperative volar carpal sub-dislocations or distal radioulnar instability. The final radiographs confirmed congruent reduction and adequate healing in all cases. The clinical outcomes were similar to those reported for locking fixations in less complex distal radius fractures.

The limitations of our study include: a small case series population (due to the type of fracture under study), and an heterogeneous population (3 patients with associated ulnar fracture). Although we observe no complications associated with the internal fixation, flexor tendon additional lesions may occur years after surgery; thus, our follow-up period may have been inadequate.

CONCLUSIONS

Additional fixation of volar marginal fragment in distal radius fractures with bent pins under the plate provides an easy, affordable and adequate alternative. This technique allows for any type of locking or non-locking plate additional fixation, thus making them more widely available for cases where a single plate fixation would be unable to achieve stability of said fragments.

Conflict of interests: Authors claim they do not have any conflict of interests.

E. Ortiz ORCID ID: <https://orcid.org/0000-0001-8292-8432>
 M. Deimundo ORCID ID: <https://orcid.org/0000-0002-2822-4394>
 A. Martínez ORCID ID: <https://orcid.org/0000-0002-8088-0874>

M. Meninato ORCID ID: <https://orcid.org/0000-0003-1858-4238>
 F. Grandoli ORCID ID: <https://orcid.org/0000-0002-5002-6984>

REFERENCES

1. Alfie V. Uso de placa palmar bloqueada en fracturas intraarticulares del radio distal en pacientes mayores de 60 años. Estudio radiológico. *Rev Asoc Argent Ortop Traumatol* 2006;71(3):197-204. <https://pdfs.semanticscholar.org/710c/a2f8be254fc9811b73b2c95a5c7fd08181f5.pdf>
2. Pereira E, Seré IA, Miranda D, Arce G, Rodríguez Castells F. Osteosíntesis con placa bloqueada palmar de ángulo fijo en fracturas del radio distal. *Rev Asoc Argent Ortop Traumatol* 2007;72(1):24-31. https://www.aaot.org.ar/revista/2007/n1_vol72/art6.pdf
3. Imatani U, Akita K, Yamaguchi K, Shimizu H, Kondou H, Ozaki T. An anatomical study of the watershed line on the volar, distal aspect of the radius: implications for plate placement and avoidance of tendon ruptures. *J Hand Surg Am* 2012;37(8):1550-4. <https://doi.org/10.1016/j.jhsa.2012.05.011>
4. Harness NG, Jupiter JB, Orbay JL, Raskin KB, Fernandez DL. Loss of fixation of the volar lunate fragment in fractures of the distal part of the radius. *J Bone Joint Surg Am* 2004;86(9):1900-8. https://www.jbjs.org/reader.php?id=97262&rsuite_id=928237&native=1&source=The_Journal_of_Bone_and_Joint_Surgery/86/9/1900/abstract&topics=hw#info
5. Berger RA, Landsmeer JMF. The palmar radiocarpal ligaments: A study of adult and fetal human wrist joints. *J Hand Surg* 1990;15(6):847-54. [https://doi.org/10.1016/0363-5023\(90\)90002-9](https://doi.org/10.1016/0363-5023(90)90002-9)
6. Chin KR, Jupiter JB. Wire-loop fixation of volar displaced osteochondral fractures of the distal radius. *J Hand Surg Am* 1999;24(3):525-33. <https://doi.org/10.1053/jhsu.1999.0525>
7. Gerostathopoulos N, Kalliakmanis A, Fandridis E, Georgoulis S. Trimed fixation system for displaced fractures of the distal radius. *J Trauma* 2007;62(4):913-8. <https://doi.org/10.1097/01.ta.0000219948.92935.cd>
8. Saw N, Roberts C, Cutbush K, Hodder M, Couzens G, Ross M. Early experience with the TriMed fragment-specific fracture fixation system in intraarticular distal radius fractures. *J Hand Surg Eur* 2008;33(1):53-8. <https://doi.org/10.1177/11753193407087887>
9. Moore AM, Dennison DG. Distal radius fractures and the volar lunate facet fragment: Kirschner wire fixation in addition to volar locked plating. *Hand (NY)* 2014;9(2):230-6. <https://doi.org/10.1007/s11552-013-9585-7>
10. Fracture and dislocation compendium. Orthopaedic Trauma Association Committee for Coding and Classification. *J Orthop Trauma* 1996;10(Suppl 1):v-ix, 1-154. PMID: 8814583
11. Orbay JL, Badia A, Indriago IR, Infante A, Khouri RK, Gonzalez E, et al. The extended flexor carpi radialis approach: a new perspective for the distal radius fracture. *Tech Hand Up Extrem Surg* 2001;5(4):204-11. <https://doi.org/10.1097/00130911-200112000-00004>

12. Orbay JL, Fernandez DL. Volar fixed-angle plate fixation for unstable distal radius fractures in the elderly patient. *J Hand Surg Am* 2004;29(1):96-102. <https://doi.org/10.1016/j.jhssa.2003.09.015>
13. Imatani J, Noda T, Morito Y, Sato T, Hashizume H, Inoue H. Minimally invasive plate osteosynthesis for comminuted fractures of the metaphysis of the radius. *J Hand Surg Br* 2005;30(2):220-5. <https://doi.org/10.1016/j.jhsb.2004.12.009>
14. Kapandji A. L'ostéosynthèse par double embrochage intra-focal. Traitement fonctionnel des fractures non articulaires de l'extrémité inférieure du radius [Internal fixation by double intrafocal plate. Functional treatment of non articular fractures of the lower end of the radius (author's transl)]. *Ann Chir* 1976;30(11-12):903-8.
15. Beaton DE, Wright JG, Katz JN, and the Upper Extremity Collaborative Group. Development of the QuickDASH: Comparison of three item-reduction approaches. *J Bone Joint Surg Am* 2005;87(5):1038-46. <https://doi.org/10.2106/JBJS.D.02060>
16. MacDermid JC, Turgeon T, Richards RS, Beadle M, Roth JH. Patient rating of wrist pain and disability: a reliable and valid measurement tool. *J Orthop Trauma* 1998;12(8):577-86. <https://doi.org/10.1097/00005131-199811000-00009>
17. Fernandez DL, Wolfe SW. Fracturas del extremo distal del radio. En: Green DP, Hotchkiss RN, Pederson WC, Wolfe SW. *Green's Cirugía de la mano*, 5ª ed. Madrid: Marban Libros; 2007:645-710.