

# Tibia Osteomyelitis secondary to BCG vaccination in an immunocompetent infant. Case report

Javier E. Dal Lago, Eduardo J. Levy

Pediatrics Orthopedics Team, Hospital Británico de Buenos Aires (Buenos Aires, Argentina)

## ABSTRACT

**Introduction:** The Bacillus Calmette-Guérin (BCG) vaccine, used to prevent severe forms of tuberculosis (TB), is the most extensively used vaccine worldwide. Adverse events associated with BCG vaccination are rare, and most of them occur at the inoculation site. We present a tibia Osteomyelitis case secondary to BCG vaccination in an immunocompetent infant. **Conclusions:** Bone involvement secondary to BCG vaccination in previously healthy patients is extremely rare. Healthcare providers must consider such settings in order to make the diagnosis and institute the appropriate treatment. Antituberculous drugs produced good therapeutic results with no need for surgical toilette.

**Key words:** Tuberculosis; TB; Bacillus Calmette-Guérin; BCG; Osteomyelitis; Osteitis.

**Level of Evidence:** IV

## Osteomielitis de tibia secundaria a la vacuna BCG en un paciente pediátrico inmunocompetente. Reporte de un caso

## RESUMEN

**Introducción:** La vacuna BCG (bacilo de Calmette-Guérin) para prevenir las formas graves de tuberculosis, es la vacuna más difundida en el mundo. Los efectos adversos asociados a la vacunación son poco frecuentes, y la mayoría de ellos ocurren en el sitio de inoculación. Presentamos un caso de osteomielitis de tibia secundaria a la vacuna BCG en un paciente pediátrico inmunocompetente. **Conclusiones:** El compromiso óseo secundario a la vacuna BCG en pacientes previamente sanos es muy raro. Es importante sospecharlo, para diagnosticarlo y administrar el tratamiento adecuado. Se obtuvieron buenos resultados administrando fármacos antituberculosos, sin necesidad de limpieza quirúrgica.

**Palabras clave:** Tuberculosis; bacilo de Calmette-Guérin; BCG; osteomielitis; osteítis.

**Nivel de Evidencia:** IV

## INTRODUCTION

TB is an infectious, chronic granulomatous disease. The etiologic agent of TB is *Mycobacterium tuberculosis* (or Koch bacillus). The World Health Organization reported an estimated 9 million cases of TB and an estimated 1.5 million deaths from TB worldwide per year; thus making TB one of the most lethal infectious diseases.<sup>1</sup>

One strategy to reduce TB mortality and the most severe forms of TB is the BCG vaccination, containing a live-attenuated strain of *Mycobacterium bovis*. In Argentina, routine BCG vaccination is mandatory for all newborns before being discharged in order to prevent bacteremia due to *Mycobacterium tuberculosis* primary infection.<sup>2</sup> Globally BCG vaccine is used extensively with approximately 100 million newborns being vaccinated each year. Despite this extensive use, few severe adverse events have been reported (Table).<sup>3</sup>

We present a clinical case report regarding Osteitis/Osteomyelitis secondary to BCG vaccination in an infant.

Received on February 17<sup>th</sup>, 2019. Accepted after evaluation on May 5<sup>th</sup>, 2019 • JAVIER E. DAL LAGO, MD • javierdalago@yahoo.com.ar 

**How to cite this paper:** Dal Lago JE, Levy EJ. Tibia Osteomyelitis secondary to BCG vaccination in an immunocompetent infant. Case report. *Rev Asoc Argent Ortop Traumatol* 2020;85(2):157-166. <http://dx.doi.org/10.15417/issn.1852-7434.2020.85.2.965>

**Table.** BCG vaccination adverse events

Nature of Adverse event	Description	Rate/doses
<b>Mild</b>	Injection site papule (onset 2-4 weeks) Mild ulceration (1-2 months) Scar (2-5 months)	Almost all vaccinees
<b>Severe</b>	<p><b>Local</b></p> Local abscess Keloid Lymphadenitis Suppuration (onset 2-6 months)	1 per 1,000-10,000
	<p><b>Systemic</b> (1-12 months onset time)</p> Cutaneous skin lesions Osteitis Disseminated BCG Immune Reconstitution Syndrome	Case reports only 1 per 3333-1,000,000 1 per 230,000-640,000 1 per 640,000

Data from the Information Sheet on observed rate of vaccine reactions. Bacille Calmette-Guérin (BCG) Vaccine. WHO 2012.

## CLINICAL CASE REPORT

In April 2015, a previously healthy 9-month girl who had complied with the regular vaccination schedule was brought to the Department of Orthopedics outpatient clinic by her mother. The mother reported that for the last couple of days her daughter presented signs of tenderness and defense on palpation of her left ankle. She had noted that her daughter had not been trying to stand up as she used to and that she dragged her left leg while crawling. She reported no history of trauma or fever.

Clinical evaluation revealed pain facies and crying to palpation of the distal third of the leg. The passive mobilization of the ankle revealed no signs of pain. There were no signs of hematoma, swelling or local inflammation.

X-rays of both legs were ordered, which revealed an osteolytic lesion affecting the distal metaphysis of the left tibia (Figure 1).

This finding suggested an initial differential diagnosis including a neoplastic process as well as a bone infection. Therefore, the decision was made to admit the patient for further workup.

Laboratory analysis revealed the following results:

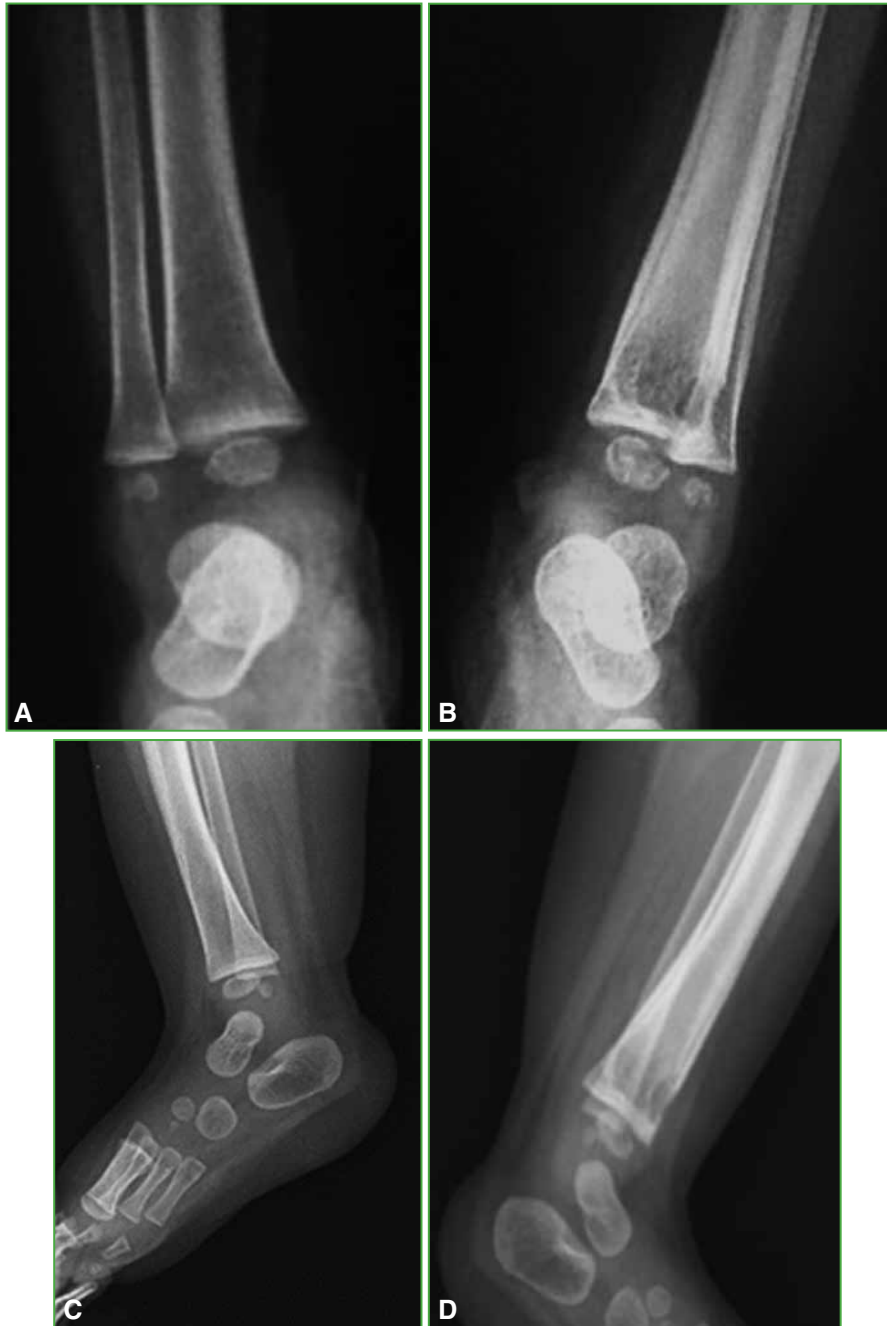Hct 33%, Hb 11.5 g/dL, WBC 9000/mm<sup>3</sup>, platelets 565.000/mm<sup>3</sup>, ESR 34 mm/h, and CRP<0.5 mg/L.

Left ankle MRI was performed under general anesthesia and showed a 10 x 8 mm well-defined lesion at the left distal tibial diaphysis-metaphyseal level, which involved growth plate with sclerotic reaction and adjacent bone marrow edema (Figure 2).

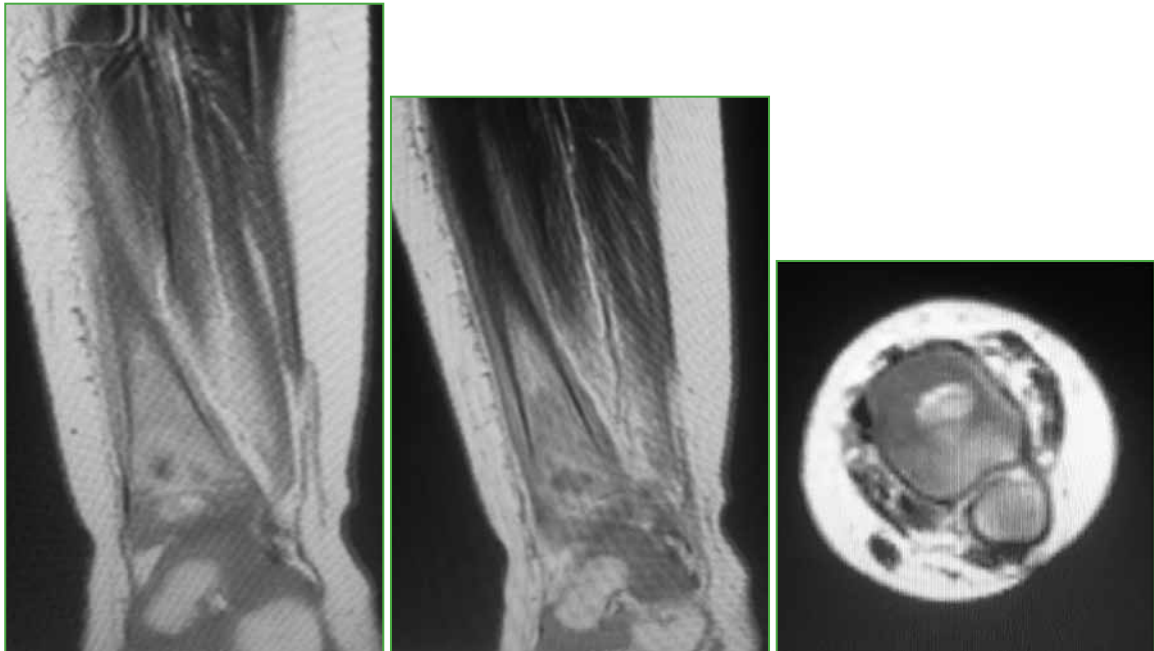
While hospitalized, the patient had her left leg immobilized by a short plaster splint, and a bone biopsy of the lesion was scheduled. Direct analysis revealed no evidence for the bacterium presence and Ziehl-Neelsen staining was negative for acid-fast bacilli.

The histopathological study reported a granulomatous reaction associated with eosinophilic granulomas. The differential diagnoses after these findings were Langerhans cell Histiocytosis and Granulomatous Osteomyelitis.

After the biopsy, the patient had a favorable course and local pain subsided. A watchful waiting strategy was employed while waiting for the bacteriological culture results from the biopsy sample. Meanwhile, other studies were performed.



**Figure 1.** Both ankles anteroposterior and lateral X-rays. **B** and **D.** X-rays evidence osteolytic lesion in the distal metaphysis of the left tibia.



**Figure 2.** Left ankle sagittal and axial MRI sections.

Immunodeficiency was ruled out. Skull and long bone X-rays showed no bone lesions. Blood and cerebrospinal fluid cultures were negative. The eyegrounds examination, visual and auditory evoked potentials tests, and chest X-rays were all normal.

After 3 weeks of incubation, mycobacterium developed in the culture from the biopsy specimen. Genetic analysis using the polymerase chain reaction indicated *Mycobacterium bovis*.

On account of the culture result, the absence of a systemic response to another disease and the possibility of an immune system disorder having been ruled out, it was diagnosed as Osteomyelitis secondary to BCG vaccination.

The treatment provided by the Department of Infectious Diseases consisted of antituberculous drug therapy for 10 months, following this schedule:

- Two weeks, intravenously: rifampicin + isoniazid + ethambutol + streptomycin (initially at the Hospital and later with home hospitalization)
- Eight months, by mouth: rifampicin + isoniazid

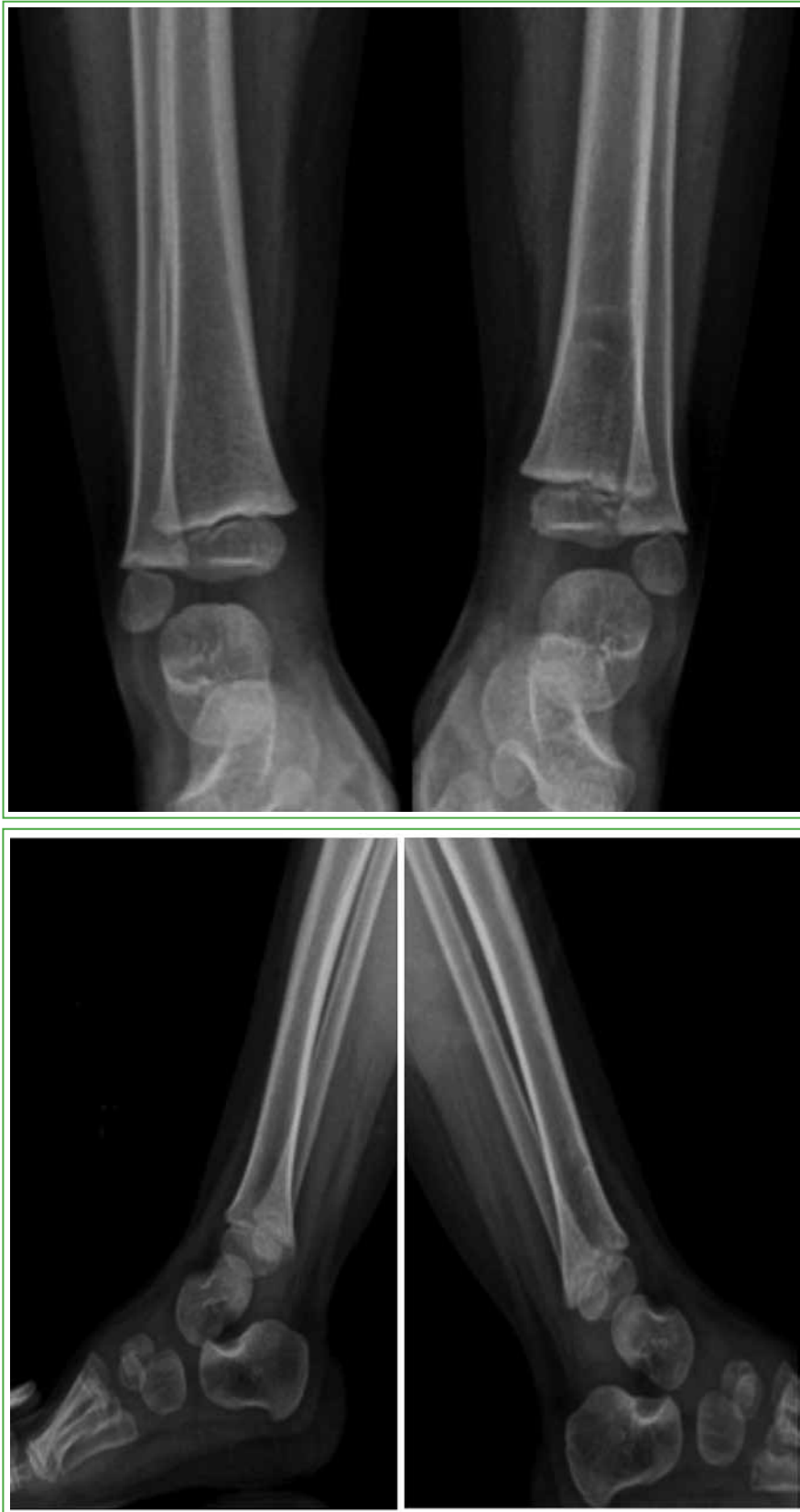The patient had a very favorable course, without signs of pain, motor sequelae, residual damage in skeleton, growth plate involvement nor leg growth disturbance.

The course of the bone lesion may be seen through the postoperative radiographic controls (Figures 3-5).

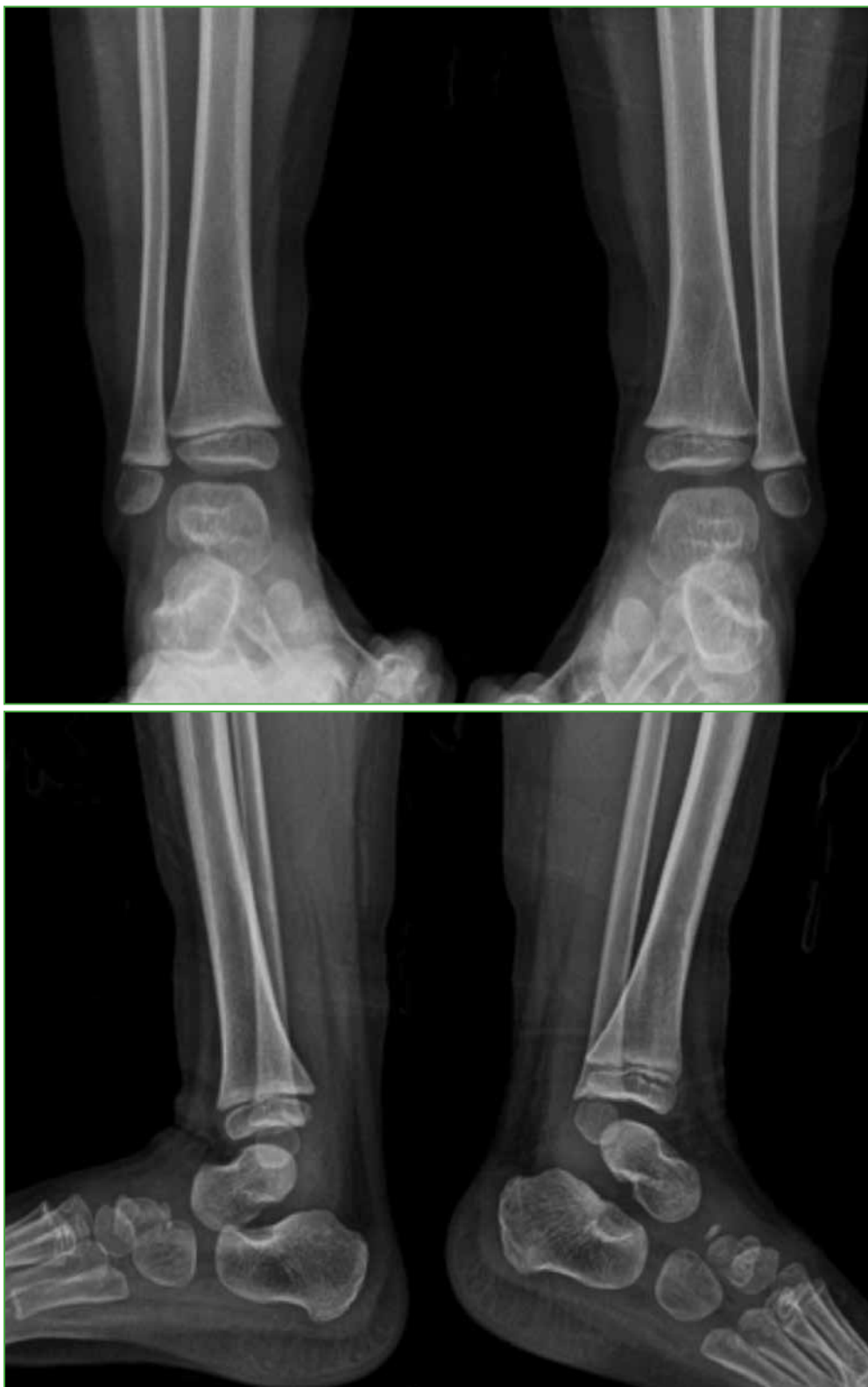## DISCUSSION

### BCG vaccine

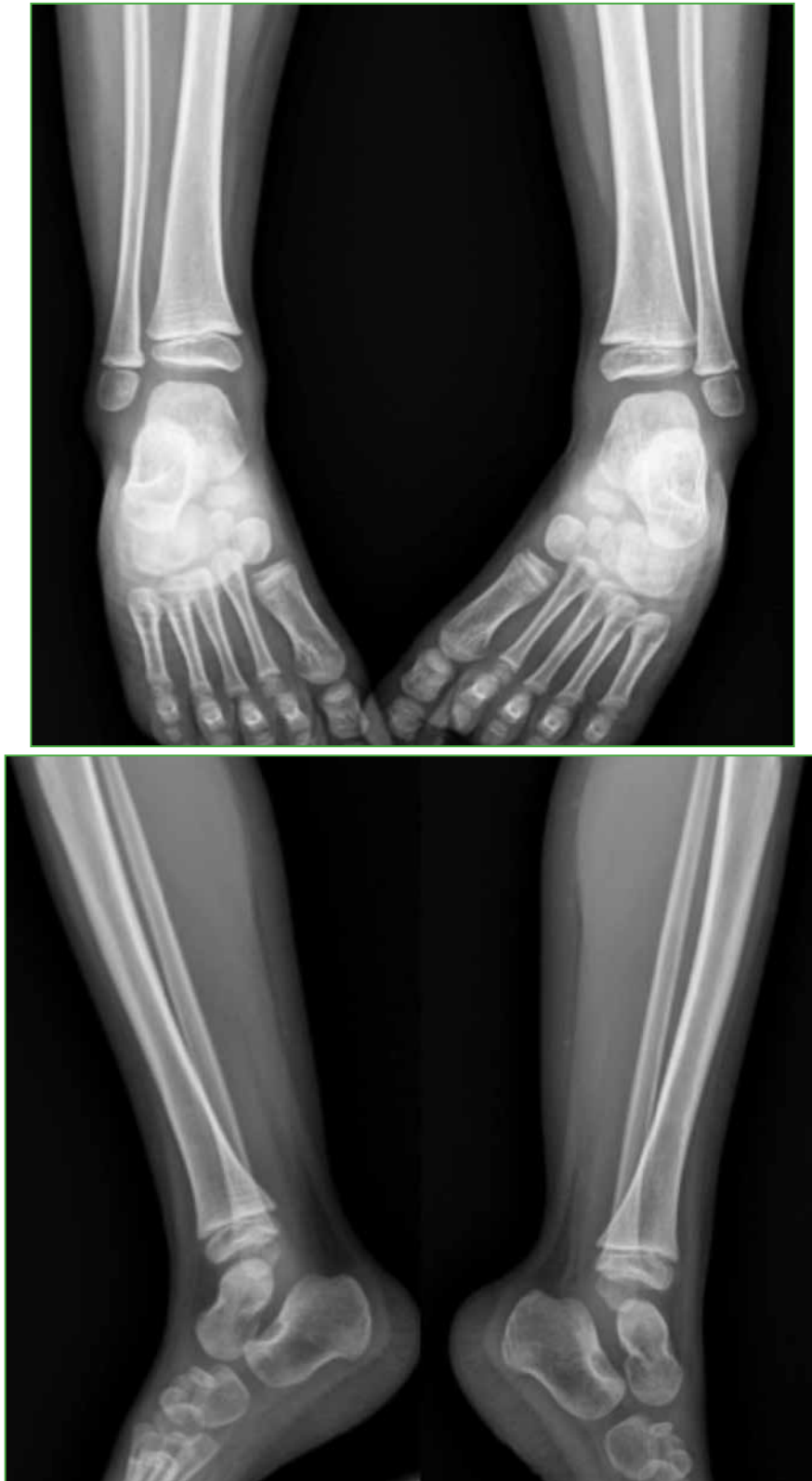BCG vaccine is a freeze-dried preparation containing live bacteria derived from a culture of the weakened bovine bacilli. All the current strains of the vaccine have evolved from the original *M. bovis* isolate that Calmette and Guérin cultured through numerous cycles for 13 years (1909-1921). These strains have an attenuated virulence while maintaining their ability to protect against TB, to cause tuberculin reactivity and to leave a scar in most vaccinees.



**Figure 3.** Both ankles anteroposterior and lateral X-rays, 1 year after the intervention.



**Figure 4.** Both ankles anteroposterior and lateral X-rays, 2 years after the intervention.



**Figure 5.** Both ankle anteroposterior and lateral X-rays, 2 years and 6 months after the intervention.

In time, strains were distributed in various local laboratories, each with its own setting, and went through different culture mediums resulted in substrains with phenotypic and genotypic differences. These substrains were named after the laboratory or city where they had been obtained. The amount of colony-forming units (CFU) of each strain is different: For example:

- Danish: from 2 to 8 million CFU/mL
- Glaxo: from 2 to 10 million CFU/mL
- Moreau: from 2 to 8 million CFU/mL
- Pasteur: from 2 to 8 million CFU/mL
- Tokyo: 30 million CFU/mL
- Public Health Central Laboratory: Pasteur strain (Buenos Aires province): from 3 to 8 million CFU/mL

Vaccine potency depends on the type of strain, the dose, adequate storage, handling, and administration. A constant refrigeration and surveillance system of vaccine temperature and transport until administration is essential. Vaccines should never be exposed to direct sunlight or any other ultraviolet source. Vaccine preparation is currently a standardized method; the World Health Organization is the agency responsible for the control vaccine quality.

Vaccination is intended to prevent tuberculous bacilli multiplication and spread through blood following the primary infection. The vaccine confers its greatest protection effect against severe disseminated TB forms (meningeal and miliar). The BCG vaccine does not prevent exogenous reinfection and its role in endogenous reactivation has not established.

The BCG vaccine is the most extensively used worldwide and Argentina added to its Expanded Program on Immunization since 1974. In Argentina, initial vaccination is given to all newborns with a birth weight  $\geq 2000$ g before leaving the maternity hospital. Children between 1 month and 6 years of age who had not been vaccinated with BCG at birth (without BCG scar or administration record) will be vaccinated once TB is ruled out, provided they are not immunologically compromised.

BCG-immunity period is estimated to be less than 10 years.

The risk of sustaining an adverse reaction is associated with the vaccine strain used by manufacturers, the dose administered, the age of the recipient, the technique of administration, and, in some cases, immunity disorders. The adverse reactions may be:

#### *Local:*

- Prolonged ulceration
- Abscess formation
- Local and enlarged or suppurative lymphadenopathies, with or without fistula formation (the presence of a small axillary lymphadenopathy may be considered normal).
- Lupus-like reaction

These reactions are mild or moderate and heal spontaneously, although their course is prolonged. None of them require surgery or local or systemic drug therapy.

#### *Systemic:*

- Disseminated BCG infection (from 1 to 12 months after inoculation): 2/1,000,000 administered vaccines.
- BCG-associated Osteitis or Osteomyelitis (from 1 to 12 months after inoculation): 1-700/1,000,000 administered vaccines.

These complications have been observed especially among patients with AIDS or other diseases that affect the immune system who were wrongly vaccinated.<sup>4</sup>

The BCG vaccine is contraindicated for patients with:

- Pathologies severely affecting the general condition
- Generalized skin conditions
- Infectious disease (especially measles and chickenpox); administration should be delayed 1 month following these infections resolution.
- Congenital or acquired immunosuppression



- Prolonged corticosteroid or immunosuppressant therapy
- Premature newborns weighing under 2,000g. The vaccine must be administered once the newborn weight is over 2,000g.

Osteitis and Osteomyelitis secondary to BCG vaccination are rare and severe complications which have primarily been reported in Scandinavia and Eastern Europe and typically associated with changes in BCG vaccine strain. There was a report of an increase in Osteitis to 35 per million in Czechoslovakia after a shift from the Prague to the Russian BCG strain (Lotte, *et al.*, 1988). Both Finland and Sweden reported increases in Osteitis after 1971 when they shifted to a Gothenburg strain produced in Denmark. Sweden reported rates as high as 1 in 3,000 vaccine recipients, which declined rapidly when the national program shifted to a Danish (Copenhagen, 1331) vaccine strain. More recently reports of Osteitis have become infrequent.<sup>3,6</sup> In 2015 Lyn *et al.* conducted a systematic review on BCG vaccination-related Osteomyelitis/Osteitis in immunocompetent children. They analyzed 34 studies published between 1976 and 2012 containing 331 cases of BCG Osteomyelitis. The results show that in most cases bone involvement was associated with a single and well-defined osteolytic lesion. As to the locations of lesions, 55.6% of the cases involved lower limbs, while 15.4% involved upper limbs; 26.0% involved the axial skeletons (spine, sternum, ribs, etc.); and only 3.0% involved simultaneously multiple bones. In 97.6% of the cases, clinical course and resolution were favorable and without sequelae. The authors concluded that antituberculous drug treatment should suffice and is the best treatment option for immunocompetent children. Surgical interventions are useful, especially in procedures for infection diagnostic purposes, including aspiration biopsy. More aggressive surgical procedures should be avoided, including lesion curettage in children when their skeleton is still immature, as they may result in permanent bone deformities secondary to the growth plate lesion (limb malalignment or discrepancy).<sup>7</sup>

Our findings are consistent with the literature review of Lin *et al.*, since our patient had a single lower limb osteolytic lesion. Also, drug therapy and symptomatic treatment proved sufficient to achieve good functional outcomes, with no clinical or radiological evidence of sequelae.

We conclude that this rare condition should always be suspected in infants presenting a lytic bone lesion, with no evident signs of a bacterial infection or neoplastic disease. In such situations, the bacteriological study should include the analysis of rare microorganisms, such as fungi, acid-fast bacilli and microbacteria, from the biopsy samples. As it is a rare condition and management experience is limited, we are incapable to establish standardized steps for treatment decision making.

---

Conflict of interests: Authors claim they do not have any conflict of interests.

E. J. Levy ORCID ID: <https://orcid.org/0000-0002-9158-8617>

## REFERENCES

1. World Health Organization. Global Tuberculosis Report 2015. Geneva: World Health Organization; 2015. <https://apps.who.int/medicinedocs/documents/s22199en/s22199en.pdf>
2. Ministerio de Salud de la República Argentina. Recomendaciones Nacionales de Vacunación Argentina 2012. [http://www.msal.gov.ar/images/stories/bes/graficos/0000000451cnt-2013-06\\_recomendaciones-vacunacion-argentina-2012.pdf](http://www.msal.gov.ar/images/stories/bes/graficos/0000000451cnt-2013-06_recomendaciones-vacunacion-argentina-2012.pdf)
3. Organización Mundial de la Salud. Hoja de información sobre las tasas observadas de reacciones a vacunas. Vacuna Bacilo de Calmette-Guérin (BCG); 2012. [https://www.who.int/vaccine\\_safety/initiative/tools/BCG\\_Vaccine\\_rates\\_information\\_sheet\\_ES.pdf?ua=1](https://www.who.int/vaccine_safety/initiative/tools/BCG_Vaccine_rates_information_sheet_ES.pdf?ua=1)
4. Ministerio de Salud de la República Argentina. Vacunación Segura: Vigilancia de eventos supuestamente atribuibles a la vacunación o inmunización (ESAVI); 2012. [http://www.msal.gov.ar/images/stories/bes/graficos/0000000448cnt-2014-01\\_manual-vacunacion-segura-esavi.pdf](http://www.msal.gov.ar/images/stories/bes/graficos/0000000448cnt-2014-01_manual-vacunacion-segura-esavi.pdf)

5. Lotte A, Wasz-Hockert O, Poisson N, Engbaek H, Landmann H, Quast U, et al. Second IUATLD study on complications induced by intradermal BCG-vaccination. *Bull Int Union Tuberc Lung Dis* 1988;63(2):47-59. PMID: 3066422
6. Organización Mundial de la Salud. Documento de posición de la OMS sobre las vacunas BCG. *Boletín Epidemiológico Semanal* 2018;8(93):73-96. [http://www9.who.int/immunization/policy/position\\_papers/pp\\_bgc\\_2018\\_ES.pdf](http://www9.who.int/immunization/policy/position_papers/pp_bgc_2018_ES.pdf)
7. Lin WL, Chiu NC, Lee PH, Huang AS, Huang FY, Chi H, et al. Review management of Bacillus Calmette-Guérin osteomyelitis/osteitis in immunocompetent children-A systematic review. *Vaccine* 2015;33(36):4391-7. <https://doi.org/10.1016/j.vaccine.2015.07.039>