

Spontaneous epidural hematoma of spine associated with acenocoumarol: A case study

Verónica Chuliá Carrasco,* Patricia Gómez Barbero**

*Orthopedic and Traumatologic Surgery Department, Hospital Lluís Alcanyis, Xativa (Valencia, Spain)

**Orthopedic and Traumatologic Surgery Department, Hospital Universitario Dr Peset (Valencia, Spain)

ABSTRACT

Spontaneous spinal epidural hematoma is an uncommon clinical entity that supposes a neurological emergency when it presents. The clinical presentation of the above-mentioned entity is very variable, appearing from a backache up to a tetraplegia, according to the severity and level of compression. We introduce the clinical case of a cardiac 71-year-old patient, in previous treatment with acenocoumarol, that presented a spontaneous epidural hematoma. The patient, being previously asymptomatic, presented as he bent over, sudden cervical pain followed by weakness in low and top members. Due to the clinical suspicion, an emergency MRI was performed, which showed a hematoma of epidural location with extension from C4 up to T8. Early diagnosis and decompressive treatment are mandatory to minimize permanent neurological damages.

Key words: Spinal spontaneous hematoma; acenocoumarol; decompressive hemilaminectomy.

Level of Evidence: IV

Hematoma espinal epidural espontáneo asociado a tratamiento anticoagulante con acenocoumarol: a propósito de un caso

RESUMEN

El hematoma epidural espontáneo es una entidad muy poco frecuente que supone una urgencia neurológica. Su presentación es muy variable, desde un dolor de espalda hasta una tetraplejía, según la gravedad y el nivel de compresión. Se comunica el caso de un paciente cardíopata de 71 años, tratado con acenocoumarol, que presentó un hematoma epidural de modo espontáneo. Al inclinarse hacia el suelo, el paciente, que no tenía síntomas, sufrió un dolor brusco cervical seguido de debilidad en los miembros superiores e inferiores. Ante la sospecha clínica de una compresión medular, se decide realizar una resonancia magnética de urgencia, que mostró un hematoma de localización epidural con extensión desde C4 hasta T8. El diagnóstico urgente y el tratamiento de descompresión precoz son fundamentales para reducir al mínimo los daños neurológicos posteriores permanentes.

Palabras clave: Hematoma espinal espontáneo; acenocoumarol; hemilaminectomía descompresiva.

Nivel de Evidencia: IV

INTRODUCTION

Spontaneous spinal epidural hematoma is an uncommon condition, but it causes high morbidity and mortality. It has an estimated incidence of less than 1/100,000 patients per year and accounts for less than 1% of all spinal canal space-occupying lesions.¹

It has been associated with thrombophilia, hemophilia, anticoagulant therapy, platelet suppressive agents, vascular malformations, and hypertensive crises or excessive effort.^{2,3}

Patients with spontaneous spinal epidural hematoma typically present with sudden neck or back pain, which corresponds with the affected dermatome. Pain sometimes radiates into the limbs, and there are nerve root and spinal cord compression symptoms that worsen over time.

Received on August 18th, 2018. Accepted after evaluation on December 6th, 2018 • VERÓNICA CHULIÁ CARRASCO, MD • veronica.chulia@gmail.com 

How to cite this paper: Chulia Carrasco V, Gómez Barbero P. Spontaneous epidural hematoma of spine associated with acenocoumarol: A case study. *Rev Asoc Argent Ortop Traumatol* 2019;84(3):260-264. <http://dx.doi.org/10.15417/issn.1852-7434.2019.84.3.892>

Since it is a rare condition that causes atypical and dissimilar symptoms, clinical suspicion is essential to guide early diagnosis that is confirmed by magnetic resonance imaging (MRI). In addition, MRI is mandatory to guide a potential emergency surgery.⁴

Appropriate treatment includes emergency decompressive surgery, so the severity and extension of subsequent neurological damage depend on the time such surgery is performed.^{5,6}

The aim of this paper is to highlight the importance of rapid diagnosis and early treatment in order to avoid neurological consequences.

CASE REPORT

A 71-year-old retired man came to the Orthopedics and Traumatology Surgery Emergency Department due to upper and lower extremity weakness. He had history of type 1 diabetes mellitus, persistent atrial fibrillation and high blood pressure, as well as acute coronary syndrome and infrarenal abdominal aortic aneurysm treated with an aortic endoprosthesis. His medical treatment combined oral antidiabetic and antihypertensive drugs, acenocoumarol and aspirin 100 mg.

Before his admission, the patient was independent in basic activities of daily living and was able to control his bowel and bladder.

In the clinical interview conducted at the Emergency Department, the patient said that, being previously asymptomatic, presented as he bent over, sudden cervical pain followed by progressive upper and lower extremity weakness.

During assessment, he was conscious, oriented, afebrile and cooperative. Review of symptoms did not provide remarkable information.

Upon medical examination, he had paraplegia and pain when the last spinous processes were palpated. His muscle strength scored as 3/5 in his upper limbs under the Medical Research Council grading system. His neurological examination revealed loss of reflexes in lower limbs and unaltered reflexes in upper limbs. His sensory level was on T3 (supramammillary area).

After the first assessment, the patient was immobilized with a rigid cervical collar and a spinal board, and methylprednisolone 200 mg, fentanyl citrate 0.07 mg, vitamin K (one vial IV) and fluid therapy 1,500 ml were administered.

At first, differential diagnosis with a stroke was established. However, since he had cervical pain and tetraplegia, spinal cord compression was more likely, so an emergency RMI was requested.

Complete lab tests were also requested before the RMI. Their results were within normal ranges. Coagulation test results showed: prothrombin time 21.2 s, prothrombin time 1.93, Quick's value 39%, INR 1.91, activated partial thromboplastin time 35.4 s and fibrinogen 424 mg/dl. All these values were within the range of an anticoagulated patient treated with acenocoumarol.

The MRI identified a 22 cm long heterogeneous collection in the cervicodorsal spinal canal, which extended from C4 to T8, had posterior epidural-subdural location and significantly compressed the spinal cord (Figure). Due to signal features and patient's medical history, it was associated with a blood collection. It was not possible to determine the source of bleeding from spinal canal vessels; no vascular malformations or any other reasons were found. Compression was more significant from C5 to T1 as a result of degenerative disc disease with osteophytes and small protrusions. The spinal cord was compressed along this segment and showed a slight alteration in signal intensity, which indicated potential contusion or edema.

At that moment, the diagnosis of epidural hematoma of cervical spine with spinal cord compression was confirmed, and an emergency decompressive surgery was scheduled. Four vials of vitamin K-dependent coagulation factor were administered prior to the surgery.

The decompressive surgery was performed about four hours after the patient was admitted to the Emergency Department. During this procedure, the cervical spine was exposed along C4-T5 posterior midline, and a large hematoma surrounding and compressing the spinal cord from C4 to T5 was observed.

A superior and inferior hemilaminectomy from C4 to T5 as well as evacuation of the hematoma were performed until it was confirmed that the spinal cord was free and there was adequate flow below laminae, which were also resected at the level of their dome.

Finally, the area was irrigated with plenty of saline solution and, after careful hemostasis, a layered closure was performed with muscle anchoring to spinous processes from C6 to T5, keeping two low-vacuum Redon drains for 48 hours.

At the immediate postoperative stage, the patient showed appropriate medical response, progressive neurological improvement, sensory level recovery and 3/5 muscle strength. However, two days after the surgery, the patient experienced pulmonary compromise that led to his death.

DISCUSSION

Spontaneous spinal epidural hematoma is a rare but important neurological emergency; early diagnosis and treatment are vital to prevent patients' morbidity and mortality. According to reviewed literature, it generally occurs among adult patients, between the ages of 50 and 80 years,¹ and it does not differentiate between sexes, with a male/female ratio of 1.4/1.⁷ Although 40% of hematomas are of unknown origin,⁸ there are a number of predisposing factors that should make us think of a spontaneous hematoma, such as previous anticoagulant or platelet suppressive therapy, previous thrombolysis due to a heart attack, hemophilia or factor XI deficiency, cocaine abuse, Paget's disease or vascular malformations.^{4,8} In our case, the patient was anticoagulated and had controlled high blood pressure. Nowadays, duly controlled high blood pressure is not considered a risk factor. However, circumstances that increase blood pressure, such as making effort, sneezing and weightlifting, are considered predisposing factors.

Even though it is an unusual disease with confusing symptoms, cervical or lumbar pain of sudden onset, which does not stop with analgesics, along with progressive neurological symptoms, should cause the suspicion of a spontaneous epidural hematoma. If the patient has a cervical or dorsal hematoma, pain is quickly followed by neurological compromise as a result of epidural canal stenosis between T3 and T9. Differential diagnosis should include herniated disc, epidural abscess or neoplastic mass. The study of choice to confirm this diagnosis is the emergency MRI, because it allows physicians to see the precise location, dimension, extension and distribution of the hematoma, as well as to assess spinal cord compromise, compression or edema. A CT scan may be an alternative if the emergency RMI is not available or is contraindicated.^{6,9,10}

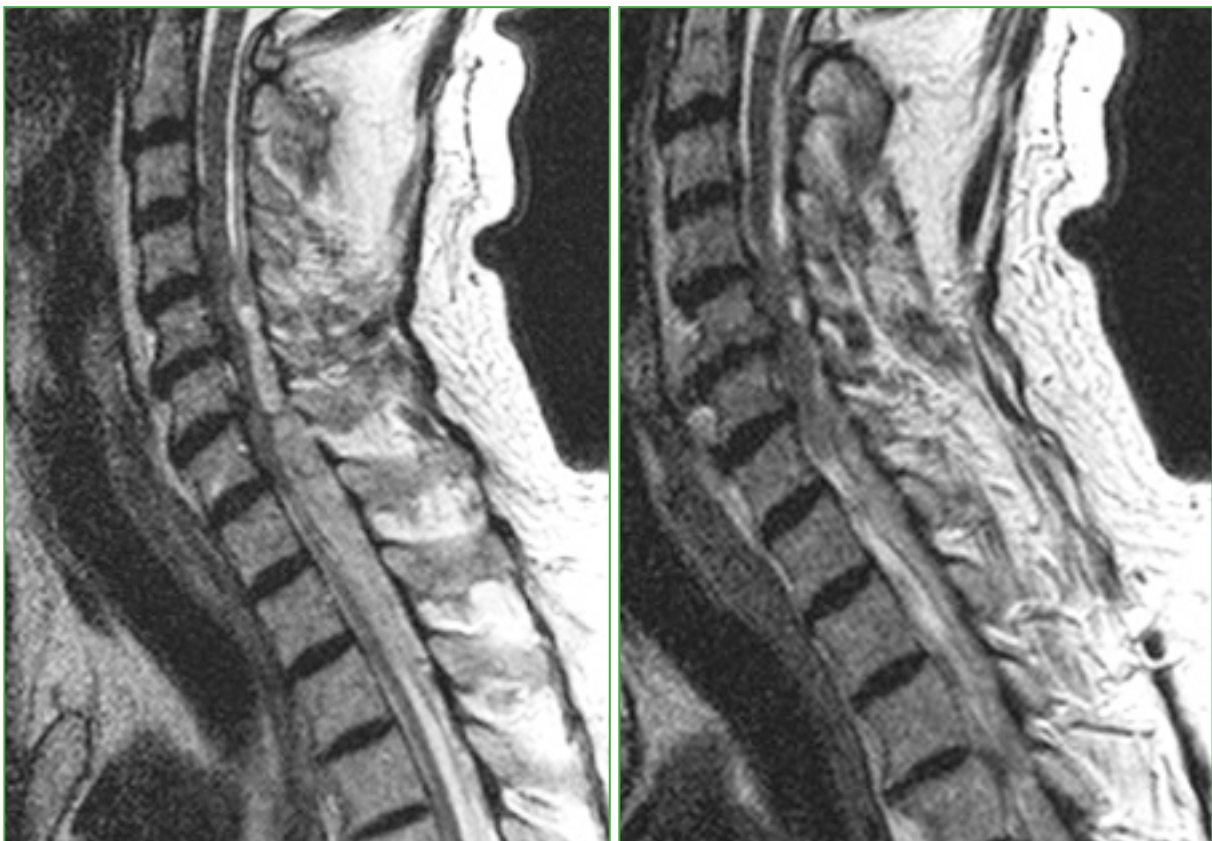


Figure. T2-weighted magnetic resonance imaging of the cervical-dorsal region. A blood collection is observed from C4 to T8.

The hematoma is most commonly located in the cervical spine, in or under the thoracolumbar junction. In the literature review, 29% of hematomas were located in the cervical region, 21% were cervicothoracic, 29% were thoracic and 21% were in the lumbar region.⁶ The etiology of hematomas is still a topic of debate. Most studies suggest that bleeding comes from the epidural venous plexus, which has laxer valves affected by pressure changes in thoracic and abdominal cavities. In addition, it has been observed that hematomas with segmental distribution typically show posterolateral location.^{11,12} However, other authors¹³⁻¹⁵ hold that hematomas are the result of arterial bleeding due to their quick formation and the fact that epidural blood pressure is lower than intrathecal pressure. In our case, emergency images did not identify the source of bleeding.

Emergency surgical treatment is the most important step in these cases because treatment outcome depends on the time between symptom onset and decompressive surgery, as well as the severity of initial neurological deficit. Groen and van Alphen¹² reviewed 333 cases of spontaneous spinal epidural hematoma and concluded that delay in surgery is the main factor predicting prognosis. They recommend performing the surgery within the first 48 hours in cases involving incomplete neurological compromise and within 36 hours in cases of complete neurological compromise. Some papers even recommend performing the surgery within the first 12 hours.^{1,12,16} However, they conclude that, despite early treatment, complete sensorimotor loss is very likely to persist after the surgery, but there is a greater chance of recovery in cases of partial compromise.¹ On the other hand, a review of 158 cases of spinal hematoma treated an emergency decompressive surgery found that complete sensorimotor recovery occurred in 41.9%, 26.1%, and 11.3% of the patients with incomplete sensorimotor, incomplete sensory but complete motor, and complete sensorimotor lesions, respectively.¹⁷ Some authors believe that motor compromise of rapid onset is a predictive factor for bad prognosis.¹⁰

The recommended surgical procedure is the one used in our case: decompression through hemilaminectomy or laminectomy and hematoma evacuation. There are some studies about conservative management, which is only indicated if neurological symptoms improve within the first 12 hours.^{8,18} There are no statistically significant results that ensure that an emergency surgery predicts better prognosis. However, an emergency surgery is still recommended to recover spinal function unless there is early neurological recovery. A review of 183 cases of spontaneous spinal epidural hematoma showed that 93% of patients treated within the first 48 hours had a satisfactory neurological recovery.¹⁹

CONCLUSIONS

Spontaneous spinal epidural hematoma is a rare condition, but it causes severe spinal cord compression. Considering risk factors and contemplating this condition in case of spinal pain along with neurological signs is critical for prognosis.

The study of choice for diagnosis is the emergency MRI, which will confirm and define the injury. Decompressive surgery allows spinal cord decompression and neurological deficit reversion. The interval between neurological symptom onset and decompressive surgical treatment affects prognosis and potential consequences. In addition, patients with incomplete preoperative neurological deficit show better outcomes with less rehabilitation. Conservative treatment is not recommended unless patient's neurological deficit has relieved spontaneously in the early period.

Conflict of interest: Authors claim they do not have any conflict of interest.

P. Gómez Barbero ORCID ID: <https://orcid.org/0000-0002-4566-4666>

REFERENCES

1. Hsieh CT, Chang CF, Lin EY, Tsai TH, Chiang YH, Ju DT. Spontaneous spinal epidural hematomas of cervical spine: report of 4 cases and literature review. *Am J Emerg Med* 2006;24(6):736-40. <https://doi.org/10.1016/j.ajem.2006.01.025>
2. Seet RCS, Lim ECH, Wilder-Smith EP V, Ong BKC. Spontaneous epidural haematoma presenting as cord compression in a patient receiving clopidogrel. *Eur J Neurol* 2005;12(10):811-2. <https://doi.org/10.1111/j.1468-1331.2005.01057.x>
3. Zhong W, Chen H, You C, Li J, Liu Y, Huang S. Spontaneous spinal epidural hematoma. *J Clin Neurosci* 2011; 18(11):1490-94. <https://doi.org/10.1016/j.jocn.2011.02.039>
4. Yu JX, Liu J, He C, Sun LY, Xiang SS, Ma YJ, et al. Spontaneous spinal epidural hematoma: a study of 55 cases focused on the etiology and treatment strategy. *World Neurosurg* 2017;98:546-54. <https://doi.org/10.1016/j.wneu.2016.11.077>
5. Yamao Y, Takagi Y, Kawauchi T, Arakawa Y, Takayama M, Miyamoto S. Surgical management of recurrent spontaneous spinal epidural hematoma with 3 episodes. *Spine (Phila Pa 1976)* 2015;40(17):E996-8. <https://doi.org/10.1097/BRS.0000000000001017>
6. Shin J J, Kuh S U, Cho Y E. Surgical management of spontaneous spinal epidural hematoma. *Eur Spine J* 2006; 15(6):998-1004. <https://doi.org/10.1007/s00586-005-0965-8>
7. Groen RJ, Ponsse H. The spontaneous spinal epidural hematoma. A study of the etiology. *J Neurol Sci* 1990;98 (2-3):121-38. PMID: 2243224
8. Liu Z, Jiao Q, Xu J, Wang X, Li S, You C. Spontaneous spinal epidural hematoma: analysis of 23 cases. *Surg Neurol* 2008;69(3):253-60. <https://doi.org/10.1016/j.surneu.2007.02.019>
9. Küker W, Thiex R, Friese S, Freudenstein D, Reinges MH, Ernemann U, et al. Spinal subdural and epidural haematomas: Diagnostic and therapeutic aspects in acute and subacute cases. *Acta Neurochir (Wien)* 2000;142(7): 777-85. PMID: 10955672
10. Hussenbocus SM, Wilby MJ, Cain C, Hall D. Spontaneous spinal epidural hematoma: a case report and literature review. *J Emerg Med* 2012;42(2):e31-4. <https://doi.org/10.1016/j.jemermed.2008.08.008>
11. Groen RJM. Non-operative treatment of spontaneous spinal epidural hematomas: a review of the literature and a comparison with operative cases. *Acta Neurochir (Wien)* 2004;146(2):103-10. <https://doi.org/10.1007/s00701-003-0160-9>
12. Groen RJM, van Alphen HAM. Operative treatment of spontaneous spinal epidural hematomas: A study of the factors determining postoperative outcome. *Neurosurgery* 1996;39(3):494-508. <https://doi.org/10.1097/00006123-199609000-00012>
13. Miyagi Y, Miyazono M, Kamikaseda K. Spinal epidural vascular malformation presenting in association with a spontaneously resolved acute epidural hematoma. *J Neurosurg* 1998;88(5):909-11. <https://doi.org/10.3171/jns.1998.88.5.0909>
14. Beatty RM, Winston KR. Spontaneous cervical epidural hematoma. A consideration of etiology. *J Neurosurg* 1984; 61(1):143-8. <https://doi.org/10.3171/jns.1984.61.1.0143>
15. Dinsmore AJ, Leonard RB, Manthey D. Spontaneous spinal epidural hematoma: A case report. *J Emerg Med* 2005; 28(4):423-6. <https://doi.org/10.1016/j.jemermed.2004.11.023>
16. Kreppel D, Antoniadis G, Seeling W. Spinal hematoma: A literature survey with meta-analysis of 613 patients. *Neurosurg Rev* 2003;26(1):1-49. <https://doi.org/10.1007/s10143-002-0224-y>
17. Foo D, Rossier AB. Preoperative neurological status in predicting surgical outcome of spinal epidural hematomas. *Surg Neurol* 1981;15(5):389-401. PMID: 9760981
18. Wagner S, Forsting M, Hacke W. Spontaneous resolution of a large spinal epidural hematoma: case report. *Neurosurgery* 1996;38(4):816-8. PMID: 8692404
19. Shimada N, Sugawara T, Itoh Y, et al. [Four cases of spontaneous spinal epidural hematoma]. *No Shinkei Geka* 2005;33(2):163-8. (en japonés) PMID: 15714962