

# Bone lengthening with external mini-fixator as treatment for brachymetatarsia

Francisco J. Sánchez Villanueva,<sup>†</sup> Pablo A. Suárez Villalobos,<sup>†</sup> Matías Sepúlveda Oviedo<sup>\*\*</sup>

<sup>†</sup>Department of Orthopedics and Traumatology, Hospital Base Osorno (Chile)

<sup>\*\*</sup>Department of Orthopedics and Traumatology, Hospital Base Valdivia (Chile)

## ABSTRACT

**Introduction:** Brachymetatarsia is a shortening of any metatarsal bone, mainly due to premature growth arrest of the growth plate. It is more common in women, the fourth and the first metatarsals being the most affected bones. The aim of this study was to evaluate the outcomes of progressive bone lengthening with an external mini-fixator. **Materials and Methods:** This was a retrospective, descriptive, case series study in which we analyzed the outcomes of all patients operated on with this technique in our Center. Six cases were evaluated, two of which presented bilateral brachymetatarsia. All patients were women and had brachymetatarsia of the 4<sup>th</sup> metatarsal. The average age was 14 years. The following aspects were evaluated: lengthening in millimetres and presence of complications, such as delayed consolidation, infection, metatarsophalangeal joint dislocation, metatarsophalangeal joint flexion, and patient satisfaction. **Results:** On average, a 15 mm-lengthening was achieved. Two patients presented superficial infection at the screw insertion site. One patient progressed to metatarsophalangeal joint dislocation, and another one to metatarsophalangeal joint flexion. No neurovascular complications were observed. **Conclusions:** Bone lengthening with external fixator is a safe and effective treatment. A greater length in millimetres can be achieved in comparison to one-stage lengthening, as well as an improved soft-tissue and neurovascular stretching. All complications resolved smoothly and did not affect final treatment results. Complications were similar to those described in the international literature.

**Key words:** Brachymetatarsia; metatarsals; bone lengthening.

**Level of evidence:** IV

## Alargamiento óseo con minitutor externo como tratamiento de braquimetatarsianos

## RESUMEN

**Introducción:** La braquimetatarsia es un acortamiento de algún metatarsiano, debido principalmente a una detención prematura del crecimiento de la fisis. Es más frecuente en mujeres, y afecta, sobre todo, al cuarto y al primer metatarsiano. El objetivo de este estudio fue evaluar los resultados del tratamiento mediante alargamiento óseo progresivo con minitutor externo. **Materiales y Métodos:** Estudio descriptivo retrospectivo. Serie de casos. Se analizaron los resultados de los pacientes operados con esta técnica en nuestro Centro. Se analizaron 6 casos, dos con braquimetatarsia bilateral. Todas eran mujeres y tenían braquimetatarsia del 4.º metatarsiano. El promedio de edad era de 14 años. Se evaluaron los siguientes aspectos: alargamiento en milímetros y complicaciones, como retraso de la consolidación, infección, luxación metatarsofalángica, articulación metatarsofalángica en flexión y satisfacción del paciente. **Resultados:** Se logró un alargamiento promedio de 15 mm. Dos pacientes tuvieron una infección superficial de las agujas. Una paciente evolucionó con luxación de la articulación metatarsofalángica; otra, con flexión de la articulación metatarsofalángica. No hubo complicaciones neurovasculares. **Conclusiones:** El alargamiento óseo guiado con tutor externo es un tratamiento seguro y eficaz, además lograría un largo mayor en milímetros que el alargamiento en un tiempo, con un mejor control del alargamiento de partes blandas y estructuras neurovasculares. Todas las complicaciones se resolvieron de manera simple, no afectaron el resultado final del tratamiento. Las complicaciones concuerdan con las descritas en la literatura internacional.

**Palabras clave:** Braquimetatarsia; metatarsianos; alargamiento óseo.

**Nivel de Evidencia:** IV

Received on May 28, 2018. Accepted after evaluation on July 7, 2018 • FRANCISCO J. SÁNCHEZ VILLANUEVA, MD • fsanvil@gmail.com 

**How to cite this paper:** Sánchez Villanueva FJ, Suárez Villalobos PA, Sepúlveda Oviedo M. Bone lengthening with external mini-fixator as treatment for brachymetatarsia. *Rev Asoc Argent Ortop Traumatol* 2019;84(1):8-14. <http://dx.doi.org/10.15417/issn.1852-7434.2019.84.1.862>

## INTRODUCTION

Brachymetatarsia or hypoplastic metatarsus is defined as an abnormal shortening of the metatarsal bone due to a premature growth arrest of the growth plate. This can occur due to congenital, traumatic, tumoral or iatrogenic causes, or it can be associated with multiple syndromes (Down, Turner, Apert, etc.). It is more common in women, with a male:female ratio of 25:1. The 4<sup>th</sup> metatarsal is the most affected bone, and it has been reported that it presents bilaterally in up to 72% of cases<sup>1</sup>.

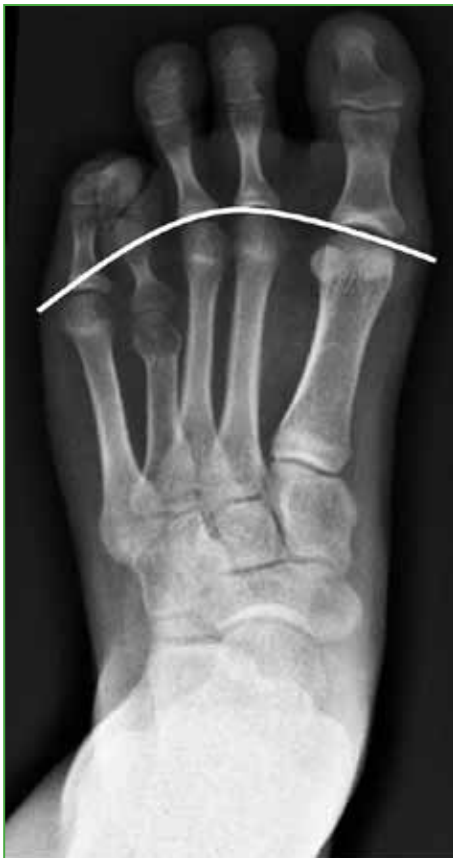X-rays confirmed the diagnosis of brachymetatarsia. AP X-rays showed a metatarsal under 5 mm proximal to the arch created by the metatarsal heads (Figure 1)<sup>2</sup>.

The affected metatarsal, being shorter, is not able to support the physiological weight. This condition can cause transfer metatarsalgia, clinically manifesting as calluses in the region of the adjacent metatarsal heads and pain. Despite this, cosmetic reasons due to the shortening of the metatarsal, which becomes evident at approximately 10 years old, are the main reason for consultation (Figure 2)<sup>1,2</sup>.

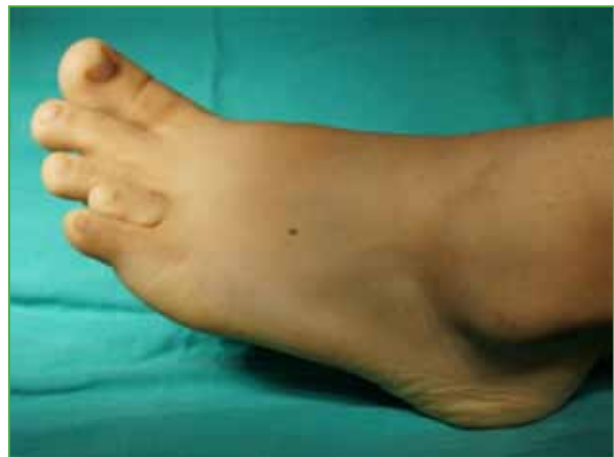According to the literature, surgical treatment offers better results after growth plate closure, which occurs between 14 and 21 years of age<sup>3</sup>.

Different surgical approaches have been published to treat brachymetatarsia, such as one-stage lengthening osteotomies using an autograft (taken from the heel bone, the navicular bone, the iliac crest, the tibia, or the fibula), an allograft or synthetic substitutes. Other approaches include metatarsophalangeal joint arthroplasty and bone lengthening by callus distraction. In addition, shortening osteotomies of the metatarsals and phalanges can be performed together with all these options.

This study aims to show the results of the treatment that we employ in our Center (bone lengthening with the Pennig® external mini-fixator [Orthofix, Texas, USA]), describe the surgical approach and discuss the complications derived from it.



**Figure 1.** AP X-ray of the foot (weight-bearing). An arch created by metatarsal heads can be observed.



**Figure 2.** Preoperative image.

## MATERIALS AND METHODS

We carried out a retrospective descriptive study for the evaluation of the results achieved by osteotomy and callus distraction with an external mini-tutor (Pennig®, Orthofix, Texas, USA) in patients operated on between 2012 and 2016 at the Hospital Base Valdivia, in Chile.

During this period, four patients were operated on with this approach, two of which had bilateral involvement, so six feet were analyzed. Osteotomies and placement of fixators were in charge of the same surgeon.

We evaluated aspects, such as millimetres of lengthening achieved; complications, such as delayed consolidation, infection, neurovascular complications, metatarsophalangeal joint dislocation, metatarsophalangeal joint flexion; and patient satisfaction.

### Surgical approach and postoperative management

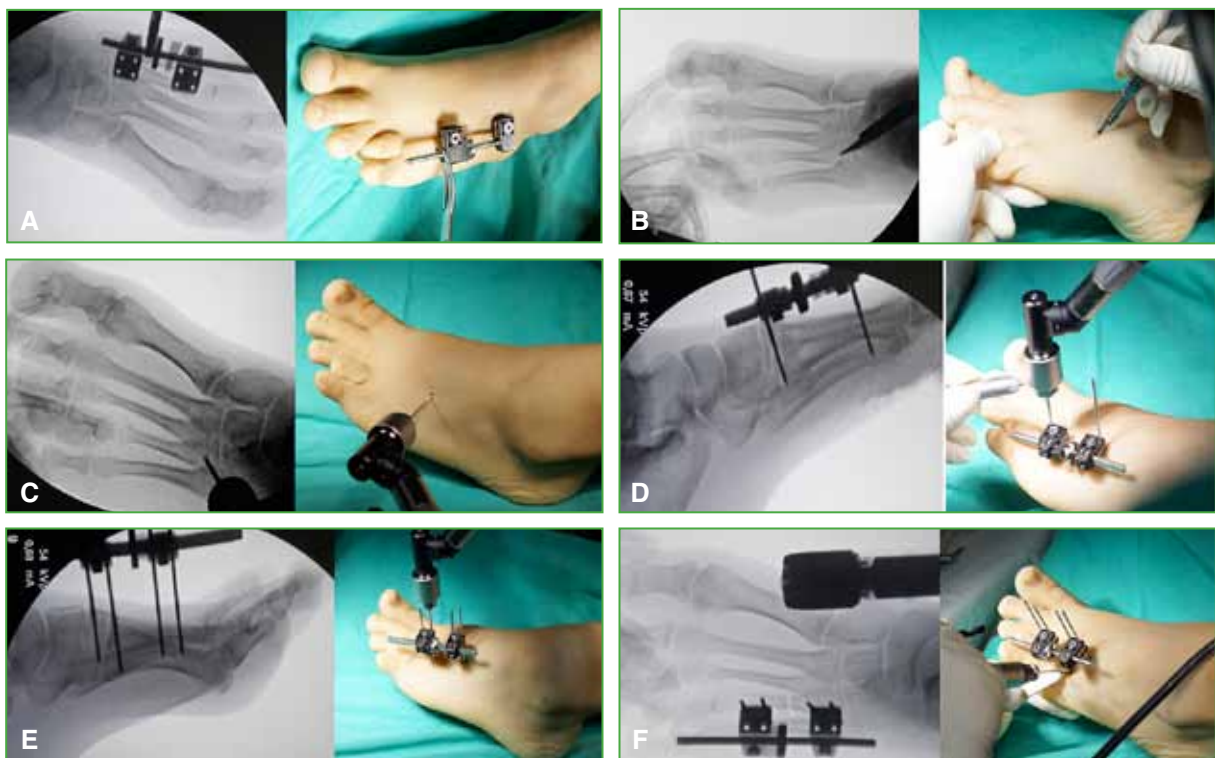
The patient is placed in the supine position, under general or spinal anesthesia. Antibiotic prophylaxis is administered intravenously (first-generation cephalosporin).

Cleaning and asepsis techniques are applied on the foot using chlorhexidine, and sterile surgical fields are created. Under fluoroscopy, the fixator is placed over the metatarsal bone to calculate the length and positioning of the ball-joints.

Percutaneously, a 2.0 screw is placed proximal to the place where the osteotomy will be performed (mid-diaphyseal region). The external fixator is then placed, and, under intraoperative fluoroscopy, the distal screw is placed through the fixator, trying to maintain parallelism between both screws. Then, an extra screw is placed distally, and another one proximally.

Next, a 1 cm-incision is made on the 4<sup>th</sup> metatarsal, and a transverse osteotomy is performed in the diaphyseal region with a 1.5 drill bit. This is completed with an osteotome under fluoroscopy. Distraction is performed with the fixator to check for complete release of the fragments distal and proximal to the osteotomy.

The system is fixed, checking for correct alignment, and the distractor is placed. The skin is closed with nylon and bandage (Figure 3).



**Figure 3.** A. Fixator placement under fluoroscopy to check its length. B. Incision under fluoroscopy. C. Insertion of the most proximal screw of the drill bit. Correct placement is verified. D. Position is marked under fluoroscopy, and the most distal screw of the drill bit is inserted through the fixator. E. Remaining screws over fixator. F. Saw blade osteotomy.

Postoperatively, no weight-bearing is allowed on the limb, and the bone lengthening begins 10 days after surgery, at a rate of 0.5 turns every 12 hours (0.5 mm per day). The external fixator is kept in place until the expected length is reached, and, after that, the mini-fixator is kept in place one month per centimetre lengthening to achieve ossification. The fixator was removed at an average of 88 days (range 72-98).

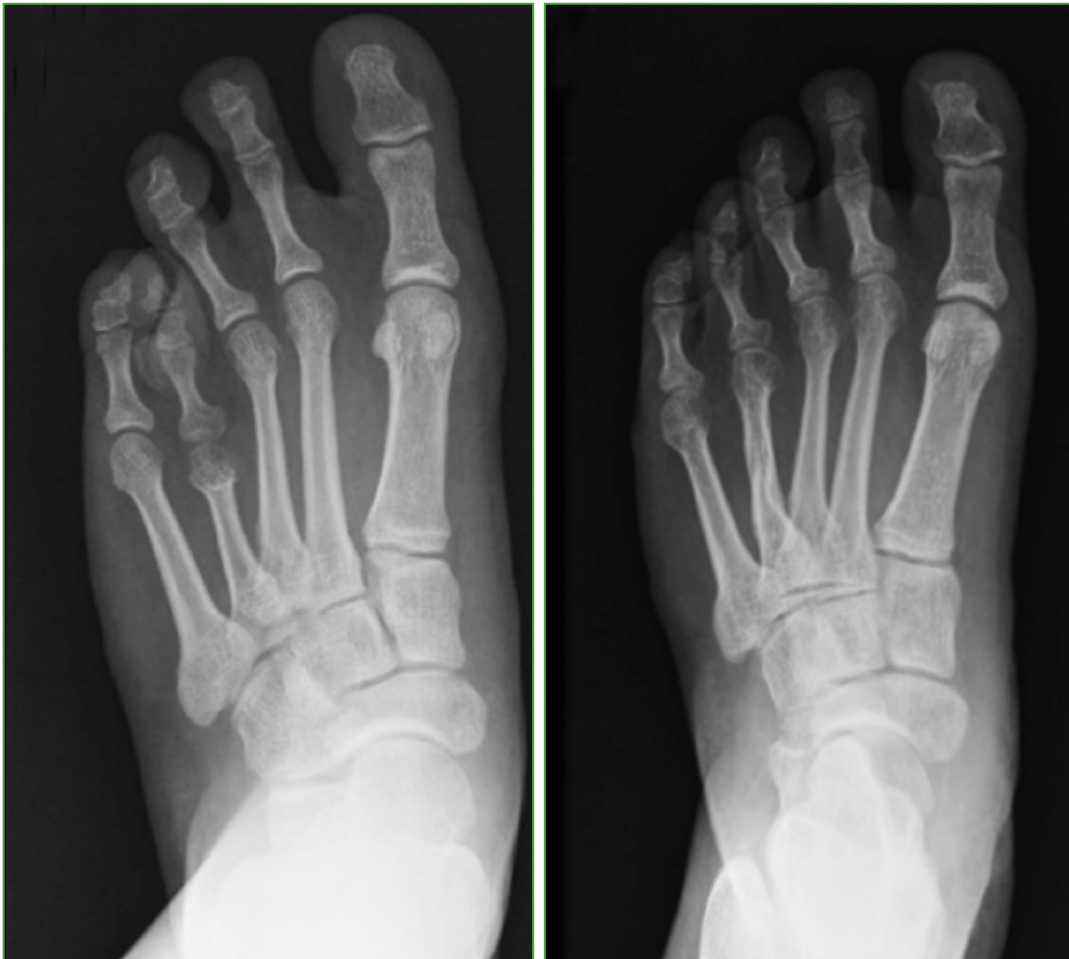## RESULTS

All patients were female, and the average age was 14 years (range 7-18). All had brachymetatarsia involving the 4<sup>th</sup> metatarsal bone. An average 15 mm-lengthening was achieved (range 13-16) (Figure 4).

Two patients presented with a superficial infection of Schanz's screws, which responded well to oral antibiotic treatment. One patient developed a dislocation of the metatarsophalangeal joint after callus distraction, since instructions were not followed when deciding to extend lengthening time. It was solved by open reduction and stabilization with Kirschner's wires when removing the fixator. Another patient progressed to metatarsophalangeal joint flexion, and a Z-tenotomy of the flexor tendon was performed when removing the fixator.

There were no delays in consolidation or neurovascular complications.

All patients were satisfied with the final result and referred that they would repeat and recommend surgery.



**Figure 4.** AP X-rays of the foot (weight-bearing) before and after the lengthening procedure with mini-fixator.

## DISCUSSION

As reported in the medical literature, we observed that brachymetatarsia is a more common condition in women and that it mostly involves the 4<sup>th</sup> metatarsal. While it may be symptomatic, all patients requested surgery for cosmetic reasons.

Numerous approaches have been described to surgically treat brachymetatarsia. They are mainly divided into progressive lengthening with an external fixator and one-stage lengthening.

For the one-stage lengthening, osteotomies without a graft, with an autograft or an allograft, and even with synthetic substitutes have been reported. During one-stage lengthening, special care must be taken regarding soft tissues and to avoid overstretching neurovascular structures.

Some authors perform soft-tissue lengthening, such as zetaplasty of the tendon and Y-plasty of the skin, in a prophylactic manner<sup>3,6</sup>.

There are authors who discuss one-stage lengthening with gradual distraction for 20-30 min, intraoperatively, before interposing a bone graft. This as an adaptive measure to avoid soft-tissue and neurovascular structure distress<sup>4</sup>.

The advantages of one-stage bone lengthening are shorter postoperative and consolidation times<sup>7-10</sup>. Some of its disadvantages are neurovascular compromise by rapid lengthening, excess of shortening or lengthening, metatarsal malalignment, graft reabsorption and lack of consolidation. All these complications would require a second and even a third intervention<sup>5,6</sup>.

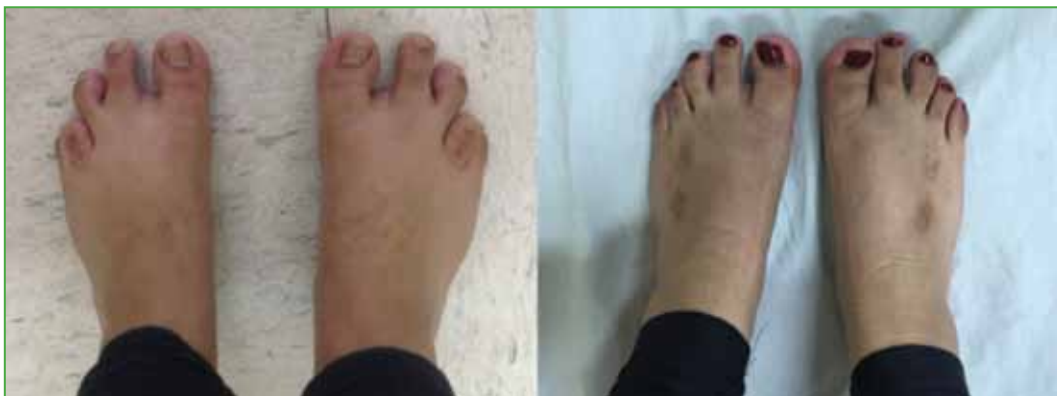Most of these complications arising from one-stage lengthening could be avoided by bone lengthening with external fixator since, being progressive, it avoids neurovascular compromise. Being a guided lengthening, over-shortening or overlengthening would be prevented, as well as malalignment, since it can be corrected during callus distraction.

Another advantage of our approach is that complications secondary to the use of grafts, such as donor site morbidity and graft resorption, can be avoided.

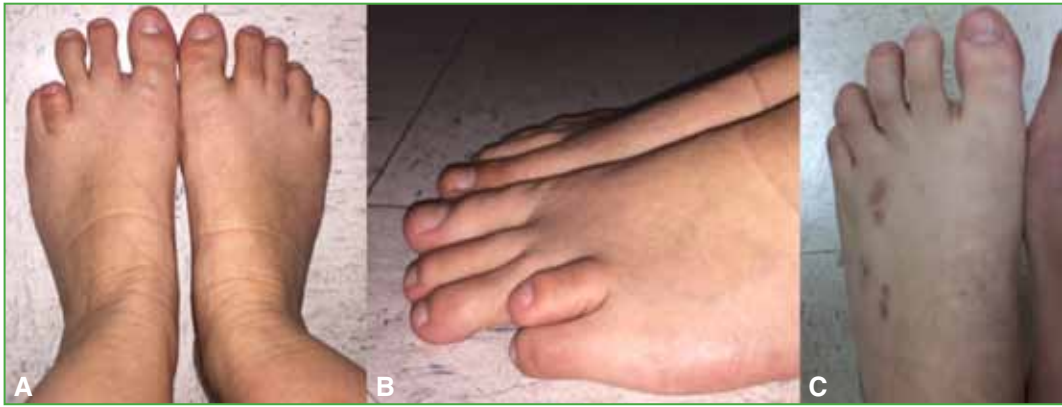In one study, Kim and colleagues compared one-stage lengthening with grafting and callus distraction in 35 patients. They showed that callus distraction offers a better lengthening, on average, up to 2.0 cm, compared to one-stage lengthening, which would reach up to 1.3 cm<sup>3</sup>. In our study, the average lengthening was 15 mm, but in all cases, we stopped because we reached the expected length for the patient.

In a recent systematic review, it was shown that, although bone lengthening achieves better results (over 15 mm and up to 40% of the original metatarsal length), it has a higher complication rate than one-stage lengthening (12.62% vs. 3.72%)<sup>6</sup>.

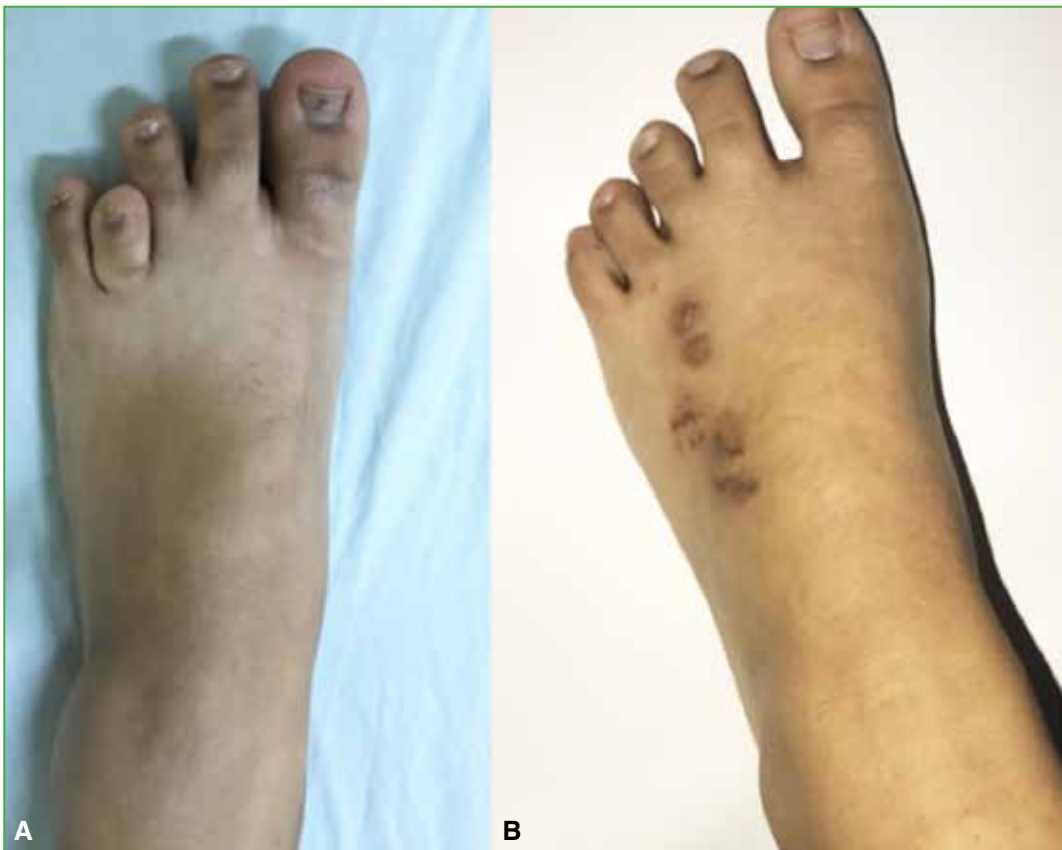According to published studies, cosmetics are the main reason for patients requesting surgery; therefore, bone lengthening with an external fixator would have an additional advantage over one-stage lengthening: the incision is smaller and, therefore, the scar is more aesthetic (Figures 5-7).



**Figure 5.** Pre- and postoperative images. We can observe adequate-length and uniform-looking toes.



**Figure 6.** A. Left-foot brachymetatarsia. B. Postoperative result.



**Figure 7.** A. Left-foot brachymetatarsia. B. Postoperative result.

As strengths of our study, the surgery was performed by a single surgeon following a standardized surgical protocol, which reduces variability. As weaknesses, we can mention the small number of cases, the lack of functional scores and a follow-up of only one year. All these aspects could be improved in a second research with more patients.

## CONCLUSIONS

Bone lengthening with external fixator is a safe and reproducible treatment for brachymetatarsia. We could achieve a greater length in millimetres than with one-stage lengthening. Also, as it is a guided and progressive treatment, a better control of the lengthening can be achieved, and this would reduce neurovascular complications, in addition to offering better cosmetic results to patients.

Conflict of interest: Authors claim they do not have any conflict of interest.

F. J. Sánchez Villanueva ORCID ID: <http://orcid.org/0000-0002-5868-5001>

P. A. Suárez Villalobos ORCID ID: <http://orcid.org/0000-0002-3554-3799>

M. Sepúlveda Oviedo ORCID ID: <http://orcid.org/0000-0002-6792-6145>

## REFERENCES

- Schimizzi A, Brage M. Brachymetatarsia. *Foot Ankle Clin* 2004;9:555-70. <https://doi.org/10.1016/j.fcl.2004.05.002>
- Hosny GS, Ahmed AS. Distraction osteogenesis of fourth brachymetatarsia. *Foot Ankle Surg* 2016;22:12-6. <https://doi.org/10.1016/j.fas.2015.03.009>
- Kim HT, Lee SH, Yoo CI, Kang JH, Suh JT. The management of brachymetatarsia. *J Bone Joint Surg Br* 2003; 85:683-90. <https://doi.org/10.1302/0301-620X.85B5.13733>
- Davidson RS. Metatarsal lengthening. *Foot Ankle Clin* 2001;6:499-518. [https://doi.org/10.1016/S1083-7515\(03\)00110-4](https://doi.org/10.1016/S1083-7515(03)00110-4)
- Baek GH, Chung MS. The treatment of congenital brachymetatarsia by one-stage lengthening. *J Bone Joint Surg* 1998;80:1040-4. <https://doi.org/10.1302/0301-620X.80B6.0801040>
- Jones MD, Pinegar DM, Rincker SA. Callus distraction versus single stage lengthening with bone graft for treatment of brachymetatarsia: A systematic review. *J Foot Ankle Surg* 2015;54:927-31. <https://doi.org/10.1053/j.jfas.2015.02.013>
- Haleem AM, Balagadde A, Borst EW, Do HT, Fragomen AT, Rozbruch SR. Distraction osteogenesis for brachymetatarsia: Clinical results and implications on the metatarsophalangeal joint. *J Limb Lengthen Reconstr* 2015;1:29-37. <https://doi.org/10.4103/2455-3719.168746>
- Takakura Y, Tanaka Y, Fujii T, Tamai S. Lengthening of short great toes by callus distraction. *J Bone Joint Surg Br* 1997;79:955-8. <https://doi.org/10.1302/0301-620X.79B6.0790955>
- Wada A, Bensahel H, Takamura K, Fujii T. Metatarsal lengthening by callus distraction for brachymetatarsia. *J Pediatr Orthop* 2004;13:206-10. [https://journals.lww.com/jpo-b/Abstract/2004/05000/Metatarsal\\_lengthening\\_by\\_callus\\_distraction\\_for.12.aspx](https://journals.lww.com/jpo-b/Abstract/2004/05000/Metatarsal_lengthening_by_callus_distraction_for.12.aspx)
- Song HR, Oh CW, Kyung HS. Fourth brachymetatarsia treated with distraction osteogenesis. *Foot Ankle Int* 2003; 24:706-11. <https://doi.org/10.1177/107110070302400910>