

Chronic exertional compartment syndrome of the forearm treated with minimally invasive fasciotomy: A case report

Tomás Gorodischer, Gerardo L. Gallucci, Pablo De Carli, Jorge G. Boretto

Hand and Upper Limb Surgery Department, Instituto de Ortopedia y Traumatología "Dr. Prof. Carlos E. Ottolenghi", Hospital Italiano de Buenos Aires (Buenos Aires, Argentina)

ABSTRACT

Chronic exertional compartment syndrome (CECS) of the forearm is uncommon and has been described in association with sports and work-related activities. We describe the uncommon presentation of a patient with CECS of the forearm who was treated through a minimally invasive fasciotomy. CECS of the forearm must be suspected in patients with pain in a specific area (compartment), even if they do not practice risky activities. Minimally invasive fasciotomy is an effective treatment option for this condition.

Key words: Compartment syndrome; fasciotomy; forearm.

Level of evidence: IV

Síndrome compartimental crónico del antebrazo tratado con fasciotomía mínimamente invasiva: reporte de un caso

RESUMEN

El síndrome compartimental crónico inducido por el ejercicio o el uso excesivo raramente afecta a los miembros superiores y se ha relacionado con actividades deportivas o laborales. Describimos un caso de un paciente con diagnóstico de síndrome compartimental crónico de antebrazo, de características poco habituales, tratado con fasciotomía mínimamente invasiva. Este síndrome debe sospecharse incluso en pacientes que no practiquen actividades de riesgo y que sufran dolor compartimental inespecífico. La fasciotomía con técnica mínimamente invasiva es una opción eficaz para curar este cuadro.

Palabras clave: Síndrome compartimental; fasciotomía, antebrazo.

Nivel de Evidencia: IV

INTRODUCTION

Although exercise- or exertion-induced chronic compartment syndrome has often been described in the lower limb,^{1,2} its presentation in the upper limb is rare and has been linked to sports activities such as weight-lifting,³ kayak,⁴ tennis,⁵ gymnastics, hockey⁶ and especially motorcycling,⁷⁻¹¹ and also with work-related activities, such as assembly work in factories² and carpentry¹².

Typical but non-specific symptoms are pain, tightness or stiffness of the forearm, cramps, swelling, paresthesia and weakness. Exercise triggers symptoms, which rest relieves, but, when patients resume activity, pain reappears. Bilateral pain is common. Differential diagnoses include tendinopathies and neurovascular entrapment. The physical examination is usually normal at rest. The syndrome is diagnosed by ruling out other causes and, in general, it is confirmed by measuring intra-compartmental pressures during or after exercise. The only effective treatment is fasciotomy, which can be open or minimally invasive.^{13,14}

Received on May 15, 2018. Accepted after evaluation on July 18, 2018 • JORGE G. BORETTO, MD • jorge.boretto@hospitalitaliano.org.ar 

How to cite this paper: Gorodischer T, Gallucci GL, De Carli P, Boretto JG. Chronic exertional compartment syndrome of the forearm treated with minimally invasive fasciotomy: A case report. *Rev Asoc Argent Ortop Traumatol* 2019;84(2):143-148. <http://dx.doi.org/10.15417/issn.1852-7434.2019.84.2.858>

We describe the case of a patient with chronic compartment syndrome of unusual features, who was treated with minimally invasive fasciotomy.

CLINICAL CASE

35-year-old, right-handed patient who referred a five-year condition characterized by moderate (visual analogue scale [VAS] 4/10), oppressive pain in both forearms, with predominance of the right side, radiating only to the volar surface of the forearm. The patient reports that pain was triggered after using a device to exercise the forearm. Symptoms improved during rest and pain increased with exercise (VAS 8/10). At first, clinical features had been interpreted as a muscle contracture and then as a tendinopathy, so the patient received physical therapy and conservative management for 6 months at another center, but without response.

In our center, the clinical examination did not show features of peripheral nerve compression. Medical history, lack of clinical evidence and previous tests ordered for various differential diagnoses (tendinopathy, myopathy, compressive neuropathy), led to the suspicion of chronic compartment syndrome, so we decided to measure intra-compartmental pressure of the volar compartment of the forearm. The following results were obtained:

- Right forearm: 22 mmHg at rest, 48 mmHg during activity (normal value: <30 mmHg).
- Left forearm: 15 mmHg at rest, 23 mmHg during activity (normal value <30 mmHg).

Once the diagnosis was confirmed, a minimally invasive right forearm fasciotomy was recommended.

Surgical approach for minimally invasive decompression of the flexor compartment

The patient is placed in the dorsal decubitus position, with the upper limb being operated on placed on a hand surgery table. A pneumatic tourniquet is placed on the root of the upper limb. The surgery is carried out under regional anesthesia.

On an imaginary line joining the epitrochlea and the midline of the palm of the hand, two small transverse incisions are made, one in the proximal third and the other in the distal third of the flexor compartment of the forearm (**Figure 1**). Next, the antebrachial fascia of the volar surface is identified, after which a subcutaneous blunt dissection is performed by joining both incisions to separate the fascia from the subcutaneous tissue (**Figure 2**).

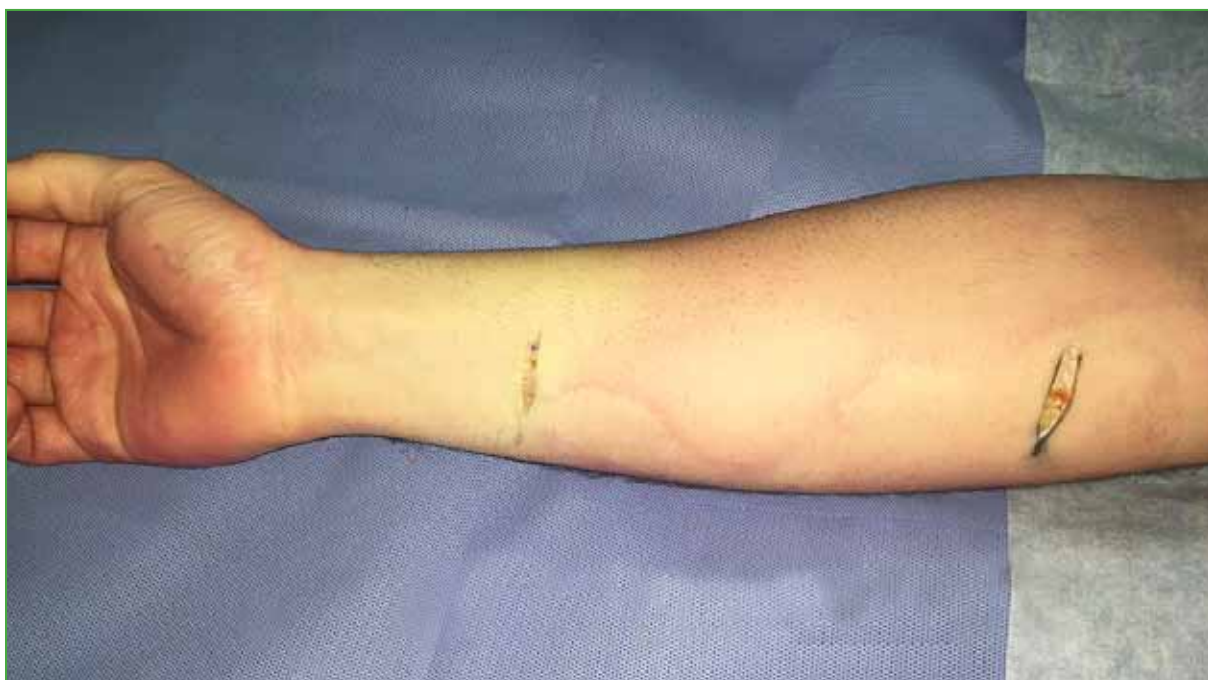

Figure 1. Transverse incisions, proximal and distal, in the anterior surface of the forearm.

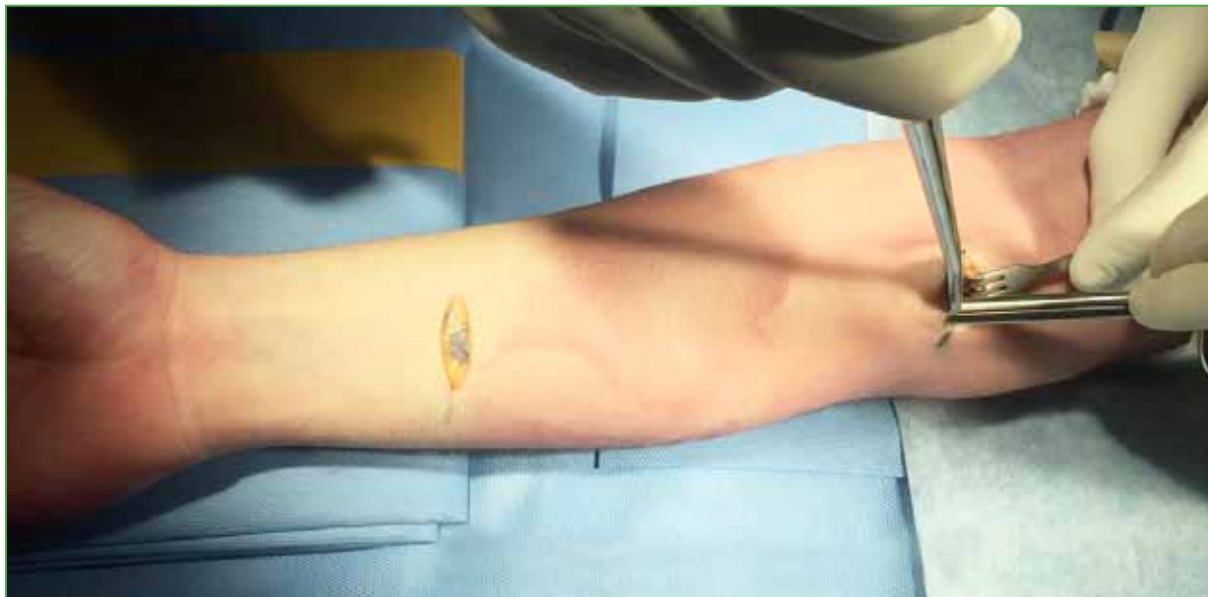


Figure 2. Subcutaneous and suprafascial blunt dissection joining the proximal to the distal incision.

A proximal (Figure 3) and a distal fasciotomy (Figure 4) are performed, and then a subfascial blunt dissection is performed to the distal incision. Next, a fasciotomy is performed on the vertical axis of the forearm, from the proximal incision to the distal one. If poor muscle implantation of one of the flexor muscles is detected, the fasciotomy is continued from the small distal incision towards the carpal tunnel without the need to section the flexor retinaculum of the hand. Then, the flexor carpi ulnaris muscle is moved radially to identify the flexor digitorum profundus muscle, which is covered by the deep antebrachial fascia. Once identified, a vertical fasciotomy is performed for decompression of the deep volar compartment. The deep volar fascia is sectioned with a scalpel following the vertical axis of the flexor digitorum profundus muscle. This VIDEO ► shows the subcutaneous and subfascial dissection approach for superficial volar fasciotomy.

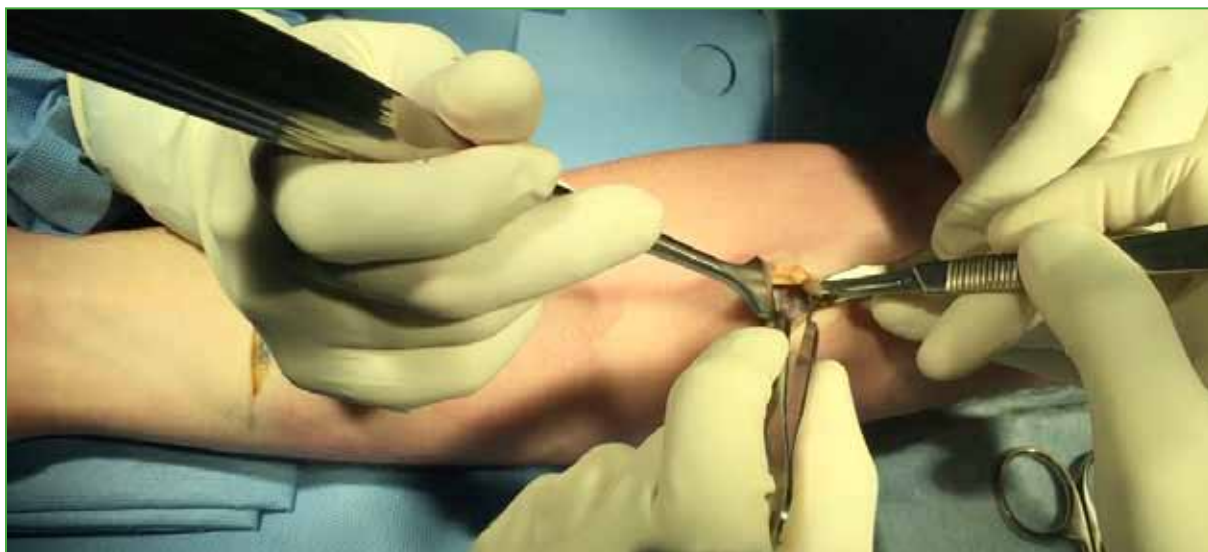

Figure 3. Proximal superficial fasciotomy.

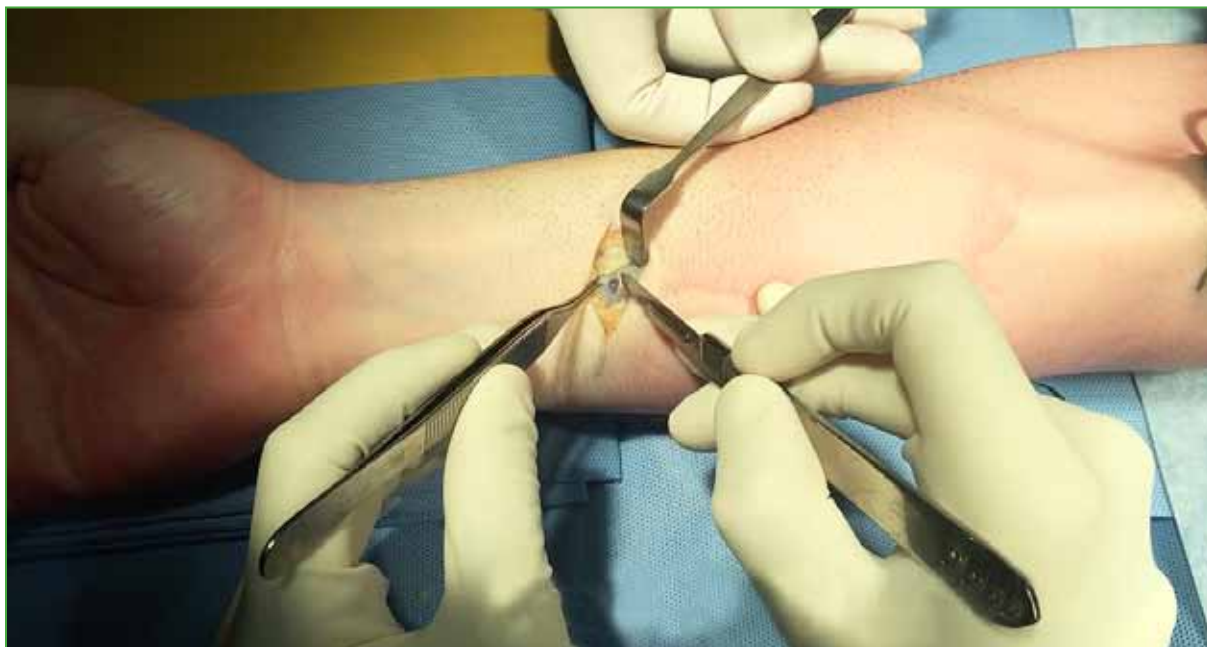

Figure 4. Distal superficial fasciotomy.

Postoperative period

In the immediate postoperative period, a padded and elastic dressing is applied to maintain moderate compression and avoid bruising. This is removed after four days. After two weeks, suture stitches are removed, and the patient can progressively resume activity. Weight-bearing and use of hand strength are allowed after 12 weeks.

RESULTS

Two months after surgery, patient progression was appropriate, and symptoms decreased (VAS 0/10 at rest, 2/10 during limited activities).

At six months, the patient had no physical restrictions, did not need pain killers and performed his usual activities without pain, both at rest and during activity (gym training).

One year after surgery, the patient returned to our center without pain at rest and with an occasional discomfort during specific efforts (opening a tightly closed bottle, carrying a heavy object for a long time), had a DASH score of 15.9 and a slight decrease in grip strength in the right hand compared to its contralateral (46 kg vs. 51 kg).

DISCUSSION

Chronic exertional compartment syndrome of the forearm can be an insidious condition and not have a clear etiology. Although it is related to specific activities that involve repetitive efforts of the forearm and the hand, such as tennis⁵ or motorcycling,⁷⁻¹¹ it is unclear why some patients who practice this type of activity develop a chronic compartment syndrome, while others do not. Some authors have proposed the existence of some type of congenital predisposition. For example, Wasilewski and Asdourian⁶ reported the case of a 14-year-old girl with bilateral chronic compartment syndrome who required fasciotomies in both forearms and who later developed a compartment syndrome in both lower limbs. García Mata *et al.*⁷ reported the case of two brothers with chronic compartment syndrome.

Diagnosis can be difficult not only because there must be a high level of clinical suspicion, but also because normal pressure ranges of the forearm compartments during and after exercise have not been reliably defined. Rydholm *et al.*¹⁵ recorded pressures of 39 mmHg in the extensor compartment during exercise, whereas Scheffl *et al.*¹⁶

recorded pressures of 36 mmHg in the flexor compartment of asymptomatic patients during exercise. In a series of 12 patients studied by Brown *et al.*,¹⁷ a peak pressure of 30 mmHg or more was defined as a diagnostic criterion, accompanied by compatible clinical features and the exclusion of other causes. There is a current diagnostic consensus reported by Pedowicz *et al.*¹⁸ in 2017, which includes intra-compartmental pressure of 15 mmHg at rest or 30 mmHg after one minute of exercise or 20 mmHg after five minutes.

Traditional fasciotomy has been widely published with good results, usually in the majority of patients.^{2-10,12,15} However, in some series, not all patients had a complete recovery after surgery, and prognostic factors could not be identified.^{15,17,19} Several authors have described minimally invasive fasciotomy,^{13,14,19} and it is presented as a simple and effective alternative for the treatment of this condition, decreasing operating time and complications related to the wound site due to a more cosmetic incision. In their series of 54 professional motorcyclist patients, Gondolini *et al.*¹⁴ concluded that the minimally invasive approach was a safe and effective treatment for chronic compartment syndrome in a long-term follow-up of five years. They also reported improvement of symptoms (pain) immediately after surgery and a low complication rate.

CONCLUSIONS

Chronic compartment syndrome of the forearm is usually related to strenuous or repetitive physical activities. However, it should be suspected even in patients who do not practice risky activities and suffer nonspecific compartment pain. Minimally invasive fasciotomy is an effective option to cure this condition.

Conflict of interests: Authors claim they do not have any conflict of interests.

T. Gorodischer ORCID ID: <http://orcid.org/0000-0002-5044-5847>

G. L. Gallucci ORCID ID: <http://orcid.org/0000-0002-0612-320X>

P. De Carli ORCID ID: <http://orcid.org/0000-0002-9474-8129>

REFERENCES

1. Detmer DE, Sharpe K, Sufit RL, Girdley FM. Chronic compartment syndrome: diagnosis, management, and outcomes. *Am J Sports Med* 1985;13:162-70. <https://doi.org/10.1177/036354658501300304>
2. Pedowitz RA, Toutoungi FM. Chronic exertional compartment syndrome of the forearm flexor muscles. *J Hand Surg Am* 1988;13:694-6. [https://doi.org/10.1016/S0363-5023\(88\)80126-6](https://doi.org/10.1016/S0363-5023(88)80126-6)
3. Jawed S, Jawad ASM, Padhiar N, Perry JD. Chronic exertional compartment syndrome of the forearms secondary to weight training. *Rheumatology* 2001;40:344-5. <https://doi.org/10.1093/rheumatology/40.3.344>
4. Piasecki DP, Meyer D, Bach BR Jr. Exertional compartment syndrome of the forearm in an elite flatwater sprint kayaker. *Am J Sports Med* 2008;36:2222-5. <https://doi.org/10.1177/0363546508324693>
5. Berlemann U, al-Momani Z, Hertel R. Exercise-induced compartment syndrome in the flexor-pronator muscle group. A case report and pressure measurements in volunteers. *Am J Sports Med* 1998;26:439-41. <https://doi.org/10.1177/03635465980260031701>
6. Wasilewski SA, Asdourian PL. Bilateral chronic exertional compartment syndromes of forearm in an adolescent athlete: Case report and review of literature. *Am J Sports Med* 1991;19:665-7. <https://doi.org/10.1177/036354659101900620>
7. Garcia Mata S, Hidalgo Ovejero A, Martinez Grande M. Bilateral, chronic exertional compartment syndrome of the forearm in two brothers. *Clin J Sport Med* 1999;9:91-9. <https://doi.org/10.1097/00042752-199904000-00009>
8. Allen MJ, Barnes MR. Chronic compartment syndrome of the flexor muscles in the forearm: A case report. *J Hand Surg Br* 1989;14:47-8. [https://doi.org/10.1016/0266-7681\(89\)90014-4](https://doi.org/10.1016/0266-7681(89)90014-4)

9. Goubier JN, Saillant G. Chronic compartment syndrome of the forearm in competitive motor cyclists: A report of two cases. *Br J Sports Med* 2003;37:452-3. <https://doi.org/10.1136/bjism.37.5.452>
10. Zandi H, Bell S. Results of compartment decompression in chronic forearm compartment syndrome: Six case presentations. *Br J Sports Med* 2005;39:e35. <https://doi.org/10.1136/bjism.2004.012518>
11. Jeschke J, Baur EM, Piza-Katzer H. Chronic compartment syndrome of the flexor muscles in the forearm due to motocross. *Handchir Mikrochir Plast Chir* 2006;38:122-5. <https://doi.org/10.1055/s-2006-923785>
12. Soderberg TA. Bilateral chronic compartment syndrome in the forearm and the hand. *J Bone Joint Surg Br* 1996;78:780-2. <https://doi.org/10.1302/0301-620X.78B5.0780780>
13. Croutzet P, Chassat R, Masmajeun EH. Mini-invasive surgery for chronic exertional compartment syndrome of the forearm. A new technique. *Tech Hand Up Extrem Surg* 2009;13(3):137-40. <https://doi.org/10.1097/BTH.0b013e3181aa9193>
14. Gondolini G, Schiavi P, Pogliacomì F, Ceccarelli F, Antonetti T, Zasa M. Long-term outcome of mini-open surgical decompression for chronic exertional compartment syndrome of the forearm in professional motorcycling riders. *Clin J Sport Med* 2017; Oct 10 [versión en línea antes de la impresión]. <https://doi.org/10.1097/JSM.0000000000000539>
15. Rydholm U, Werner CO, Ohlin P. Intracompartmental forearm pressure during rest and exercise. *Clin Orthop* 1983; 175:213-5. <https://doi.org/10.1097/00003086-198305000-00034>
16. Schoeffl V, Klee S, Strecker W. Evaluation of physiological standard pressures of the forearm flexor muscles during sport specific ergometry in sport climbers. *Br J Sports Med* 2000;38:422-5. <https://doi.org/10.1136/bjism.2002.003996>
17. Brown JS, Wheeler PC, Boyd KT, Barnes MR, Allen MJ. Chronic exertional compartment syndrome of the forearm: a case series of 12 patients treated with fasciotomy. *J Hand Surg Eur* 2011;36(5):413-9. <https://doi.org/10.1177/1753193410397900>
18. Pedowitz RA, Hargens AR, Mubarak SJ, Gershuni DH. Modified criteria for the objective diagnosis of chronic compartment syndrome of the leg. *Am J Sports Med* 1990;18:35-40. <https://doi.org/10.1177/036354659001800106>
19. Miller EA, Cobb AL, Cobb TK. Endoscopic fascia release for forearm chronic exertional compartment syndrome: case report and surgical technique. *Hand (NY)* 2017;12(5):NP58-NP61. <https://doi.org/10.1177/1558944716669799>