

Traumatic rupture of the extensor hallucis longus at the level of the distal insertion

Case report

FERNANDO M. VAGO ANAYA, EMILIANO LONCHARICH

*Foot and Ankle Section, Hospital Británico de Buenos Aires,
Ciudad Autónoma de Buenos Aires*

Received on October 29th, 2017; accepted after evaluation on November 20th 2017 • FERNANDO M. VAGO ANAYA, MD • fmvago@hotmail.com 

How to cite this article: Vago Anaya FM, Loncharich E. Traumatic rupture of the extensor hallucis longus at the level of the distal insertion. Case report. *Rev Asoc Argent Ortop Traumatol* 2018;83(4):298-302. doi: 10.15417/issn.1852-7434.2018.83.4.782

ABSTRACT

The rupture of the extensor hallucis longus is infrequent, even more in spontaneous lesions and in those caused by indirect trauma. It can occur in any part of the tendon, but the most frequent lesions are those caused by cutting injury. There is no specific surgical technique described for the distal reinsertion of the tendon.

The aim of this article is to present a thirty-five years old patient who due to indirect traumatism suffered the rupture of the extensor hallucis longus at the level of its distal insertion. We describe the surgical technique we used, and the patient's rehabilitation and preoperative and postoperative results in the AOFAS scale.

Key words: Traumatic rupture; extensor hallucis longus.

Level of evidence: IV

ROTURA TRAUMÁTICA DEL EXTENSOR PROPIO DEL HALLUX EN LA INSERCIÓN DISTAL. REPORTE DE UN CASO

RESUMEN

Las roturas del extensor propio del hallux son poco frecuentes, más aún aquellas espontáneas o por traumas indirectos. Se pueden producir en cualquier parte del recorrido del tendón, pero las lesiones más frecuentes son las secciones tendinosas por heridas cortantes. No existe una técnica quirúrgica específica descrita para la re inserción distal del tendón.

El objetivo de este artículo es presentar a un paciente de 35 años que, por un traumatismo indirecto, sufrió la rotura del extensor propio del hallux a nivel de la inserción distal. Se describen la técnica quirúrgica, la rehabilitación y los resultados según el puntaje de la AOFAS preoperatorio y posoperatorio.

Palabras clave: Rotura traumática; extensor propio del hallux.

Nivel de Evidencia: IV

Conflicto de intereses: Los autores no declaran conflictos de intereses.

Introduction

The rupture of the extensor hallucis longus is infrequent. It has been described as the lesion caused by cutting injuries on the dorsal aspect of the foot or as unusually secondary to indirect traumatism.^{1,2}

The spontaneous rupture of the extensor hallucis longus is very infrequent. There are predisposing factors such as chronic traumatism, chronic disease, or the interruption of blood supply to whichever portion of the tendon.³

There are just few reports on cases of extensor hallucis longus spontaneous rupture or rupture due to indirect traumatism at the level of its distal insertion; there are not

reports on treatment either. We present the case of one rupture of the extensor hallucis longus at the level of its distal insertion in a 35 year-old patient with history of indirect traumatism: hallux hit against the floor in plantar flexion. We describe the surgical techniques we used, rehabilitation and the patient's postoperative function by the AOFAS scale.

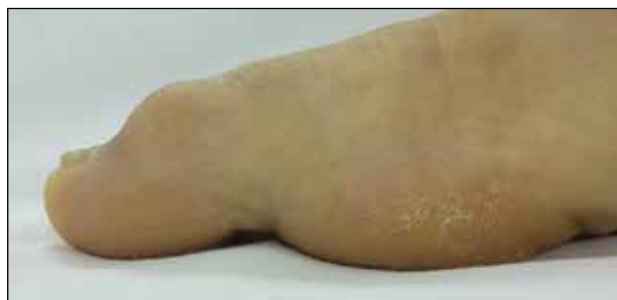Case

It is the case of a thirty-five years old patient who consults six weeks after suffering indirect traumatism at the level of his right hallux by hitting it against the floor while practicing sports with sport-shoes generating a mechanism of foot sudden plantar flexion.

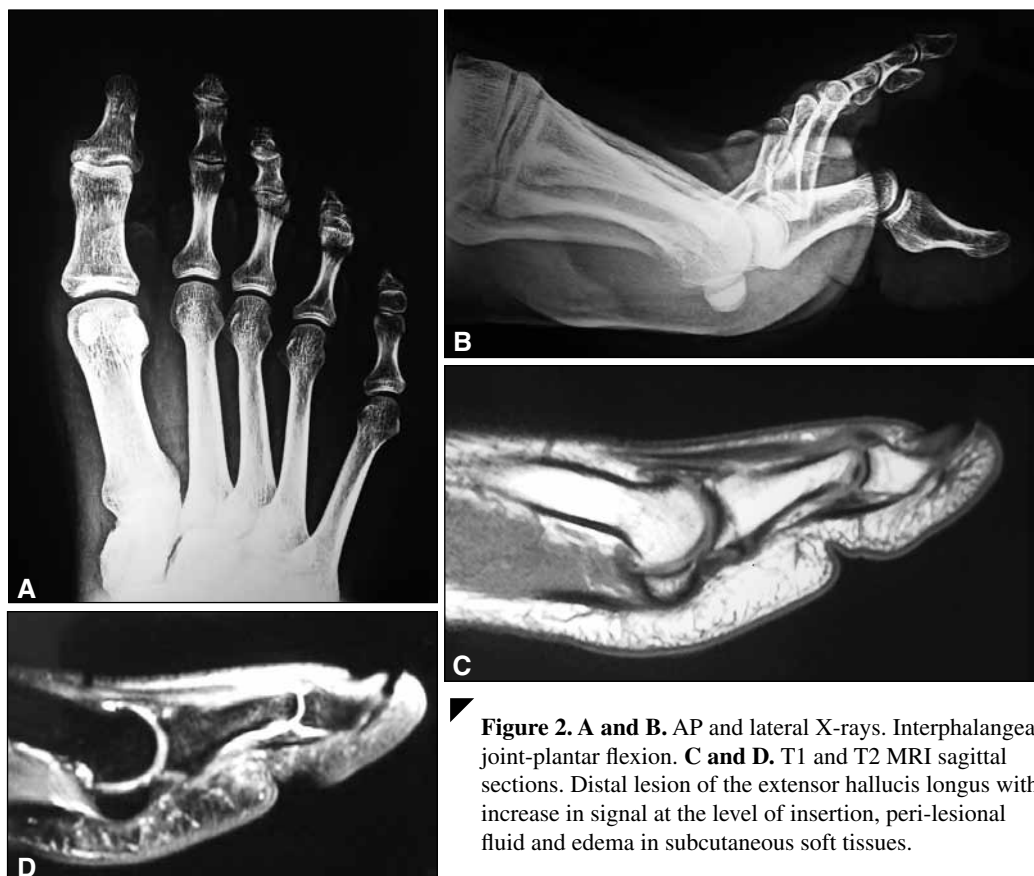
At physical examination, the patient's hallux is in interphalangeal joint-plantar flexion with loss of active extension of the distal phalanx and decrease in the extensive power of the metatarsophalangeal joint (Figure 1). There is complete interphalangeal and metatarsophalangeal joints mobility at passive mobilization.

X-rays show flexion at the level of the interphalangeal joint (Figures 2A and B).

MRI shows rupture of the extensor hallucis longus at the level of its insertion (Figures 2C and D).



▲ **Figure 1.** Clinic image of hallux in interphalangeal joint-plantar flexion.



▲ **Figure 2.** A and B. AP and lateral X-rays. Interphalangeal joint-plantar flexion. C and D. T1 and T2 MRI sagittal sections. Distal lesion of the extensor hallucis longus with increase in signal at the level of insertion, peri-lesional fluid and edema in subcutaneous soft tissues.

We interpret this one as a traumatic rupture of the extensor hallucis longus at the level of its distal insertion and we suggest surgical treatment considering the patient's age and physical activity status.

Surgical technique

The patient goes in supine position with ischemia in his lower limb. We carry out a dorsal skin and subcutaneous soft-tissue Z-approach until exposing the sheath of the extensor tendon (Figure 3) and verifying scar fibrous tissues with no continuity of the tendon up to its distal insertion.

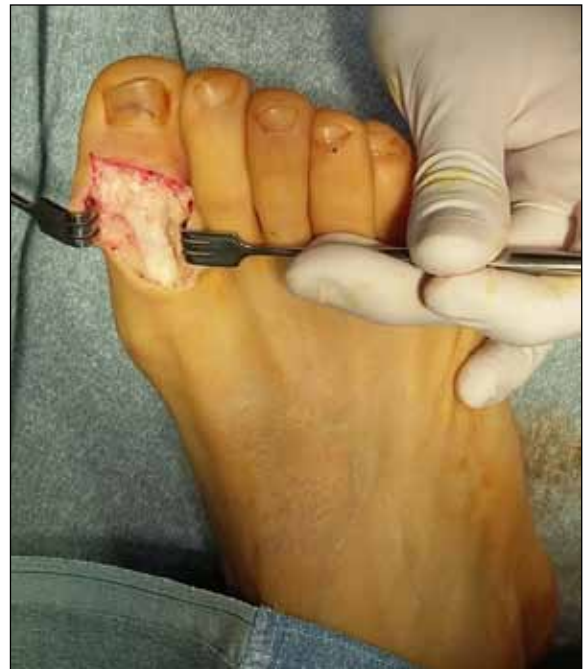We carry out scar-tissue resection up to tendon with normal appearance, we conduct curettage in the prospective re-insertion area and we re-insert the tendon at the level of the distal phalanx using a 2.8-mm harpoon of polyetheretherketone (PEEK) discharging the suture with proximal stitches (Figures 4 and 5).

Upon tendon re-insertion we verify interphalangeal joint hyperextension. We carry out wound closure by planes and provide the patient with immobilization with a short-leg cast with metatarsophalangeal and interphalangeal joints in hyperextension (Figure 6).

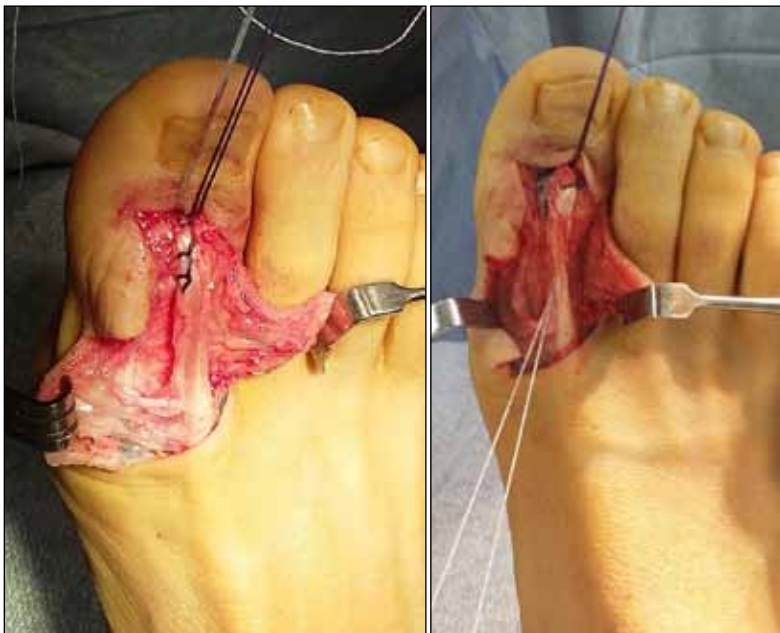We keep short-leg cast without weight-bearing during three weeks, and then we implement protected weight-bearing with walker boot during three more weeks with the patient doing active mobility exercises without weight-bearing, and physiotherapy. The patient is evaluated by the AOFAS scale at the end of rehabilitation (3 months after the surgery) and he gets a 90-score out of 100. There are no postoperative complications.

Discussion

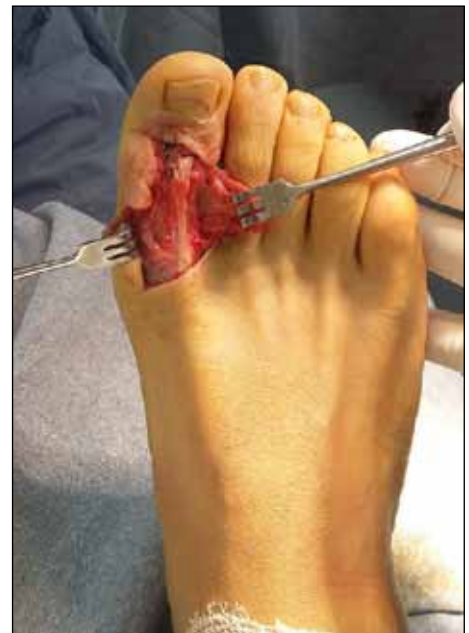The rupture of the extensor hallucis longus is infrequent. The optimal treatment for the closed sudden rupture of this tendon is still controversial due to its low incidence.



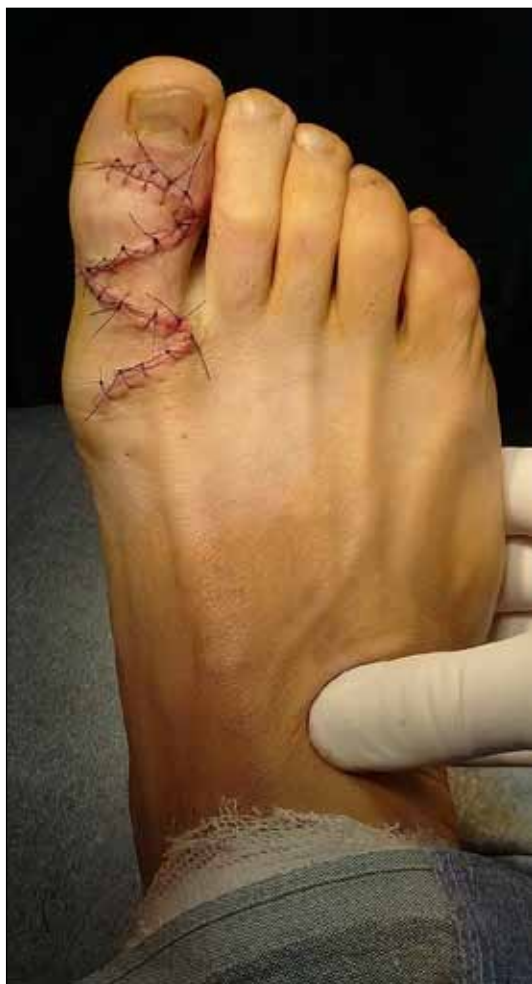▲ **Figure 3.** Surgical technique. Dorsal approach. Scar fibrous tissue.



▲ **Figure 4.** Surgical technique. Anchorage of the tendón at distal level with harpoon plus proximal reinforcement.



▲ **Figure 5.** Surgical technique. Reinserted tendon.



▲ **Figure 6.** Surgical technique. Closure of the wound. Interphalangeal joint in extension.

A brief bibliographic revision involving the treatment of lacerations affecting the extensor hallucis longus shows that treatment at acute stages is conservative,^{4,5} but end-to-end tenorrhaphy is also suggested.

Published reports on the surgical treatment of the rupture of the extensor hallucis longus are promising, but for some painful scars,⁵ and it is worth highlighting that surgery decreases the risk of developing hallux flexus.^{6,7} There are reports on excellent results with leg immobilization with hallux in hyperextension during three to eight weeks.^{8,9}

Treatment in rupture of the extensor hallucis longus can be successful with early diagnosis and prompt surgical treatment. If the patient consults during the 4-6 weeks consecutive to the rupture of the tendon, and the tendon ends can be approximated and sutured to each other without excessive tension, it is possible to carry out primary reparation.

In chronic ruptures where tendon ends cannot be sutured to each other or the tendon is degenerated, there are reports on tendon transfer surgery and tendon graft from another tendon.¹

Table. Forefoot AOFAS scale

Forefoot AOFAS scale goals, hallux, toe MTP and IF joints and phalanges	Preoperative	Postoperative
Over the past 4 weeks		
Pain: No (40) Mild, occasional (30) Moderate, daily (20) Severe, Constant (0)	20	30
Function-activities: No limitations, no help (10) No limitations in activities of daily living, but limitations in recreative activities, (7) Limitations in activities of daily living and in recreative activities (4) Sever limitations in activities of daily living and recreative activities (0)	7	10
Function-shoes: Normal (10) Comfortable, with need for insert (5) Modified or special (0)	10	10
Function-MTP mobility (plantar and dorsal flexion): Normal or slight restriction; >75° (10) Moderate restriction; 30°-74° (5) Restricción severa; <30° (0)	5	10
Function-IP mobility (plantar flexion): No restrictions (5) Severe restriction; <10° (0)	0	5
Function-MTP-IP stability (all directions): Stable (5) Unstable or prone to dislocation (0)	5	5
Function-callus in MTP-IP: No or asymptomatic (5) Symptomatic (0)	5	5
Alignment: Good, good aligned hallux (15) Fair, asymptomatic misalignment (8) Poor, symptomatic misalignment (0)	8	15
TOTAL (max. 100):	60	90

A bibliographic search showed few case reports, with the most frequent ones being on bone avulsion from distal insertion, but this was not the case with disinsertion or rupture at the level of insertion.

The first reports on distal bone avulsions were those by Rapoff in 1999 and Saxby in 2001, who suggested non-operative treatment with hyperextension sling.^{9,10} Such reports were on middle-aged patients who had suffered

bone avulsion lesions and, after treatment, they had rigidity in their hallux interphalangeal joint, but they were asymptomatic and with good function.

Given the few cases reported, there are no reports on a unique surgical technique; as a result, we decided to describe the surgical technique and communicate the case.

Hong and Tan reported two cases of reparation of distal disinsertion in the extensor hallucis longus using bioabsorbable suture anchorage and non-absorbable suture combined with early mobilization of the interphalangeal joint.¹¹ They are concerned about the interphalangeal rigidity consecutive to the temporary pin-fixation through the joint and the likely rupture of the wire at joint level, on top of the greater risk of infection.

The authors showed that, with this surgical technique, i.e. without going through the joint with a pin, their patients recovered complete function without joint rigidity.

Results were good, with an AOFAS score of 90 three months later (preoperative score= 60).

Upon analyzing our case, the patient's outcomes and his results in the AOFAS scale, we conclude that this is an adequate surgical technique for the insertional lesion of the extensor hallucis longus (Table). Although it is controversial alternative, at early stages conservative treatment can get good results as it has already been published. It is necessary to analyze a greater number of cases and a longer follow-up so as to assure ourselves of this conclusion.

Bibliography

- Langenberg VR. [Spontaneous rupture of the tendon of the musculus extensor hallucis longus]. *Zentbl Chir* 1989;114(6):400-3. PMID: <https://www.ncbi.nlm.nih.gov/pubmed/?term=PMID%3A+2728659>
- Sim FH, DeWeerd JH Jr. Rupture of the extensor hallucis longus tendon while skiing. *Minn Med* 1977;60(11):789-90. PMID: <https://www.ncbi.nlm.nih.gov/pubmed/?term=PMID%3A+927409>
- McMaster PE. Tendon and muscle ruptures: clinical and experimental studies of the causes and location of subcutaneous ruptures. *J Bone Joint Surg* 1933;15(3):705-22. <https://bit.ly/2ENigKz>
- Floyd DW, Heckman JD, Rockwood CA Jr. Tendon lacerations in the foot. *Foot Ankle* 1983;4(1):8-14. doi: <https://doi.org/10.1177/107110078300400103>
- Griffiths JC. Tendon injuries around the ankle. *J Bone Joint Surg Br* 1965;47(4):686-9. doi: <https://doi.org/10.1302/0301-620X.47B4.686>
- Berens TA. Autogenous graft repair of an extensor hallucis longus laceration. *J Foot Surg* 1990;29(2):179-82. PMID: <https://www.ncbi.nlm.nih.gov/pubmed/1970988>
- Tachdjian MO. *The child's foot*, Philadelphia: WB Saunders; 1985:456-7.
- Menz P, Nettle WJS. Closed rupture of the musculotendinous junction of extensor hallucis longus. *Injury* 1989;20(6):379-81. doi: [https://doi.org/10.1016/0020-1383\(89\)90022-3](https://doi.org/10.1016/0020-1383(89)90022-3)
- Hennessy MS, Saxby TS. Traumatic "mallet toe" of the hallux: a case report. *Foot Ankle Int* 2001;22(12):977-8. doi: <https://doi.org/10.1177/107110070102201209>
- Rapoff AJ, Heiner JP. Avulsion fracture of the great toe: a case report. *Foot Ankle Int* 1999;20(5):337-9. doi: <https://doi.org/10.1177/107110079902000514>
- Hong CC, Tan KJ. Suture anchor fixation of unstable bony mallet injuries of the hallux. *Foot Ankle Int* 2013;34(12):1737-40. doi: <https://doi.org/10.1177/1071100713499906>