

Metaphyseal bone decompression of distal radius for early stages of Kienböck's disease. Minimum follow-up of 10 years

EZEQUIEL E. ZAIDENBERG, PABLO DE CARLI, JORGE G. BORETTO, AGUSTÍN DONNDORFF,
VERÓNICA ALFIE, GERARDO L. GALLUCCI, ALDO ILLARAMENDI

*Unit of Hand and Upper Limb Reconstructive Surgery Orthopaedics Department,
Hospital Italiano of Buenos Aires, Ciudad Autónoma de Buenos Aires, Argentina*

Received on July 29th, 2017; accepted after evaluation on October 12th, 2017 • EZEQUIEL E. ZAIDENBERG, MD • ezequiel.zaidenberg@hospitalitaliano.org.ar 

ABSTRACT

Introduction: The aim of this study is to analyze medical and radiological long-term results in a series of patients with Lichtman's stages II and IIIA-Kienböck's disease treated by metaphyseal core decompression in the distal radius.

Materials and Methods: Descriptive, retrospective study which included 23 patients with Kienböck's disease (Lichtman's stages II and IIIA) treated by metaphyseal core decompression in the distal radius with a minimal 10-year follow-up. At last follow-up, we evaluated wrist range of motion and grip strength by the modified Mayo Clinic scale and pain by the visual analogue scale. We assessed patients' X-rays according to the Lichtman's classification and the carpal height ratio.

Results: Average follow-up was 14 years (10-19 range). Nine patients were females and fourteen, males. Fifteen cases were Lichtman's stage IIIA and eight, stage II. According to the Mayo Clinic scale, results were excellent in 9 patients, good in 11, moderate in 2 and poor in one patient. The score in the preoperative visual analogue scale was 7 (6-10 range) and 1.1 (0-6) at last follow-up. The average flexion/extension arch was 78% and grip strength was 81%. According to the Lichtman's classification, there was progression in 4 patients, whereas the remaining 19 stayed at the same stage as preoperatively.

Conclusion: Metaphyseal core decompression in distal radius got long-term favourable results in Lichtman's stages II and IIIA-Kienböck's disease.

Key words: Kienböck; bone decompression; results; long-term; early stages.

Level of evidence: IV

DESCOMPRESIÓN ÓSEA METAFISARIA DEL RADIO DISTAL PARA ESTADIOS TEMPRANOS DE LA ENFERMEDAD DE KIENBÖCK. SEGUIMIENTO MÍNIMO DE 10 AÑOS

RESUMEN

Introducción: El objetivo de este estudio es analizar los resultados clínicos y radiológicos a largo plazo de una serie de pacientes con enfermedad de Kienböck en estadios II y IIIA de la clasificación de Lichtman, tratados mediante descompresión metafisaria del radio distal.

Materiales y Métodos: Estudio retrospectivo y descriptivo que incluyó a 23 pacientes con enfermedad de Kienböck (estadios II y IIIA de Lichtman) tratados mediante descompresión metafisaria del radio distal con, al menos, 10 años de

Conflict of interests: The authors have reported none.

seguimiento. Al final del seguimiento, se evaluaron el rango de movilidad de la muñeca, la fuerza de puño, mediante la escala de la Clínica Mayo modificada y el dolor, según la escala analógica visual. Se valoró a los pacientes radiográficamente según la clasificación de Lichtman y el índice de altura carpiana.

Resultados: El seguimiento promedio fue de 14 años (rango 10-19). Nueve pacientes eran mujeres y catorce, hombres. Quince casos correspondían al estadio IIIA y ocho, al estadio II. Según la escala de la Clínica Mayo, los resultados fueron excelentes en 9 pacientes, buenos en 11 pacientes, moderados en 2 y pobres en uno. El puntaje en la escala analógica visual preoperatoria fue 7 (rango 6-10) y 1,1 (rango 0-6) al final del seguimiento. El arco de flexión/extensión promedio fue del 78% y la fuerza de puño, del 81%. Según la clasificación de Lichtman, hubo progresión en 4 pacientes, mientras que los otros 19 permanecieron en la misma etapa que en el preoperatorio.

Conclusión: La descompresión metafisaria del radio distal logró resultados favorables a largo plazo para los estadios II y IIIA de la enfermedad de Kienböck.

Palabras claves: Kienböck; descompresión ósea; resultados; largo plazo; estadios tempranos.

Nivel de Evidencia: IV

Introduction

Kienböck's disease was described in 1910; however, even today it is subject to controversy in literature. In association with Kienböck's disease, there are several aetiologies that have been suggested: traumatic, mechanical (increase in pressure upon the lunate bone) and vascular aetiologies.¹ Due to this wide disagreement, there are reports on quite varied surgical alternatives for its treatment, such as osteotomy for radial bone shortening or ulnar lengthening, carpal arthrodesis and vascularized bone grafting.^{2,3} In spite of the considerable differences in such surgical techniques, there are reports on similarly satisfactory results using all of them.⁴⁻⁶

In 2001, Illarramendi et al. described the technique of "metaphyseal core decompression in the distal radius", which consists of a bone window in the distal radius with compaction of the spongy bone in the distal metaphysis, what might cause a biological stimulus in the whole wrist by the effect of indirect revascularization of the involved lunate bone.⁷ These authors reported satisfactory results, similar to those got by means of other techniques of joint levelling or direct revascularization, using a simpler alternative associated with just few complications.

The aim of this study is to analyze medical-radiological results in a series of patients with stages II and IIIA-Kienböck's disease treated by metaphyseal core decompression in the distal radius, with a minimal follow-up of 10 years.

Materials and Methods

We conducted a retrospective study which was approved by our institution's Ethical Committee. The inclusion criteria were: patients with Kienböck's disease (Lichtman II and IIIA) subject to metaphyseal core decompression in the distal radius, with a minimal 10-year follow-up. The exclusion criteria were stages I, IIIB or IV in the Lichtman classification, skeletally immature patients and tho-

se with previous wrist surgery. Between 1998 and 2005, 66 patients with Kienböck's disease were treated at our institution. Twenty-five patients met the inclusion criteria, but two of them were lost from follow-up. Therefore, we included 23 patients in our study (14 males and 9 females who at the time of treatment averaged 42 years old [ranging from 28 to 64]). Fifteen patients had their dominant hand affected. Average follow-up was 14 years (ranging from 10 to 19). Fifteen cases were stage IIIA and eight, stage II. Fourteen wrists showed negative ulnar variance, whereas nine wrists had neutral ulnar variance. In no case did we carry out procedures additional to the metaphyseal core decompression in the distal radius.

Functional evaluation

Medical assessment was carried out by two surgeons/researchers who used a hand goniometer to evaluate the flexion and extension active range of motion of the wrist. Grip strength was evaluated with a Jamar® dynamometer (Patterson Medical Co, Bolingbrook, IL, US) and was reported as the average of three tries. We corrected hand dominance assuming that the dominant hand would be 10% stronger. Both range of motion and grip strength were compared to the contralateral hand at the end of follow-up. Preoperative and postoperative pain was assessed by the visual analogue scale, which ranges within 0 (no pain) and 10 (worst possible pain). Subjective and objective medical results were evaluated by the modified Mayo Clinic scale, which classifies scores between 90 and 100 as excellent, between 80 and 89 as good, between 65 and 79 as moderate and lower than 65 as poor.⁸

Radiologic evaluation

We carried out preoperative and postoperative radiologic assessment with standard AP and lateral X-rays of the wrist which were evaluated by two independent authors. Radiographic assessment included carpal height ratio (CHR) modified by Natrass et al. (AP X-ray carpal height divided by the length of the capitate bone) as well as the Lichtman's classification.⁹ The normal value of the CHR

is 1.57 ± 0.05 .¹⁰ The progression of the disease (carpal collapse) during follow-up was verified by changes in the Lichtman's classification and the modified CHR.

Surgical technique

In our series all surgeries were carried out by the main author. Distal radius should be approached by a 3-4 cm-longitudinal incision along the radial edge of the metaphysis of the distal radius, starting 1 cm proximally to the radial styloid process. The branches of the sensitive radial nerve should be individualized and taken care of. The tendons in the first compartment are to be retracted towards the posterior or the anterior cortex, as the surgeon prefers. At a deeper layer level, the distal tendon of the brachioradialis muscle should be severed in "H" longitudinal fashion and raised from the distal radius together with periosteum. What comes next is the creation of an approximately 2 cm-long and 0.5 cm-wide bony window, starting 2 cm proximally to the radial styloid process, using either osteotome or bone saw (Figure 1). Then, the spongy bone of the distal metaphysis is to be compacted through the window without removing it.¹¹ Spongy bone compaction is carried out only at the level of the metaphysis, consistently reaching anterior, posterior and ulnar cortex.

Differently from what is described in the original technique by Illarramendi et al. in no case did we carry out ulnar decompression.⁷ Upon surgery, the wrist was immobilized during two weeks by a forearm cast to protect the surgical wound. Rehabilitation to recover complete range of motion started as from that moment. Patients were allowed to do activities of daily living immediately, and sports were restricted for three months to avoid the risk of radial fracture across the cortical window.

We recorded complications and the need of reoperation. Those complications that did not require surgical treat-

ment (such as superficial infection in the surgical wound) were classified as minor complications. Major complications included deep infection, nerve or tendon lesion, distal radius fracture, complex regional pain syndrome or failure that led to reoperation.¹²

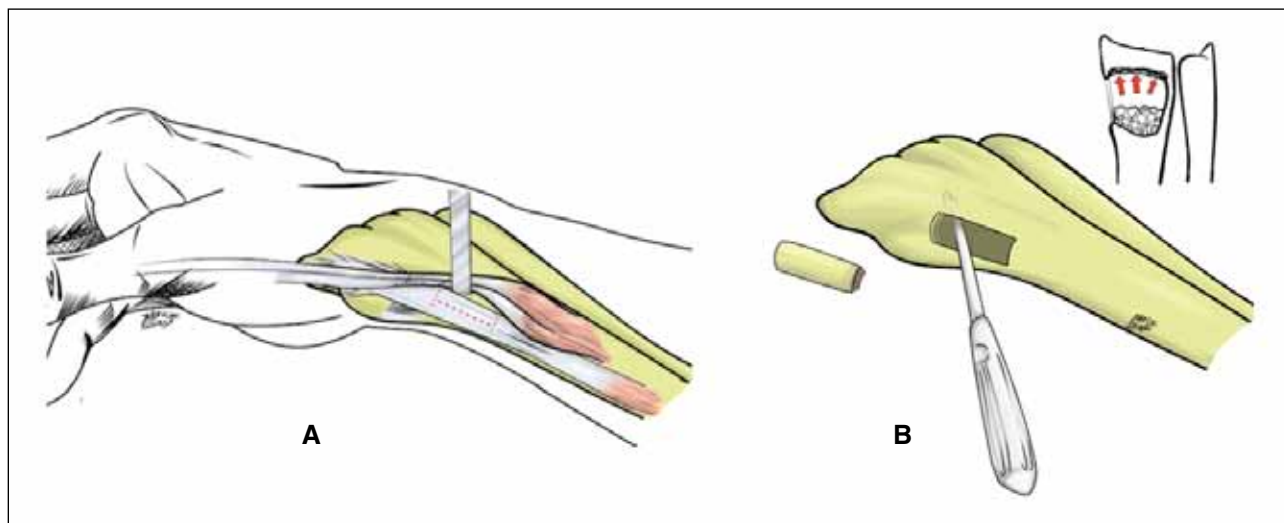
Statistical evaluation

We used averages and standard deviations for the quantitative variables, and percentages for the categorical variables. To compare the preoperative and postoperative quantitative variables, we used non-parametric methods of grouped measurements (Wilcoxon matched pairs test).

Results

According to the score showed by the modified Mayo Clinic scale, medical results were excellent in nine patients, good in 11 cases, moderate in two and poor in one patient who required proximal row carpectomy as revision surgery. According to the visual analogue scale, average preoperative pain was 7 (ranging from 6 to 10), whereas at final follow-up, pain was 1.1 in such scale (ranging from 0 to 6) ($p > 0.05$). What is more, at that moment, 17 out of the 23 patients showed a 0 or 1-score in the visual analogue scale. There were statistically significant differences between stages II and IIIA in terms of symptoms improvement neither in the visual analogue scale nor in the Mayo Clinic score. As compared to the opposite hand, patients' flexion/extension arch averaged 78% and grip strength, 81%. All the patients but two were able to retake their original jobs.

Two patients showed disease radiologic progression from II to IIIA according to the Lichtman's classification, whereas other two wrists developed such progression



▲ **Figure 1.** Anatomic sketch of the distal radius. **A.** "H" tenotomy of the brachioradialis muscle. **B.** Bony window metaphyseal core decompression is carried out through without removing spongy bone.

from IIIA to IIIB. The remaining 19 patients, however, stayed at the same stage as that one they showed previously to the surgery (Figures 2 and 3).

The preoperative CHR in Lichtman's stage II was 1.52 (ranging from 1.48 to 1.58) and 1.38 (ranging from 1.5 to 1.28) in Lichtman's stage IIIA. The average postoperative CHR was 1.5 (ranging from 1.40 to 1.58) in stage II and 1.34 (ranging from 1.42 to 1.25) in stage IIIA; there was no statistically significant decrease in the lunate bone height ($p < 0.05$). We did not detect any complication related to the procedure of metaphyseal core decompression in the distal radius.

Discussion

We analyzed a series of patients with Kienböck's disease in Lichtman's stages II and IIIA treated by metaphyseal core decompression in the distal radius. Medical results were good or excellent in 20 out of the 23 patients that we studied, with a minimal follow-up of 14 years.

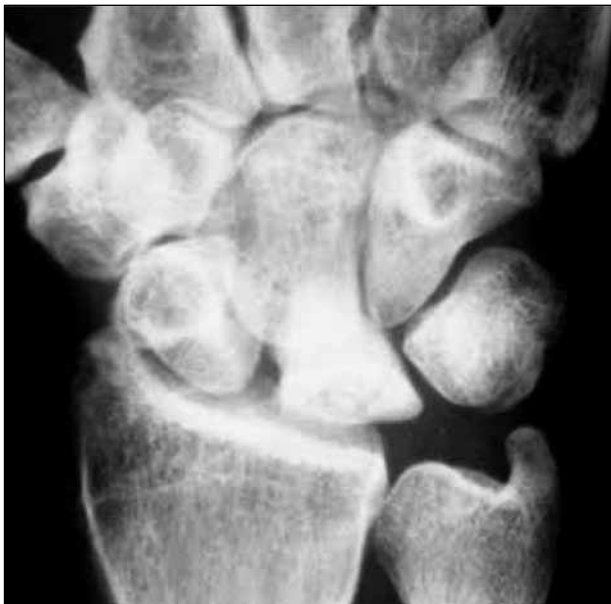There is controversy in literature regarding the surgical treatment of choice.

There are several reports on long-term follow-up which have evaluated results in shortening osteotomy of the radial bone.¹³ Luegmair et al. published a series of 36 patients with an average follow-up of 12.1 years, whereas Watanabe reported a series of 12 patients with a 21 year follow-up.^{14,15} The first study only analyzed patients in Lichtman's stage IIIA whereas in the second study three patients were in stage IIIB; four of them, in stage IIIA

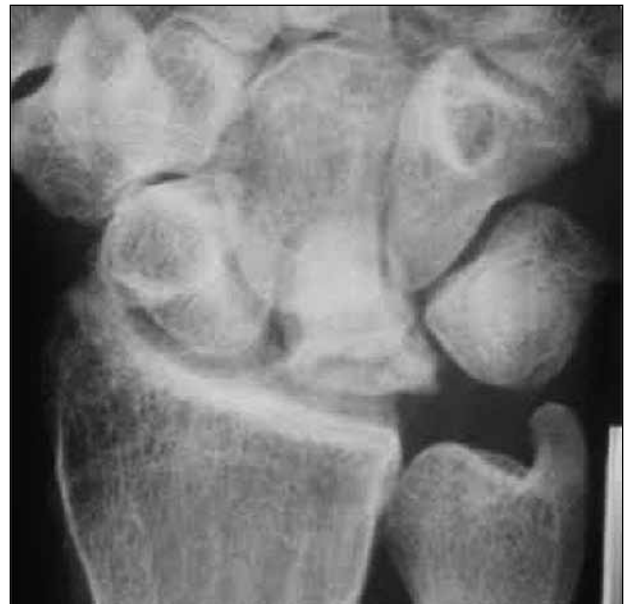and six patients, in stage II. Medical results were similar to ours in terms of improvement of pain, range of motion and grip strength. In the Luegmair's series, however, 14 out of the 36 patients required plate removal and one had to undergo a second surgery for wrist denervation.

There are just few reports on long-term results of vascularized bone graft in Kienböck's disease. Fujiwara published favourable results in the treatment of the Kienböck's disease-state III using vascularized bone graft from distal radius and metacarpal bones.⁸ In another series, Arora et al. carried out free vascularized bone grafting from the iliac crest in 18 patients (15 in Lichtman's stage IIIA and three in stage IIIB) with a 13-year follow-up, and they had satisfactory medical results.¹⁶ However, two of the 18 cases suffered pin infection, two did not incorporate the vascularized graft, and 19% of the whole series got just moderate Mayo Clinic scale-results at last follow-up.

Like Sherman et al., we believe that the beneficial effects of metaphyseal core decompression in the distal radius does not come from the discharge of overpressure on the lunate aspect of the radius (mechanical effect), but from some unknown biological reaction of vascular kind which is generated by the procedure at regional level.¹⁷ Thus, our hypothesis is that, as it is the case in other bone procedures nearby the lunate bone, radial decompression generates a regional vascular stimulus at carpal-bone level. Radial osteotomy may generate—as it has been verified in radial fractures—a cascade release of angiogenesis and osteogenesis factors at regional level which might underlie the effects on the lunate bone caused by radial surgery.¹⁸



▲ **Figure 2.** 45-year-old patient with stage IIIA-Kienböck's disease. Preoperative AP X-ray.



▲ **Figure 3.** AP X-ray 12 years after metaphyseal core decompression of distal radius.

Innes and Strauch revised the results of vascularized bone graft, radial shortening osteotomy and metaphyseal core decompression in the distal radius during the first stages of Kienböck's disease.¹⁹ They compared several publications and agreed on the fact that pain improved independently of the type of treatment, and that what the three techniques had in common was just bone cortex violation in carpal, radial and ulnar bones.

Recently Blanco et al. published favourable results with radial osteotomy without bone shortening, with a minimal 10-year follow-up.²⁰ These authors carried out a complete osteotomy of the distal radius through a posterior approach and fixed the radial bone with a plate. From our point of view, both metaphyseal core decompression in the distal radius and radial osteotomy without bone shortening share the same biological effect. However, we prefer to use metaphyseal core decompression in the distal radius because it is a simpler procedure with no potential

complications related to osteosynthesis or complete radial osteotomy.

This study shows some limitations. First of all, it is a retrospective study conducted in a small number of patients. Secondly, there was no control group; therefore, we cannot draw conclusions in terms of comparison with other types of treatment methods or the impact of metaphyseal core decompression in the distal radius on Kienböck's disease progression.

Conclusions

Results suggest the metaphyseal core decompression in the distal radius is a simple procedure with long-term favourable results, and that could be considered as a surgical alternative for the early stages of the Kienböck's disease.

Bibliography

1. Lichtman DM, Degnan GG. Staging and its use in the determination of treatment modalities for Kienböck's disease. *Hand Clin* 1993;9(3):409-16.
2. Beredjikian PK. Kienböck's disease. *J Hand Surg Am* 2009;34(1):167-75.
3. Ilan CH, Joshi A, Lichtman DM. Kienböck's disease: diagnosis and treatment. *J Am Acad Orthop Surg* 2001;9:128-36.
4. Tambe AD, Trail IA, Stanley JK. Wrist fusion versus limited carpal fusion in advanced Kienböck's disease. *Int Orthop* 2005;29:355-8.
5. Afshar A, Eivaziatashbeik K. Long-term clinical and radiological outcomes of radial shortening osteotomy and vascularized bone graft in Kienböck disease. *J Hand Surg Am* 2013;38(2):289-9.
6. Elhassan BT, Shin AY. Vascularized bone grafting for treatment of Kienböck's disease. *J Hand Surg Am* 2009;34:146-54.
7. Illarramendi AA, Schulz C, De Carli P. The surgical treatment of Kienböck's disease by radius and ulna metaphyseal core decompression. *J Hand Surg Am* 2001;26:252-60.
8. Fujiwara H, Oda R, Morisaki S, Ikoma K, Kubo T. Long-term results of vascularized bone graft for stage III Kienböck disease. *J Hand Surg Am* 2013;38(5):904-8.
9. Nattrass GR, King GJ, McMurtry RY, Brant RF. An alternative method for determination of the carpal height ratio. *J Bone Joint Surg Am* 1994;76(1):88-94.
10. Stahelin A, Pfeiffer K, Sennwald G, Segmüller G. Determining carpal collapse: an improved method. *J Bone Joint Surg Am* 1989;71:1400-5.
11. Illarramendi AA, De Carli P. Radius decompression for treatment of Kienböck disease. *Tech Hand Up Extrem Surg* 2003;7(3):110-3.
12. McKay SD, MacDermid JC, Roth JH, Richards RS. Assessment of complications of distal radius fractures and development of a complication checklist. *J Hand Surg Am* 2001;26:916-22.
13. Martin GR, Squire D. Long-term outcomes for Kienböck's disease. *Hand (NY)* 2013;8(1):23-6.
14. Luegmair M, Goetz F, Kalb K, Cip J, van Schoonhoven J. Radial shortening osteotomy for treatment of Lichtman stage IIIA Kienböck disease. *J Hand Surg Eur* 2017;42(3):253-9.
15. Watanabe T, Takahara M, Tsuchida H, Yamahara S, Kikuchi N, Ogino T. Long-term follow-up of radial shortening osteotomy for Kienböck disease. *J Bone Joint Surg Am* 2008;90:1705-11.
16. Arora R, Lutz M, Deml C, Krappinger D, Zimmermann R, Gabl M. Long-term subjective and radiological outcome after reconstruction of Kienböck's disease stage 3 treated by a free vascularized iliac bone graft. *J Hand Surg Am* 2008;33:175-81.

17. Sherman GM, Spath C, Harley BJ, Weiner MM, Werner FW, Palmer AK. Core decompression of the distal radius for the treatment of Kienböck's disease: a biomechanical study. *J Hand Surg Am* 2008;33:1478-81.
18. Pountos I, Panteli M, Panagiotopoulos E, Jones E, Giannoudis PV. Can we enhance fracture vascularity: What is the evidence? *Injury* 2014;45(Suppl 2):S49-57.
19. Innes L, Strauch RJ. Systematic review of the treatment of Kienböck's disease in its early and late stages. *J Hand Surg Am* 2010;35(5):713-7, 717.e1-4.
20. Blanco RH, Blanco FR. Osteotomy of the radius without shortening for Kienböck's disease: a 10-year follow-up. *J Hand Surg Am* 2012;37(11):2221-5.