

Use of dual-mobility acetabular cups for isolated femoral revision of metal-on-metal hip resurfacing arthroplasty using large-diameter femoral heads

Sebastián E. Valdez

*Department of Orthopedics and Traumatology, Hip and Knee Division,
Clínica 25 de Mayo, Mar del Plata, Buenos Aires (Argentina)*

ABSTRACT

Large-diameter metal head hip arthroplasty revisions have a significant complication rate, mainly related to the removal of the acetabular component, as well as to the type of friction used. In some cases, an isolated femoral revision can be made, sparing the acetabular cup and, thus, decreasing surgical morbidity.

This paper discusses a case successfully treated with a dual-mobility acetabular cup in a patient with a resurfacing hip replacement and a pseudotumor that caused pain and instability.

Mastering this surgical approach allows hip surgeons to solve complex problems in a simple and safe manner, and with a low complication rate.

Key words: Dual-mobility cups; resurfacing hip revision; metal-on-metal hip arthroplasty.

Level of evidence: IV

Cotillos de doble movilidad. Uso para la revisión femoral aislada de prótesis de cadera con fricción metal/metal con cabezas grandes

RESUMEN

Los recambios de cadera con cabezas metálicas grandes provocan una mayor tasa de complicaciones, principalmente asociadas al retiro del componente acetabular, como al par fricción utilizado. En casos determinados, pueden realizarse revisiones femorales aisladas, conservando la copa acetabular, disminuyendo la morbilidad quirúrgica.

Presentamos un caso tratado exitosamente con una copa de doble movilidad, en un paciente con una prótesis de superficie con un pseudotumor que generó dolor e inestabilidad.

El conocimiento de esta técnica quirúrgica permite al cirujano de cadera resolver problemas complejos de forma sencilla y segura, con una baja tasa de complicaciones.

Palabras clave: Copas de doble movilidad; revisión; prótesis de superficie; artroplastias metal/metal.


Nivel de Evidencia: IV

INTRODUCTION

In the last two decades, metal-on-metal hip replacements have gained interest due to their low wear rate and the possibility of using large-diameter femoral heads, which decreases the risk of dislocation and spares the proximal femur in cases of hip resurfacing. These original advantages were overshadowed by allergic reactions to metal debris¹⁻⁵.

The alleged ease of replacement was only such when using hip resurfacing prostheses and sparing the acetabular component. In cases of adverse reactions to metal, reviews report complications without exception.

These reactions are related to debris from metal-on-metal implants used for hip resurfacing surgeries due to wear and corrosion of the implant.

Received on 06/03/2017. Accepted after evaluation on 04/08/2018 • SEBASTIÁN E. VALDEZ, MD • drvaldezmdp@gmail.com 

How to cite this paper: Valdez SE. Use of dual-mobility acetabular cups for isolated femoral revision of metal-on-metal hip resurfacing arthroplasty using large-diameter femoral heads. *Rev Asoc Argent Ortop Traumatol* 2019;84(1):55-62. <http://dx.doi.org/10.15417/issn.1852-7434.2019.84.1.741>

Locally, these complications can present as soft-tissue masses, called “pseudotumors,” which may require an implant revision surgery.

Although friction surfaces of all types of implants carry a risk of metal-related complications, these are more likely in total hip arthroplasties (THA)—in contrast to surfacing procedures—due to the additional debris released at the femoral head-neck junction.

In this paper, we discuss the case of a patient with a surfacing reimplant presenting a pseudotumor and instability as complications.

CLINICAL CASE

A 75-year-old patient with a heart history (4 stents) consulted for pain in the right hip in 2016. He had a history of resurfacing surgery in 2011 (Figure 1).

Three years after the primary surgery, the patient consulted his surgeon for hip pain, for which he was prescribed anti-inflammatory agents and PT. Since the pain persisted, he came to our Department and was diagnosed with a lump on the lateral hip. We ordered an ultrasound, blood work, a puncture and an MRI.

The initial results revealed a fluid-filled mass originating in the hip joint (Figure 2). Cultures were negative; the X-ray showed no signs of osteolysis; components were well-oriented, and erythrocyte sedimentation and C-reactive protein levels were low.

The serum level of chromium and cobalt was lower than the reference range.

The diagnosis was a local adverse reaction to metal, warranting an implant revision. The patient refused, indicating a partial improvement after arthrocentesis, which removed 150 mL of fluid.

In the following visits, the lump recurred, along with pain and functional limitations. The patient continued to refuse surgery.

Later, he came to the ER for implant dislocation when putting on his shoes (something he was previously able to do without any problems).

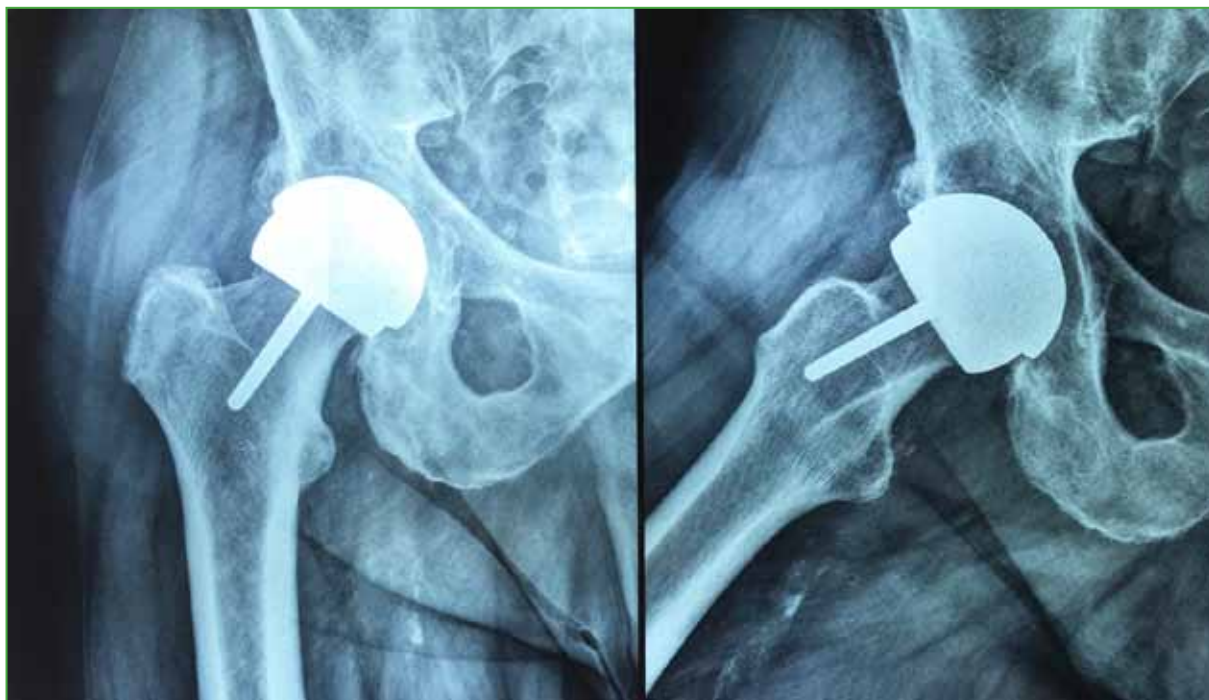

Figure 1. Right hip resurfacing performed five years ago.

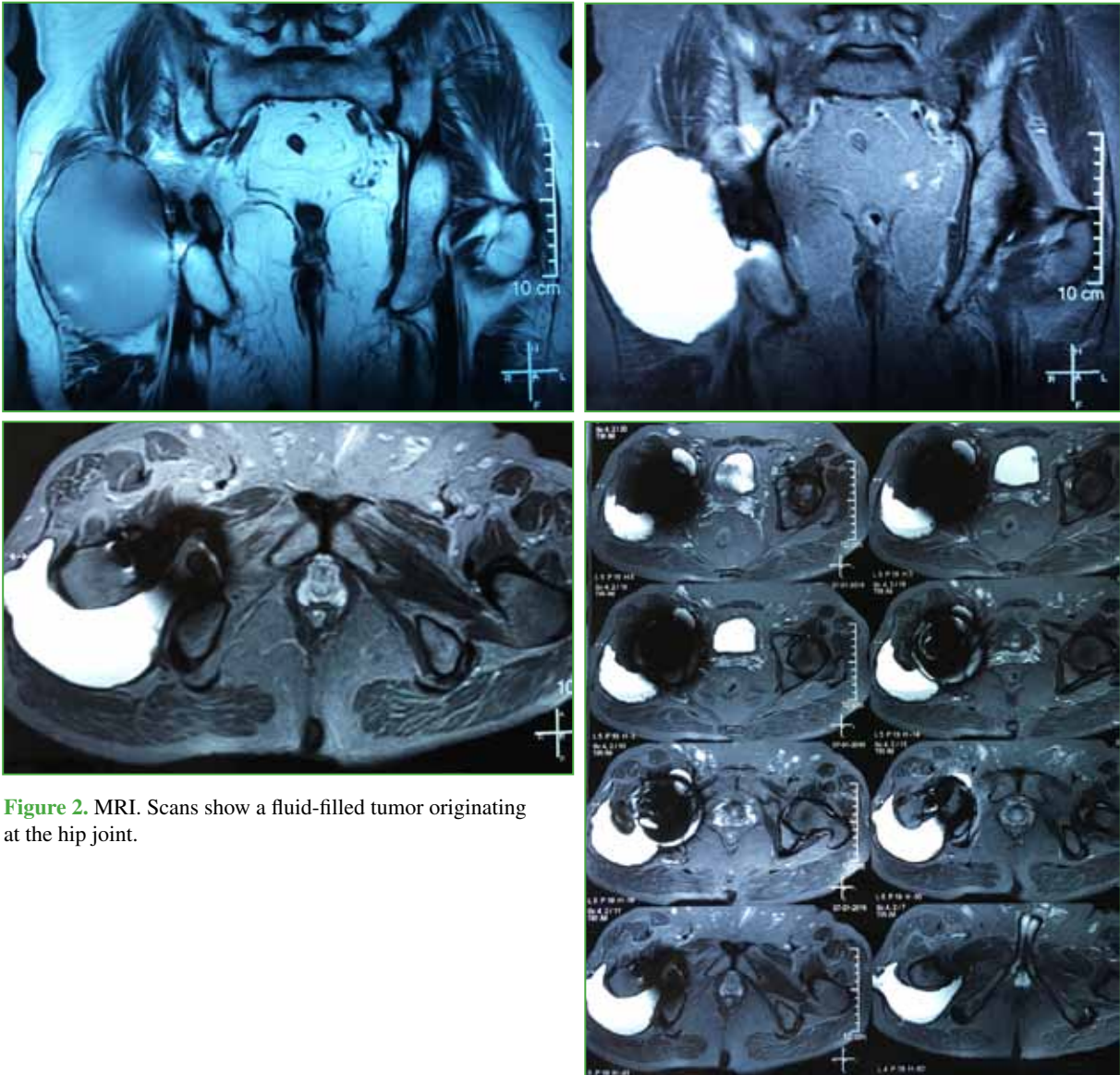


Figure 2. MRI. Scans show a fluid-filled tumor originating at the hip joint.

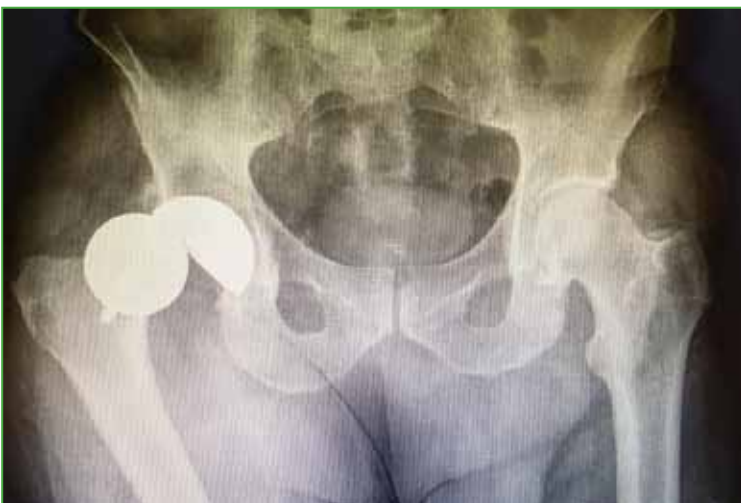

Figure 3. Implant dislocation.

A closed reduction was made and an implant revision with removal of the tumoral mass was planned (Figure 3).

Due to the poor results published in cases of implant replacements due to adverse reactions to metal in patients with solid or liquid-filled masses¹⁻⁵, we decided to perform a THA with a ceramic head and a dual-mobility acetabular cup, leveraging the well fixed and metal cup. The alumina ceramic head would prevent a new source of metallosis at the femoral head-neck junction, and the large polyethylene cup would reduce the risk of dislocation, particularly in this case^{6,7}.

The surgery was performed with spinal anesthesia, using the same posterolateral approach from the previous surgery. We found a mass filled with 500 mL of a dark-brown fluid and well-defined margins (Figure 4), originating from the prosthetic joint,

which was completely removed. After a thorough examination of the acetabular cup, we decided to spare it. We performed an osteotomy at the femoral stem location to remove it and replace it with a cementless HA-coated one.

A polyethylene mobile liner (Amplitude) was used for insertion of the 54 mm-acetabular cup the patient already had (Figure 5). Cultures from samples taken intra-operatively were negative.

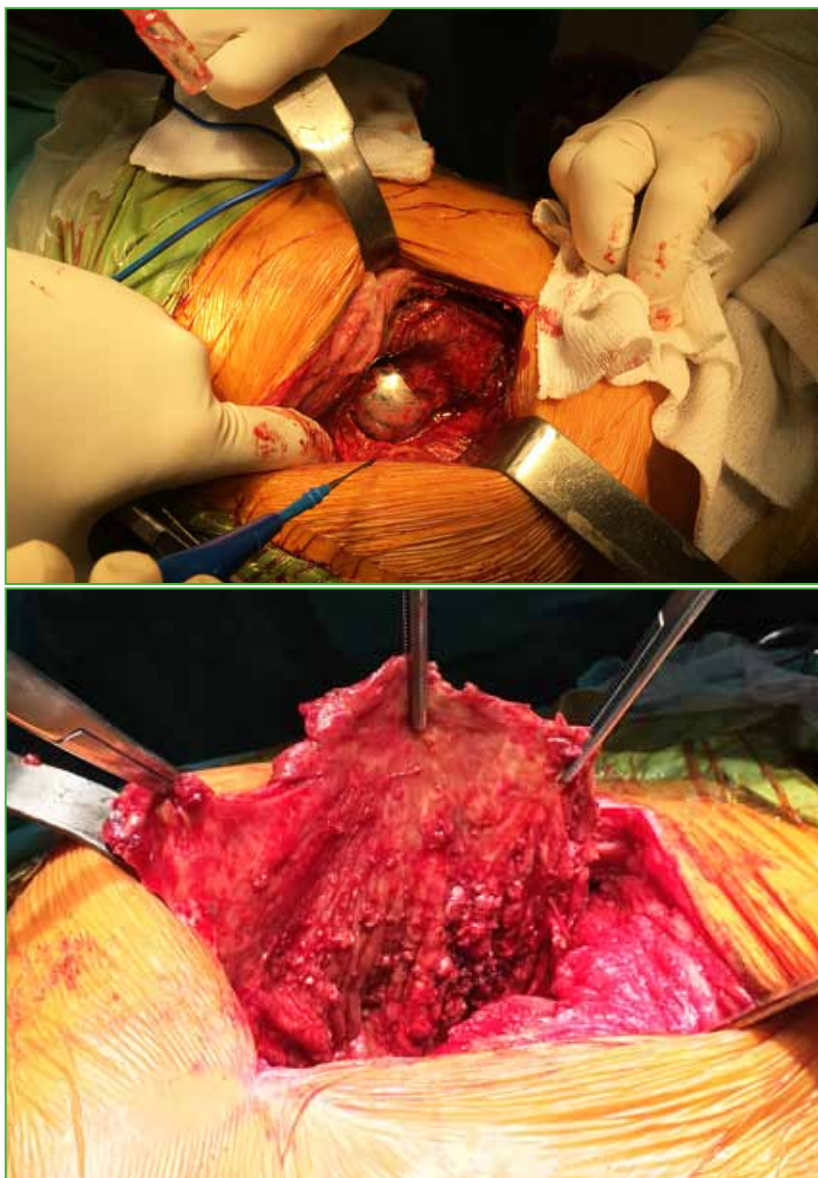


Figure 4. Intra-operative scans showing a dark-brown fluid-filled tumor with well-defined margins.

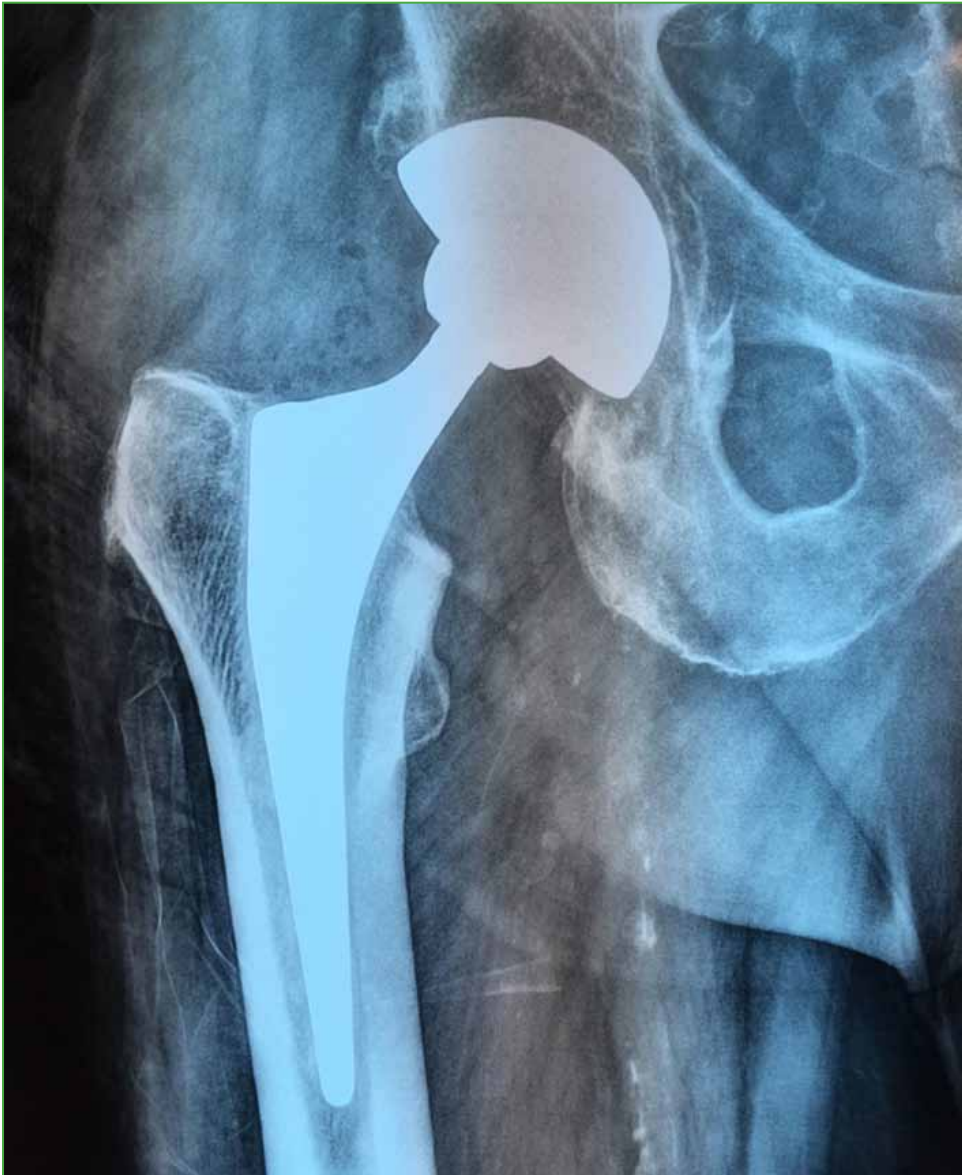

Figure 5. Post-operative X-ray. Cementless dual-mobility implant sparing primary resurfacing cup.

After a 45-minute surgery, correct stability was achieved. The patient did not require transfusions and immediately resumed standing on both feet without any aids.

Ten days after surgery, the wound began to suppurate. The wound was cleaned, and a specimen was taken, which analysis revealed methicillin-resistant *Staphylococcus epidermidis*. Successful specific antibiotic treatment was administered for three months (seven days intravenously and the rest orally).

DISCUSSION

In recent years, adverse reactions to metal debris have caused an increasing number of surgical revisions. In 2012, in England, Wales and Ireland, implant replacements of this nature accounted for 13.2% of all revisions⁸.

Although the indications for implant replacement due to metal-related reactions are still unclear, especially in asymptomatic patients, recommendations for early revisions do exist due to poor outcomes and higher morbidity in advanced cases^{8,9}.

It is important to note that, in general, metal-on-metal implants have been used in young and active people. Poor outcomes in these cases result in severe deficits on quality of life, as well as on work-related and leisure activities.

Several studies on revisions made due to reactions to metal debris on patients with traditional implants show a high rate of complications and the need for surgical revisions, mainly due to dislocations, infections, aseptic loosening, and recurrence of metal-related adverse reactions.

Reported outcomes of pseudotumors are poorer than those published for surgical revisions of metal-on-metal implants due to other causes, such as loosening, fractures, among others^{2,8,10}.

Instability presents due to the need of soft-tissue debridement as a result of pseudotumors and to the primary compressive and damaging injury they produce. The smallest-sized femoral head frequently used for metal implant replacements also plays a role as the cause of dislocations.

The highest rate of infections might be a result of necrosis and dead spaces.

Aseptic loosening is related to bone loss caused by adverse reactions to metal debris that affect implant fixation and bone-implant integration.

Recurrent metallosis has been reported in patients whose implants were replaced by another metal-on-metal implant, a prosthesis with friction at the femoral head-neck junction or other modular components^{2,8,11,12}. Incompletely resected tumors can also be a recurrence factor in this kind of reactions.

Due to poor outcomes, especially those related to soft tissues, and their consequences, we developed a strategy that might prove useful in the performance of surgical revisions in most of these cases.

The strategy consisted in reducing surgical morbidities, improving functional scores and lowering the rate of complications compared with the one described for revisions of traditional replacements resulting from pseudotumors¹².

In our case, we decided to perform a one-component revision, eradicating the source of metallic ion release, both at the joint friction surface and the modular components. Another goal was to use a large-diameter head to avoid dislocations and reduce dead space. Bearing that in mind, we performed the surgical revision of our patient using a dual-mobility implant comprised by a mobile polyethylene acetabular cup and a 28 mm-ceramic head, thus avoiding any kind of metal-on-metal friction.

Similar successful cases have been published^{12,16}. American surgeon Pritchett reported 14 cases with a follow-up of 41 months and no complications whatsoever¹².

Verhelst and colleagues described this approach as a new strategy to deal with metal-on-metal friction complications. They reported three cases, with one of them presenting persistent serous suppuration, which did not require treatment.

While they used 22 mm-chromium-cobalt heads, serum levels of these metals decreased in all cases¹³.

Renowned surgeons such as Berend, Lombardi and Craig de la Valle, among others, carried out a multicenter trial which assessed 25 patients treated with this approach. They reviewed 11 resurfacing implants and 14 THA of metal-on-metal implants sparing the acetabular cup. For this, they used metal and ceramic heads. Their report described only one complication (intraprosthetic dislocation) in one female patient with a BMI of 44.4 and a 67°-acetabular inclination. Blood loss was only 250 mL. Twenty-two of the 25 patients achieved good and excellent outcomes during a short-term follow-up¹⁴.

Figueras and colleagues described 10 patients treated with this approach. They deem it an attractive alternative with a low morbidity rate in cases of well-fixed and oriented cups. Their report highlights bone stock preservation and absence of complications¹⁵.

These cups, as described in this paper, are dual-mobility cups¹⁷.

They have been used in Europe for decades, but it wasn't until 2009 that they were approved by the United States Food and Drug Administration (FDA). Currently, manufacturers such as Amplitude, Smith and Nephew, Biomet, Stryker, Novae, SunFit, among others, carry this type of implant. In Argentina, there are several surgical groups (especially in Córdoba) with proven success using dual-mobility implants, since they have been educated in Orthopedics following the French line of thinking.

The main advantage of these implants is that they can be used in patients with a high risk of postoperative dislocation (as those requiring revisions), tumor prostheses, lateral femur fractures requiring prostheses, or neurological conditions, elder people, patients with cognitive deficits, morbid obesity, etc. There are highly experienced surgeons who also state they can be used for primary THA in high-performance patients¹⁸.

I personally think that intraprosthetic dislocation rates would be higher in said patients¹⁷.

To these standard indications we could add metal-on-metal implant revisions, carried out either by resurfacing or by the traditional approach, in patients with metal-related complications. Mainly in cases preserving the acetabular component or in femoral component-only revisions, correct fixation and orientation of this component is key to spare it. Therefore, it should be thoroughly examined in search of damage indicators. This also proves useful when performing large-diameter metallic head-only revisions, which only require a ceramic head and a mobile polyethylene liner, preserve the intramedullary stem, and remove metal-on-metal friction and corrosion at the femoral head-neck junction.

CONCLUSIONS

Considering the high rate of complications described for revisions of metal-on-metal prostheses, the use of dual-mobility cups allows for preservation of the acetabular component in selected cases, with a lower surgical morbidity and fewer complications compared to revisions that include the acetabular cup. Regarding postoperative instability, this choice of implant maintains a large head diameter and improves stability, while also eliminating sources of metal debris.

The downside to this is that this paper reviews only one case, added to the scarce publication of similar cases, which had a short-term follow-up and no control group. However, implants used for this patient are the same as those of a standard dual-mobility prosthesis, with a long-proven record in Europe and excellent long-term results if the indication is appropriate.

Conflict of interest: The author claims he does not have any conflict of interest.

S. E. Valdez ORCID iD: <http://orcid.org/0000-0001-6824-1212>

REFERENCES

1. Snir N, Park BK, Garofalo G, Marwin SE. Revision of failed hip resurfacing and large metal on metal total hip arthroplasty using dual mobility components. *Orthopedics* 2015;38(6):369-74. <https://doi.org/10.3928/01477447-20150603-04>
2. Grammatopoulos G, Pandit H, Kwon YM. Hip resurfacings revised for inflammatory pseudotumour have a poor outcome. *J Bone Joint Surg Br* 2009;91(8):1019-24. <https://doi.org/10.1302/0301-620X.91B8.22562>
3. Browne JA, Bechtold CD, Berry DJ, Hanssen AD, Lewanllen DG. Failed metal-on-metal hip arthroplasties: a spectrum of clinical presentations and operative findings. *Clin Orthop Relat Res* 2010;468(9):2313-20. <https://doi.org/10.1007/s11999-010-1419-0>
4. Su EP, Su SL. Surface replacement conversion: results depend upon reason for revision. *Bone Joint J* 2013;95 (11 Suppl A):88-91. <https://doi.org/10.1302/0301-620X.95B11.32663>
5. Matharu GS, Pynsent PB, Dunlop DJ. Revision of metal and metal hip replacements and resurfacings for adverse reaction to metal debris: a systematic review of outcomes. *Hip Int* 2014;24:311-320. <https://doi.org/10.5301/hipint.5000140>
6. Combes A, Migaud H, Girard J, Duhamel A, Fessy MH. Low rate of dislocation of dual mobility cups in primary total hip arthroplasty. *Clin Orthop Relat Res* 2013;471(12):3891-900. <https://doi.org/10.1007/s11999-013-2929-3>
7. Guyen O, Pibarot V, Vaz G, Chevillat C, Bejui-Hegues J. Use of a dual mobility socket to manage total hip arthroplasty instability. *Clin Orthop Relat Res* 2009;467(2):465-72. <https://doi.org/10.1007/s11999-008-0476-0>
8. National Joint Registry for England and Wales. National Joint Registry for England and Wales 8th Annual Report 2011. Hertfordshire, United Kingdom: National Joint Registry for England and Wales; 2011. <http://www.njrcentre.org.uk/njrcentre/portals/0/documents/njr%208th%20annual%20report%202011.pdf>
9. Haddad FS, Thakrar RR, Hart AJ. Metal on metal bearings: the evidence so far. *J Bone Joint Surg Br* 2011;93:572-79. <https://doi.org/10.1302/0301-620X.93B4.26429>

10. De Smet KA, Van Der Straeten C, Van Orsouw M, Doubi R, Backers K, Grammatopoulos G. Revisions of metal on metal hip resurfacing: lessons learned and improved outcome. *Orthop Clin North Am* 2011;42(2):259-69. <https://doi.org/10.1016/j.ocl.2011.01.003>
11. Rajpura A, Porter ML, Gambhir AK, Freemont AJ, Board TN. Clinical experience of revision of metal on metal hip arthroplasty for aseptic lymphocyte dominated vasculitis associated lesions (ALVAL). *Hip Int* 2011;21:43-51. <https://doi.org/10.5301/HIP.2011.6276>
12. Pritchett JW. One-component revision of failed hip resurfacing from adverse reaction to metal wear debris. *J Arthroplasty* 2014;29:219-24. <https://doi.org/10.1016/j.arth.2013.04.011>
13. Verhelst LA, Van der Bracht H, Vanhegan IS, Van Backlé B, De Schepper J. Revising the well-fixed, painful resurfacing using a double-mobility head: a new strategy to address metal-on-metal complications. *J Arthroplasty* 2012;27(10):1857-62. <https://doi.org/10.1016/j.arth.2012.05.012>
14. Plummer DR, Botero HG, Berend KR. Salvage of monoblock metal-on-metal acetabular components using a dual-mobility bearing. *J Arthroplasty* 2016;31(4):846-9. <https://doi.org/10.1016/j.arth.2015.08.016>
15. Figueras G, Planell RV, Serra Fernandez R, Biayna JC. Revision of metal-on-metal hip arthroplasty with well-fixed and positioned acetabular component using a dual-mobility head and review of literature. *Open Orthop J* 2016;10:512-21. <https://doi.org/10.2174/1874325001610010512>
16. Sassoon AA, Barrack RL. Pseudotumour formation and subsequent resolution in metal-on-metal total hip arthroplasty following revision. *Bone Joint J Br* 2016;98(6):736-40. <https://doi.org/10.1302/0301-620X.98B6.36908>
17. Valdez S, Bouxin B. Cótilos con doble movilidad: principios, ventajas y resultados. *Rev Asoc Argent Ortop Traumatol* 2009;74:102-10. http://www.scielo.org.ar/scielo.php?script=sci_arttext&pid=S1852-74342009000100016
18. Hamadouche M, Arnould H, Bouxin B. Is cementless dual mobility socket in primary THA a reasonable option? *Clin Orthop Relat Res* 2012;470(11):3048-53. <https://doi.org/10.1007/s11999-012-2395-3>