

Traumatic lumbosacral spondylolisthesis

Report of four cases and literature review

JUAN PABLO GUYOT,* EMANUEL ZARAGOZA,# RUY LLOYD,*#
RAÚL FURMENTO,# FEDERICO GELOSI*#

**Orthopedics Department, Hospital Universitario Austral, Pilar, Buenos Aires*
#*Orthopedics Department, Hospital Británico of Buenos Aires,*
Ciudad Autónoma de Buenos Aires

Received on April 28th, 2015; accepted after evaluation on June 30th, 2015 • JUAN PABLO GUYOT, MD • juanpabloguyot@gmail.com

ABSTRACT

In 1976, Wiltse et al. classified spondylolisthesis into five groups according to its etiology—dysplastic, isthmic, degenerative, tumoral and traumatic spondylolisthesis. Traumatic spondylolisthesis is one of the most infrequent ones—so far, there are very few reports. Traumatic spondylolisthesis are injuries hardly frequent. Usually they are related to high-energy trauma and often they are associated with injuries in the abdominal organs and thorax, and cranioencephalic trauma. The vast majority of these injuries are usually subject to surgical treatment due to their great instability. We present four patients operated on over the past few years, with a minimal follow-up of four years, and an up-dated review of specialized literature.

Key words: Traumatic spondylolisthesis; lumbo-pelvic dislocation; spinal trauma.

Level of evidence: IV

ESPONDILOLISTESIS TRAUMÁTICA LUMBOSACRA. REPORTE DE CUATRO CASOS Y REVISIÓN DE LA BIBLIOGRAFÍA

RESUMEN

En 1976, Wiltse y cols. clasificaron a las espondilolistesis en cinco tipos, según su etiología: displásica, ístmica, degenerativa, tumoral y traumática. Esta última es una de las más infrecuentes; hasta la fecha, se han publicado muy pocos casos. Las espondilolistesis traumáticas son lesiones poco frecuentes. Su causa suele estar relacionada con traumas de alta energía y es frecuente su asociación con lesiones de órganos abdominales, craneoencefálicos y tórax. La gran mayoría de estas lesiones son habitualmente de resolución quirúrgica por su alta inestabilidad.

Se presentan cuatro pacientes operados en el último tiempo, con un seguimiento mínimo de 4 años, y una revisión actualizada de la literatura.

Palabras clave: Espondilolistesis traumática; disociación lumbopelviana; trauma espinal.

Nivel de Evidencia: IV

Conflict of interests: The authors have reported none.

Introduction

In 1976, Wiltse et al. classified spondylolisthesis in five types according to its etiology—dysplastic, isthmic, degenerative, tumoral and traumatic spondylolisthesis.¹ Traumatic spondylolisthesis is the most infrequent type—so far, there are very few reports. It usually occurs after high-energy trauma, especially traffic accidents and, sometimes, it is associated with signs of radicular injury.²

We present four patients operated on over the past few years with a minimal follow-up of four years, and an updated review of specialized literature.

Cases

We present four patients with lumbosacral spondylolisthesis of traumatic origin; three of them in the L5-S1 segment, and the other one at S1-S2 level. The average age at the time of the injury was 32.2 years old (ranging from 25 to 54). All of them were males.

The injury had been brought about by high-energy trauma—in one case, at falling from horseback and, in the other ones, due to traffic accidents.

It is worth highlighting that only one patient showed signs of radicular injury by his remarkable decrease in dorsal flexion in his left foot (M3); another one felt pain in the S1 nerve root territory, which improved by decompression, and the other two patients did not show signs of compression at sac-nerve root level.

At analyzing imaging studies, we detected three patients with traumatic spondylolisthesis as unique spinal injury, whereas in another one this finding was associated with an L2 crash fracture (type A4 in the AO Classification).³

At admission, most patients (three) suffered injuries in abdominal organs which required immediate surgical resolution and put off the treatment of the axial skeleton.

All the cases were operated on by sac-nerve root decompression and instrumented stabilization by posterior approach.

One patient had an acute infection in the surgical approach which required toilette two weeks after the surgery plus antibiotic treatment, with good results. In this case, it was necessary to carry out anterior approach for the stabilization of the L2 crash fracture, which was carried out eight months after the initial treatment of the lumbosacral fracture-dislocation.

During the surgery, the four patients had great segmental instability with remarkable involvement of the ligament indemnity; therefore, we decided to carry out instrumentation in the two cephalic segments as well as two anchorage spots below the injury in all cases. In the patient with L2 fracture, instrumentation was extended up to T11.

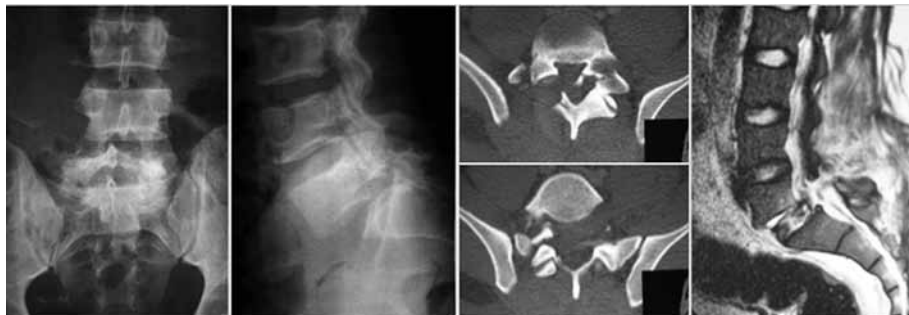Only one of the cases showed signs of non-union by rupture of one of the bars, and it was necessary to revise him six months after the initial surgery. At long-term follow-up, all the patients were able to re-take day-to-day activities at levels similar to those ones previous to the injury (Figures 1-3).

Discussion

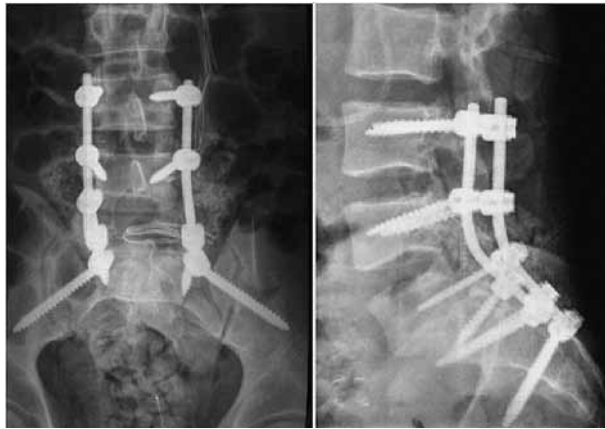
L5-S1 traumatic spondylolisthesis, also known as traumatic lumbosacral dislocation, is a very infrequent condition; so much so, that publications so far have only dealt with case reports, with no clear consensus about its physiopathology and treatment.⁴

Watson-Jones published the first case in 1940, and attributed this injury to a mechanism of hyper-extension.⁵ However, nowadays it is believed that it results from a mechanism that combines hyper-flexion and compression forces.

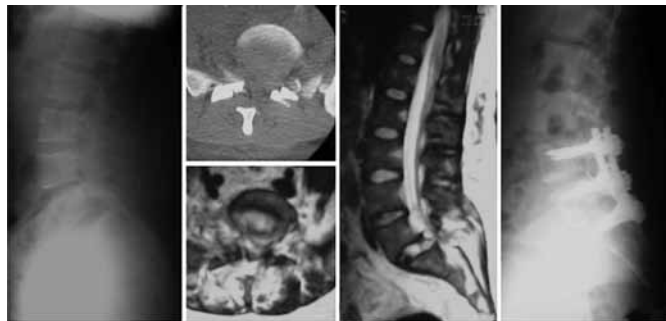
Facet dislocation or fracture-dislocation is a frequent condition in the cervical spine. However, at lumbosacral level, the presence of the ilio-lumbar ligaments and the orientation of the joint aspects give the spine considerable intrinsic stability; therefore, for an injury at this level to occur more than one prevailing force have to concur.



▲ **Figure 1.** L5-S1 traumatic spondylolisthesis. In imaging studies there is L5 displacement upon the sacral bone associated with rotation of the cephalic vertebral bones, facet dislocation as well as an injury in the posterior ligament complex and the L5-S1 disc.



▲ **Figure 2.** Resolution of the case in Figure 1. Instrumentation between L3 and the pelvic bone because of great segmental instability.



▲ **Figure 3.** L5-S1 traumatic spondylolisthesis resolved by short arthrodesis due to the lesser instability during the surgery.

Biomechanical studies show that it takes the combination of a hyper-flexion mechanism with shearing forces upon the sacral bone, together with a rotation force, for a facet dislocation to take place.⁶

This infrequent injury results from high-energy trauma, especially traffic accidents. Injuries in the axial skeleton usually are associated with injuries in abdominal organs and thorax, cranioencephalic trauma, and even fractures in long bones. Therefore, there are many cases in which they are not initially diagnosed, and it is necessary to suspect them strongly to make timely diagnosis.⁵

X-rays sometimes are enough to reach diagnosis and they show L5 displacement upon the sacral bone. In all cases, evaluation has to be rounded off with CT scan to visualize the facet anomalies (fracture or dislocation), apart from pedicle indemnity, what will be useful for pre-operative planning. Another radiographic sign, which can be seen in many reported cases, is the association of this injury with fracture in lumbar transverse processes, a sign which should lead us to suspect lumbosacral fracture-dislocation.

However, sometimes the quality of X-rays at the Emergencies Room makes it impossible to identify subtle L5-S1 displacements, cases in which CT scan takes on major importance in diagnosis.

MRI helps to identify injuries in vertebral discs and the posterior ligament complex. In our series, the four patients also had injuries in the vertebral disc and the posterior ligament complex in the affected segment.

There are two classifications set out for these injuries, which differentiate them according to the injured structures and the degree of rotation at the lumbosacral joint level.^{7,8} Both classifications are descriptive and coincide in treatment guidelines.

With respect to therapeutic procedures, standpoints and publications are diverse. Most treatments are based on isolated cases, since the largest case series that has been published so far is made up of just 11 cases, collected at six different centers.⁷

Given the great number of injured structures stemming from the pathophysiology of this injury (disc, ligament, and bone), it is considered a highly unstable injury. Even

though there are reports on cases treated conservatively, nowadays, most authors agree on instrumented stabilization by posterior approach.⁹

The greatest controversy has broken out over the anterior support complement to be given to the L5-S1 disc and the levels to give instrumentation to, mainly towards the cephalic end. With respect to the anterior support, there are authors who prefer to use it whenever there are signs of disc injury, whereas other surgeons are inclined to posterolateral fixation in traumatic injuries.⁴ On our part, we decided instrumented stabilization by posterior approach

in all cases. We decided not to use inter-somatic devices due to the possibility of posterior migration. In one patient we added anterior approach, but it was for stabilization of the fracture in the cephalic segment.

With respect to instrumentation in the cephalic segments, most authors try to preserve as many segments as possible. In the patients in our series we attempted the same but, during the surgery, we needed at least two instrumentation segments towards the cephalic end in all cases, due to the great local instability in these kinds of injuries.

Bibliography

1. Wiltse LL, Newman PH, Macnab I. Classification of spondylolysis and spondylolisthesis. *Clin Orthop* 1976;117:23-29.
2. Lamm M, Henriksen SE, Eiskjaer S. Acute traumatic L5-S1 spondylolisthesis. *J Spinal Disord Tech* 2003;16(6):524-527.
3. Vaccaro AR, Oner C, Kepler CK, Dvorak M, Schnake K, Bellabarba C, et al. AOSpine thoracolumbar spine injury classification system: fracture description, neurological status, and key modifiers. *Spine (Phila Pa 1976)* 2013;38(23):2028-2037.
4. Herrera AJ, Berry CA, Rao RD. Single-level transforaminal interbody fusion for traumatic lumbosacral fracture-dislocation: a case report. *Acta Orthop Belg* 2013;79(1):117-122.
5. Tsirikos AI, Saifuddin A, Noordeen MH, Tucker SK. Traumatic lumbosacral dislocation: report of two cases. *Spine (Phila Pa 1976)* 2004;29(8):E164-E168.
6. Roaf R. A study of the mechanics of spinal injuries. *J Bone Joint Surg Br* 1960;42:810-823.
7. Vialle R, Charosky S, Rillardon L, Levassor N, Court C. Traumatic dislocation of the lumbosacral junction diagnosis, anatomical classification and surgical strategy. *Injury* 2007;38(2):169-181.
8. Aihara T, Takahashi K, Yamagata M, Moriya H. Fracture-dislocation of the fifth lumbar vertebrae. A new classification. *J Bone Joint Surg Br* 1998;80:840-845.
9. Fabris D, Costantini S, Nena U, Lo Scalzo V. Traumatic L5-S1 spondylolisthesis: report of three cases and a review of the literature. *Eur Spine J* 1999;8(4):290-295.