

# Osteosynthesis of ankle fracture. Evolutionary analysis with early loading Preliminary study

JUAN MANUEL YAÑEZ ARAUZ,<sup>\*</sup> IGNACIO R. ARZAC ULLA,<sup>\*\*</sup> GUSTAVO FIORENTINI,<sup>\*\*</sup>  
JUAN MARTÍN YAÑEZ ARAUZ<sup>#</sup>

<sup>\*</sup>Leg, Ankle and Foot Department, Hospital Universitario Austral, Buenos Aires

<sup>\*\*</sup>Leg, Ankle and Foot Department, Hospital "Churrucá-Visca", Buenos Aires

<sup>#</sup>Medical Student

Received on March 30<sup>th</sup>, 2015; accepted after evaluation on August 10<sup>th</sup>, 2015 • IGNACIO R. ARZAC ULLA, MD • ignacioarzac@hotmail.com

## Abstract

**Introduction:** Reduction and fixation of ankle fractures allow early recovery. However, typically the weight load is not allowed for about 6 weeks. The aim of this study is to analyze if immediate weight bearing in patients with fibula fractures produces complications and/or secondary displacement.

**Methods:** Twenty-one patients with AO type 44B1 operated fractures were analyzed, and immediate loading was indicated.

Clinical and radiographic outcomes were evaluated. Follow-up was >3 months.

**Results:** Weight load with a walker boot protection occurred, on average, at day 2. The AOFAS ankle score averaged 99 points three months after surgery. Patients returned to work at 2.1 months and to the previous sporting activity at 2.95 months, on average.

**Conclusions:** Patients with low-energy AO type 44B1 fractures, treated by reduction and osteosynthesis, can support early weight load without risk of secondary movements. Early loading with early mobilization has a very good clinical outcome, and it does not induce a higher rate of complications.

**Key words:** Ankle fracture; load weight.

**Level of Evidence:** IV

## OSTEOSÍNTESIS DE FRACTURA DE TOBILLO. ANÁLISIS EVOLUTIVO CON CARGA PRECOZ. ESTUDIO PRELIMINAR

## Resumen

**Introducción:** La reducción y la osteosíntesis de las fracturas de tobillo permiten una recuperación precoz. Sin embargo, clásicamente, no se permite la carga del peso durante casi seis semanas. El objetivo de este estudio es analizar si la carga inmediata del peso en pacientes con fracturas de peroné produce complicaciones o desplazamientos secundarios, o ambos.

**Materiales y Métodos:** Se estudió a 21 pacientes con fracturas de tipo AO 44B1 operados, a quienes se les indicó carga inmediata. Se analizó su evolución clínica y radiológica. El seguimiento fue superior a tres meses.

**Resultados:** La carga del peso con protección con bota "walker" ocurrió, en promedio, a los dos días. El puntaje de la AOFAS para tobillo a los tres meses de la cirugía fue de 99. El tiempo promedio para el retorno a la actividad laboral fue de 2.1 meses y de 2.95 meses para la actividad deportiva.

Conflict of interests: The authors have reported none

**Conclusiones:** Los pacientes con fracturas de tipo AO 44B1 de baja energía, tratados mediante reducción y osteosíntesis, pueden realizar carga del peso precoz, sin riesgo de desplazamientos secundarios. La carga precoz junto a la movilización temprana logra una muy buena evolución clínica, y no incide en un mayor índice de complicaciones.

**Palabras clave:** Fractura de tobillo; carga de peso.

**Nivel de Evidencia:** IV

## Introduction

In the past, the fibula was considered a static lateral structure in the ankle joint; nowadays, however, together with the inferior tibio-fibular ligaments it is acknowledged as functionally more important and dynamic than that.<sup>1-3</sup> Fibular mobility stems from the orientation of its inferior joint surface and the interosseous membrane.<sup>1</sup> When the leg is subject to axial loading, the fibula moves downward, reducing the talar mortise and increasing stability<sup>2,4</sup> except when it is osteotomized, occasions on which it moves upward.<sup>3</sup> When the ankle moves from plantar flexion to dorsal flexion, the fibula moves laterally and posteriorly.<sup>5-7</sup>

Loading on the ankle was widely studied by Lambert, who reports that the interosseous membrane has little effect on such and that the fibula gets 1/6, i.e. 15% of the load.<sup>8</sup>

Takabe et al. report that, if the interosseous membrane is cut, ankle loading does not change. On the contrary, Skraha y Greenwald report that cutting the inferior tibio-fibular ligaments reduces loading on the fibula<sup>9,10</sup> and increases its mobility downward. Moreover, they affirm that syndesmosis reparation fixing the tibia and the fibula with one or two screws alters loading distribution on the fibula.<sup>8</sup>

Ankle fracture-dislocations and unstable fractures are generally treated by stable open reduction and internal fixation (ORIF) to avoid mal-union, joint defects and non-union.<sup>11-15</sup> Standard osteosynthesis techniques for distal fibula fractures consist of internal stabilization by inter-fragmentary compression screws and neutralization plates and screws.<sup>16,17</sup> Since at this level soft tissue covering is thin, and based on the principles of biological surgery, minimally invasive surgery (MIS) is a useful alternative when the skin shows injuries, blisters or contusions.<sup>18,19</sup>

Osteosynthesis with the MIS technique, by indirect reduction, decreases iatrogenesis on soft tissues and bone vascularization, and it also preserves the fracture hematoma.<sup>20-24</sup> Together with this scarcely traumatic technique, there is development of osteosynthesis systems that allow less trauma and absolute stability.

The aim of this study is to analyze if fibular fractures with incomplete injury of the medial complex (neither tibial malleolar fracture nor complete tear of the medial ligamentary complex) surgically treated by reduction and

osteosynthesis can be subject to total weight loading in the immediate postoperative period with no complications or secondary displacements.

## Materials and Methods

### Population sample

Between March 2010 and September 2013, we treated 32 patients with ankle fractures B1 type as described by the AO classification. Among them, 21 were monitored and included in this study.

All the patients were operated on by conventional ORIF or MIS using one third tubular plates and interfragmentary compression screws.

The selection criteria for the method were based on previous assessment and X-ray evaluation, with or without computer tomography scan. We evaluated the type, the localization (transsyndesmotric), the number of fragments and the fracture line, the fracture displacement, and also whether or not there was complete injury of the medial complex. All of them were transsyndesmotric ankle fractures (Weber B) with neither involvement of the medial complex nor posterior malleolar fracture. Three patients were treated by conventional open reduction whereas the other 18 patients received MIS.

Inclusion criteria were: 1) distal fibula trans-syndesmotric fractures (AO B), 2) closed fractures, 3) acute fractures, 4) unimalleolar fractures, 5) fibula fractures with less than three fragments, 6) 12-month minimal follow-up, 7) surgical treatment (ORIF or MIS).

Exclusion criteria were: 1) fibula supra-syndesmotric fractures (AO C), 2) fibula infra-syndesmotric fractures (AO A), 3) open fractures, 4) fibula comminuted fractures, 5) immature skeleton fractures, 6) bimalleolar or three-malleolar fractures (or their ligamentary variants), 7) lack of follow-up.

Before the surgery, patients were asked to take anterior-posterior, lateral and 20° -internal rotation anterior-posterior X-rays of the affected ankle. This allowed us to establish the fracture pattern, the number of fragments, misalignments and displacements; moreover, we were able to classify the fracture and plan the surgery.

We used the AO/OTA classification of malleolar fractures and recorded whether or not there was open fracture or ankle dislocation.

### Case Analysis

In all cases, we recorded the time passed between the fracture and the surgery. Reduction and osteosynthesis were performed with ORIF or MIS techniques using conventional one third tubular plates (7 patients) or locking plates (14 patients).

Thirty-eight patients were discharged on the surgery day, and the remaining 62%, following the protocol of the Health Center they were treated at, 24 hours later. Patients received medical and X-ray follow-up. Body Mass Index was recorded.

All patients were allowed weight loading in the immediate postoperative period. Immediate postoperative weight loading was considered to be patients resting on their operated ankle within the first six days after the surgery, bearing in mind that, out of fear or pain, some patients did not want to rest on their operated ankle even though they were allowed to do so. Medical follow-up was carried out by the ankle AOFAS score, 90 days after the surgery.

Patients were asked to take images in the immediate postoperative period as reference and assessment of likely future loss of reduction. We considered definite X-ray results the anterior-posterior, 20°-internal rotation anterior-posterior and lateral images taken three months after the surgery or later. In the X-ray assessment, we took as reference the Burwell and Charnley's reduction criteria. Minimal follow-up was 12 months (ranging from 6 to 18).

### Results

All of the patients had AO type B1 fractures. No patient suffered open fracture. Although all fractures were displaced fractures, no patient suffered joint dislocation. In all cases, fractures were low-impact fractures.

Average time between the fracture and the surgery was 5.5 days (ranging from 2 to 14). Average body mass index was 29.69 (ranging from 22.22 to 37.98).

Eighty-five point seven percent of the patients were operated on by reduction and internal fixation using the MIS technique, whereas 14.3 % received the conventional ORIF technique (Figure 1).

All of the patients were allowed immediate weight loading as tolerated, with 90° protection. Weight loading protected with walker boot was allowed, on average, two days after the surgery (ranging from 1 to 6) (Figure 2). In our small population, weight loading time in patients operated on conventionally and patients operated on using the MIS technique did not differ.

Ankle AOFAS score recorded three month after the surgery was, on average, 99 (ranging from 90 to 100). Patients were back to work, on average, 2.1 months after the

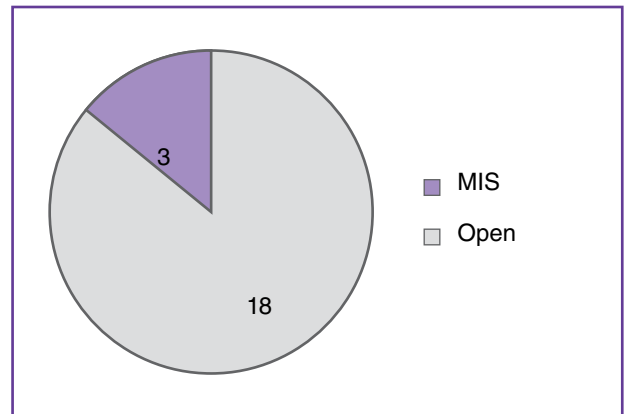


Figure 1. Open surgery vs. surgery using the MIS technique.

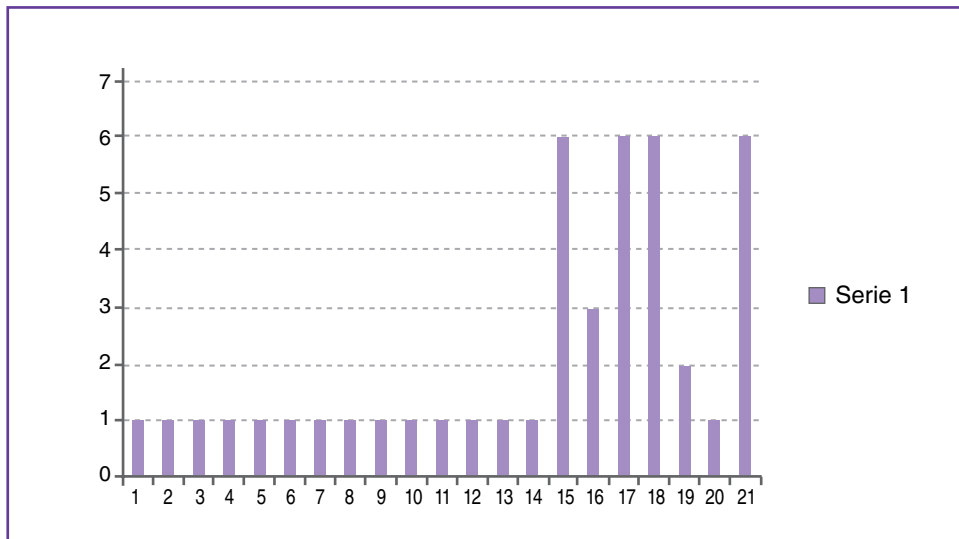
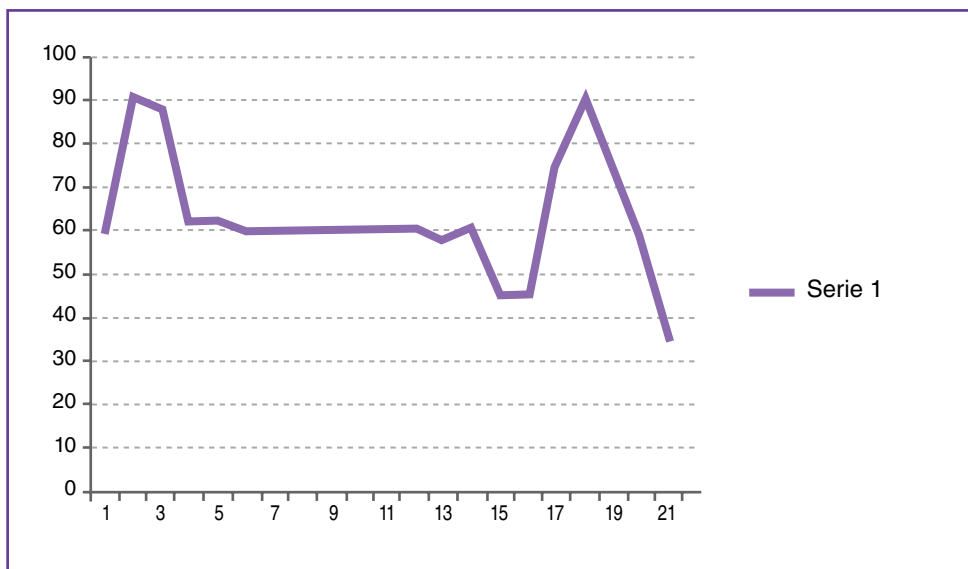


Figure 2. Patients' weight loading, in days.



▲ **Figure 3.** Return to work, in postoperative days.

surgery (ranging from 1 to 3) (Figure 3) and back to sports 2.95 months after the surgery (ranging from 2 to 4).

Taking as reference the Burwell y Charnley's reduction criteria, anatomic reduction was achieved in all cases, as recorded in the immediate postoperative images. In the 90-day postoperative follow-up and later, and with complete fracture healing, reduction did not suffer secondary displacement in spite of early weight loading. This was assessed in the X-rays taken more than three months after the surgery.

## Discussion

Among lower limb fractures, ankle fractures are the more frequently treated by orthopedists.<sup>18,25</sup> The treatment goal, as in every joint fracture, is to achieve anatomic reduction and early functional recovery.<sup>14,26,27</sup>

Postoperative management of internal fixation of ankle fractures is still controversial. Nowadays it is widely acknowledged that early motion following internal fixation is beneficial to decreasing cast disease.<sup>28-30</sup>

Early weight loading and protection with a plastic walker boot facilitated recovery of the injured joint range of motion (ROM), decreased swelling and soft tissues atrophy, and avoided osteoporosis development.<sup>31-34</sup> As seen in Jarvinen and Nash's works,<sup>31-34</sup> in our series, we saw that patients treated this way are soon back to work and sports, with good function and a very low complications rate.

Sondenaa et al.<sup>35</sup> compared two protocols of immobilization in ankle fractures. Half of the patients did active-principle exercises and used a removable splint, whereas the other half were not allowed to do exercise. The second

group showed a temporary increase in pain, swelling and ROM reduction, what seems to justify the ASIF principle of early motion.

Ahl et al.<sup>36,37</sup> assessed early and late weight loading in ankle fractures. They concluded that early weight loading protected with under-the-knee immobilization is safe, but it may cause infection in the superficial surgical wound. They advised starting weight loading after the first surgical wound dressing.

Lehtonen et al.<sup>38</sup> reported an unacceptably high rate (66%) of complications of the surgical wound on the first day of immediate postoperative motion. Sondenaa et al.<sup>31</sup> had a case of soft tissues infection in patients treated with early motion. In our series, no patient suffered complications in the surgical wound by receiving immediate motion and weight loading protected with a walker boot. This may stem from the fact that most patients in the series were operated on using the MIS technique.

Shah et al.<sup>39</sup> evaluated 69 patients with ankle fractures. Fifty percent showed remaining pain, 63%, stiffness, and 45%, ankle swelling five years after the surgery. In our study, two patients showed remaining pain, but mainly related to the osteosynthesis material, that is why this was removed four and six month, respectively, after the surgery. We believe that good medical evolution three months after the surgery (with high AOFAS scores) is related to early postoperative exercise and weight loading.

In their series, Lehtonen et al.<sup>38</sup> reported two cases of deep venous thrombosis. In our analysis, we did not detect such cases.

DiStasio et al.<sup>40</sup> reported that patients subject to early motion were back to work in 5.8 months. Our patients were back to work, on average, two months after the surgery.

## Conclusions

Although there is little literature about immediate postoperative weight loading in ankle fractures, and our analysis is based on a low number of patients, in view of our results, we can infer that: 1) patients with AO type

B1 low-impact fractures, treated by reduction and osteosynthesis, can do early weight loading with no risk of secondary displacement; 2) early weight loading along with early motion lead to very good outcomes, allowing that patients are soon back to work and sports; 3) early weight loading does not determine higher complications rates.

## Bibliography

1. Goh J, Mech A, EngHing L, Ang E, Bayon P, Pho R. Biomechanical study on the load-bearing characteristics of the fibula and the effects of fibular resection. *Clin Orthop* 1992; 279: 223-8.
2. Scranton P, Mc Master J, Kelly E. Dynamic fibular function. A new concept. *Clin Orthop Relat Res* 1976;118:76.
3. Wang Q, Whittle M, Cunningham J, Kenwright J. Fibula and its ligaments in load transmission and ankle joint stability. *Clin Orthop Relat Res* 1996;330:261-70.
4. Weiner C, Mc Master J, Ferguson R. Dynamic function of the human fibula. *Am J Anat* 1969;138:145-50.
5. Karrholm J, Hansson L, Selvik G. Mobility of the lateral malleolus: A roentgen stereophotogrammetric study. *Acta Orthop Scand* 1985;56:479-83.
6. Lofvenberg R, Karrholm J, Selvik G. Fibular mobility in chronic lateral instability of the ankle. *Foot Ankle* 1990;11:22-9.
7. Segal D, Wiss D, Whitelaw G. Functional bracing and rehabilitation of ankle fractures. *Clin Orthop* 1985;199:39-45.
8. Lambert K. The weight-bearing function of the fibula. A strain gauge study. *J Bone Joint Surg Am* 1971;53(3):507-13.
9. Skraba J, Greenwald A. The role of the interosseous membrane on tibiofibular weightbearing. *Foot Ankle* 1984;4:301-4.
10. Takabe K, Nakagawa A, Minami H, Kanazawa H, Hirohata K. Role of the fibula in weight-bearing. *Clin Orthop* 1984;184:289-92.
11. Hughes J, Weber H, Willenegger H, Kuner E. Evaluation of ankle fractures: non-operative and operative treatment. *Clin Orthop Rel Res* 1979;138:111-9.
12. Milner B, Mercer D. Bicortical screw fixation of distal fibula fractures with a lateral plate: An anatomic and biomechanical study of a new technique. *J Foot Ankle Surg* 2007; 46(5):341-7.
13. Minihane K, Lee C, Ahn C. Comparison of lateral locking plate and antiglide plate for fixation of distal fibular fractures in osteoporotic bone. A biomechanical study. *J Orthop Trauma* 2006;20(8):562-6.
14. Stufkens S, Van den Bekerom M, Kerkhoffs G. Long term outcome after 1822 operatively treated ankle fractures: A systematic review of the literature. *Injury* 2011;42:119-27.
15. Yablon IG, Heller FG, Shouse L. The key role of the lateral malleolus in displaced fractures of the ankle. *J Bone Joint Surg Am* 1977;59:169-73.
16. Schatzer J, Tile M. *The role of operative fracture care*, New York: Springer Verlag; 1987.
17. Van Laarhoven C, Meeuwis J, Van der Werken C. Postoperative treatment of internally fixed ankle fractures: a prospective randomised study. *J Bone Joint Surg Br* 1996;78(3):395-9.
18. Yañez Arauz JM. Osteosíntesis mínimamente invasiva en fracturas del peroné distal. *Rev Asoc Argent Ortop Traumatol* 2005;70(2):136-45.
19. Yañez Arauz JM. Osteosíntesis mínimamente invasiva del maléolo peroneo. *Flamecipp* 2012;(2):N137-46.
- 20.- Bloomstein L, Schenk R, Grob P. Percutaneous plating of periarticular tibial fractures: a reliable, reproducible technique for controlling plate passage and positioning. *J Orthop Trauma* 2008;22(8):566-71.
21. Collinge C, Sanders R, DiPasquale T. Treatment of complex tibial periarticular fractures using percutaneous techniques. *Clin Orthop Relat Res* 2000;375:69-77.
22. Ozkaya U, Parmaksizoglu A, Gul M. Minimally invasive treatment of distal tibial fractures with locking and non locking plates. *Foot Ankle Int* 2009;30(12):1161-7.
23. Ruedi TP, Buckley RE, Morgan CG. *AO Principles of Fracture Management*, 2<sup>nd</sup> ed. AO Foundation Publishing; 2007.
24. Tornkvist H, Hearn TC, Schatzker J. The strength of plate fixation in relation to number and spacing of bone screws. *J Orthop Trauma* 1996;10(3):204-8.
25. Bauer M, Bengner U, Johnell O, Redlund-Johnell I. Supination-eversion fractures of the ankle joint: changes in incidence over 30 years. *Foot Ankle* 1987;8(1):26-8.

26. Chapman MW. Fracture and fracture dislocation of the ankle. En: Mann RA, Coughlin MJ (eds). *Surgery of the foot and ankle*, 6<sup>th</sup> ed. St Louis: Mosby; 1993:1464-1493.
27. Muller M, Allgower M, Schneider R, Willenegger H. *Manual of internal fixation, techniques recommended by the AO Group*, 3<sup>rd</sup> ed. New York: Springer Verlag; 1991.
28. Muller M, Allgower M, Schneider R, Willenegger H. *Manual der Osteosynthesen, AO-Technique*, Berlin: Springer Verlag; 1969.
29. Ramsey PL, Hamilton W. Changes in tibiotalar area of contact caused by lateral talar shift. *J Bone Joint Surg Am* 1976;58(3):356-7.
30. Stuart P, Brumby C, Smith S. Comparative study of functional bracing and plaster cast treatment of stable lateral malleolar fracture. *Injury* 1989;20:323-6.
31. Jarvinen M, Kannus P. Current concepts review. Injury of an extremity as a risk factor for the developing of osteoporosis. *J Bone Joint Surg Am* 1997;79:263-76.
32. Kalish S, Pelcovitz N, Zawada S, Donatelli R, Wooden M, Castellano B. The Aircast Walking Brace versus conventional casting methods. A comparison study. *J Am Podiatr Med Assoc* 1987;77:589-95.
33. Mohtadi N. Commentary: Injured limbs recover better with early mobilisation and functional bracing than with cast immobilisation. *J Bone Joint Surg Am* 2005; 87:1167.
34. Nash C, Mickan S, Del Mar C, Glasziou P. Resting injured limbs delays recover: A systematic review. *J Fam Pract* 2004;53:706-12.
35. Sondenaa K, Hoigaard U, Smith D, Alho A. Immobilization of operated ankle fractures. *Acta Orthop Scand* 1986;57:59-61.
36. Ahl T, Dalen N, Holmberg S, Selvik C. Early weight bearing of displaced ankle fractures. *Acta Orthop Scand* 1987;58:535-8.
37. Ahl T, Dalen N, Holmberg S, Selvik C. Early weight bearing of malleolar fractures. *Acta Orthop Scand* 1986;57:526-9.
38. Lehtonen B, Jarvinen T, Honkonen S, Nyman M, Vihtonen K, Jarvinen M. Use of a cast compared with a functional ankle brace after operative treatment of an ankle fracture. A prospective, randomized study. *J Bone Joint Surg Am* 2003;85:205-11.
39. Shah NH, Sundaram RO, Velusamy A, Braithwaite IJ. Five year functional outcome analysis of ankle fracture fixation. *Injury* 2007;38:1308-12.
40. DiStasio A, Jaggars F, DePasquale L, Frassica F, Turen C. Protected early motion versus cast immobilization in postoperative management of ankle fractures. *Contemp Orthop* 1994;29(4):73-7.