

Case Resolution

Juan Ignacio Pérez Abdala, Tomás Scarpaci, José I. Albergo, Germán Farfalli, Luis Aponte Tinao

Instituto de Ortopedia y Traumatología "Carlos E. Ottolenghi", Hospital Italiano de Buenos Aires, Autonomous City of Buenos Aires, Argentina.

Case presentation on page 3.

Stress Fracture as a Differential Diagnosis for Bone Sarcomas

ABSTRACT

Stress fractures require a thorough evaluation to differentiate them from neoplastic processes. This evaluation includes medical history, physical examination, and diagnostic studies. A diagnostic algorithm is proposed.

Keywords: Stress fracture; biopsy; bone sarcoma.

Level of Evidence: IV

Fractura por estrés como diagnóstico diferencial de sarcomas óseos

RESUMEN

Las fracturas por estrés requieren una evaluación exhaustiva para distinguirlas de procesos neoplásicos. Esta incluye la anamnesis, el examen físico y los estudios complementarios. Se propone un algoritmo diagnóstico.

Palabras clave: Fractura por estrés; biopsia; sarcoma óseo.

Nivel de Evidencia: IV

DIAGNOSIS: Stress fracture of the left femoral diaphysis.

DISCUSSION

Based on the findings in the imaging studies described above, a core needle biopsy of the lesion was performed under CT guidance (Figure 4).

The histopathological analysis revealed compact bone with marked signs of remodeling, without evidence of cellular atypia (Figure 5).

After ruling out a neoplastic process and confirming a stress fracture, partial weight-bearing was maintained, and a consultation with Endocrinology was requested to evaluate possible metabolic causes. Laboratory tests and bone densitometry were performed, and metabolic disorders were ruled out.

After four weeks of partial weight-bearing, the patient reported no pain, allowing for full weight-bearing. Follow-up radiographs showed no changes compared to previous imaging. At six-month and one-year follow-ups, the patient remained asymptomatic and was able to perform daily activities and sports without restrictions.

A stress fracture results from cyclic and repetitive mechanical overload that prevents adequate bone remodeling in a metabolically healthy bone. Repeated loading below the bone's maximum resistance threshold leads to microfractures without sufficient time for repair.^{1,2} It is crucial to differentiate stress fractures from pathological fractures, where tumor tissue replaces healthy bone and alters its strength, and from insufficiency fractures, where bone architecture is weakened, leading to reduced bone quality.¹⁻³ In both cases, fractures can occur with

Received on October 19th, 2024. Accepted after evaluation on January 2nd, 2025 • Dr. JUAN IGNACIO PÉREZ ABDALA • ignacio.perez@hospitalitaliano.org.ar  <https://orcid.org/0000-0002-5398-6876>

How to cite this article: Pérez Abdala JI, Scarpaci T, Albergo JI, Farfalli G, Aponte Tinao L. Postgraduate Orthopedic Instruction - Imaging. Case Resolution. *Rev Asoc Argent Ortop Traumatol* 2025;90(1):103-108. <https://doi.org/10.15417/issn.1852-7434.2025.90.1.2052>

physiological loads or very low-energy trauma. The classic triad of a stress fracture includes a new activity or a modification in activity, increased intensity, and repetitive loading, leading to symptom onset—criteria that our patient meets.³

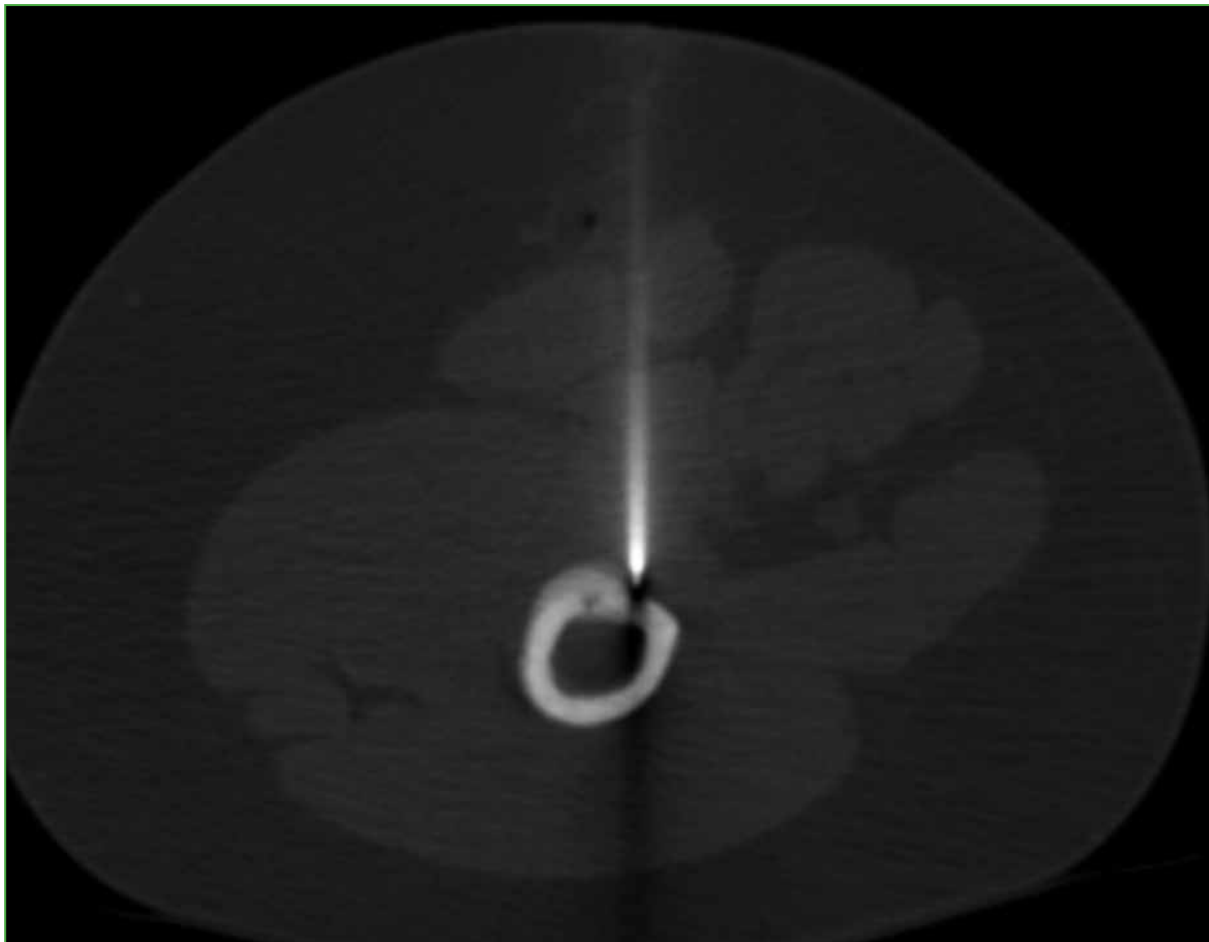


Figure 4. Computed tomography of the left femur, axial view. The site of the bone biopsy is observed in the area of cortical thickening.

The location of stress fractures depends on the type of activity performed and specific anatomical characteristics. The femoral diaphysis is considered a low-risk site for stress fractures, and metabolic factors should always be evaluated (Table 1).¹

Diagnosis is based on medical history, physical examination, and complementary studies, including imaging and, if necessary, histopathological analysis. Regarding medical history, it is essential to evaluate symptom duration, the type and intensity of physical activity, changes in activity frequency, pain characteristics, load tolerance, and the presence of nocturnal pain. Initially, pain occurs only during activity, but as the mechanical stress progresses, it may persist at rest and even become nocturnal. Additionally, metabolic, hormonal, and nutritional factors should be assessed, as they may influence bone metabolism.⁴

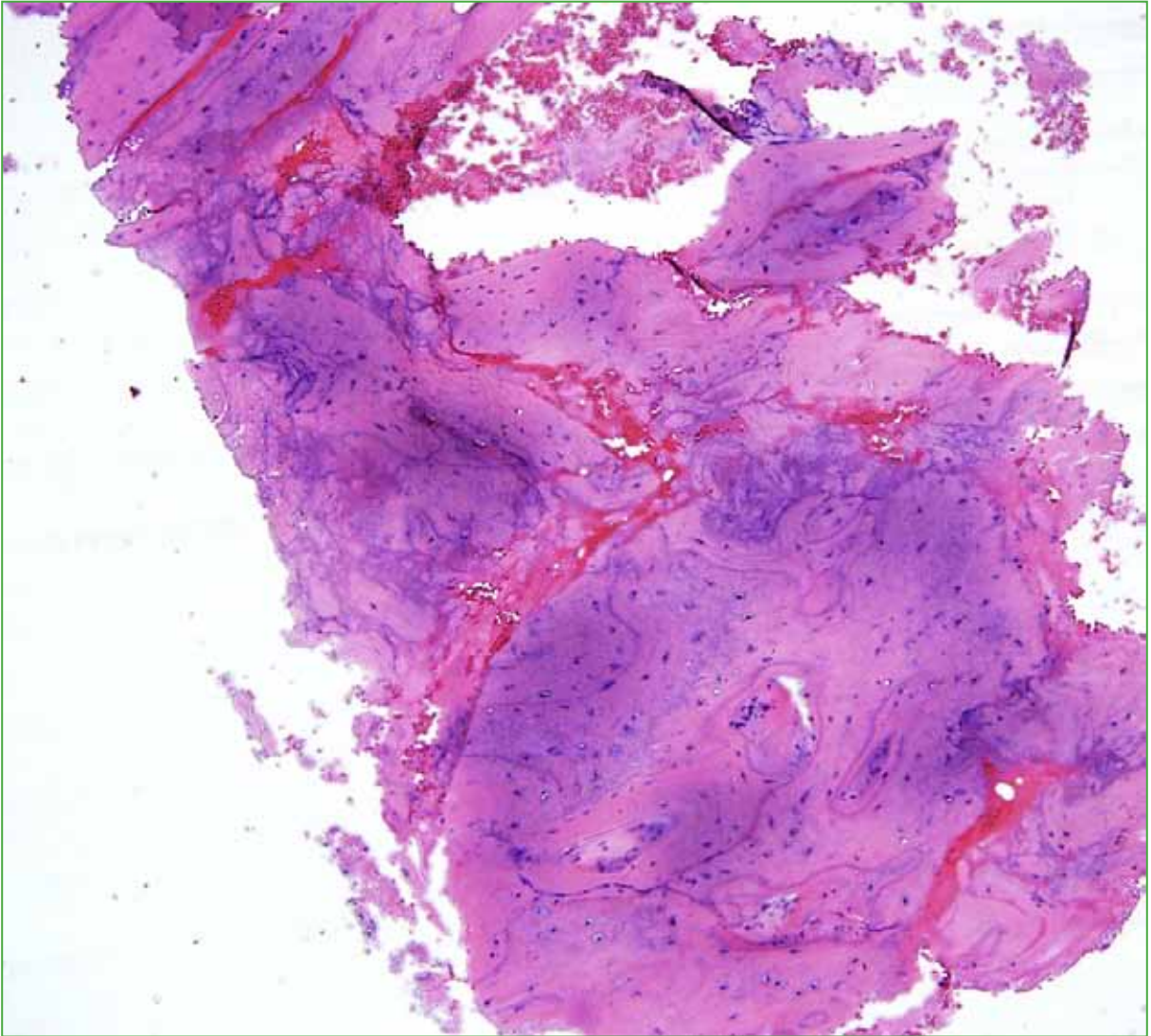


Figure 5. Pathological anatomy specimen. Bone tissue with signs of remodeling is observed, without atypical cells or cellular pleomorphisms. These signs are interpreted as fracture repair. Hematoxylin-eosin stain, magnification in x10 field.

Physical examination is often nonspecific. Patients typically present with localized tenderness and pain, with painful full-range or limited mobility. In chronic cases, there may be localized swelling, increased temperature, or a palpable mass.

Treatment includes reducing mechanical load, pain management, physiotherapy to optimize biomechanics, and evaluation of phosphocalcic metabolism. The time required for bone healing depends on fracture location and severity, requiring clinical and imaging follow-up.

To prevent recurrence, biomechanical and environmental factors should be optimized, including activity type and frequency, skeletal alignment, footwear, and nutritional habits.

Table 1. Typical locations of stress fracture sites by type of activity.

Location of fracture site	Type of activity
Ulna/coronoid	Throwing
Humerus-distal diaphysis	Throwing
Ribs	Golf, carrying heavy items
Cervical spine	<i>Lacrosse</i>
Lumbar spine	Lifting, ballet
Obturator foramen	Gymnastics, <i>bowling</i>
Neck and femoral diaphysis	Ballet, running
Distal fibula	Running
Proximal fibula	Jumping
Tibia	Running
Calcaneus	Jumping
Navicular	Running
Metatarsal diaphyses	Walking

It is essential to distinguish stress fractures from neoplastic processes, often referred to as tumor-like lesions.⁵ Although radiographs may show features suggestive of a stress fracture, detection is not always straightforward, and additional imaging may be required (Table 2). Necessary diagnostic imaging methods may include:

- Radiographs: The initial imaging modality. Early stress fractures may not be visible on radiographs, with changes appearing between the second and fourth week after symptom onset. Findings may include cortical thickening, benign periosteal reaction, a cortical radiolucent line, or medullary sclerosis during the repair process.
- CT: Depending on the stage of the fracture, CT can show focal cortical thickening, benign periosteal reaction, and a hypodense line perpendicular to the cortical axis, surrounded by reparative bone tissue, in up to 79% of cases.⁶ Soft tissue edema may also be seen. Unlike tumor lesions, stress fractures do not present with endosteal thinning, medullary involvement, pathological calcifications, permeative or punched-out cortical destruction, soft tissue involvement, malignant periosteal reactions (e.g., sunburst pattern, Codman's triangle, or onion skin periosteal reaction), or hypodense cortical lesions like *nidus*. Contrast-enhanced CT can highlight hyperemic tissue, although it is not routinely used.
- MRI: The most sensitive and specific imaging modality for diagnosing stress fractures. In early stages, MRI reveals bone marrow and periosteal edema, often with adjacent soft tissue edema. T2 or STIR sequences typically show an increased medullary signal, which is nonspecific. T1-weighted sequences provide better definition, distinguishing circumscribed hypointensity in neoplastic lesions (due to tumor components) from the diffuse hypointensity seen in stress fractures (due to edema). Contrast enhancement can help differentiate neoplastic lesions by outlining the inflammatory component and highlighting the tumor mass. As the fracture progresses, cortical thickening develops, and in advanced cases, a hypointense fracture line may be visible on T1 or T2 sequences, although bony changes are best visualized on CT. Bone marrow edema may persist for up to six months after symptom resolution due to ongoing bone remodeling.

- Bone scintigraphy: Detects areas of increased metabolic activity. It is highly sensitive but nonspecific. Stress fractures typically exhibit linear or localized hyperuptake, whereas neoplastic lesions show diffuse hyperuptake, but these patterns are not specific. Bone scintigraphy has been largely replaced by MRI.
- Positron Emission Tomography (PET-CT): Combines metabolic activity detection with improved anatomical precision compared to scintigraphy, though it is more costly and involves higher radiation exposure. Stress fractures tend to show linear or localized uptake, while neoplastic processes display diffuse uptake, although these patterns are not specific.

Table 2. Characteristics of stress fractures and neoplastic processes in imaging studies.

Imaging study	Stress fracture	Tumor lesion
Radiography	Cortical thickening Benign periosteal reaction Cortical radiolucent line Spinal cord sclerosis (reparative sign)	Endostic irregularity Malignant periosteal reaction Radiopaque “shadow” in soft tissues Alteration of medullary morphology
Computed tomography	Cortical thickening Benign periosteal reaction (formation of bony callus) Cortical hypodense line (fracture line)	Endosteal scalloping Malignant periosteal reaction Destructive cortical pattern Soft tissue and spinal cord involvement Calcification
Magnetic resonance imaging	Medullary, periosteal and soft tissue edema. Poorly defined medullary hypointensity in T1 sequence Cortical thickening Hypointense line in T1 sequence (fracture line).	Medullary, periosteal and soft tissue edema. Well-defined medullary hypointensity in T1 sequence (tumor component). Extension to soft tissues Signal heterogeneity due to liquid, hemorrhagic, necrotic or solid component
Bone scintigraphy	Focal or linear hyperuptake	Diffuse hyperuptake
Positron emission tomography	Focal or linear hyperuptake	Diffuse hyperuptake

Awareness of stress fractures and their clinical and imaging characteristics is essential for accurate diagnosis. As a diagnostic approach, we propose performing a detailed medical history and physical examination. If a stress fracture is suspected, we obtain a radiograph of the entire affected bone. If radiographic findings suggest a stress fracture, we proceed with CT and MRI. If radiographs are inconclusive, we request an MRI. If uncertainty remains after imaging, we perform a core needle biopsy to assess for atypical cells. If clinical suspicion persists despite negative imaging, we consider bone scintigraphy to assess hyperuptake and, if it is negative, we rule out a stress fracture. If it is positive, we proceed with a core needle biopsy for definitive diagnosis (Figure 6)

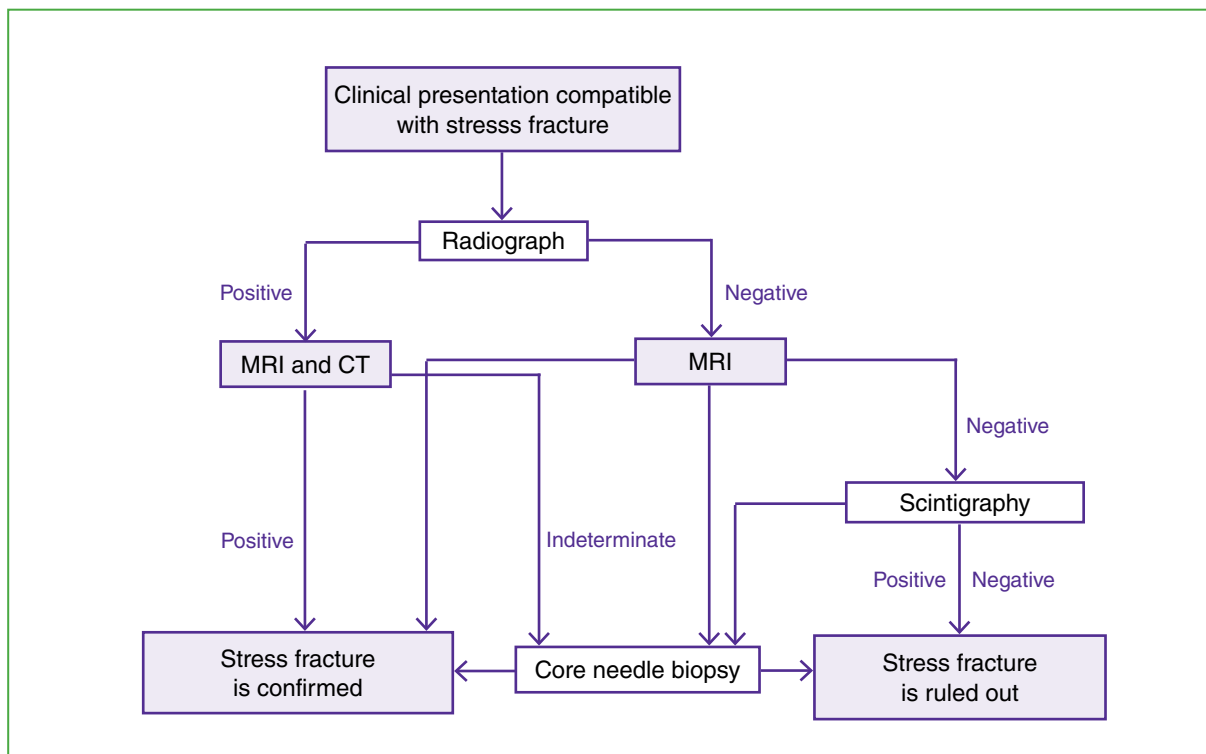


Figure 6. Diagnostic algorithm for suspected stress fracture. MRI = magnetic resonance imaging; CT = computed tomography

T. Scarpaci ORCID ID: <https://orcid.org/0009-0000-2404-5527>
 J. I. Albergó ORCID ID: <https://orcid.org/0000-0002-7175-6812>

G. Farfalli ORCID ID: <https://orcid.org/0000-0001-7986-2989>
 L. Aponte Tinao ORCID ID: <https://orcid.org/0000-0002-2096-7206>

REFERENCES

- Costa Astur D, Zanatta F, Gonçalves Arliani G, Ramalho Moraes E, de Castro Pochini A, Ejnisman B. Stress fractures: definition, diagnosis and treatment. *Rev Bras Ortop* 2015;51(1):3-10. <https://doi.org/10.1016/j.rboe.2015.12.008>
- Fayad LM, Kamel IR, Kawamoto S, Bluemke DA, Frassica FJ, Fishman EK. Distinguishing stress fractures from pathologic fractures: a multimodality approach. *Skeletal Radiol* 2005;34(5):245-9. <https://doi.org/10.1007/s00256-004-0872-9>
- Krych A, Odland A, Rose P, Dahm D, Levy B, Wenger D, et al. Oncologic conditions that simulate common sports injuries. *J Am Acad Orthop Surg* 2014;22:223-4. <https://doi.org/10.5435/JAAOS-22-04-223>
- Coria HE, Fedún Rodríguez E, García D, Masaragian H, Mizdraji L, Perin F, et al. Fracturas de tibia por estrés y hallazgos patológicos asociados en reclutas. *Rev Asoc Argent Ortop Traumatol* 2024;89(2):143-9. <https://doi.org/10.15417/issn.1852-7434.2024.89.2.1868>
- Raymond AK, Jaffe N. Conditions that mimic osteosarcoma. *Cancer Treat Res* 2009;152:85-121. https://doi.org/10.1007/978-1-4419-0284-9_5
- Fottner A, Baur-Melnyk A, Birkenmaier C, Jansson V, Dürr HR. Stress fractures presenting as tumours: a retrospective analysis of 22 cases. *Int Orthop* 2009;33(2):489-92. <https://doi.org/10.1007/s00264-007-0488-5>