

Arthroscopic Repair of the TFCC by Knotless Double-row Suture Anchoring and Early Mobilization: Preliminary Outcomes

Juan Matías Sala, Aldo D. Ledesma

Servicio de Cirugía de Mano Patagónica (CIMAP), OTI, Clínica del Valle S.R.L. Comodoro Rivadavia, Chubut, Argentina.

ABSTRACT

Objective: This study retrospectively evaluates the functional outcomes of patients with triangular fibrocartilage complex (TFCC) foveal injuries treated arthroscopically with knotless double-row suture anchor repair. **Materials and Methods:** Fourteen consecutive patients with Atzei type 2/3 TFCC foveal lesions were retrospectively analyzed. All were of working age and had an average follow-up of 15 months. Arthroscopic repair was performed using a knotless double-row suture anchor repair with monotonnel foveal anchorage. One suture fixed the volar radioulnar ligament, while the other secured the dorsal radioulnar ligament to the fovea. Outcomes assessed included range of motion (ROM), grip strength, the Mayo Wrist Score, and the Disabilities of the Arm, Shoulder, and Hand (DASH) score. **Results:** Improvements in pain and strength were observed. The Mayo Wrist Score results were rated as excellent or good. The average DASH score improved from 62 preoperatively to 8 postoperatively. Comparative grip strength was 80% of the contralateral side. **Conclusions:** Arthroscopic repair of Atzei type 2/3 lesions using a double-row suture anchor repair with monotonnel ligament anchorage yields good outcomes, improving ROM, restoring stability, and achieving partial or total recovery of strength. Careful attention should be given to suture passage through the TFCC and screw fixation in the metaphysis to minimize complications.

Keywords: Wrist arthroscopy; triangular fibrocartilage complex; TFCC isometric anchorage; radioulnar instability.

Level of Evidence: IV

Resultados del tratamiento artroscópico de lesiones foveales del complejo del fibrocartilago triangular mediante doble sutura isométrica sin nudo

RESUMEN

Objetivo: Evaluar, en forma retrospectiva, la función y los resultados de los pacientes con una lesión foveal del complejo del fibrocartilago triangular tratados con un anclaje óseo isométrico con doble sutura ligamentaria, monotúnel, por vía artroscópica.

Materiales y Métodos: Se evaluó a 14 pacientes consecutivos, en edad laboral, que tenían una lesión foveal del complejo del fibrocartilago triangular Atzei 2/3 y un seguimiento promedio de 15 meses. Todas las lesiones se repararon mediante artroscopia con una doble sutura ligamentaria, isométrica, sin nudo con anclaje foveal monotúnel. Se utilizó una sutura para fijar el ligamento radiocubital volar y otra para fijar el ligamento radiocubital dorsal a la fovea. Se evaluaron el rango de movilidad, la fuerza de agarre, y se utilizaron el *Mayo Wrist Score* y el puntaje DASH. **Resultados:** Los puntajes de dolor y fuerza mejoraron. El *Mayo Wrist Score* fue excelente y bueno. El puntaje DASH preoperatorio era de 62 y de 8 en el posoperatorio. El promedio de la fuerza comparativa contralateral fue del 80%. **Conclusiones:** La reparación artroscópica de las lesiones Atzei 2/3 mediante doble sutura isométrica con anclaje ligamentario monotúnel, sin nudo logra buenos resultados: mejora el rango de movilidad, recupera la estabilidad y la fuerza en forma total o parcial. Se debe tener cuidado en el pasaje de las suturas por el complejo del fibrocartilago triangular y la fijación mediante el tornillo en la metafisis para evitar las complicaciones comunicadas en esta serie.

Palabras clave: Artroscopia de muñeca; complejo del fibrocartilago triangular; anclaje isométrico; inestabilidad radiocubital distal.

Nivel de Evidencia: IV

Received on June 4th, 2024. Accepted after evaluation on October 2nd, 2024 • Dr. JUAN MATÍAS SALA • salajuanmatias@icloud.com  <https://orcid.org/0000-0001-5542-5004>

How to cite this article: Sala JM, Ledesma AD. Arthroscopic Repair of the TFCC by Knotless Double-row Suture Anchoring and Early Mobilization: Preliminary Outcomes. *Rev Asoc Argent Ortop Traumatol* 2024;89(6):584-605. <https://doi.org/10.15417/issn.1852-7434.2024.89.6.1980>

INTRODUCTION

The triangular fibrocartilage complex (TFCC) primarily functions to stabilize the distal radioulnar joint (DRUJ) and to transmit and cushion the load of the hand to the wrist.

This complex is composed of the articular disc, the proximal and distal dorsal and palmar radioulnar ligaments, the ulnocarpal ligaments, and the extensor carpi ulnaris (ECU) subsheath. The articular disc is specifically responsible for load transmission and cushioning.¹

The stability of the DRUJ relies on the compression between articular surfaces and the tension generated during movement by the dorsal and volar radioulnar ligaments. These ligaments attach radially at the distal radius and deeply at the ulnar fovea. They originate from the ulnodorsal and ulnovolar angles of the distal radius, converging at the distal ulnar fovea, with some fibers extending to the ulnar styloid.¹

The DRUJ can be conceptualized as a “tensegrity” structure, where tension and compression work together to ensure proper joint function.¹

Secondary stabilizers of the DRUJ include the joint capsule, the posterior ulnar sheath, the deep head of the pronator quadratus, and the distal oblique band of the interosseous membrane.²

The TFCC has a rich vascular supply in its ulnar area, poor vascularity on its radial side, and no vascularization at the center of the disc.^{1,2} This complex is surrounded by fibrous structures that play a crucial role in rotational stability, load transmission, and force translation from the wrist to the forearm.²

TFCC injury is one of the most common causes of ulnar wrist pain, often limiting daily activities.^{1,3}

Palmer classified TFCC injuries into two types: traumatic (acute) and degenerative (chronic) (Table 1).¹⁻⁶

Table 1. Palmer’s classification for triangular fibrocartilage complex (TFCC) lesions.

Class 1	A. Central perforation B. Ulnar avulsion C. Avulsion of the ulnocarpal ligaments D. Radial avulsion
Class 2	TFCC central wear Central wear of the TFCC and chondromalacia of the lunate or ulnar head. Perforation of the TFCC and chondromalacia of the lunate or ulnar head. C plus perforation of the lunotriquetral ligament D plus ulnocarpal osteoarthritis

Acute injuries result from wrist trauma involving hyperextension, ulnar deviation, direct impact, or weight-bearing activities.^{1,3} Degenerative injuries are associated with repetitive axial loading and ulnar deviation, as well as poor healing of distal radius fractures.^{5,6}

Atzei and Luchetti modified the traditional “hammock” concept of the TFCC to an “iceberg” model. In this model, the superficial fibers represent the visible portion that tolerates and absorbs impact, while the deep fibers, responsible for stability, remain hidden. They expanded Palmer’s classification for 1B lesions, distinguishing between injuries to superficial and deep fibers and differentiating acute from chronic lesions (Table 2).^{1,3}

Wrist arthroscopy is the gold standard for diagnosing and treating TFCC injuries. The two most commonly used arthroscopic tests are the hook test for foveal lesions and the trampoline test for superficial lesions, both with sensitivity and specificity close to 90%.^{2,5}

Table 2. Atzei classification for Palmer's 1B lesions.

Class	DRUJ instability	TFCC Involvement		Healing potential of the TFCC	DRUJ cartilage condition	Treatment
		Distal	Proximal			
1 Distal repairable	Mild or negative	Torn	Healthy	Good	Good	Suture
2 Repairable foveal	Moderate or severe	Torn	Torn	Good	Good	Foveal repair
3 Distal and foveal repairable	Moderate or severe	Healthy	Torn	Good	Good	Foveal repair
4 Not repairable	Severe	Torn	Torn	Poor	Good	Reconstruction
5 DRUJ osteoarthritis	Moderate or severe	-	-	-	Poor	Salvage procedure

DRUJ = distal radio ulnar joint; TFCC = triangular fibrocartilage complex.

The preferred technique for treating unstable TFCC lesions involves reinsertion of the foveal fibers.

The aim of this study was to demonstrate that isometric, anatomic repair using the arthroscopically assisted monotunnel anchor technique yields favorable outcomes for TFCC Atzei 2/3 lesions.

MATERIALS AND METHODS

A retrospective study was conducted to evaluate outcomes in 14 adult patients with deep TFCC Atzei 2/3 lesions who underwent surgery between February 1, 2021, and December 31, 2022. Atzei 2 and 3 lesions are foveal TFCC injuries causing DRUJ instability.

Inclusion criteria were: age >18 years, no history of TFCC surgery or wrist arthroscopy, who had ulnar wrist border pain compatible with a TFCC injury limiting work, sport or daily activities; positive Berger, Ruby and Nakamura tests, Atzei 2/3 lesions confirmed by arthroscopy and a minimum postoperative follow-up of 6 months. In this study, the association or not of ulnar styloid fracture was not considered.

Exclusion criteria were: previous TFCC surgery, previous wrist arthroscopy, Palmer 2 degenerative TFCC lesions, and DRUJ osteoarthritis.

Fourteen patients (10 males and 4 females) with unstable foveal TFCC lesions were included. Twelve surgeries involved dominant wrists, while two involved non-dominant wrists.

Wrist range of motion in flexion, extension, and ulnar/radial deviation was measured using a standard PVS hand goniometer. Grip strength was evaluated with a Baseline-Orthowell® hydraulic joint dynamometer.

Pain was assessed using the visual analog scale (VAS) and functional outcomes were measured with the Mayo Clinic Wrist Score (MWS) and the Disabilities of Arm, Shoulder, and Hand (DASH) score.

The mean time from injury to surgery was 4 months (range: 6 weeks to 14 months). Postoperative follow-up ranged from 11 to 22 months (mean: 15 months).

The treatment protocol was as follows: During the first consultation for ulnar wrist pain, a detailed history of the trauma mechanism was obtained, followed by a clinical examination. Tests including Nakamura's, Waiter's, Ruby's, Berger's, and axial ulnocarpal compression in three wrist positions (compared to the contralateral side) were performed. Radiographs (anteroposterior and weight-bearing anteroposterior views) and MRI were requested.

For injuries confirmed by imaging within 6 weeks of occurrence, immobilization with a sugar-tong splint for 3 weeks was prescribed. Following immobilization, physiotherapy was initiated. If positive clinical signs persisted after rehabilitation, diagnostic and therapeutic wrist arthroscopy was performed. For injuries presenting more than 6 weeks after the trauma, surgical repair was directly indicated.

Surgical Technique

The procedure is performed under plexus block anesthesia with an ischemia-preventive cuff inflated to 250 mmHg. Standard portals 3-4 and 6R, along with an ulnar incision approximately 3 cm long and located 1.5 cm distal to the ulnar styloid tip, are routinely utilized.

First, the entire radiocarpal joint is explored. Subsequently, the trampoline and hook tests are conducted to assess TFCC lesions and classify them (Figures 1 and 2).

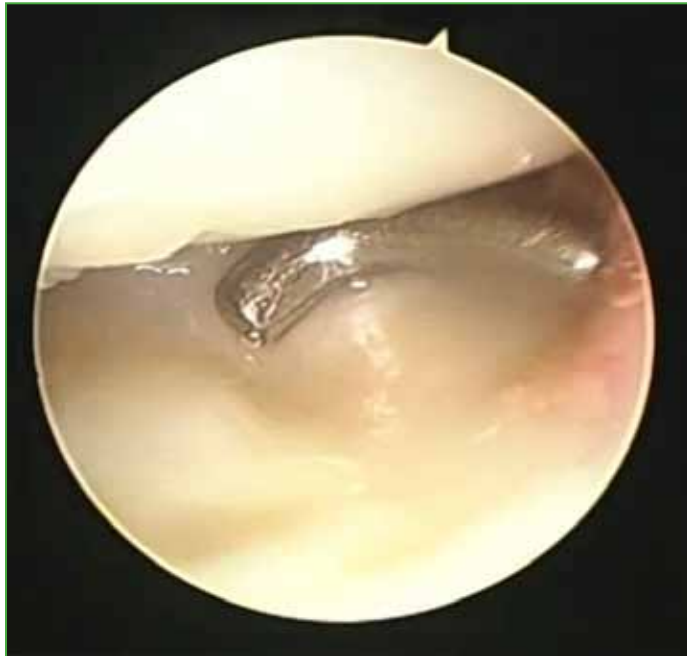


Figure 1. Trampoline test.

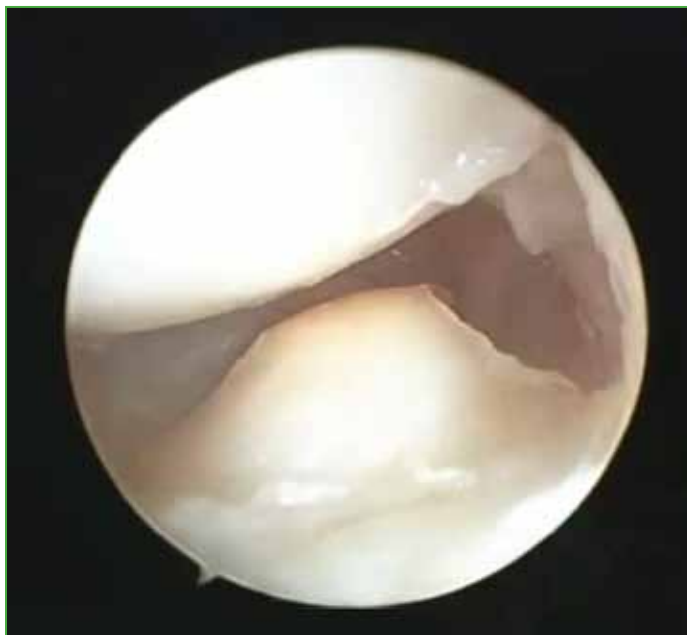

Figure 2. Hook test.

During the hook test, the probe is inserted through the 6R portal into the prestyloid recess. An attempt is made to elevate the articular disc. A negative test indicates failure to elevate the disc, while a positive test confirms successful elevation and indicates a foveal lesion of the deep radioulnar ligaments.

During the trampoline test, the probe is inserted through the 6R portal and pressed onto the articular disc to assess its tension. If the disc resists depression, the test is negative. Conversely, a positive test demonstrates depression of the disc, confirming a lesion of the superficial radioulnar ligaments.

Once a lesion is confirmed, synovectomy and debridement are performed. A TFCC guide is positioned externally at the ulnar site, entering through portal 6R, to create the ulnar tunnel in Matsumoto zone 2/2 (Figure 3).

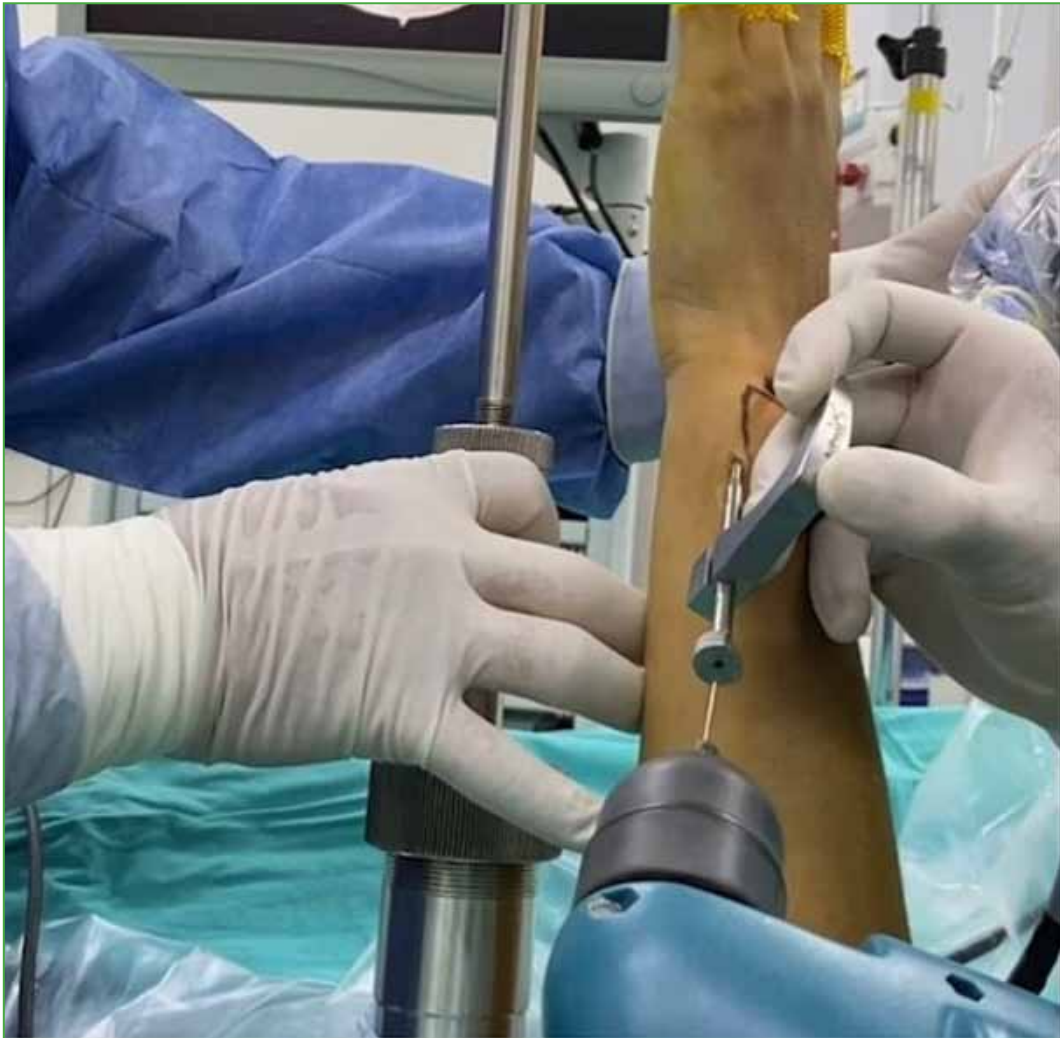

Figure 3. Placement of the triangular fibrocartilage complex guide through the 6R portal.

An ulnar incision, approximately 3 cm long, is made starting 1.5 cm distal to the ulnar styloid. This approach allows placement of the guide wire through portal 6R. Careful dissection is crucial to prevent injury to the ulnar sensory branch.

The guide is set at a 45° angle, 1.5 cm from the ulnar styloid, with an aperture for pin placement. Maintaining this angle and distance is essential to ensure the pin exits in the correct area of the ulna.

After proper alignment, a pin is inserted using a motor to create the ulnar tunnel. The pin penetrates the articular disc, confirming the tunnel's accurate positioning in Matsumoto zone 2.

Reaming of the bone tunnel is performed using a 3.5 mm guide with a reamer protector to prevent damage to the sensory branch of the ulnar nerve. Reaming is limited to the ulna and must avoid drilling through the articular disc to preserve its integrity for subsequent anchorage. After reaming, the guide, reamer, and initial pin are removed.

A suture passer with a 2.0 unbreakable suture (FiberWire®) is introduced through the ulnar tunnel, penetrating the volar radioulnar ligament in zone 1. The needle is inserted 2 mm dorsal to the ulnocarpal ligaments. One end of the suture is retrieved through portal 6R, while the other remains outside the ulnar tunnel (Figures 4-6).

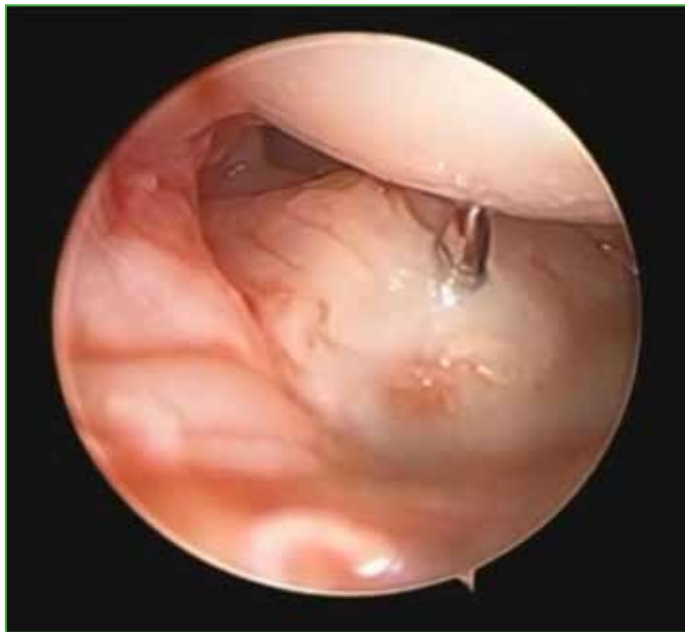

Figure 4. View of the pin in zone 2.

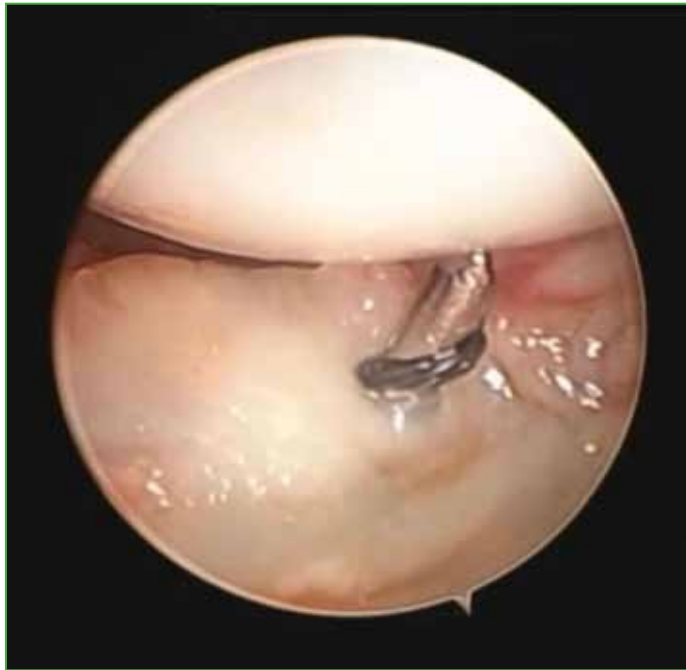

Figure 5. Suture pin insertion in Matsumoto zone 2.

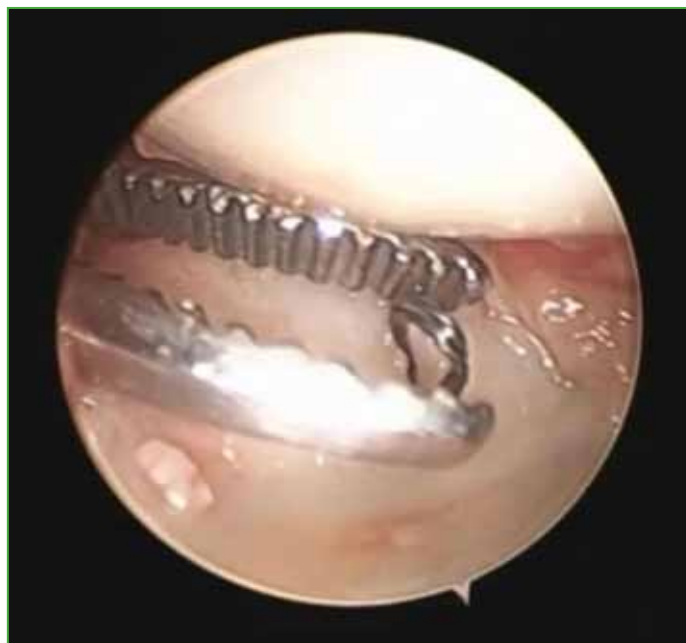

Figure 6. Retrieval of the thread through portal 6R.

A suture puller is then introduced through the ulnar tunnel, penetrating the volar radioulnar ligament in zone 3, with an insertion 2 mm dorsal to the ulnocarpal ligaments. The suture puller exits through portal 6R, creating a loop. The free end of the first suture is passed through this loop and gently pulled, securing it in the ulnar tunnel. This process tightens the fibrocartilage at the volar ligament margin (Figures 7-9).

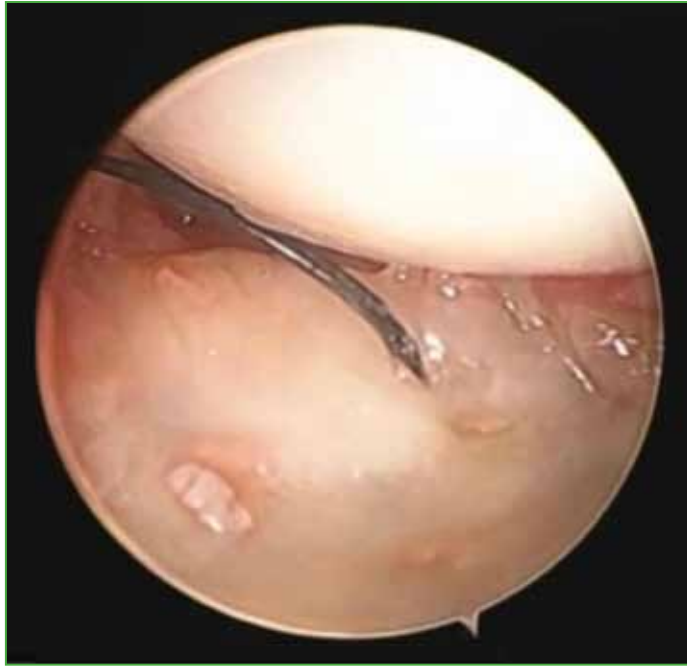

Figure 7. View from portal 3-4 of the suture passer thread retrieved through portal 6R.

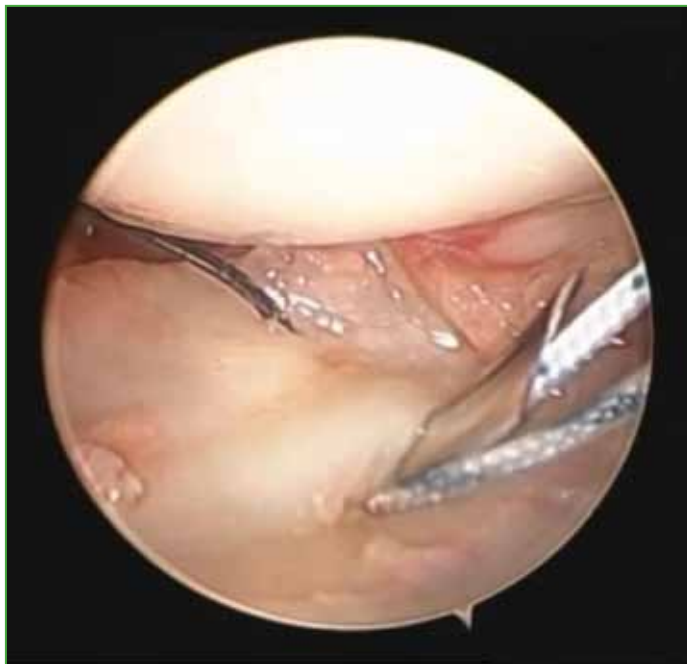

Figure 8. Needle with FiberWire® suture performing the volar radioulnar ligament.

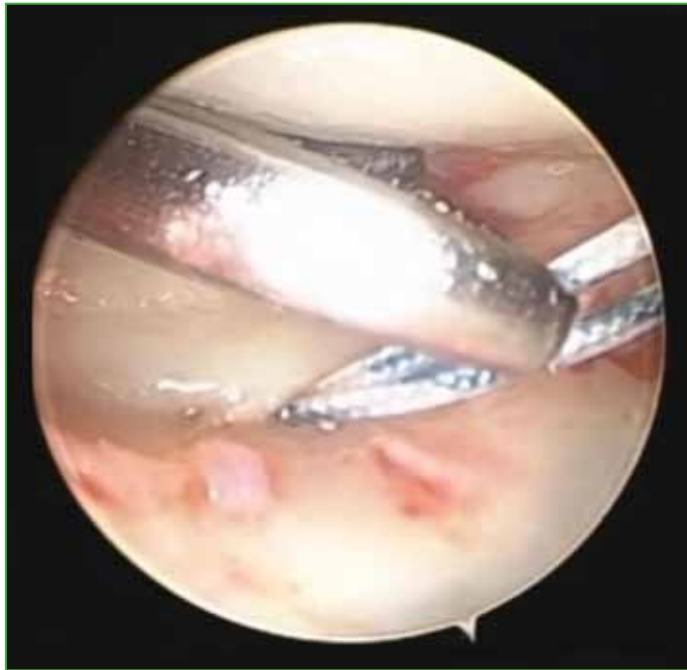

Figure 9. Retrieval of the FiberWire® suture through the 6R portal.

The approximate distance between the two perforations of the volar radioulnar ligament is 2 to 3 mm. The end of the suture that was retrieved through portal 6R is placed inside the loop of the suture retriever and gently pulled from the end of the suture retriever that was held outside the ulnar tunnel by visualization through portal 3-4. The free end that was through portal 6R is seen to descend through the traction of the suture retriever and is introduced into the ulnar hole by tightening the fibrocartilage at its volar ligamentous margin (Figures 10-13). In this way, a suture is obtained by tightening the volar radioulnar ligament with its two limbs through the ulnar tunnel and its ends outside it.

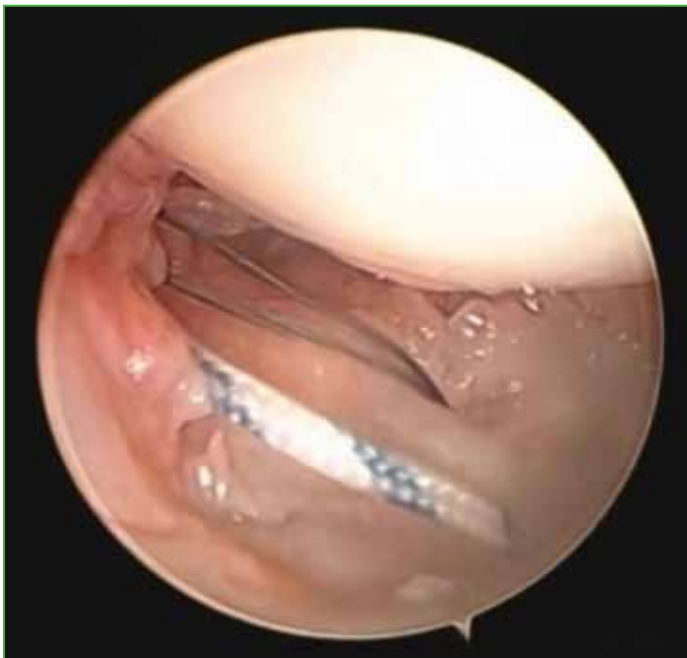

Figure 10. FiberWire® suture retrieved through the 6R portal.

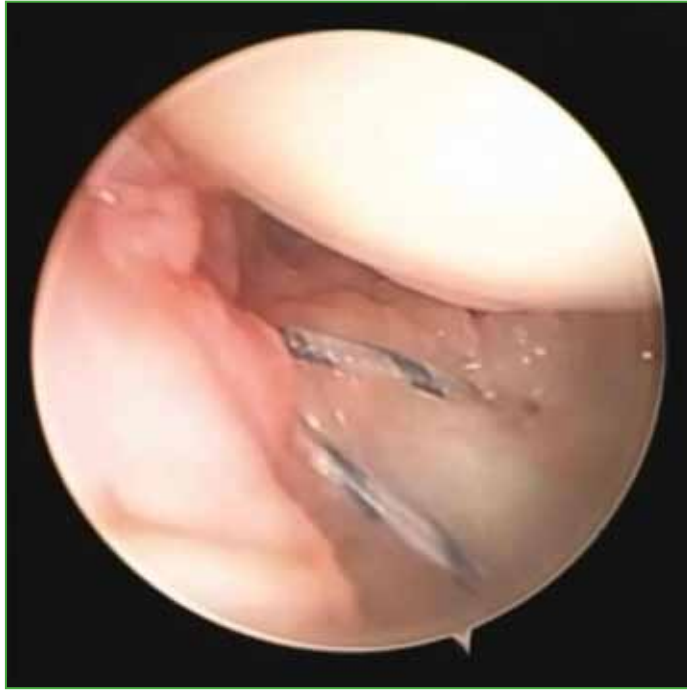

Figure 11. Passage of the FiberWire® suture through the ulnar tunnel using the suture retriever.

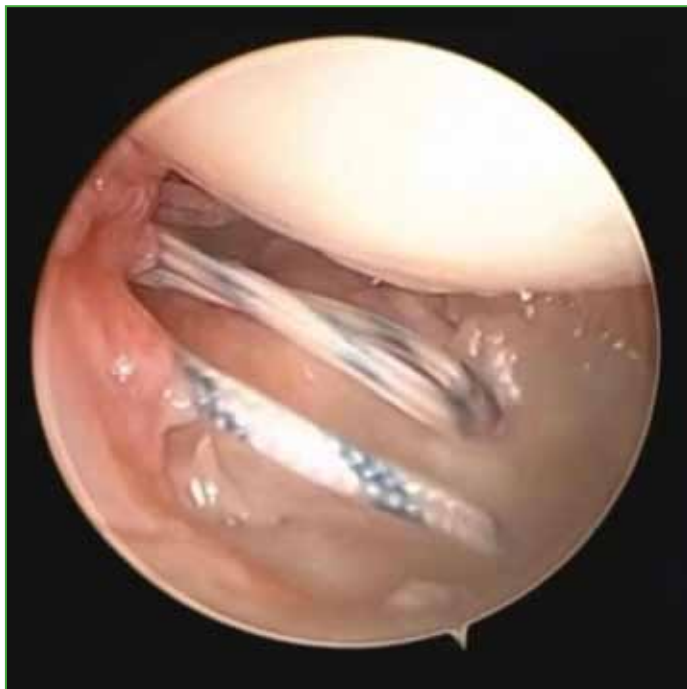

Figure 12. Suture retrieval through the ulnar tunnel, as seen through the 6R portal.

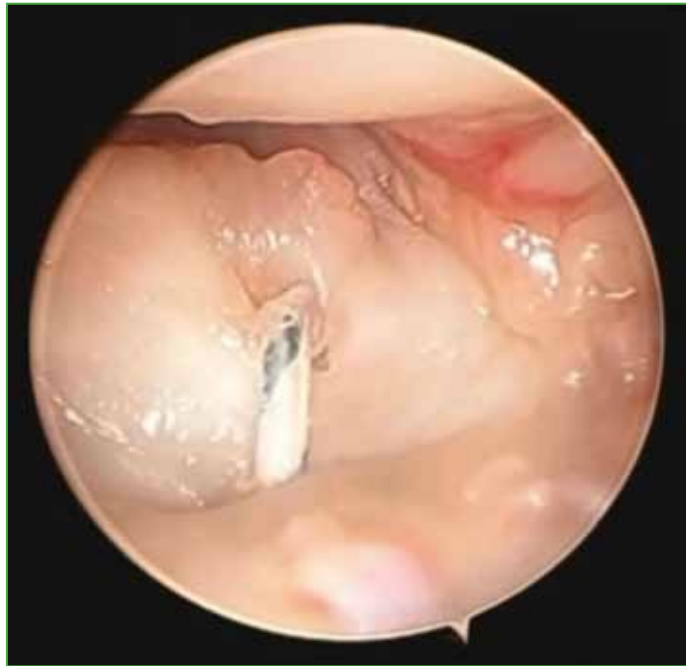

Figure 13. Tensioning of the volar radioulnar ligament, first suture, seen from portal 3-4.

Then, a suture passer with FiberWire® is used to penetrate the dorsal radioulnar ligament in zone 4, with insertion 2 mm volar to the dorsal capsule. The suture is retrieved through portal 6R and tightened through the ulnar tunnel (Figures 14-16).

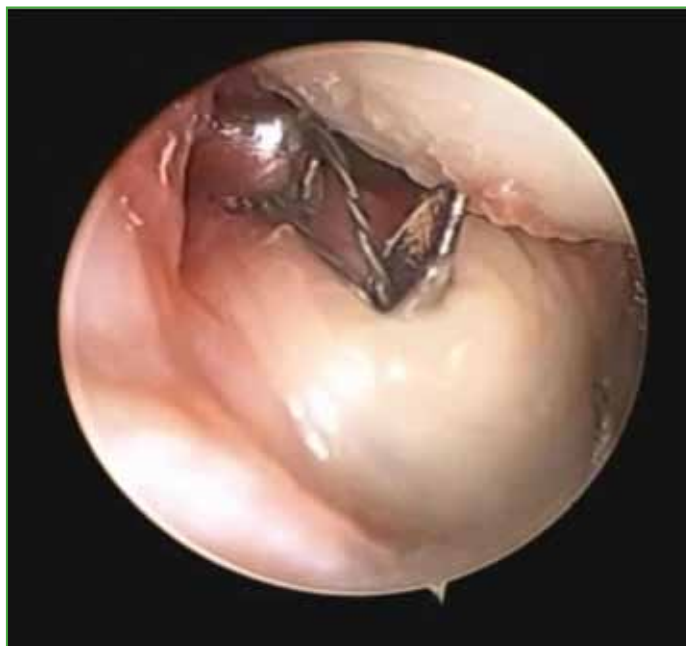

Figure 14. Second threaded pin through the ulnar tunnel. The dorsal radioulnar ligament is perforated, as seen from portal 3-4.

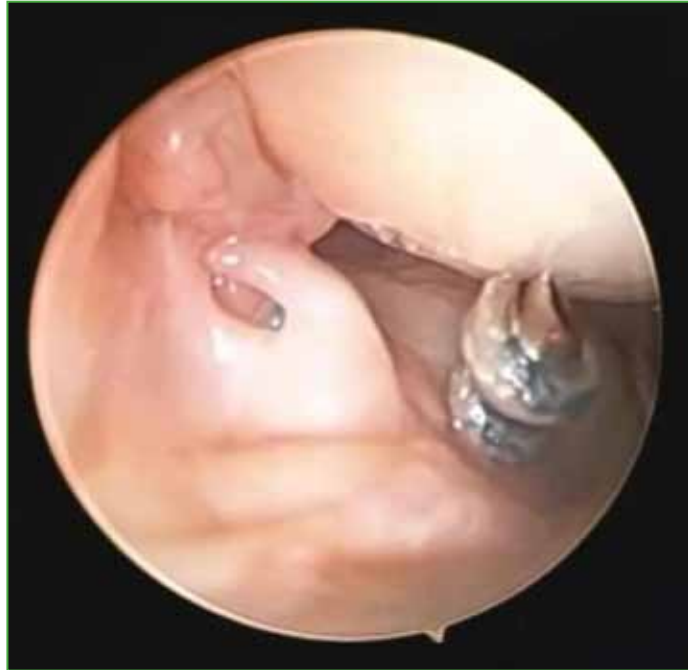

Figure 15. Second FiberWire® suture through the ulnar tunnel, 2 mm radial to the dorsal radioulnar ligament.

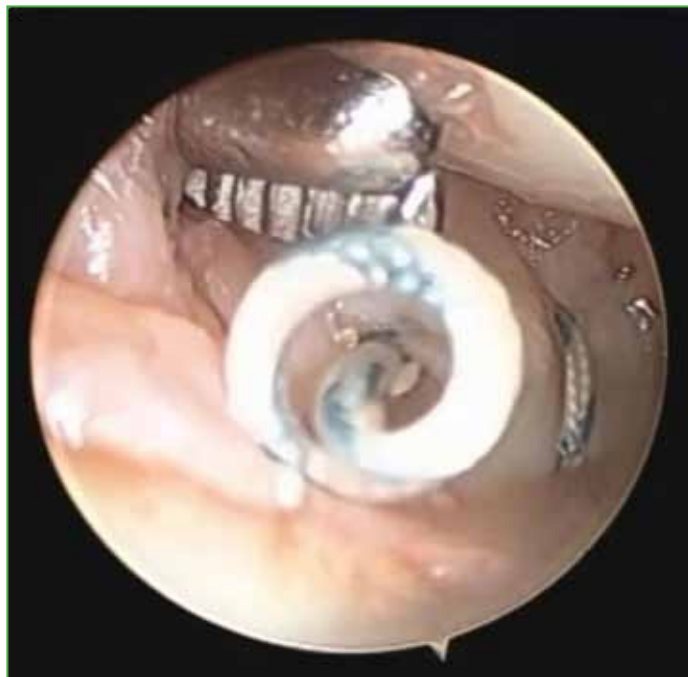

Figure 16. FiberWire® suture retrieved through the 6R portal.

Another suture puller is introduced to secure the dorsal ligament in zone 6, again 2 mm volar to the dorsal capsule. The suture is passed through the loop, tightened, and secured in the ulnar tunnel (Figures 7-9).

The approximate distance between the two dorsal radioulnar ligament perforations is 2 to 3 mm. The end of the suture that was retrieved through portal 6R is placed inside the loop of the suture retriever and gently pulled from the end of the suture retriever that was held outside the ulnar tunnel by visualization through portal 3-4. It is observed how the free end that was through portal 6R descends thanks to the traction of the suture retriever and is introduced into the ulnar hole by tightening the fibrocartilage at its dorsal ligamentous margin (Figures 17 and 18).

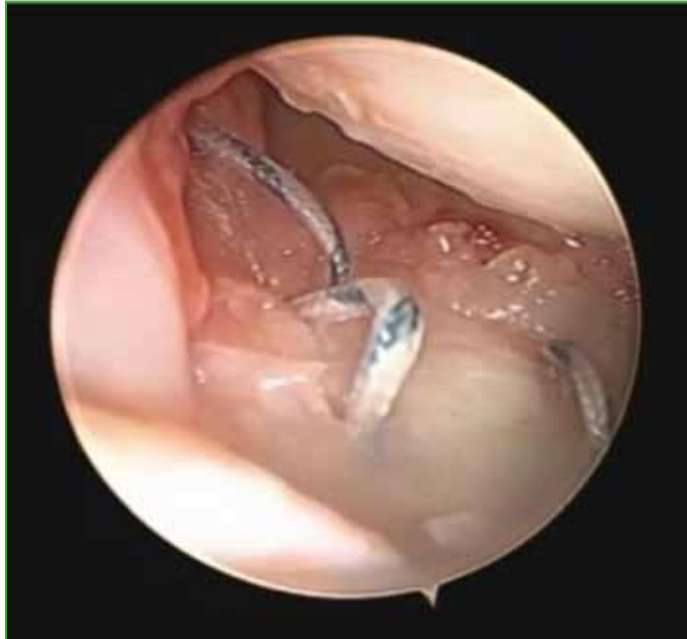

Figure 17. Second FiberWire® suture retrieved through the 6R portal.

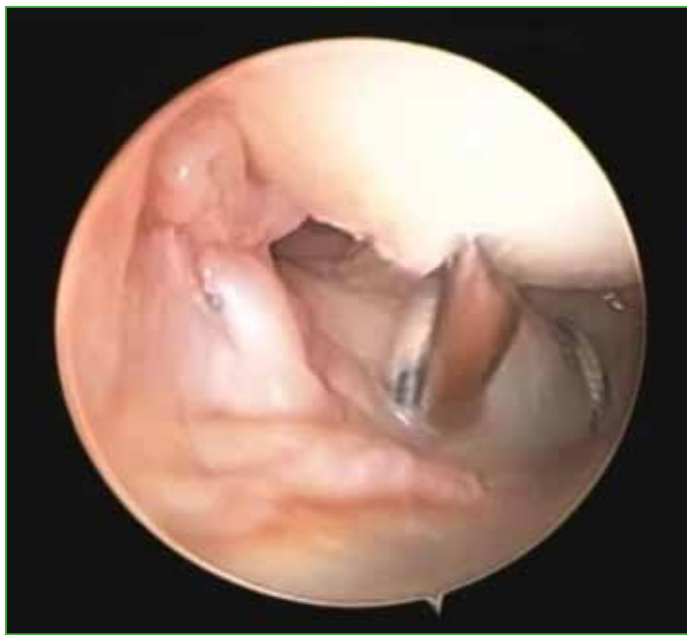

Figure 18. Passage and retrieval of the FiberWire® suture through the ulnar tunnel, view from portal 3-4.

In this way, a suture is obtained by tightening the dorsal radioulnar ligament with its two limbs through the ulnar tunnel and its ends outside the ulnar tunnel (Figure 19).

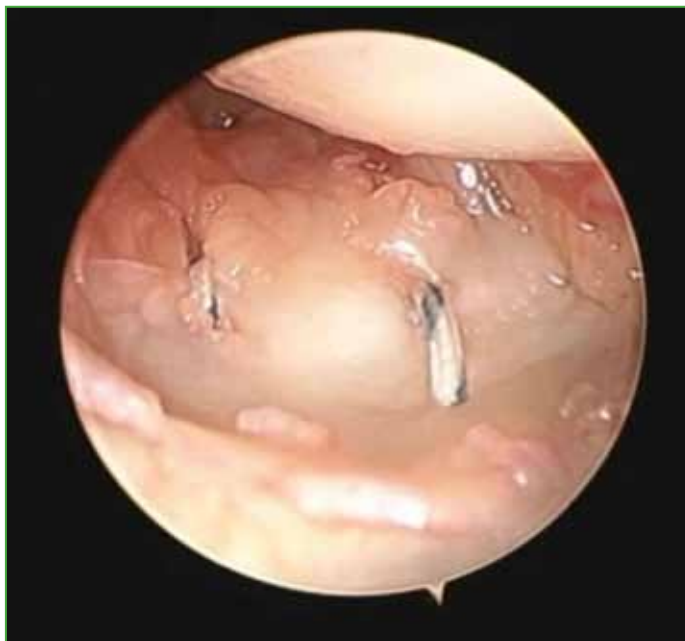

Figure 19. Tensioning of the dorsal radioulnar ligament of the triangular fibrocartilage complex, view from portal 3-4.

The two sutures tightening the TFCC are observed through portal 3-4, one in zones 1 and 3 corresponding to the volar radioulnar ligament and the other tightening the TFCC in zones 4 and 6 tightening the dorsal radioulnar ligament.

To finalize the repair, a 2.5 mm knotless anchorage device is employed. This device consists of a biodegradable screw with an eyelet for suture placement. A 2.2 mm bone tunnel is drilled horizontally into the ulnar metaphysis, 1 cm distal to the previously created ulnar tunnel, taking care to avoid damage to the dorsal sensory branch of the ulnar nerve. The sutures are threaded through the eyelet of the device, and the fixation system is inserted into the tunnel. After ensuring proper positioning, the device is impacted with a hammer, and the free suture ends are pulled to confirm secure anchorage.

The wrist is then placed in the traction tower, and the trampoline and hook tests are repeated to confirm stability (Figure 20). Full pronation and supination movements are performed under visualization to ensure the sutures remain secure. Finally, the wrist is removed from the traction tower, and the DRUJ is tested using the Nakamura test. Once stability is confirmed, the portals and ulnar incision are closed, and a Münster-type splint (sugar-tong splint) is applied. Figures 21 and 22 illustrate the bone and suture placements (Video).

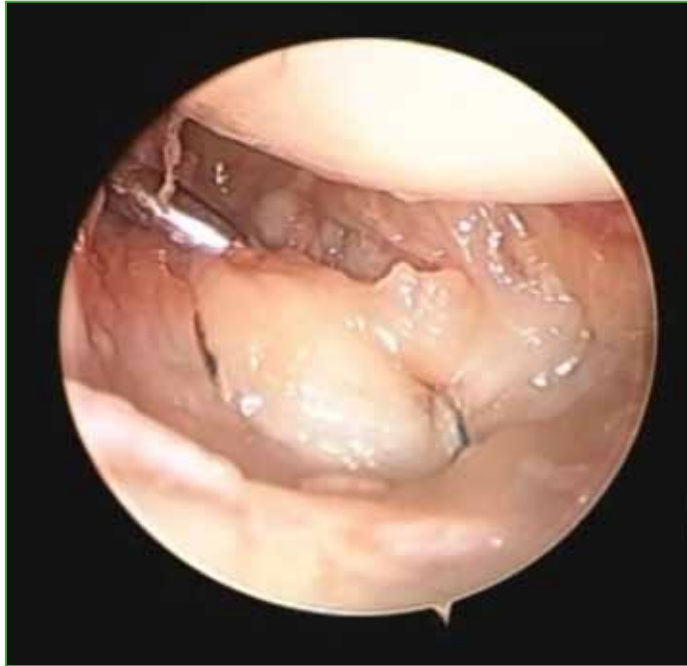

Figure 20. Reinsertion of the dorsal and volar ligaments of the triangular fibrocartilage complex. Negative hook test. View from portal 3-4.

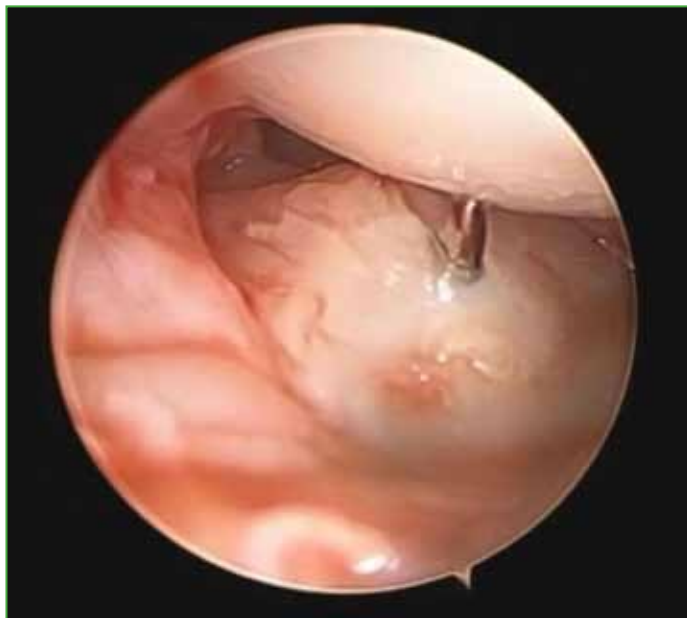

Figure 21. Verifying the pin in bone zone 2.

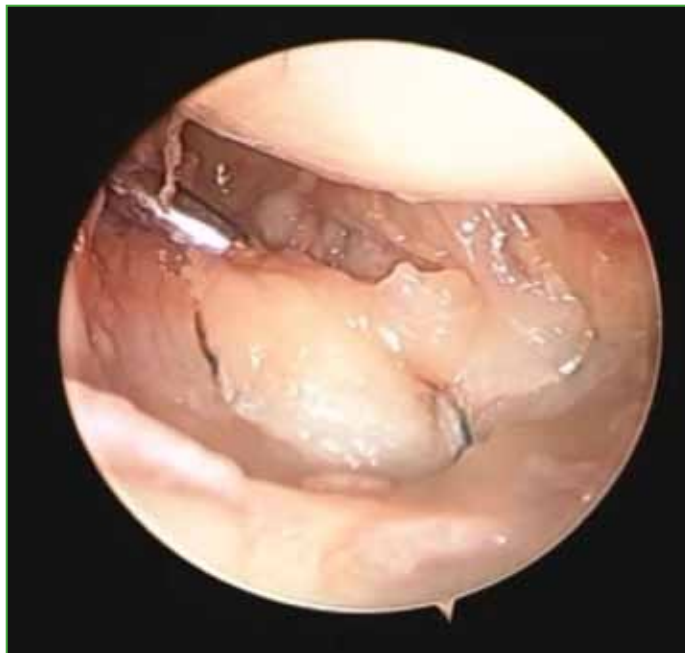

Figure 22. Verifying the suture areas in positions 1 and 3 (volar suture), and 4 and 6 (dorsal suture).

Postoperative Protocol

Seventy-two hours after surgery, the first dressing change is performed. The Münster-type splint is removed, a whale wrist brace is applied, and early mobility exercises are initiated under the guidance of a kinesiologist or occupational therapist.

The early mobility protocol includes: use of a nocturnal wrist brace for the first 3 weeks only; immediate initiation of 70% pronation, with progressive increase to 100% by the third week; immediate initiation of full flexion-extension (100%).

At the third week, the nocturnal wrist brace is discontinued, and strengthening exercises for the stabilizing tendons of the distal radioulnar joint (DRUJ) are introduced. Progressive strengthening begins at 6 weeks, and sports activities, including paddle and racquet sports, are authorized after 2 months.

RESULTS

Fourteen consecutive patients were retrospectively evaluated with a follow-up ranging from 11 to 22 months (mean: 15 months). None of the patients dropped out of follow-up.

Range of motion was measured using a standard PVS handheld goniometer, yielding the following results: extension: 85°; flexion: 80°; radial deviation: 20°; ulnar deviation: 30°; pronation: 80°; supination: 75°

Grip strength was assessed at the third month of follow-up using a standard hydraulic joint dynamometer (Baseline-Orthowell®). Comparative grip strength with the contralateral hand was 80% for both dominant and non-dominant operated hands.

The mean DASH (Disabilities of the Arm, Shoulder, and Hand) score improved significantly, from 62 (range: 41–90) preoperatively to 8 (range: 2–16) postoperatively. The Mayo Wrist Score (MWS) was excellent in 85% of cases and good in 15%.

All patients resumed their sports activities. The mean visual analog scale (VAS) score for pain decreased from 7 preoperatively to 2 at the final follow-up.

Recovery was confirmed when the Nakamura, Ruby, and Derby tests were negative.

Postoperative MRI was performed in four patients (required by work insurance companies), and imaging specialists confirmed healed foveal insertions in all cases (Figure 23).

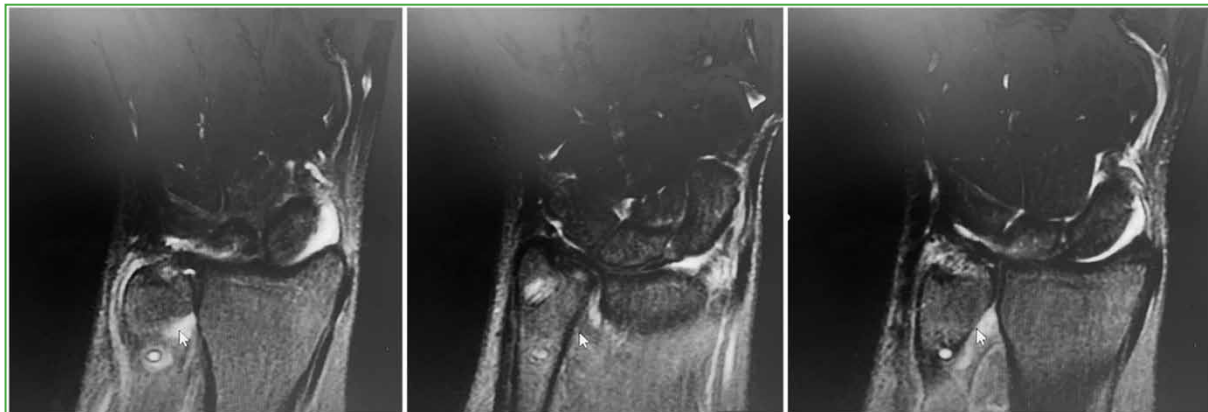

Figure 23. Foveal healing of the triangular fibrocartilage complex with vertical bone tunnel and metaphyseal anchorage at the ulna is seen.

One complication occurred: breakage of the biodegradable screw during placement due to a 2 mm ulnar metaphyseal tunnel. This issue was resolved intraoperatively by widening the tunnel with a 2.2 mm drill and successfully placing a new screw in the correct position.

DISCUSSION

A retrospective study analyzed the surgical outcomes of 14 consecutive adult patients with deep foveal lesions of the Atzei 2/3 TFCC, treated using arthroscopic knotless anchorage. The results were rated good to excellent based on the Mayo Wrist Score (MWS), and significant improvements were observed in the postoperative DASH score compared to preoperative values.

The fibers of the radioulnar ligaments exhibit a spiral rotation as they insert into the fovea. This unique configuration allows different portions of the ligaments to remain taut and functional across the full range of wrist motion, engaging specific bundles at varying joint angles. When the superficial fibers of the volar or dorsal radioulnar ligament are tightened, the deep fibers relax, and vice versa.¹

Numerous techniques for ligament reinsertion have been described, including harpoon placement in the fovea, reinsertion with monotunnels or bitunnels, and soft tissue anchorage with sutures.^{1,2,4-6}

Reinsertion of the dorsal and volar radioulnar ligaments must be both anatomical—over the correct ulnar insertion area—and isometric. Isometry, in this context, refers to the biomechanical principle of maintaining equal ligament length and tension across the widest possible range of motion.

Several alternatives have been published to solve this problematic situation. Although open surgery achieves good long-term outcomes, arthroscopic techniques offer several advantages, including complete evaluation of the lesion, reduced postoperative stiffness, minimal capsular damage, and the ability to address associated injuries.

Nakamura et al. introduced the outside-in technique using two separate tunnels for foveal lesions. In their study of 24 wrists with a mean follow-up of 3.5 years, MWS outcomes were excellent (54%), good (12%), satisfactory (16%), and poor (16%).⁷ Shinohara et al. reported on foveal repair using two tunnels and needles in 11 patients with a 30-month follow-up. They found grip strength recovery at 84%, with MWS outcomes being excellent (63%), good (27%), and poor (10%). However, 27% of patients experienced neuropraxia in the territory of the sensory branch of the ulnar nerve.⁴

Ma et al. compared the biomechanical outcomes between open and arthroscopic repair in cadaveric models. They obtained better strength outcomes and lower ulnar translation in arthroscopic than in open repairs.³ Atzei and Luchetti treated 48 patients arthroscopically, using a foveal harpoon. They reported excellent to good MWS outcomes in 83% of cases, with 85% of patients returning to sports at their pre-injury level. Despite these positive results, the Nakamura test remained positive in 8% of cases. Patients achieved 95% of flexion-extension, 98% of pronation-supination, and 92% of grip strength, though 10% experienced ulnar sensory neuropathy.¹

Jung et al. evaluated arthroscopic foveal repair using knotless anchorage in 42 patients with a mean follow-up of 26 months. Their MWS outcomes were excellent (12 cases), good (18 cases), fair (11 cases), and poor (1 case). Grip strength reached 69% of the contralateral side.⁵ Park et al. conducted a study on arthroscopic foveal repair of the TFCC using a single bone tunnel in 17 patients, with a follow-up of 30 months. Grip strength reached 57% of the unaffected side, and 83% of patients achieved excellent or good outcomes according to the MWS. The DASH score improved from 35.5 preoperatively to 9 postoperatively.⁶

In their cadaveric study, Matsumoto et al. identified the optimal positioning for transosseous tunneling and suture placement in the TFCC based on their impact on joint mobility. They divided the fovea into six zones and the TFCC into another six zones. Their findings showed that tunneling in zone 2 and suturing in any TFCC zone minimized suture mobility. Matsumoto emphasized the importance of creating a precise bone tunnel (Figures 24-26).⁷

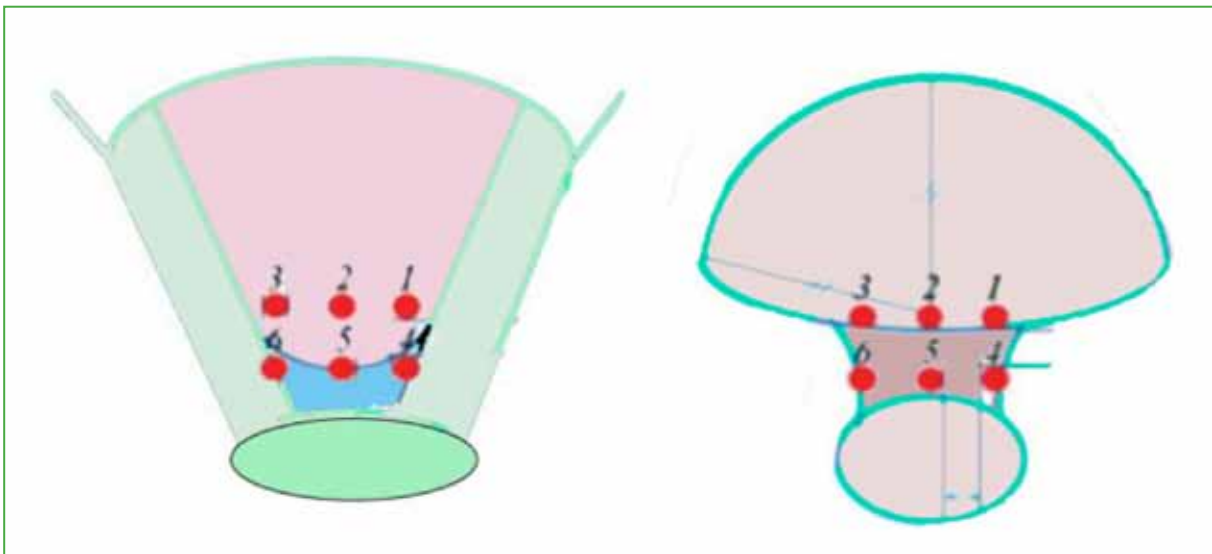


Figure 24. Images of the Matsumoto zones. Foveal areas and areas of the triangular fibrocartilage complex.

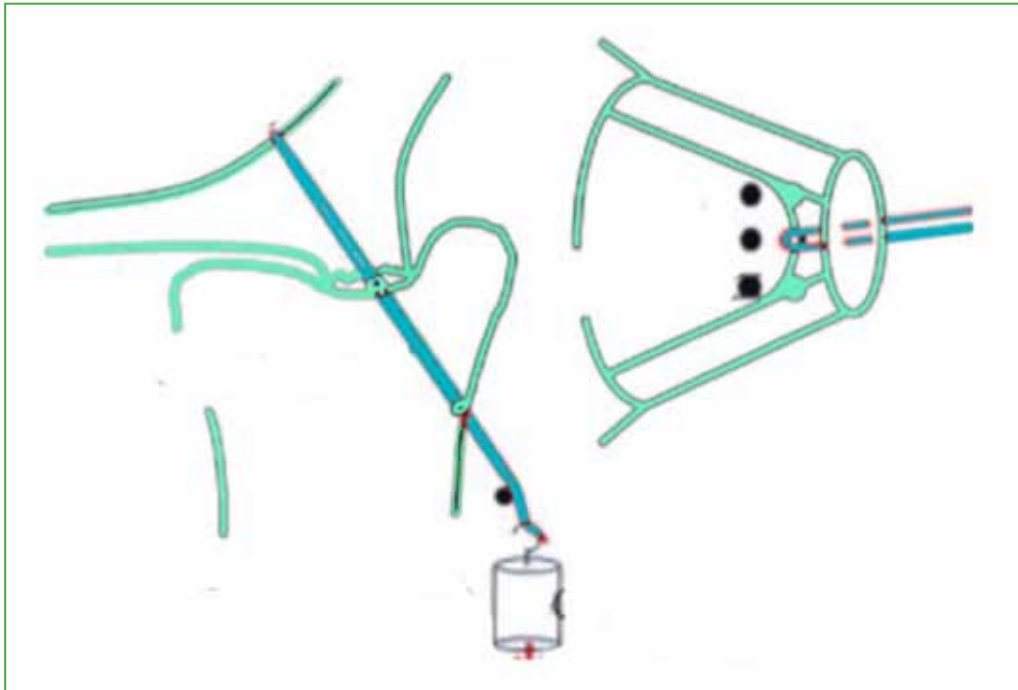


Figure 25. Coronal and axial images of the bone tunnel in zone 2.

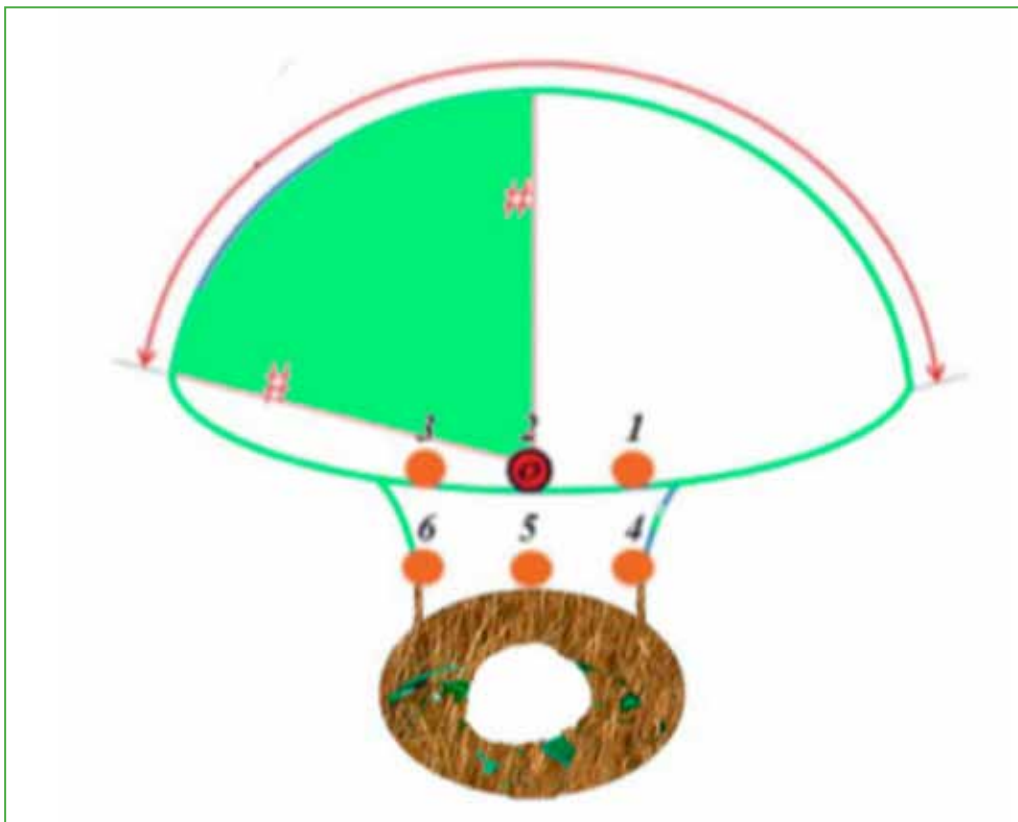


Figure 26. Image of foveal zone 2.

Table 3 presents the comparative outcomes of monotunnel fixation.

Table 3. Comparative outcomes of monotunnel fixation

Authors	Technique	Patients (n)	Follow-up (months)	Grip strength (%)	DASH	MWS (good or excellent) (%)	Sensory neuropathy	Residual instability (n)
Jung et al.	Knotless anchor, 1 tunnel	42	26	70	-	71	-	2
Shinohara et al.	Anchoring 2 tunnels with needle	11	30	-	-	93	27	-
Atzei and Luchetti	Anchoring with harpoon	48	30	92	42 preop. 20 postop.	83	-	2
Nakamura et al.	2 needle tunnels	24	42	-	-	66	-	-
Park et al.	Knotless anchor, 1 tunnel	17	30	57%	35 preop. 7 postop.	83	-	-
Our series	Knotless bone anchor, 1 tunnel	14	15	70	56 preop. 8 postop.	100	16	0

MWS = Mayo Wrist Score; DASH = Disabilities of Arm, Shoulder and Hand score.

Okuda, in a study of 26 cadaveric specimens, analyzed the ligament insertion site within the fovea and its area of attachment. He described the foveal fibers as being widely and intricately interwoven at their insertion on the ulna. The TFCC insertion occupied an area of 34 mm with a diameter of 9 mm over the ulnar fovea. His findings highlighted a broad insertion area encompassing the bases of the dorsal and volar radioulnar ligaments of the TFCC.⁸

This study aligns with the concept of a broad fixation of both ligament components to achieve isometric anchorage (Figure 27).⁸

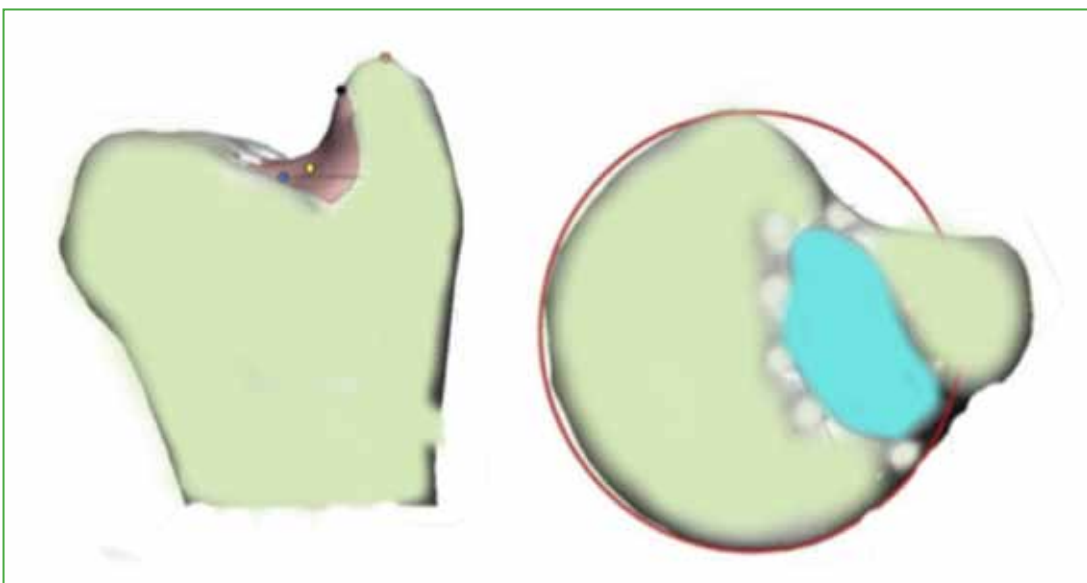


Figure 27. Insertion zone of the triangular fibrocartilage complex in the fovea.

Building upon Matsumoto and Okuda's findings, the present research evaluated the functional outcomes of arthroscopic knotless foveal anchorage for Atzei 2/3 TFCC lesions. The technique used a monotunnel in zone 2, combined with TFCC sutures in zones 1 and 3 to anchor the volar radioulnar ligament, and zones 4 and 6 to anchor the dorsal radioulnar ligament. This approach optimizes tunnel positioning to minimize suture motion and ensures comprehensive TFCC anchorage across its insertion area while preserving the isometry of the dorsal and volar radioulnar ligament fibers. Anchoring ligament fibers distant from the ulna risks increasing ligament tension, potentially causing fiber damage or restricted joint mobility.

Biomechanical studies suggest that tunnel-based anchorage is superior to foveal harpoon anchorage. Placing the ulnar tunnel in zone 2, alongside sutures in the distal radioulnar ligament zones 1 and 3 (volar) and 4 and 6 (dorsal), minimizes TFCC movement during healing and achieves comprehensive anchorage. This method recreates the original ligament insertion on the ulnar fovea, maintaining ligament length and tension. This isometric anchorage supports proper anatomical and biological healing, enabling early rehabilitation with minimal suture movement during recovery phases, fostering the anatomical repair of the foveal ligaments.

This study achieved outcomes comparable to those of previous authors, despite a shorter follow-up period. Additionally, the patients exhibited greater grip strength than reported in most prior studies, and all returned to sports.

Advances in technology and biomechanical studies confirm that the stability of the TFCC and the distal radioulnar joint (DRUJ) primarily depends on its foveal fibers. The key objective is to restore a stable, pain-free, and functional DRUJ.^{1-3,5}

Other authors have reported complications such as ulnar paresthesia and reinterventions due to pain or instability. In this series, no such complications were observed. One biodegradable screw fractured during placement in a 2-mm ulnar metaphyseal tunnel, which was resolved intraoperatively by enlarging the tunnel to 2.2 mm and placing a new screw. Another case involved creating a dorsal cortical ulnar metaphyseal tunnel, which failed to ensure linear suture traction. A new tunnel, located 1 cm distal to the original, was created centrally in the metaphysis, achieving proper screw placement. This required extending the ulnar incision by 2 cm.

Other than these, no additional complications occurred. However, it is crucial to acknowledge the need for a learning curve to perform this or similar techniques. In other arthroscopic series, complications such as ulnar nerve neuropraxia, central articular disc rupture, ulnar fractures, malposition of cubital tunnels, and suture tension loss have been reported.

The strengths of this study include the homogeneous patient population, the consistent follow-up, and the use of a single surgeon employing a standardized method. Limitations include its retrospective nature and the absence of arthroscopic reevaluation to confirm long-term repair quality.

CONCLUSIONS

Arthroscopic repair of Atzei 2/3 lesions using isometric, monotunnel, knotless bone anchorage yields favorable functional outcomes. It enables foveal ligament anchorage at its anatomical insertion, improving range of motion, reducing pain, and restoring stability to the DRUJ.

Based on our results, it is possible to conclude that isometric repair using the monotunnel anchor technique with arthroscopic assistance offers good functional outcomes in the repair of TFCC Atzei 2/3 lesions.

Conflict of interest: The authors declare no conflicts of interest.

REFERENCES

1. Hagert E, Hagert C-G. Understanding stability of the distal radioulnar joint through an understanding of its anatomy. *Hand Clin* 2010;26:459-66. <https://doi.org/10.1016/j.hcl.2010.05.002>
2. Trehan SK, Wall LB, Calfee RP, Shen TS, Dy CJ, Yannascoli SM, et al. Arthroscopic diagnosis of the triangular fibrocartilage complex foveal tear: a cadaver assessment. *J Hand Surg Am* 2018;43(7):680.e1-680.e5. <https://doi.org/10.1016/j.jhsa.2017.12.017>
3. Ma CH, Lin TS, Wu CH, Li DY, Yang SC, Tu YK. Biomechanical comparison of open and arthroscopic transosseous repair of triangular fibrocartilage complex foveal tears: a cadaveric study. *Arthroscopy* 2017;33(2):297-304. <https://doi.org/10.1016/j.arthro.2016.10.027>
4. Shinohara T, Tatebe M, Okui N, Yamamoto M, Kurimoto S, Hirata H. Arthroscopically assisted repair of triangular fibrocartilage complex foveal tears. *J Hand Surg Am* 2013;38(2):271-7. <https://doi.org/10.1016/j.hsa.2012.11.008>
5. Jung HS, Song KS, Jung HS, Yoon BI, Lee JS, Park MJ. Clinical outcomes and factors influencing these outcome measures resulting in success after arthroscopic transosseous triangular fibrocartilage complex foveal repair. *Arthroscopy* 2019;35(8):2322-30. <https://doi.org/10.1016/j.arthro.2019.03.060>
6. Park JH, Kim D, Park JW. Arthroscopic one-tunnel transosseous foveal repair for triangular fibrocartilage complex (TFCC) peripheral tear. *Arch Orthop Trauma Surg* 2018;138(1):131-8. <https://doi.org/10.1007/s00402-017-2835-3>
7. Matsumoto T, Tang P, Fujio K, Strauch RJ, Rosenwasser MP. The optimal suture placement and bone tunnels for TFCC repair: a cadaveric study. *J Wrist Surg* 2018;7(5):375-81. <https://doi.org/10.1055/s-0038-1661361>
8. Okuda M. Morphology of the ulnar insertion of the triangular fibrocartilage complex and related osseous landmarks. *J Hand Surg Am* 2021;46(7):625.e1-625.e7. <https://doi.org/10.1016/j.jhsa.2020.12.006>