

# Total Hip Arthroplasty in Patients with Crowe Grades II, III, and IV Developmental Dysplasia of the Hip: Evaluation of Different Acetabular Reconstruction Techniques. Clinical and Functional Outcomes and Radiographic Analysis

Valentín Rivera Bacile, María Luz Paz, Nicolás Rabello, Ricardo Mishima, Ignacio J. Pioli, José M. Gómez, Santiago L. Iglesias, Bartolomé L. Allende

Department of Joint Replacement and Lower Limb Trauma, Sanatorio Allende, Córdoba, Argentina.

## ABSTRACT

**Introduction:** Developmental dysplasia of the hip (DDH) is one of the leading causes of hip osteoarthritis, particularly in young patients. Total hip arthroplasty (THA) is an effective treatment to alleviate pain and improve function in these patients. However, anatomical deformities and the variability in the presentation of DDH make these surgeries challenging. **Objectives:** To evaluate the clinical and functional outcomes of THA in patients with Crowe grades II, III, and IV DDH and to analyze the acetabular reconstruction techniques used. **Methods:** This retrospective study included patients who underwent THA between 2008 and 2023. Patients were assessed using the Harris Hip Score and radiographic imaging. Statistical analyses were performed to compare outcomes and evaluate the relationship between age and postoperative progress. **Results:** The sample included 50 patients with Crowe grades II, III, and IV DDH. Of the patients, 78% were female, with a mean age of 47.24 years. Crowe grade II DDH was found in 49.12% of the patients. The most common acetabular reconstruction technique was medialization (58%). There was no significant relationship between age and clinical outcomes. Postoperative complication rates were similar across age groups. **Conclusions:** This study suggests that age does not significantly influence THA outcomes in patients with Crowe grades II, III, and IV DDH. The choice of acetabular reconstruction technique should be individualized for each case.

**Keywords:** Developmental dysplasia of the hip; Crowe classification; Total hip arthroplasty.

**Level of Evidence:** IV

## Artroplastia total de cadera en pacientes con displasia congénita de cadera grados II, III y IV de Crowe. Evaluación del manejo acetabular: resultados clínico-funcionales y análisis radiográfico

## RESUMEN

**Introducción:** La displasia congénita de cadera (DCC) es la causa principal de osteoartritis de cadera, especialmente en pacientes jóvenes. La artroplastia total de cadera (ATC) es un tratamiento eficaz para aliviar el dolor y mejorar la función de estos pacientes. Sin embargo, las deformidades anatómicas y la variabilidad en la presentación de la DCC hacen que estas cirugías sean desafiantes. **Objetivos:** Evaluar los resultados clínicos y funcionales de la ATC en pacientes con DCC grados II, III y IV de Crowe, y analizar las técnicas de reconstrucción acetabular utilizadas. **Materiales y Métodos:** Estudio retrospectivo en pacientes sometidos a una ATC entre 2008 y 2023. Los pacientes fueron evaluados con el Harris Hip Score y radiografías. Se utilizaron análisis estadísticos para comparar resultados y evaluar la relación entre la edad y la evolución posquirúrgica. **Resultados:** La muestra incluyó a 50 pacientes con DCC grados II, III y IV de Crowe. El 78% eran mujeres y la media de la edad era de 47.24 años. El 49,12% tenía DCC grado II de Crowe. La técnica de reconstrucción acetabular más común fue la medialización (58%). No se halló una relación significativa entre la edad y los resultados clínicos. La tasa de complicaciones posquirúrgicas fue similar en ambos grupos etarios. **Conclusiones:** Este estudio sugiere que la edad no influye significativamente en los resultados de la ATC en pacientes con DCC grados II, III y IV de Crowe. La elección de la técnica de reconstrucción acetabular debe adaptarse a cada caso.

**Palabras clave:** Displasia de cadera; clasificación de Crowe; artroplastia total de cadera.

**Nivel de Evidencia:** IV

Received on May 21<sup>st</sup>, 2024. Accepted after evaluation on July 7<sup>th</sup>, 2024 • Dr. VALENTÍN RIVERA BACILE • valenriverabacile@gmail.com  <https://orcid.org/0009-0004-7173-8990>

**How to cite this article:** Rivera Bacile V, Paz ML, Rabello N, Mishima R, Pioli IJ, Gómez JM, Iglesias SL, Allende BL. Total Hip Arthroplasty in Patients with Crowe Grades II, III, and IV Developmental Dysplasia of the Hip: Evaluation of Different Acetabular Reconstruction Techniques. Clinical and Functional Outcomes and Radiographic Analysis. *Rev Asoc Asoc Argent Ortop Traumatol* 2024;89(5):443-449. <https://doi.org/10.15417/issn.1852-7434.2024.89.5.1966>

## INTRODUCTION

Developmental dysplasia of the hip (DDH) is a leading cause of secondary osteoarthritis of the hip, particularly in young patients. It often results in significant pain and loss of function. Total hip arthroplasty (THA) is the most effective treatment for relieving pain, restoring joint function, and correcting leg length discrepancies in these patients.<sup>1</sup> DDH is a congenital condition characterized by joint incongruity due to inadequate development of the acetabulum, often accompanied by chronic dislocation of the femoral head.<sup>2</sup>

THA presents a challenging procedure for orthopedic surgeons in these cases. Various anatomical variations on both the femoral and acetabular sides increase the complexity of the surgical technique. Surgeons may encounter a narrow femoral canal, excessive femoral anteversion, coxa valga, a hypoplastic and retroverted greater trochanter, and a hypoplastic acetabulum with more anteversion than usual. Additionally, soft tissue contractures around the joint due to chronic dislocation further complicate the procedure.<sup>3</sup>

Despite these morphological alterations, special attention must be given to the patient's age, as DDH often affects young individuals who may require future surgical revisions.<sup>4</sup>

Restoring the anatomical center of rotation of the hip yields favorable biomechanical outcomes in THA for patients with DDH. To achieve this, femoral shortening through osteotomies is often necessary. This allows proper reduction while preventing excessive limb lengthening and reducing the risk of sciatic neuropraxia.<sup>1,3</sup>

## OBJECTIVE

To evaluate the clinical and functional outcomes of THA in patients with Crowe classification grades II, III, and IV DDH.

## MATERIALS AND METHODS

A retrospective, descriptive, observational study was conducted with patients who underwent total hip arthroplasty (THA) for Crowe classification grades II, III, and IV developmental dysplasia of the hip (DDH) at both sites of Sanatorio Allende, between 2008 and 2023.

Patients with Crowe grade I DDH were excluded. To facilitate the analysis of results, the sample was divided into two groups: patients aged  $\leq 46$  years (group 1) and those  $> 46$  years (group 2).

Surgical planning included radiographic and functional evaluations using the Harris Hip Score (HHS). Preoperative radiographs were used to determine femoral head migration, measured by comparing the vertical distance from the center of rotation to a horizontal line joining the distal edges of both teardrops.

Surgery was performed with patients in the lateral decubitus position using a posterolateral approach. Postoperatively, a progressive 50% weight-bearing protocol on the affected leg with a walker was recommended for the first 6 weeks. All patients followed strict hip mobility precautions, specifically limiting flexion, abduction, and internal rotation. Antibiotic prophylaxis was administered preoperatively and in the immediate postoperative period, with antithrombotic prophylaxis given for 28 days.

Follow-up evaluations were conducted at 3 and 6 weeks, 3 months, and annually. The HHS was used immediately postoperatively, and radiographs were taken at 3 months and yearly. Postoperative radiographs were used to assess the orientation of the acetabular cup in the sagittal and coronal planes and to check for areas of radiolucency on the acetabular side (DeLee and Charnley zones). Acetabular cup loosening was defined as a  $> 2$  mm change in the horizontal or vertical position, accompanied by an adjacent radiolucent zone or a radiolucent zone  $> 3$  mm.

Lower limb length discrepancy correction, the occurrence of complications (sciatic nerve neuropraxia, instability, infection), and the time to femoral osteotomy consolidation were also evaluated.

## Statistical analysis

Fisher's exact test was used to compare categorical variables between groups. Numerical variables were analyzed using Student's t-test or the Wilcoxon test, depending on the data distribution. The relationship between age and HHS variation was assessed using simple linear regression.

Kaplan-Meier survival curves were constructed to compare prognoses between groups, and the log-rank test was applied. A p-value  $< 0.05$  was considered statistically significant. All analyses were performed using the RStudio software.

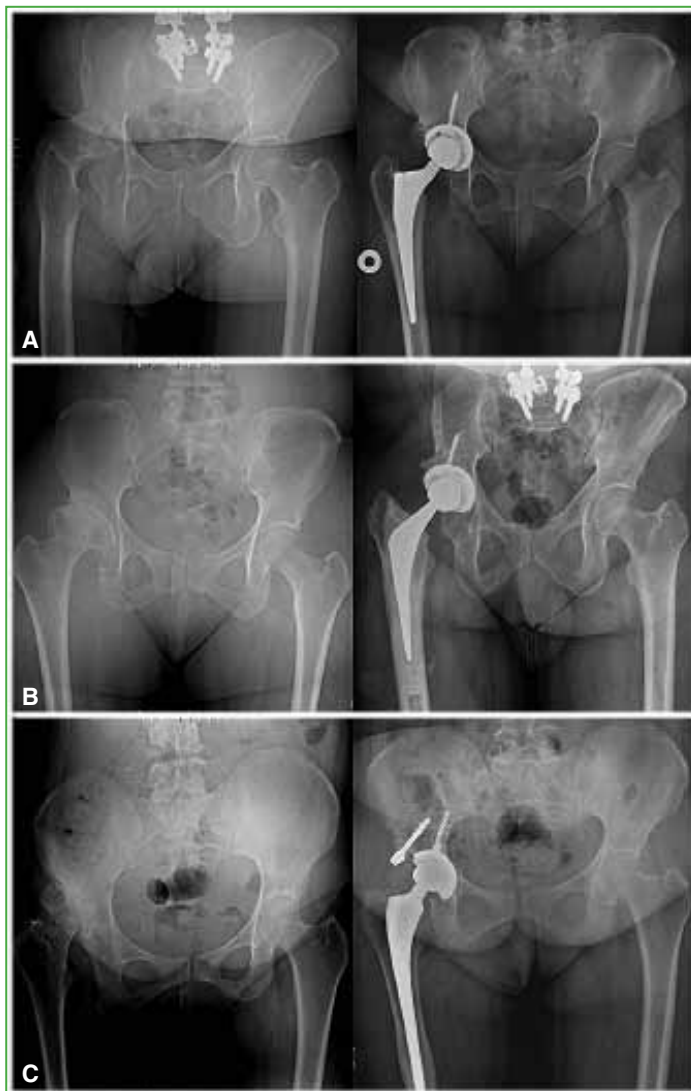
### Ethical aspects

This study carries minimal risk as it is observational, classifying it as a category II study according to the World Health Organization. The patients' personal data were protected in accordance with Law 25,326 (Data Protection Law), specifically Article 8 regarding data registry and Habeas Data, ensuring the confidentiality of both personal and professional information. The study adhered to the guidelines of Good Clinical Practice and the principles outlined in the Declaration of Helsinki, including its respective updates. This project was approved by the Research Ethics Committee of Sanatorio Allende, Córdoba, Argentina.

### RESULTS

A sample of 50 patients with Crowe grade II, III, and IV DDH who underwent THA at Sanatorio Allende between 2008 and 2023 was evaluated. Of these, 78% (39 patients) were women, and the mean age was  $47.24 \pm 12.88$  years. The distribution of Crowe grades was as follows: 49.12% had grade II DDH (24 cases), 36.84% had grade III (18 cases), and 14.04% had grade IV (8 cases).

Regarding the surgical management of the acetabulum, 58% (29 cases) underwent medialization, 38% (18 cases) were treated with the high hip center technique, and 8% (3 cases) required bone grafting (Figure 1). The sample was divided into two groups: patients aged  $\leq 46$  years (group 1) and those  $>46$  years (group 2) (Table).



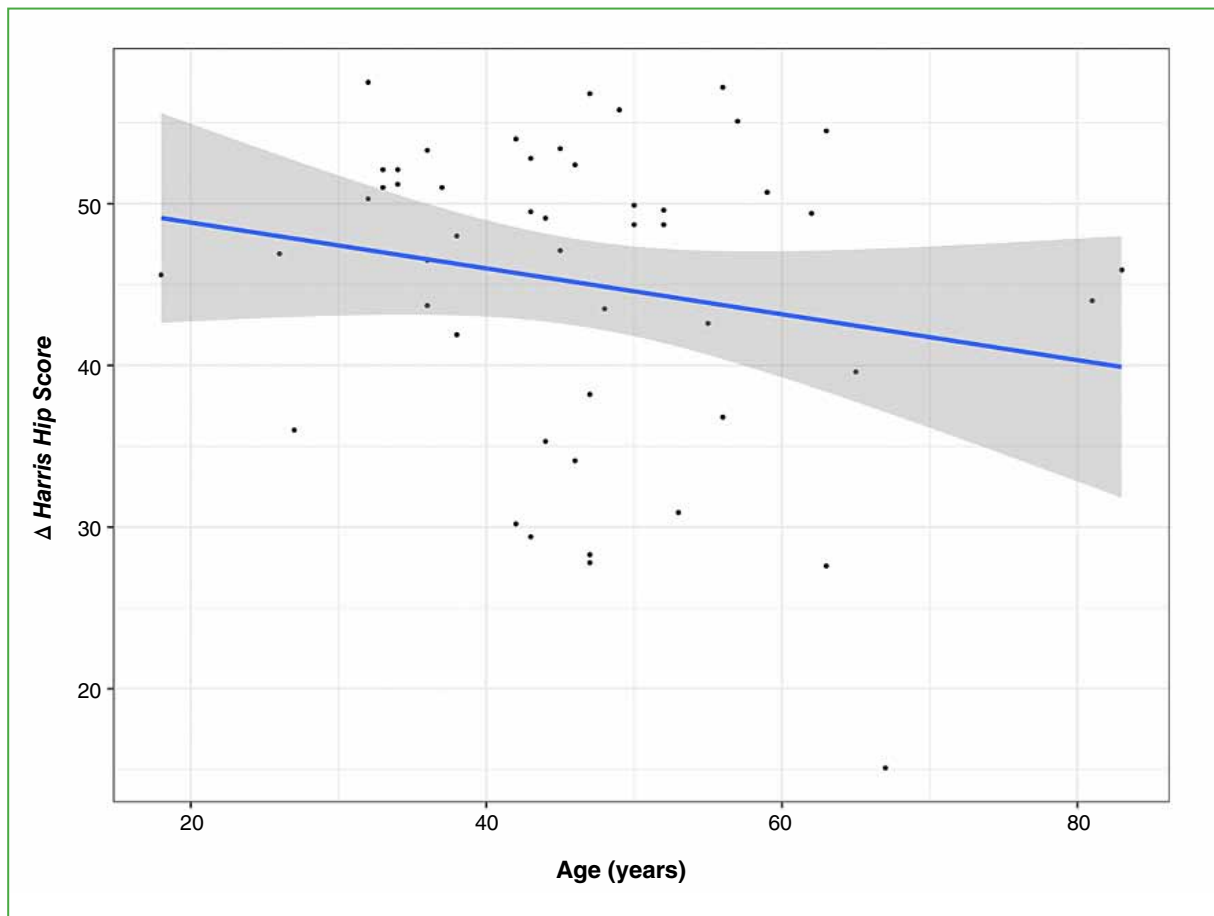
**Figure 1.** Preoperative (left column) and postoperative (right column) radiographs according to acetabular management technique: medialization (A), high hip center (B), and bone grafting (C).

**Table.** Characteristics of the groups

	age ≤46 years (n = 27)	age >46 years (n = 23)	p
Bilateral (%)	3 (11.1)	5 (21.7)	0.5
Preoperative HHS ± SD	47.3 ± 6.7	48.4 ± 6.7	0.6
Postoperative HHS ± SD	94 ± 6	91.7 ± 8.7	0.3
Complications (%)	8 (29.6)	3 (13.0)	0.3
Loosening	6 (22.2)	2 (8.7)	
HHS <70	0	1 (4.3)	
Infection	2 (7.4)	0	
Follow-up (days ± SD)	1327 ± 1300	1507 ± 1626	0.7

HHS = Harris Hip Score; SD = standard deviation.

Simple linear regression analysis showed no statistically significant relationship between age and post-surgical Harris Hip Score (HHS) ( $p < 0.2$ ). This indicates that HHS improvement after THA was independent of age (Figure 2).



**Figure 2.** Scatter plot. Age (years) vs.  $\Delta$  Harris Hip Score.

To evaluate the survival rate of the prosthesis in both groups, the Kaplan-Meier curve was used, which showed no statistically significant differences between the groups concerning post-surgical complications that could lead to prosthesis failure ( $p = 0.072$ ) (Figure 3).

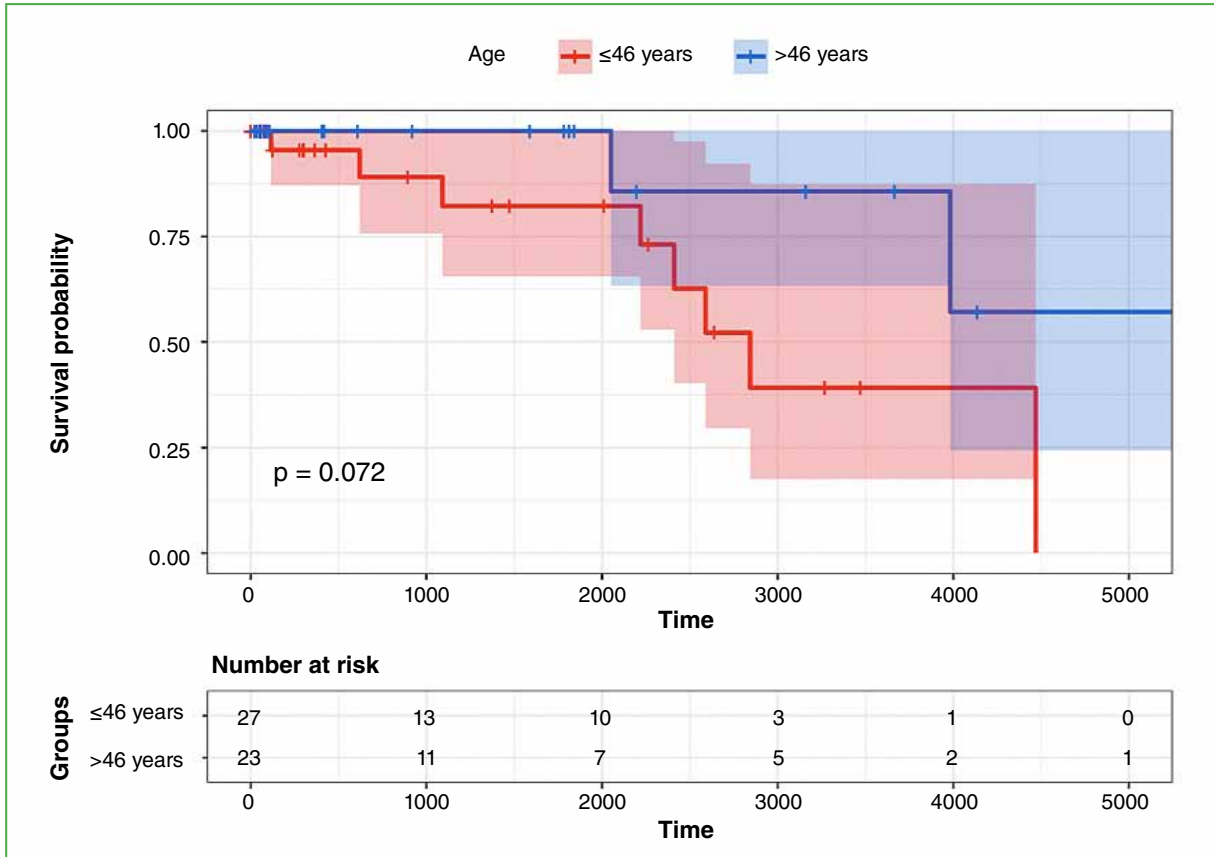


Figure 3. Kaplan-Meier curve.

A total of 11 patients experienced complications. There were eight cases of loosening, identified by radiolucency on the acetabular side (DeLee and Charnley areas). Only one of these patients required revision surgery, while the others remained asymptomatic. Two cases of infection occurred—one treated with single-stage revision, and the other required a two-stage revision with the placement of a cement spacer with antibiotics followed by THA in a subsequent procedure. Only one patient had a post-surgical HHS <70 and was treated with analgesics and physiotherapy.

## DISCUSSION

Total hip arthroplasty (THA) in patients with developmental dysplasia of the hip (DDH) remains a significant challenge for hip arthroplasty specialists. In our study, we evaluated the clinical and functional outcomes of patients undergoing THA for Crowe grades II, III, and IV DDH. Although no statistically significant relationship between age and the various outcome variables was found, our findings align with several previous studies.<sup>5,6</sup> These studies also suggest that age does not appear to be a decisive factor in the short-term outcomes of THA in patients with DDH.

The most commonly used acetabular reconstruction technique was medialization, which was predominantly employed in patients with Crowe grade II DDH (49.12%).

Jasty and Harris report that for patients with Crowe grades I and II DDH, the surgical technique generally does not require extensive modification or special procedures. They argue that medialization of the acetabular implant in

such patients is often sufficient to achieve good coverage and bone contact for the prosthesis. However, in patients with Crowe grades III and IV DDH, due to soft tissue contracture and lower limb length discrepancy, additional surgical measures—such as moving the rotational center superiorly or performing femoral osteotomies—are often necessary to achieve optimal postoperative outcomes.<sup>7</sup> This approach is supported by previous research that has demonstrated satisfactory outcomes in terms of pain relief and functional improvement in patients with Crowe II, III, and IV DDH.<sup>8,9</sup> Delp and Maloney, as well as Makita et al., report favorable outcomes using the high hip center and bone grafting techniques, emphasizing the importance of tailoring the surgical approach to each patient's specific anatomy and needs.<sup>10,11</sup>

Regarding postoperative complications of THA in patients with DDH, common issues include loosening of the implant (both femoral and acetabular), infection, and functional disability of the joint. Functional disability was assessed using the Harris Hip Score (HHS) before surgery and at the final follow-up. Akbaba et al. also used the HHS to measure postoperative function, categorizing scores <70 as poor, 71–80 as acceptable, 81–90 as good, and >90 as excellent.<sup>12</sup> In our study, we classified scores below 70 as indicative of postoperative complications related to functional disability of the prosthesis.

Our analysis of prosthesis lifespan revealed no significant differences in postoperative complication rates between age groups. These findings are consistent with existing literature, which suggests that age is not an independent risk factor for postoperative complications in THA.<sup>13,14</sup> However, it is important to recognize that complications may be influenced by multiple factors, including pre-existing comorbidities and the specific surgical technique used, which should be considered during clinical evaluation.

Our study has limitations, including the relatively small sample size and limited follow-up period. The absence of significant differences in some comparisons may be attributable to the limited statistical power in a small cohort. Further research with larger sample sizes and longer follow-up periods is needed to fully assess the influence of age and acetabular reconstruction techniques on outcomes in patients with DDH.

## CONCLUSIONS

Our results suggest that age at the time of surgery does not appear to be a significant factor in determining the immediate outcomes or postoperative complications of total hip arthroplasty (THA) in patients with Crowe grades II, III, and IV developmental dysplasia of the hip (DDH). Additionally, our findings highlight that the choice of acetabular reconstruction technique should be based on an individualized assessment of each patient. However, it is important to acknowledge the limitations of this study and that future studies with larger cohorts and longer follow-up periods are needed to confirm these results and provide more robust clinical guidance for managing this patient population.

Conflict of interest: The authors declare no conflicts of interest.

M. L. Paz ORCID ID: <https://orcid.org/0000-0002-3612-9231>

N. Rabello ORCID ID: <https://orcid.org/0000-0003-0647-2124>

R. Mishima ORCID ID: <https://orcid.org/0000-0001-5163-7130>

I. J. Pioli ORCID ID: <https://orcid.org/0000-0001-8697-1980>

J. M. Gómez ORCID ID: <https://orcid.org/0000-0002-1162-2708>

S. L. Iglesias ORCID ID: <https://orcid.org/0000-0001-6698-2914>

B. L. Allende ORCID ID: <https://orcid.org/0000-0003-2757-4381>

## REFERENCES

1. Zeng WN, Liu JL, Wang FY, Zhang X, Fan HQ, Chen GX, et al. Total hip arthroplasty for patients with Crowe type IV developmental dysplasia of the hip: Ten years results. *Int J Surg* 2017;42:17-21. <https://doi.org/10.1016/j.ijso.2017.04.029>
2. Grappiolo G, La Camera F, Della Rocca A, Mazziotto G, Santoro G, Loppini M. Total hip arthroplasty with a monoblock conical stem and subtrochanteric transverse shortening osteotomy in Crowe type IV dysplastic hips. *Int Orthop* 2018;43(1):77-83. <https://doi.org/10.1007/s00264-018-4122-5>

3. Krych AJ, Howard JL, Trousdale RT, Cabanela ME, Berry DJ. Total hip arthroplasty with shortening subtrochanteric osteotomy in Crowe type-IV developmental dysplasia. *J Bone Joint Surg Am* 2010;92(Suppl 1 Pt 2):176-87. <https://doi.org/10.2106/JBJS.J.00061>
4. Greber E, Pelt CE, Gililland J, Anderson MB, Erickson J, Peters CL. Challenges in total hip arthroplasty in the setting of developmental dysplasia of the hip. *J Arthroplasty* 2017;32(9S):S38-S44. <https://doi.org/10.1016/j.arth.2017.02.024>
5. Hartofilakidis G, Karachalios T, Stamos KG. Epidemiology, demographics, and natural history of congenital hip disease in adults. *Orthopedics* 2000;23(8):823-7. <https://doi.org/10.3928/0147-7447-20000801-16>
6. Crowe JF, Mani VJ, Ranawat CS. Total hip replacement in congenital dislocation and dysplasia of the hip. *J Bone Joint Surg Am* 1979;61(1):15-23. PMID: 365863
7. Jasty M, Harris WH. Total hip replacement in the congenitally dysplastic hip. *Op Tech Orthop* 1995;5(4):336-40. [https://doi.org/10.1016/S1048-6666\(95\)80034-4](https://doi.org/10.1016/S1048-6666(95)80034-4)
8. O'Neill CL, Creedon SB, Brennan SA, O'Mahony FJ, Lynham RS, Guerin S, et al. Acetabular revision using trabecular metal augments for Paprosky type 3 defects. *J Arthroplasty* 2018;33(3):823-8. <https://doi.org/10.1016/j.arth.2017.10.031>
9. Park MS, Kim KH, Jeong WC, Han SH. Cementless total hip arthroplasty with subtrochanteric transverse shortening osteotomy in Crowe type IV hip dysplasia. *J Arthroplasty* 2007;22(7):1031-6. <https://doi.org/10.1016/j.arth.2007.05.011>
10. Delp SL, Maloney W. Effects of hip center location on the moment-generating capacity of the muscles. *J Biomech* 1993;26(4-5):485-99. [https://doi.org/10.1016/0021-9290\(93\)90011-3](https://doi.org/10.1016/0021-9290(93)90011-3)
11. Makita H, Inaba Y, Hirakawa K, Saito T. Cementless total hip arthroplasty for Crowe type IV hip dysplasia: surgical technique and long-term results. *J Arthroplasty* 2012;27(5):860-6. <https://doi.org/10.1016/j.arth.2006.02.157>
12. Akbaba YA, Can A, Erdoğan, F. The outcome of total hip arthroplasty in patients with developmental dysplasia of the hip. *J Back Musculoskelet Rehabil* 2019;32(6):913-9. <https://doi.org/10.3233/BMR-181367>
13. Eskelinen A, Helenius I, Remes V, Ylinen P, Tallroth K, Paavilainen T. Cementless total hip arthroplasty in patients with high congenital hip dislocation. *J Bone Joint Surg Am* 2006;88(1):80-91. <https://doi.org/10.2106/JBJS.E.00037>
14. Smolders JM, Pakvis DF, Hendrickx BW, Verdonschot N, Van Susante JL. Periacetabular bone mineral density changes after resurfacing Hip arthroplasty versus conventional total hip arthroplasty. a randomized controlled DEXA study. *J Arthroplasty* 2013;28(7):1177-84. <https://doi.org/10.1016/j.arth.2012.08.025>