

# Modified Lemaire Lateral Extraarticular Tenodesis in Skeletally Immature Patients: Technical Note

Felipe Pauletti, J. Javier Masquijo

Department of Pediatric Orthopedics and Traumatology, Sanatorio Allende, Córdoba, Argentina.

## ABSTRACT

In recent years, the incidence of anterior cruciate ligament (ACL) injuries in skeletally immature athletes has increased exponentially. Although numerous techniques have been developed to stabilize the knee while minimizing the risk of physeal injury, ACL reconstruction in young patients remains associated with a high graft failure rate. The anterolateral ligament has recently gained considerable attention due to its role in anterolateral rotational stability. The objective of this article is to describe the surgical technique used by the authors to perform a combined ACL reconstruction and anterolateral tenodesis in patients with open physes who are at high risk of ACL re-tear.

**Keywords:** Modified Lemaire tenodesis; pediatric; anterolateral ligament; anterior cruciate ligament.

**Level of Evidence:** V

## Tenodesis extrarticular lateral de Lemaire modificada en pacientes esqueléticamente inmaduros.

### Nota técnica

## RESUMEN

La incidencia de lesiones del ligamento cruzado anterior en deportistas esqueléticamente inmaduros ha aumentado, de manera exponencial, en los últimos años. Si bien se han desarrollado numerosas técnicas que permiten estabilizar la rodilla minimizando el riesgo de lesión fisaria, la reconstrucción del ligamento cruzado anterior en pacientes jóvenes sigue vinculada a una alta tasa de fracaso del injerto. El ligamento anterolateral ha despertado un considerable interés recientemente debido a su papel en la estabilidad rotatoria anterolateral. El objetivo de este artículo es describir la técnica quirúrgica utilizada por los autores para realizar una reconstrucción combinada del ligamento cruzado anterior y tenodesis anterolateral en pacientes con fisis abiertas que presentan un riesgo elevado de re-rotura del ligamento cruzado anterior.

**Palabras clave:** Tenodesis de Lemaire; niños; ligamento anterolateral; ligamento cruzado anterior.

**Nivel de Evidencia:** V

## INTRODUCTION

The incidence of anterior cruciate ligament (ACL) injuries in skeletally immature athletes has increased exponentially in recent years.<sup>1,2</sup> Current literature favors early surgical management in children when the injury is complete and the knee is clinically unstable. Although numerous techniques have been developed to stabilize the knee while minimizing the risk of physeal injury, ACL reconstruction in young patients is still associated with a high rate of graft failure.<sup>3</sup> The anterolateral ligament (ALL) has recently attracted considerable interest due to its role in anterolateral rotational stability.<sup>4,5</sup> This has led surgeons to consider lateral extra-articular tenodesis (LET) and ALL reconstruction techniques as adjuncts to ACL reconstruction.

In biomechanical studies, both procedures have been shown to significantly reduce internal tibial rotation and anterolateral rotational instability. When combined with ACL reconstruction, they restore anterior tibial translation to levels comparable to those seen in healthy, native knees.<sup>6</sup>

Received on May 2<sup>nd</sup>, 2024. Accepted after evaluation on December 7<sup>th</sup>, 2024 • Dr. J. JAVIER MASQUIJO • javimasquijo@yahoo.com.ar  <https://orcid.org/0000-0001-9018-0612>

**How to cite this article:** Pauletti F, Masquijo JJ. Modified Lemaire Lateral Extraarticular Tenodesis in Skeletally Immature Patients: Technical Note. *Rev Asoc Argent Ortop Traumatol* 2025;90(1):97-102. <https://doi.org/10.15417/issn.1852-7434.2025.90.1.1954>

Clinical studies have demonstrated significant advantages, including lower graft rupture rates, improved knee stability, and higher rates of return to sports.<sup>7</sup>

Due to the proximity of the femoral insertion of the ALL, techniques commonly used in adults may pose a risk to the lateral physis of the distal femur in pediatric and adolescent patients.

The aim of this article is to describe the surgical technique used by the authors to perform a combined ACL and ALL reconstruction (LET) in patients with open physes who present a high risk of ACL re-tear.

## SURGICAL TECHNIQUE

### Indications

The authors' current indications for ACL reconstruction combined with LET in patients with open physes are: 1) Revision of a failed ACL reconstruction; 2) a high-grade pivot shift on clinical examination; 3) generalized ligamentous hyperlaxity; 4) high-performance athletes engaged in sports requiring pivoting movements.

### Description of the Procedure

The patient is placed in the supine position under spinal anesthesia, with a hemostatic cuff applied. A single dose of 1 g of cefazolin is administered preoperatively. Aseptic and antiseptic preparation is performed, and surgical drapes are placed according to standard technique. After exsanguinating the affected limb with an Esmarch bandage, a hemostatic cuff is inflated to 250 mmHg.

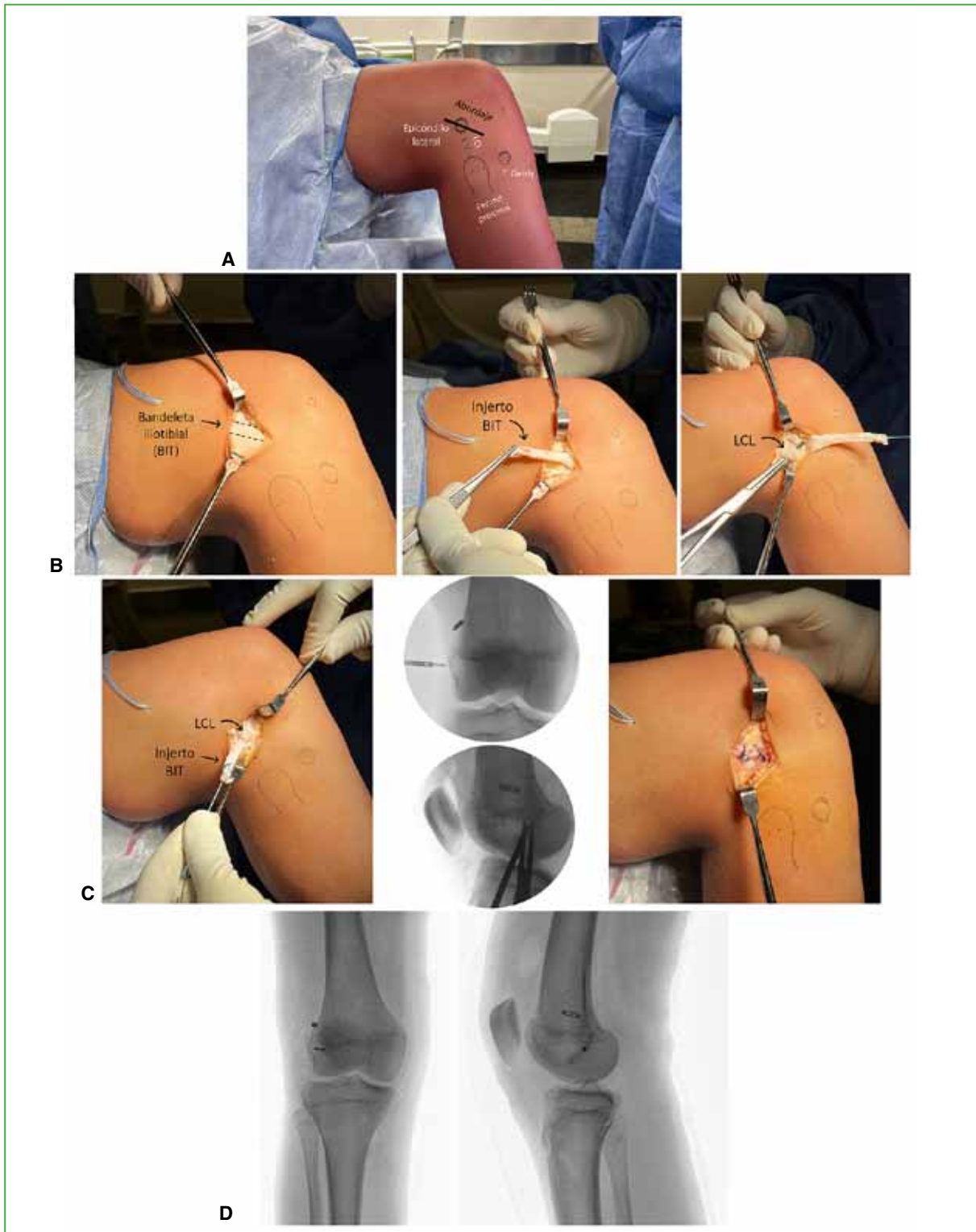
Following ACL reconstruction, the knee is positioned in approximately 80° of flexion, and a longitudinal incision of about 5 cm is made, 1 cm posterior to the lateral femoral epicondyle, starting 2 cm proximal to Gerdy's tubercle. If greater visualization is required, particularly in patients with abundant subcutaneous tissue, the incision can be extended proximally. The anterior and posterior borders of the iliotibial band (ITB) are dissected and identified. A strip of ITB measuring 6–8 cm in length and 1 cm in width is harvested from its posterior half, ensuring that the distal insertion at Gerdy's tubercle remains intact. A No. 1 Vicryl™ suture (Ethicon Inc., NJ, USA) is placed at the free end of the graft. The lateral collateral ligament (LCL) is identified by palpation with the leg in a figure-four position. Two small capsular incisions are made anterior and posterior to the proximal portion of the LCL, and a dissection is carried out from anterior to posterior to create a passage for the graft. It is crucial to remain extracapsular and avoid damaging the popliteus muscle or the LCL. The ITB graft is then passed under the LCL from distal to proximal using double utility forceps. The femoral fixation point is determined at the level of the lateral epicondyle, below the physis, using fluoroscopic guidance (Figure) A 3.5 mm or 2.8 mm titanium or bioabsorbable anchor is placed, depending on the patient's size. When inserting the anchor, care must be taken to avoid invading the physis or damaging the femoral attachment of the ACL, as the suspensory button anchor is in close proximity. With the knee flexed at 90° and the foot in neutral rotation to prevent overconstriction of the lateral compartment, the graft is held taut and secured with the anchor sutures. The wound is irrigated, hemostasis is confirmed, and the wound is closed in layers. The ITB is repaired with interrupted No. 1 Vicryl™ sutures up to the level of the transverse retinacular ligament.

### Postoperative Management

All patients follow the same rehabilitation program used after ACL reconstruction. This includes the use of a knee immobilizer and crutches for 10–14 days, with immediate partial weight-bearing (50% of body weight) and an allowed range of motion from 0° to 90° immediately after surgery. After the first two weeks, weight-bearing and range of motion are increased as tolerated. Rehabilitation focuses on maintaining full extension and promoting early quadriceps activation.

Cycling exercises are introduced approximately four weeks after surgery, along with a progressive strengthening program. Straight-line jogging and agility training begin at four months postoperatively, progressing to sport-specific training and jumping exercises.

At six months, patients undergo a functional return-to-sport assessment, which includes evaluations of range of motion, strength, thigh circumference, balance, and functional performance. Any identified deficiencies are addressed. Return to sport is gradual and typically begins between 10 and 12 months, depending on the results of the functional assessment.



**Figure.** Surgical technique. **A.** Anatomical parameters. **B.** Surgical approach, graft harvest and dissection of the lateral collateral ligament (LCL). **C.** Graft passage, fluoroscopy-guided femoral fixation and iliotibial band (ITB) closure. **D.** Immediate postoperative radiograph.

## DISCUSSION

This article describes the technique used by the authors to perform combined ACL and ALL reconstruction in patients with open physes who are at high risk of ACL re-tear. The surgical technique involves placing an iliotibial band graft as an anterolateral tenodesis, with a femoral fixation point guided by intraoperative fluoroscopy to avoid injuring the distal femoral physis or interfering with the ACL tunnel. The advantages and disadvantages of this procedure are summarized in [Table 1](#).

**Table 1.** Advantages and disadvantages of the combined anterior cruciate ligament and LET technique in skeletally immature high-risk patients.

Advantages	Disadvantages
Preserves the femoral and tibial physis.	Increases surgical time
Provides additional rotational stabilization	Requires an additional incision
Decreases the tear rate of the anterior cruciate ligament graft.	Overtightening of the tenodesis can lead to overconstriction of the knee and restriction of rotational motion.
	Intraoperative fluoroscopy required

LET = lateral extra-articular tenodesis.

The ALL is located in the lateral region of the knee, anterior to the LCL. Recent anatomical and biomechanical studies have highlighted the role of this extra-articular anterolateral structure and its synergistic relationship with the ACL in maintaining rotational stability of the knee. Although the specific indications for these procedures remain a topic of debate, recent studies suggest that this surgery significantly reduces the risk of ACL reconstruction failure.<sup>8,9</sup> In a randomized controlled trial, failure rates at two years were reported as 11% for primary ACL reconstructions using a hamstring autograft (semitendinosus/gracilis) and 4.5% for ACL reconstructions combined with LET (modified Lemaire technique), with no significant differences in patient-reported subjective outcomes.<sup>9</sup>

The addition of lateral extra-articular procedures has also been shown to be effective in pediatric patients, although the available literature on this population remains limited. A recent systematic review<sup>10</sup> analyzed 381 pediatric patients (mean age 11.73 years, range 5.6–16) with a mean follow-up of 50.1 months. The overall graft failure rate was 4.65% (range 0–13.6%), which is comparable to that reported for ACL plus LET reconstruction in adults. The return-to-sport rate was high (95.11%), with good functional scores (Lysholm mean 94.51 and Pedi-IKDC 93.39).

Although multiple studies have been conducted on the anatomy of the LCL, some controversy remains regarding its anatomical insertions. A pediatric cadaveric study<sup>11</sup> demonstrated that the popliteal insertion and the origin of the LCL are consistently distal to the distal femoral physis, suggesting that tunnels or drill holes should be positioned within the epiphysis. Due to the smaller size of pediatric knees, the proximity of the femoral tunnel for ACL reconstruction, and the undulating shape of the distal femoral physis, caution is necessary when securing the graft to the epiphysis. Our current preference is to use a 2.8 mm or 3.5 mm harpoon, which eliminates the need for a tunnel that could interfere with the ACL tunnel. The same study<sup>11</sup> also found that the iliotibial band insertion at Gerdy's tubercle had an inconsistent relationship with the physis, being proximal to the physis in six specimens and distal in three. For this reason, we currently prefer to leave the iliotibial band insertion intact and avoid additional tibial fixation.

It remains unclear whether performing LET in skeletally immature patients increases the risk of growth disturbances due to the forces exerted on the growth plate. In the same study by the SANTI group,<sup>10</sup> 1.9% of patients developed a coronal plane deformity, and 0.8% had a limb length discrepancy. The authors of this article are currently evaluating a series of 48 patients aged 13 to 18 years who underwent the described surgical procedure, with 61% being skeletally immature. None of these cases have shown angular deformities or limb length discrepancies.

In summary, this article presents a surgical technique for combined ACL reconstruction and anterolateral tenodesis in pediatric patients with open physes. We emphasize the importance of intraoperative fluoroscopy and precise anatomical knowledge of the distal femoral physis and ALL insertions to prevent complications related to physeal injury (Table 2). While preliminary results in this high-risk population are promising, further studies are needed to validate clinical outcomes and assess potential complications in this patient group.

**Table 2.** Important aspects to avoid complications.

Insufficient graft length (<6 cm) may hinder femoral fixation.

To avoid damage to the physis, epiphyseal femoral fixation should be performed under fluoroscopic control.

Consider the anatomy of the distal femoral physis (wavy shape) at the time of femoral fixation.

Fixation with a 3.5 mm anchor allows fixation of the graft in the epiphysis without the need for tunneling.

Avoid confluence of the anchor with the femoral tunnel of the anterior cruciate ligament.

If the tibia is in external rotation during LET tension and fixation, it may result in overconstriction of internal rotation of the knee.

If the tibia is in internal rotation, it may result in laxity of the graft and impede the protective effects of the LET.

LET = lateral extra-articular tenodesis.

Conflict of interest: The authors declare no conflicts of interest.

F. Pauletti ORCID ID: <https://orcid.org/0009-0000-3125-4714>

## REFERENCES

1. Dodwell ER, Lamont LE, Green DW, Pan TJ, Marx RG, Lyman S. 20 years of pediatric anterior cruciate ligament reconstruction in New York State. *Am J Sports Med* 2014;42(3):675-80. <https://doi.org/10.1177/0363546513518412>
2. Tepolt FA, Feldman L, Kocher MS. Trends in pediatric ACL reconstruction from the PHIS Database. *J Pediatr Orthop* 2018;38(9):e490-e494. <https://doi.org/10.1097/BPO.0000000000001222>
3. Andernord D, Desai N, Björnsson H, Ylander M, Karlsson J, Samuelsson K. Patient predictors of early revision surgery after anterior cruciate ligament reconstruction: a cohort study of 16,930 patients with 2-year follow-up. *Am J Sports Med* 2015;43(1):121-7. <https://doi.org/10.1177/0363546514552788>
4. Lutz C, Sonnery-Cottet B, Niglis L, Freychet B, Clavert P, Imbert P. Behavior of the anterolateral structures of the knee during internal rotation. *Orthop Traumatol Surg Res* 2015;101(5):523-8. <https://doi.org/10.1016/j.otsr.2015.04.007>
5. Sonnery-Cottet B, Lutz C, Daggett M, Dalmay F, Freychet B, Niglis L, et al. The involvement of the anterolateral ligament in rotational control of the knee. *Am J Sports Med* 2016;44(5):1209-14. <https://doi.org/10.1177/0363546515625282>
6. Geeslin AG, Moatshe G, Chahla J, Kruckeberg BM, Muckenhirn KJ, Dornan GJ, et al. Anterolateral knee extra-articular stabilizers: A robotic study comparing anterolateral ligament reconstruction and modified Lemaire lateral extra-articular tenodesis. *Am J Sports Med* 2018;46(3):607-16. <https://doi.org/10.1177/0363546517745268>
7. Aglietti P, Buzzi R, D'Andria S, Zaccherotti G. Long-term study of anterior cruciate ligament reconstruction for chronic instability using the central one-third patellar tendon and a lateral extraarticular tenodesis. *Am J Sports Med* 1992;20(1):38-45. <https://doi.org/10.1177/036354659202000111>

8. Getgood AMJ, Bryant DM, Litchfield R, Heard M, McCormack RG, Rezansoff A, et al. Lateral extra-articular tenodesis reduces failure of hamstring tendon autograft anterior cruciate ligament reconstruction: 2-year outcomes from the STABILITY study randomized clinical trial. *Am J Sports Med* 2020;48(2):285-97. <https://doi.org/10.1177/0363546519896333>
9. Sonnery-Cottet B, Saithna A, Cavalier M, Kajetanek C, Temponi EF, Daggett M, et al. Anterolateral ligament reconstruction is associated with significantly reduced ACL graft rupture rates at a minimum follow-up of 2 years: A prospective comparative study of 502 patients from the SANTI Study Group. *Am J Sports Med* 2017;45(7):1547-57. <https://doi.org/10.1177/0363546516686057>
10. Carrozzo A, Monaco E, Saithna A, Annibaldi A, Guy S, Ferreira A, et al. Clinical outcomes of combined anterior cruciate ligament reconstruction and lateral extra-articular tenodesis procedures in skeletally immature patients: A systematic review from the SANTI Study Group. *J Pediatr Orthop* 2023;43(1):24-30. <https://doi.org/10.1097/BPO.0000000000002236>
11. Randhawa S, Stavinoha TJ, Trivedi S, Ganley TJ, Tompkins M, Ellis H, et al. Paediatric reference anatomy for ACL reconstruction and secondary anterolateral ligament or lateral extra-articular tenodesis procedures. *J ISAKOS* 2022;7(6):206-13. <https://doi.org/10.1016/j.jisako.2022.04.008>