

Extraforaminal L5-S1 Disc Herniation Treated by Endoscopic Transfacet Approach. Case Report and Technical Note

Máximo de Zavalía, Enrique Gobbi, Santiago Yeregui

Spine Unit, Orthopedics and Traumatology Service, Hospital Universitario CEMIC, Grupo Médico Vertebral, Autonomous City of Buenos Aires, Argentina

ABSTRACT

Extraforaminal L5-S1 disc herniations are usually difficult to treat due to their complicated access and risk of nerve injury. We present the case of a patient with left L5-S1 disc disease who was treated by endoscopic discectomy using a transfacet Wiltse-like approach. This method provides safe access to L5-S1 extraforaminal herniations while avoiding manipulation and irritation of the L5 root.

Keywords: Endoscopy; minimally invasive; spine; lumbar; disc disease.

Level of Evidence: IV

Hernia extraforaminal en el espacio L5-S1 tratada por abordaje transfacetario endoscópico. Presentación de un caso y nota técnica

RESUMEN

Las hernias de disco extraforaminales en el espacio L5-S1 suelen ser difíciles de tratar por su complicado acceso y el riesgo de lesión nerviosa. Se presenta el caso de un paciente con discopatía en L5-S1 izquierda que fue tratado mediante discectomía endoscópica por abordaje símil Wiltse transfacetario. Este tipo de abordaje permite el acceso seguro a las hernias extraforaminales en el espacio L5-S1 evitando la manipulación e irritación de la raíz de L5.

Palabras clave: Endoscopia; abordaje mínimamente invasivo; columna vertebral; lumbar; discopatía.

Nivel de Evidencia: IV

INTRODUCTION

Lateral disc herniations account for 1% to 12% of all lumbar herniations¹ and can be classified as intraforaminal or extraforaminal, according to their location with respect to the foramen.² The latter were first described by Abdullah et al. in 1974 and are more frequent in older patients, with L4-L5 often being the most affected level.^{3,4}

Surgical treatment of these disc lesions is usually more difficult than that of central herniations, especially in the L5-S1 space, where access is more complex, mainly due to the height of the iliac crests and the volume of the L5 transverse process.⁵ Currently, the surgical options for this type of lesions include the classic discectomy via the posterolateral Wiltse approach,⁶⁻¹⁰ minimally invasive techniques, such as tubular microdiscectomy via a homolateral or contralateral approach,^{5,11} and an increasing number of endoscopic discectomy techniques, such as the contralateral interlaminar approach and access to the foramen.¹²

Endoscopic surgery has several advantages over other techniques, including reduced bleeding, preservation of the paravertebral musculature, and shorter hospitalization.¹² There are several approaches to accessing the disc herniation in the L5-S1 space: contralateral extraforaminal, transiliac, and posterolateral, which can be performed with or without drilling the facet. The main complications of these techniques are postoperative pain, transient paresis, and nerve injury caused by manipulation of the L5 root.

Received on November 27th, 2023 Accepted after evaluation on December 16th, 2023 • Dr. MÁXIMO DE ZAVALÍA • maximodezavalia@gmail.com  <https://orcid.org/0000-0002-4022-4100>

How to cite this article: de Zavalía M, Gobbi E, Yeregui S. Extraforaminal L5-S1 Disc Herniation Treated by Endoscopic Transfacet Approach. Case Report and Technical Note. *Rev Asoc Argent Ortop Traumatol* 2024;89(1):70-75. <https://doi.org/10.15417/issn.1852-7434.2024.89.1.1856>

We present the case of a patient who underwent endoscopic treatment for an extraforaminal herniation in the L5-S1 space via a posterolateral approach with facet drilling. Because experience and knowledge of this technique are limited in our country, a literature review was conducted.

CLINICAL CASE

A 45-year-old man came in for a consultation due to a left radiculopathy of L5 that had been developing for seven months (visual analog scale 8/10). On physical examination, range of motion and strength were preserved, and there were no motor deficits. On MRI, an extraforaminal herniation was visualized in the L5-S1 space on the left side (Figure 1). The patient reported having undergone 20 sessions of physical therapy, two selective root blocks of L5-S1 and having received treatment with pregabalin 75 mg for three months, with improvement in symptoms, but of short duration. In the absence of a response to conservative treatment, an endoscopic discectomy was proposed.

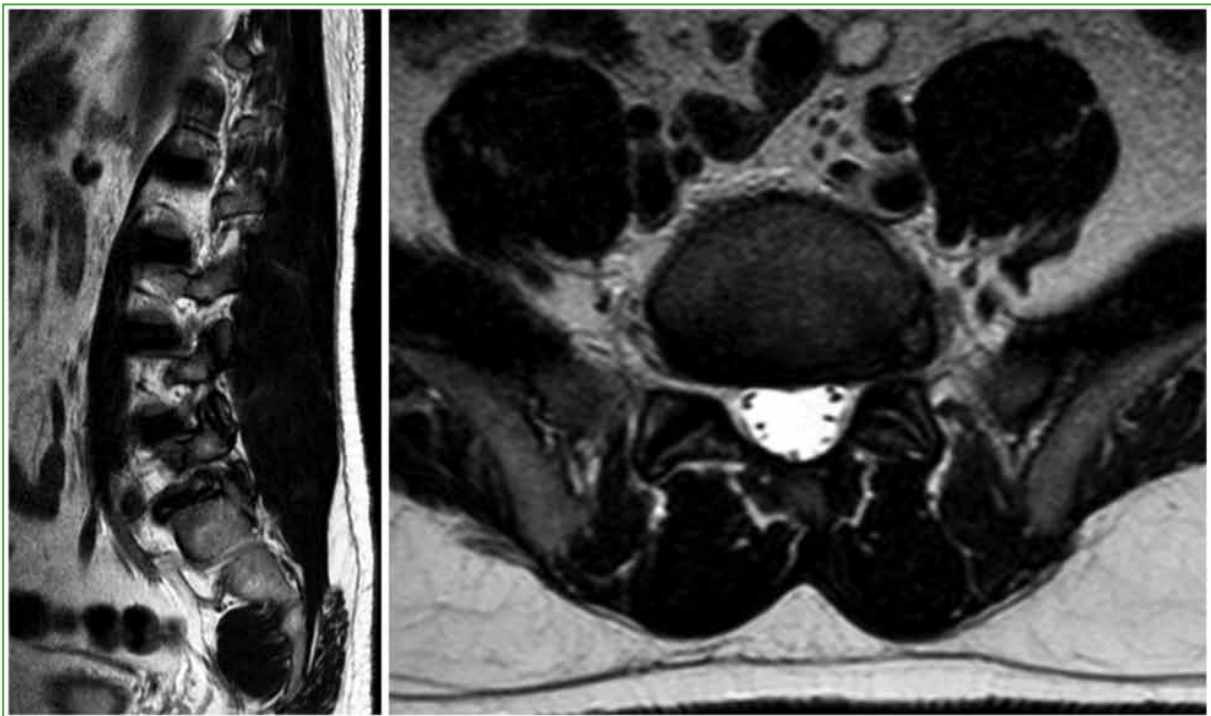


Figure 1. Magnetic resonance imaging of the lumbosacral spine, sagittal and axial sections. An extraforaminal hernia is observed in the L5-S1 space on the left side.

Surgical technique

Under general anesthesia, the patient is placed in the ventral decubitus position. Chlorhexidine is applied for skin asepsis before surgical fields are set up for the posterior lumbar approach. Using direct fluoroscopy in the antero-posterior position, the left tip of the superior articular facet of S1 is marked with a 16 G needle (Figure 2). An 8 mm skin incision is performed, followed by the opening of the lumbar fascia. The working cannula is then lowered together with an Elliquence® transforaminal endoscope with a 30° lens. The S1 facet is drilled laterally with an endoscopic drill bit. As space is created in the ventral direction, the working cannula is lowered. Once the anterior cortex of the facet is located, it is resected with 3 mm Kerrison Rongeur forceps. Then, a fluoroscopic control is performed to ensure the correct working direction (Figure 3).

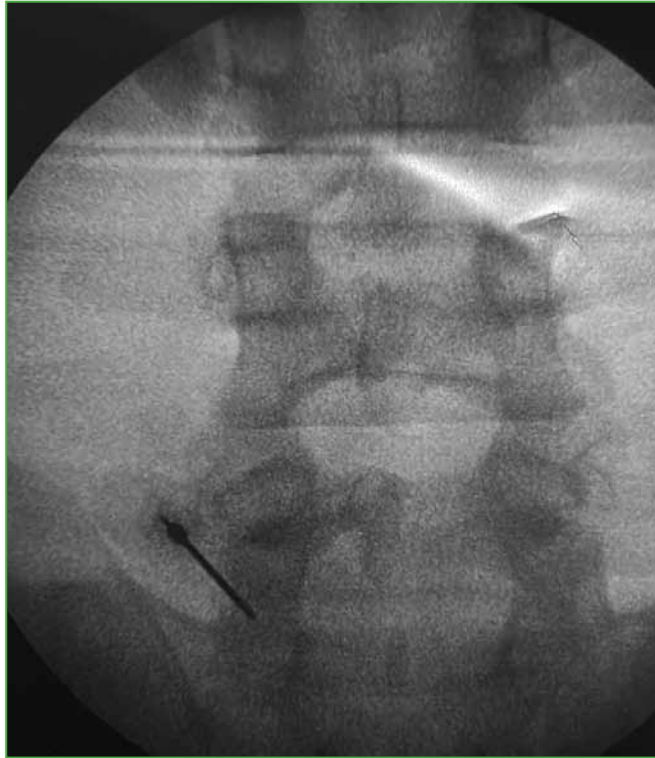


Figure 2. Fluoroscopic control of the left marking of the superior articular facet of S1 with a 16 G needle.

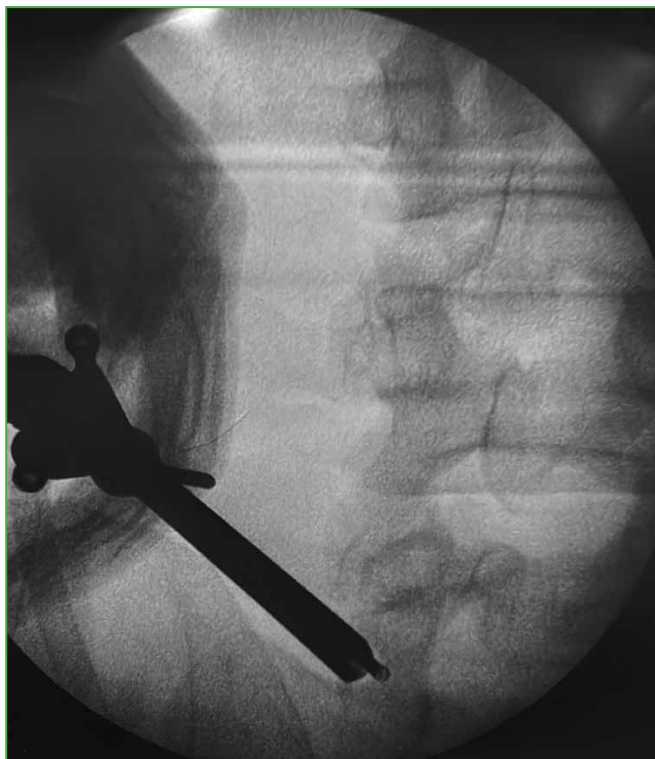

Figure 3. Fluoroscopy ensures the correct working direction.

The extruded disc fragment is palpated in the extraforaminal space using a bone hook (Figure 4). The extruded fragment is excised with disc forceps (Figure 5) and the correct release of the L5 root is verified (Figure 6 and Video).

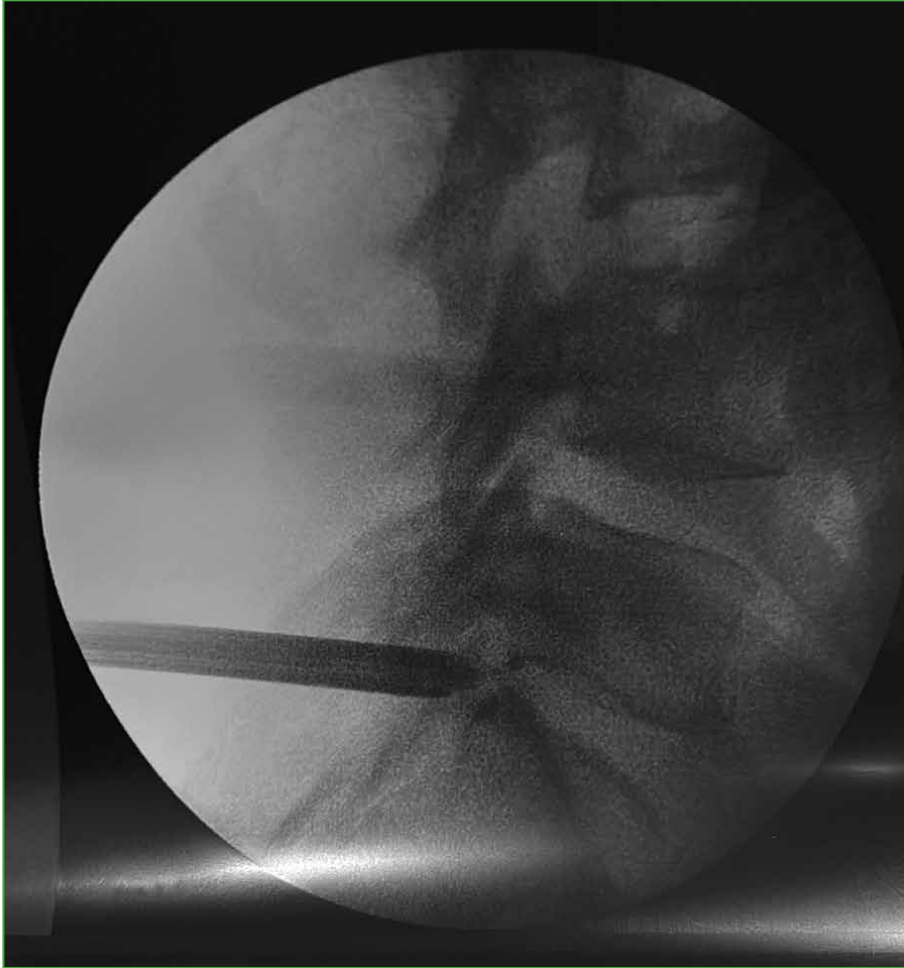


Figure 4. Fluoroscopy showing the palpation of the disc fragment.

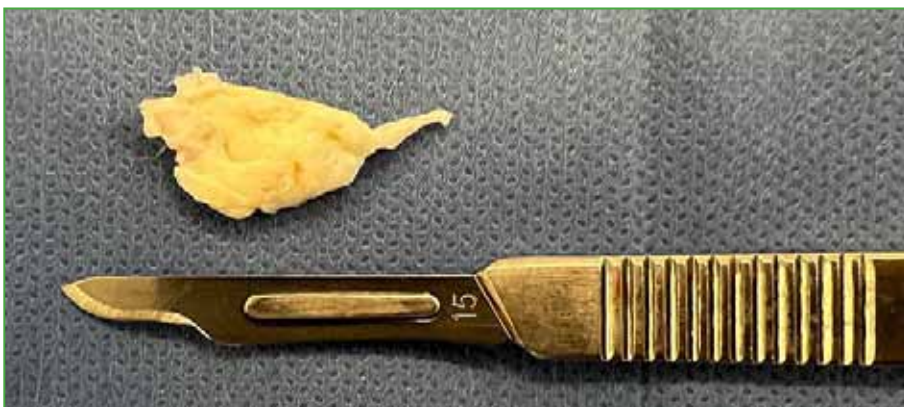


Figure 5. Fragment of the extracted disc.

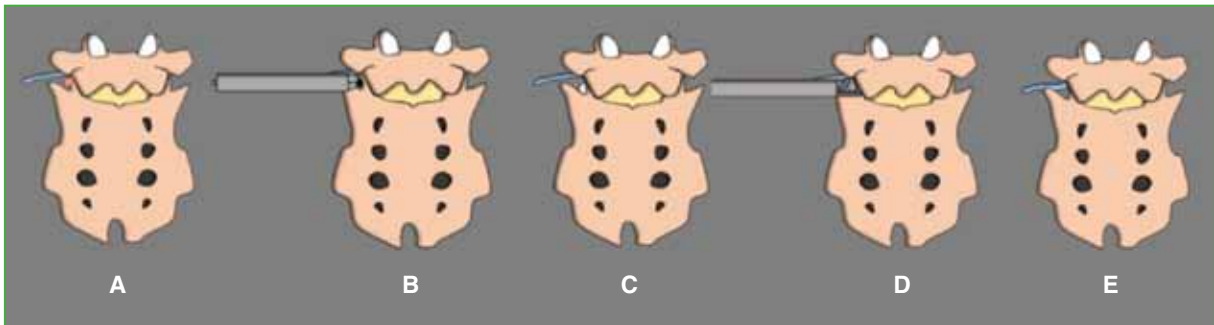


Figure 6. A. Lateral identification of the superior articular facet of S1. B. Drilling of the facet from lateral to medial and in the ventral direction. C. Visualization of the extruded disc fragment. D. Disc fragment excision. E. Free L5 root.

Clinical evolution

The patient recovered from anesthesia without complications in the immediate postoperative period. Regarding pain, he reported the absence of radiculopathy immediately after surgery and was discharged 12 hours later. The radicular visual analog scale score was 1/10 after one month and 1/10 after three months. There was no recurrence of symptoms or low back pain five months after surgery.

DISCUSSION

Foraminal and extraforaminal herniated discs have specific clinical manifestations that include, in particular, severe root pain.¹ The dorsal root ganglion has been identified as one of the causes of the above symptoms.^{13,14} Treatment for herniated discs aims to achieve nerve decompression with as little trauma as possible. This objective can become challenging when dealing with foraminal or extraforaminal herniations, and it becomes even more difficult when the affected level is L5-S1, due to the anatomical particularities of the segment, such as the high iliac crest and frequent foraminal narrowing at that level.¹⁵ Endoscopic discectomy by interlaminar approach is often a solution that allows for overcoming these anatomical barriers.¹⁶ However, this approach is usually more appropriate for treating axillary disc herniations or migrated hernias. On the other hand, the transforaminal approach may be an option to treat foraminal or extraforaminal hernias; however, it is not easily accessible in patients with high iliac crests or transverse mega-apophysis (Castellvi 2, 3 and 4).¹⁷ The conventional open transfacet approach has been widely used in spine surgery, because it is suitable for disc decompression involving the ventral dural sac and hypertrophic ligamentum flavum.¹⁸ In our case, we used this approach endoscopically, which allowed us to access the hernia more easily.

The key to the success of this technique is to create a precise and adequate working space while keeping the segment mechanically stable. The use of the drill allows us to have more working space in an area without the risk of injuring nerve or vascular structures. However, care must be taken with bone resection to reduce the probability of segmental instability, which is avoided by carefully controlling the direction of work under fluoroscopy and attempting the smallest possible resection. In our case, we resected approximately 15% of the facet, which allowed us to generate a good working space without destabilizing the segment.

In a patient with an extraforaminal disc herniation in the L5-S1 space, we opted for an endoscopic discectomy via the posterolateral transfacet approach using a drill, and the postoperative outcome was satisfactory.

CONCLUSIONS

The endoscopic approach allows safe access to extraforaminal hernias in the L5-S1 space, avoiding manipulation and irritation of the L5 root. Therefore, we believe this technique is a safe option to consider when treating this type of hernia.

Conflict of interest: The authors declare no conflicts of interest.

E. Gobbi ORCID ID: <https://orcid.org/0000-0001-7310-6170>

S. Yeregui ORCID ID: <https://orcid.org/0009-0005-8992-0368>

REFERENCES

- Jang JS, An SH, Lee SH. Transforaminal percutaneous endoscopic discectomy in the treatment of foraminal and extraforaminal lumbar disc herniations. *J Spinal Disord Tech* 2006;19(5):338-43. <https://doi.org/10.1097/01.bsd.0000204500.14719.2e>
- Postacchini F, Cinotti G, Gumina S. Microsurgical excision of lateral lumbar disc herniation through an interlaminar approach. *J Bone Joint Surg Br* 1998;80(2):201-7. <https://doi.org/10.1302/0301-620x.80b2.8163>
- Abdullah AF, Ditto EW 3rd, Byrd EB, Williams R. Extreme-lateral lumbar disc herniations. Clinical syndrome and special problems of diagnosis. *J Neurosurg* 1974;41(2):229-34. <https://doi.org/10.3171/jns.1974.41.2.0229>
- Siebner HR, Faulhauer K. Frequency and specific surgical management of far lateral lumbar disc herniations. *Acta Neurochir (Wien)* 1990;105(3-4):124-31. <https://doi.org/10.1007/BF01669995>
- Yeom JS, Kim KH, Hong SW, Park KW, Chang BS, Lee CK, et al. A minimally invasive technique for L5-S1 intraforaminal disc herniations: microdiscectomy with a tubular retractor via a contralateral approach. *J Neurosurg Spine* 2008;8(2):193-8. <https://doi.org/10.3171/SPI/2008/8/2/193>
- Garrido E, Connaughton PN. Unilateral facetectomy approach for lateral lumbar disc herniation. *J Neurosurg* 1991;74(5):754-6. <https://doi.org/10.3171/jns.1991.74.5.0754>
- Jane JA, Haworth CS, Broaddus WC, Lee JH, Malik J. A neurosurgical approach to far-lateral disc herniation. Technical note. *J Neurosurg* 1990;72(1):143-4. <https://doi.org/10.3171/jns.1990.72.1.0143>
- Kunogi J, Hasue M. Diagnosis and operative treatment of intraforaminal and extraforaminal nerve root compression. *Spine (Phila Pa 1976)* 1991;16(11):1312-20. <https://doi.org/10.1097/00007632-199111000-00012>
- Müller A, Reulen HJ. A paramedian tangential approach to lumbosacral extraforaminal disc herniations. *Neurosurgery* 1998;43(4):854-61; discussion 861-2. <https://doi.org/10.1097/00006123-199810000-00077>
- O'Brien MF, Peterson D, Crockard HA. A posterolateral microsurgical approach to extreme-lateral lumbar disc herniation. *J Neurosurg* 1995;83(4):636-40. <https://doi.org/10.3171/jns.1995.83.4.0636>
- Kapetanakis S, Gkasdaris G, Angoulas AG, Givissis P. Transforaminal percutaneous endoscopic discectomy using transforaminal endoscopic spine system technique: Pitfalls that a beginner should avoid. *World J Orthop* 2017;8(12):874-80. <https://doi.org/10.5312/wjo.v8.i12.874>
- Yeung AT, Tsou PM. Posterolateral endoscopic excision for lumbar disc herniation: Surgical technique, outcome, and complications in 307 consecutive cases. *Spine (Phila Pa 1976)* 2002;27(7):722-31. <https://doi.org/10.1097/00007632-200204010-00009>
- Kikuchi S, Sato K, Konno S, Hasue M. Anatomic and radiographic study of dorsal root ganglia. *Spine (Phila Pa 1976)* 1994;19(1):6-11. <https://doi.org/10.1097/00007632-199401000-00002>
- Vanderlinden RG. Subarticular entrapment of the dorsal root ganglion as a cause of sciatic pain. *Spine (Phila Pa 1976)* 1984;9(1):19-22. <https://doi.org/10.1097/00007632-198401000-00006>
- Dasenbrock HH, Juraschek SP, Schultz LR, Witham TF, Sciubba DM, Wolinsky JP, et al. The efficacy of minimally invasive discectomy compared with open discectomy: a meta-analysis of prospective randomized controlled trials. *J Neurosurg Spine* 2012;16(5):452-62. <https://doi.org/10.3171/2012.1.SPINE11404>
- Wang B, Lü G, Patel AA, Ren P, Cheng I. An evaluation of the learning curve for a complex surgical technique: the full endoscopic interlaminar approach for lumbar disc herniations. *Spine J* 2011;11(2):122-30. <https://doi.org/10.1016/j.spinee.2010.12.006>
- Nie H, Zeng J, Song Y, Chen G, Wang X, Li Z, et al. Percutaneous endoscopic lumbar discectomy for L5-S1 disc herniation via an interlaminar approach versus a transforaminal approach: A prospective randomized controlled study with 2-year follow up. *Spine (Phila Pa 1976)* 2016;41 Suppl 19:B30-B37. <https://doi.org/10.1097/BRS.0000000000001810>
- Yang X, Liu X, Zheng Y. Surgical treatment of thoracic disc herniations using a modified transfacet approach. *Indian J Orthop* 2014;48(2):158-62. <https://doi.org/10.4103/0019-5413.128756>