

# Dermatraction: A Retrospective Study on its Effectiveness in the Closure of Soft Tissue Leg Defects

Pablo Carranza,\* Faustino Krause,\*\* Adali Otero,\*\* José L. Bottarelli,\*\* Federico Plana\*\*

\*Lower Limb Reconstructive Surgery Department, Orthopedics and Traumatology Service, Hospital Privado SADIV, Buenos Aires, Argentina

\*\*Lower Limb Reconstructive Surgery Department, Orthopedics and Traumatology Service, Hospital Interzonal General de Agudos "Prof. Dr. Luis Güemes", Buenos Aires, Argentina

## ABSTRACT

**Introduction:** Viscoelasticity is a distinctive characteristic of the human skin. A constant force pulling on the skin and subcutaneous tissue allows it to cover exposed areas in relatively short periods of time. The objective of this study is to analyze a series of cases with soft tissue leg defects where integumentary closure was accomplished with a skin stretching technique using 'traction bands' in order to determine which injuries can benefit from this treatment. **Materials and Methods:** This is a retrospective, descriptive, longitudinal study carried out in the period between 2012 and 2019. The inclusion criteria for this study were: 1) wounds with a soft-tissue coverage deficit in the leg of diverse traumatic etiology (surgical wound dehiscence, fasciotomies due to compartment syndrome, open fractures, and open wounds with soft tissue deficit). **Results:** 36 patients (mean age: 28 years) with injuries with loss of coverage in different regions of the leg were analyzed. Closure was achieved in 27 patients (75%), without the need for additional procedures. In three patients (8.3%), the exposed area was reduced, requiring skin grafting as a complementary procedure. Six patients required myocutaneous and fasciocutaneous soft tissue reconstructive procedures. **Conclusions:** This technique is effective, simple, and economical for closing complex wounds and/or fasciotomies. Dermatraction allows closure a few days after the trauma.

**Keywords:** Coverage defect; open wound; traction bands; viscoelasticity; integumentary closure.

**Level of Evidence:** IV

## Dermotracción por bandas: estudio retrospectivo sobre su efectividad en el cierre diferido de defectos de cobertura en la pierna

## RESUMEN

**Introducción:** Una propiedad característica del tegumento humano es la viscoelasticidad. La piel y el tejido celular subcutáneo traccionados por una fuerza constante pueden llegar a cubrir áreas expuestas en lapsos relativamente breves. El objetivo de este estudio fue analizar una serie de casos con defectos de cobertura de la pierna. Se realizó la síntesis tegumentaria con técnica de dermatracción mediante "bandas de tracción", con la finalidad de poder precisar qué lesiones pueden beneficiarse de este método. **Materiales y Métodos:** Estudio retrospectivo, descriptivo, longitudinal realizado entre 2012 y 2019. Los criterios de inclusión fueron: 1) heridas con déficit de cobertura tegumentaria en la pierna, de etiología traumática diversa (dehiscencia de abordajes quirúrgicos, fasciotomías por síndrome compartimental, fracturas expuestas y heridas abiertas con déficit de partes blandas). **Resultados:** Se analizó a 36 pacientes (edad promedio 28 años) que tenían lesiones con pérdida de cobertura localizadas en distintas regiones de la pierna. En 27 pacientes (75%), se logró el cierre sin necesidad procedimientos complementarios. En el 8,3%, se logró la reducción del área expuesta y fue necesario un procedimiento complementario (injerto de piel). Seis pacientes requirieron técnicas reconstructivas de partes blandas miocutáneas y fasciocutáneas. **Conclusiones:** Esta técnica es efectiva, simple y económica para lograr el cierre diferido de las heridas complejas o fasciotomías. La dermatracción permite el cierre diferido en pocos días luego del trauma.

**Palabras clave:** Defecto de cobertura; herida abierta; bandas de tracción; viscoelasticidad; síntesis tegumentaria.

**Nivel de Evidencia:** IV

Received on August 6<sup>th</sup>, 2023 Accepted after evaluation on February 17<sup>th</sup>, 2024 • Dr. PABLO CARRANZA • cabrusof@hotmail.com  <https://orcid.org/0009-0008-7375-4694>

**How to cite this article:** Carranza P, Krause F, Otero A, Bottarelli JL, Plana F. Dermatraction: A Retrospective Study on its Effectiveness in the Closure of Soft Tissue Leg Defects. *Rev Asoc Argent Ortop Traumatol* 2024;89(2):150-157. <https://doi.org/10.15417/issn.1852-7434.2024.89.2.1805>

## INTRODUCTION

Viscoelasticity is a distinctive characteristic of the human skin. A constant force pulling on the skin and subcutaneous tissue allows it to cover exposed areas in relatively short periods of time.<sup>1</sup> At the same time, the constantly tractioned skin will progressively elongate, reducing the tension to which it was subjected: this phenomenon is called “stress relaxation”.<sup>2</sup>

In the context of high-energy trauma, complex wounds characterized by exposure of the deep planes are frequent, often with integumentary deficits that make primary synthesis impossible.

Reconstructive surgery has a long learning curve, reflecting the difficulty and complexity of the procedures available for extensive wound coverage. Reconstructive procedures, such as free or rotation flaps, are not only technically more demanding, but also take longer, cost more, and are associated with significant complications and donor site morbidity.

Traditionally, surgeons attempted wound synthesis with as simple a procedure as possible, and its complexity increased with the evolution of each individual case, as the wounds became more complex.<sup>3</sup> Today, some surgical schools prefer to use less technically complex reconstructive procedures in the acute phase.<sup>4</sup>

The aim of this study was to analyze a series of cases with coverage defects in different regions of the leg where skin closure was accomplished using the dermatraction technique with “traction bands”, in order to determine which wounds can benefit from this method.

## MATERIALS AND METHODS

A retrospective, descriptive, longitudinal study was conducted between 2012 and 2019. The inclusion criteria were: 1) wounds with soft tissue coverage deficits in the leg caused by diverse traumatic etiologies (dehiscence of surgical approaches, fasciotomies due to compartment syndrome, open fractures, and open wounds with soft tissue deficit), and 2) complete follow-up in hospital records.

All patients were operated on by the same surgical team, trained in traumatic pathology of the lower limbs following the same therapeutic guidelines.

### Initial wound management

On admission, all patients underwent wound cleaning and treatment with a vacuum aspiration system. Depending on the availability of each case, portable industrial equipment at 100 mmHg was used intermittently for 5-10 days until granulation was achieved, or homemade equipment with polyurethane sponge, suction cannula, transparent nylon film, and suction connection at the patient’s bed. If the patient had an underlying infection, antibiotics were administered according to the culture report.

### Debridement

Once the vacuum suction system was removed, systematic debridement was performed, paying special attention to the regularization of the skin edges to a bleeding plane.

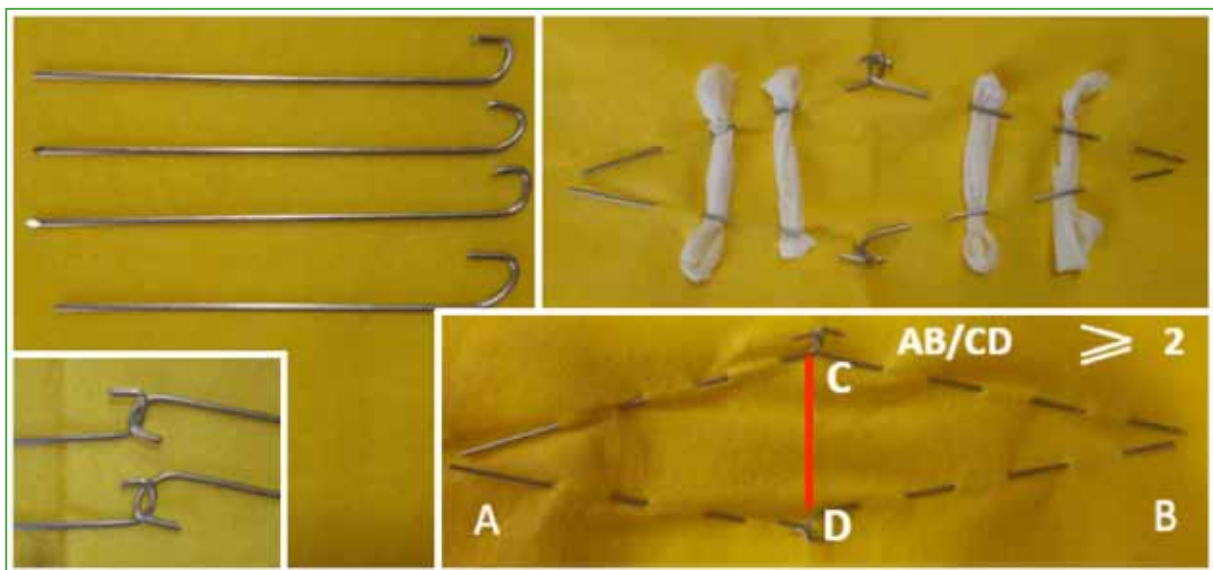
### Surgical technique and threading

Four standard-length Kirschner pins, 1.5-1.8 mm in diameter, were used, two on each side of the wound, although sometimes, in smaller wounds, the procedure was performed with two pins. The pins were inserted through the skin and subcutaneous tissue, parallel to and about 1 cm from the incision margin. The contiguous ends of each pin in the middle of the wound were bent into a hook shape and joined together forming a hinge, while the far ends were left free or secured to the pin at the opposite skin edge with a nylon suture. Surgical glove rims were used as traction bands, placed underneath the Kirschner pins and tied to the opposite side in tension. Once the skin edges were satisfactorily opposed and tension-free, the Kirschner pins and traction bands were removed and the wound was sutured at the same time (Table 1).

**Table 1.** Technical tips for proper wound closure.

- Debride the edges before placing the Kirschner pins.
- Place the pins only in the skin and subcutaneous tissue.
- Prevent the formation of inverted skin edges.
- If the injury is in an articular area, we recommend immobilizing it.
- If areas of traction necrosis are observed, remove the pins.

The number of traction bands used depends on the size of the wound (Figure 1).



**Figure 1.** Hook-shaped pins at one end. Placement of the pins 1 cm from the skin margin, arrangement of traction bands between opposing pins. Better results were observed when the AB length exceeded twice the CD length.

Generally, small wounds up to approximately 6 cm require two traction bands and larger wounds require three or four.

The magnitude of the tension applied to the traction band is determined manually; there are no instruments available to measure the tension at the edges. The tension is determined by the following factors: a) the flap's distensibility when mobilized (clinical mobility of the skin next to the wound), b) avoiding flap pallor, and c) limiting tension when pain arises.

In general, 50% of the defect can be closed in 48 hours, but we do not encourage hurrying the procedure; traction adjustment of the bands is performed at the patient's bedside after 48 hours.

Once the patient was discharged, outpatient controls were performed 10 days after the removal of the pins, and one month, two months, three months, and six months later, followed by a yearly control (Table 2).

**Table 2.** Strengths of the surgical technique

- Simple method. The learning curve is relatively fast
- Can be performed under local anesthesia
- It is economical
- Achieves closure of most wounds
- Does not preclude the use of other reconstructive procedures.
- Avoids donor site morbidity
- Can be used in infected wounds after debridement.

## RESULTS

Thirty-six patients were analyzed (mean age: 28 years; range 19-37) who suffered injuries with loss of soft tissue coverage located in different regions of the leg. Twenty-seven were men and six were women. The pathogenesis of the injuries was as follows: fasciotomy due to compartment syndrome (12 cases, 33%), exposed Gustilo IIIb fractures (9 cases, 25%), dehiscence of surgical wounds due to fibula osteosynthesis (8 cases, 22%), full-thickness skin tears (7 cases, 20%).

In 27 patients (75%), closure was achieved without the need for complementary procedures. In three patients (8.3%), reduction of the exposed area was achieved with a skin graft. These patients had large wounds in regions close to the knee.

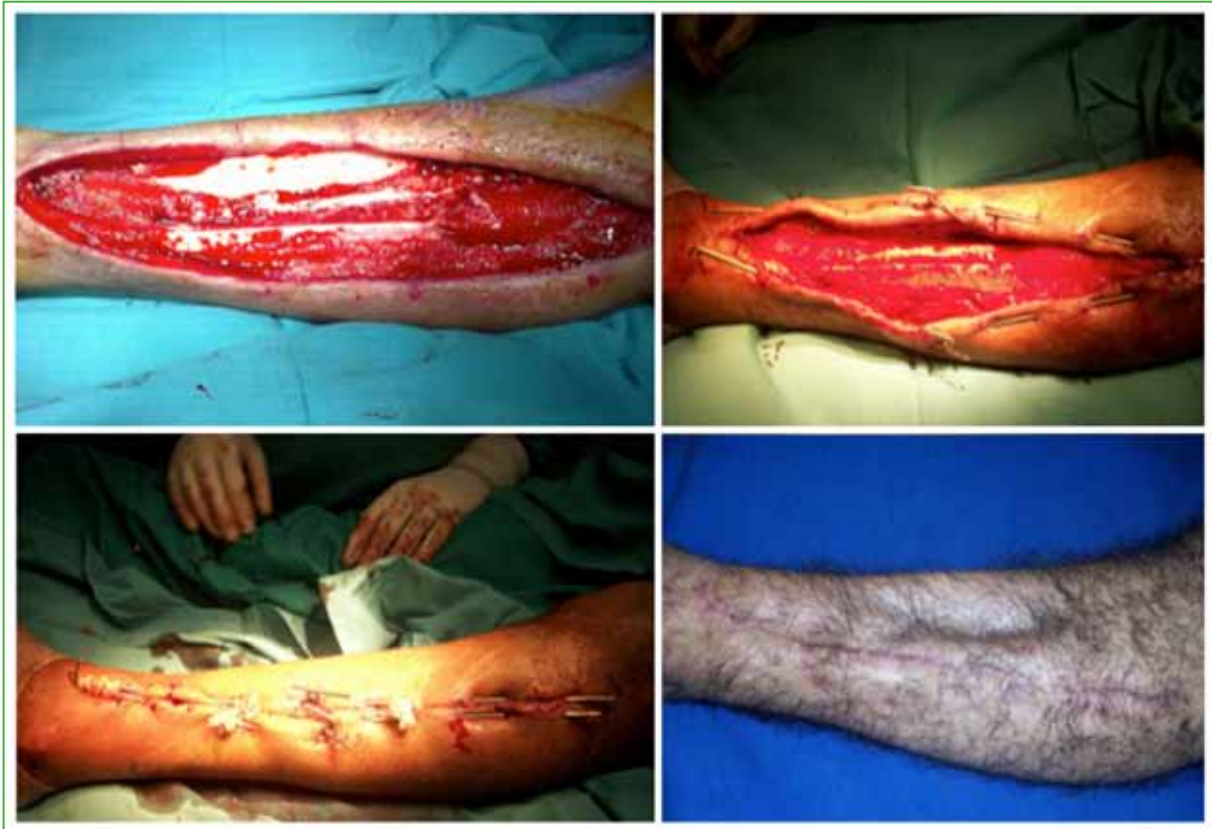Six patients required myocutaneous and fasciocutaneous reconstructions, all of whom had sustained high-energy injuries with significant soft tissue loss. When performing the initial cleaning, we observed a great compromise of the tissues around the injury and poor vascularity in the underlying muscle. In these cases, we made a new evaluation when removing the suction system, where the vascular status was evaluated by observation along with the state of the tissues at the site of the injury. We noticed that the skin's elongation capacity was limited due to substance loss, aggressive cleaning, and fibrosis; thus, we opted for reconstructive techniques with the following procedures: gastrocnemius rotational flap (8.3%), associated gastrocnemius and soleus flaps (5.6%) and anterolateral thigh free flap (2.8%).

The procedure was always successful when applied to cases of dehiscence and fasciotomy and failed in patients with exposed fractures or full-thickness skin tears.

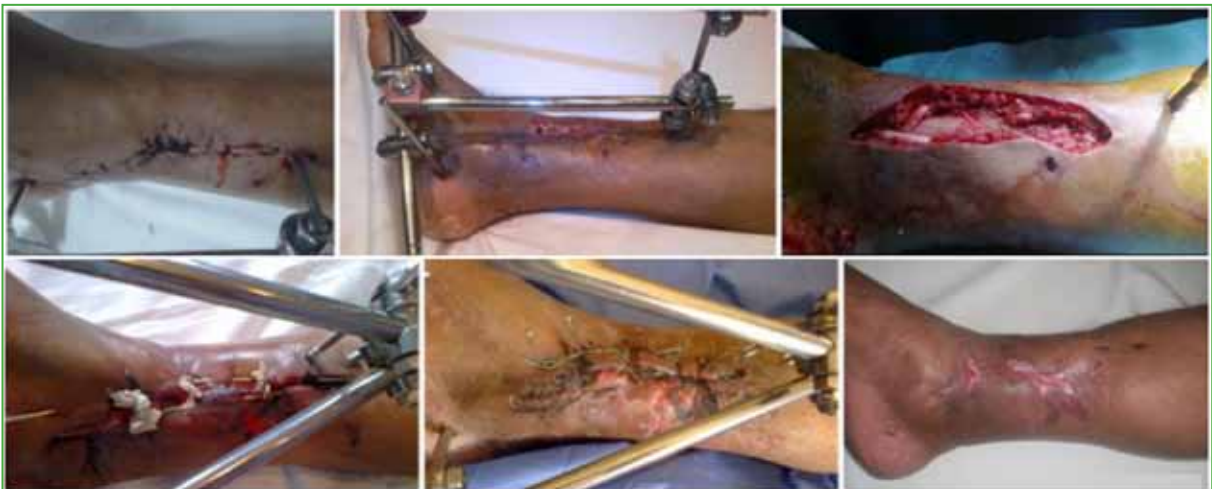Six (16.6%) infections were recorded: three in patients with open fractures, the microorganisms found were: *Staphylococcus aureus* (2 cases), enterococcus (1 case), *S. aureus* in the dehiscence of a fibula wound (1 case) and *Pseudomonas aeruginosa* in full-thickness skin tears (2 cases). All patients were treated according to sensitivity testing. The infection did not interfere with the application of the method.

Although the aesthetic outcome is not the procedure's primary goal, the patients treated reported a high level of satisfaction.

Three cases are illustrated: two with four pins (Figures 2 and 3) and one with two pins (Figure 4).

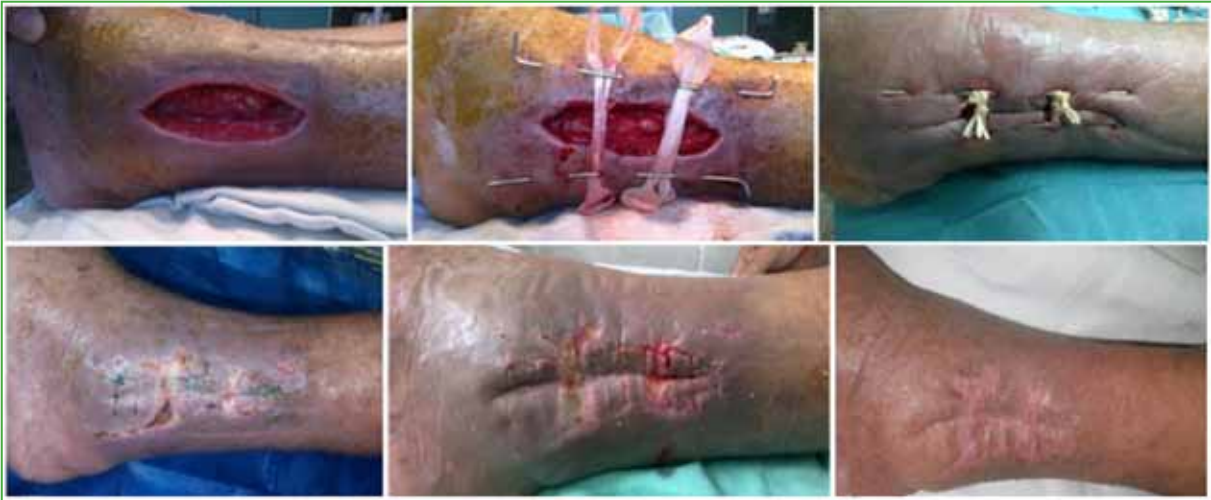

**Figure 2.** 18-year-old male, with traumatic posterior dislocation of the knee with vascular compromise and subsequent compartment syndrome. A femoral-tibial bypass with contralateral reversed internal saphenous vein and decompressive fasciotomy were performed. After healing of an infection, closure with pins was performed.



**Figure 3.** 22-year-old male with an open tibial plafond fracture and an ongoing infection in the open wound. A mechanical-surgical cleaning was performed and treated with a vacuum aspiration system. The external fixator was repositioned and the wound was closed with this pin method.





**Figure 4.** 35-year-old man with an operated ankle fracture. The wound presents dehiscence with exposure of the surgical material. The material is removed, the wound is treated with a vacuum aspiration system and closed with two pins.

## DISCUSSION

The literature describes numerous complex leg wound closure techniques that use a variety of materials ranging from surgical tapes, skin staples, and subcutaneous sutures to more sophisticated, high-cost devices that have evident limitations in their application. Few studies describe the use of Kirschner pins for skin closure.<sup>5,6</sup> It is a simple method that, if unsuccessful, does not result in significant difficulties for local or free flaps. It is extremely useful to describe and incorporate simple surgical techniques for the treatment of severe soft tissue defects, because it has made a true solution available to everyone in our environment, significantly broadening the horizons in this field, extending indications, and improving functional and aesthetic outcomes.

Our successful outcomes correspond to the closure of surgical wound dehiscences and fasciotomies. In such scenarios, controlled dermatraction maintains uniform tension along the system at the entire skin edge, reducing the risk of skin necrosis. Similarly, intramuscular pressure does not appear to increase beyond the safe limit during the procedure, ensuring proper perfusion pressures in the extremities.<sup>7,8</sup> Another advantage to consider is that the elongated skin retains similar properties to the adjacent skin in terms of color, hair distribution, sensitivity and functionality, which improves the cosmetic result and decreases aesthetic sequelae.

Finally, it does not have the disadvantages of more complex reconstructive procedures, such as skin grafts or flaps, which cause aesthetic sequelae, increase associated morbidity, and require a longer hospital stay.<sup>9,10</sup> Wounds associated with severe open fractures or full-thickness skin tears suggest an unfavorable outcome with this technique. In this group of patients, the elongation capacity of the skin does not compensate for the loss of substance secondary to the aggressiveness of the cleaning, so it is advisable to opt for more sophisticated reconstructive techniques, such as flaps of different types, where the success rate ranges between 91% and 93%.<sup>11,12</sup> However, we believe that the failure rate would be higher in our hands; this should be considered in the context of what it means to introduce a surgical technique with a long learning curve; thus, we recommend treatment with pins for wound closure in wounds that meet the characteristics described above as an initial method of treatment, with more complex procedures reserved for a second instance.

Since measurement instruments were not available in the workplace where this study was conducted, two prognostic scenarios for dermatraction were segmented based on practical experience:

- A positive outcome is expected with dehiscences and fasciotomies.
- A negative outcome is expected with open fractures and full-thickness skin tears.

In our study, we demonstrated that the tension produced at the edge of the skin is evenly distributed throughout the system, thus reducing the risk of skin necrosis. As a result, this procedure is currently our preferred method for treating and closing complex wounds and fasciotomies.

## CONCLUSIONS

Dermatotractor performed by hand with traction bands is an effective, simple, and cost-effective treatment for traumatic injuries with extensive exposure. It allows for deferred closure within a few days after trauma. In the series analyzed, the most favorable scenario for its application was in cases of dehiscence and fasciotomies, whereas open fractures and full-thickness skin tears had negative outcomes. Based on our experience, this technique has become our first choice for treating open wounds, as its failure does not interfere with more complex soft tissue coverage procedures.

Conflict of interest: The authors declare no conflicts of interest.

F. Krause ORCID ID: <https://orcid.org/0000-0002-1258-4037>

A. Otero ORCID ID: <https://orcid.org/0009-0001-6131-4412>

J. L. Bottarelli ORCID ID: <https://orcid.org/0009-0002-7442-4036>

F. Plana ORCID ID: <https://orcid.org/0009-0000-2785-7993>

## REFERENCES

1. Samis AJ, Davidson JS. Skin-stretching device for intraoperative primary closure of radial forearm flap donor site. *Plast Reconstr Surg* 2000;105(2):698-702. <https://doi.org/10.1097/00006534-200002000-00034>
2. Turgut G, Ozcan A, Sümer O, Yeşiloğlu N, Baş L. Reconstruction of complicated scalp defect via skin traction. *J Craniofac Surg* 2009;20(1):263-4. <https://doi.org/10.1097/SCS.0b013e3181843766>
3. Saulis AS, Lautenschlager EP, Mustoe TA. Biomechanical and viscoelastic properties of skin, SMAS, and composite flaps as they pertain to rhytidectomy. *Plast Reconstr Surg* 2002;110(2):590-8; discussion 599-600. <https://doi.org/10.1097/00006534-200208000-00035>
4. Wilhelmi BJ, Blackwell SJ, Mancoll JS, Phillips LG. Creep vs stretch: a review of the viscoelastic properties of skin. *Ann Plast Surg* 1998;41(2):215-9. <https://doi.org/10.1097/0000637-199808000-00019>
5. Parrett BM, Matros E, Pribaz JJ, Orgill DP. Lower extremity trauma: trends in the management of soft-tissue reconstruction of open tibia–fibula fractures. *Plast Reconstr Surg* 2006;117(4):1315-22. <https://doi.org/10.1097/01.prs.0000204959.18136.36>
6. Melis P, Bos KE, Horenblas S. Primary skin closure of a large groin defect after inguinal lymphadenectomy for penile cancer using a skin stretching device. *J Urol* 1998;159(1):185-7. [https://doi.org/10.1016/s0022-5347\(01\)64052-7](https://doi.org/10.1016/s0022-5347(01)64052-7)
7. Wiger P, Blomqvist G, Styf J. Wound closure by dermatotractor after fasciotomy for acute compartment syndrome. *Scand J Plast Reconstr Hand Surg* 2000;34(4):315-20. <https://doi.org/10.1080/028443100750059084>
8. Yamamoto N, Kiyosawa T, Arai K, Nakayama Y. Dermal neof ormation during skin wound healing as demonstrated using scanning electron microscopy. *Ann Plast Surg* 2004;52(4):398-406. <https://doi.org/10.1097/01.sap.0000106982.98568.92>
9. Ismavel R, Samuel S, Boopalan PRJVC, Chittaranjan SB. Simple solution for wound coverage by skin stretching. *J Orthop Trauma* 2011;25(3):127-32. <https://doi.org/10.1097/BOT.0b013e318206f556>
10. Bjarnesen JP, Wester JU, Siemssen SS, Jensen NK. External tissue stretching for closing skin defects in 22 patients. *Acta Orthop Scand* 1996;67(2):182-4. <https://doi.org/10.3109/17453679608994668>

11. Hirshowitz B, Lindenbaum E, Har-Shai Y. A skin-stretching device for the harnessing of the viscoelastic properties of skin. *Plast Reconstr Surg* 1993;92(2):260-70. <https://doi.org/10.1097/00006534-199308000-00010>
12. Hijjawi HB, Bishop AT. Management of simple wounds: local flaps, Z-plasty, and skin grafts. In: Moran SL, Cooney WP (eds). *Master techniques in orthopaedic surgery: Soft tissue surgery*. Philadelphia: Lippincott Williams & Wilkins; 2009:37-47.