

Total Hip Arthroplasty in Adults with Legg-Calvé-Perthes Disease

Patricia Marqueta González, Ana M. Bueno Sánchez, Teresa Rodríguez del Real, Aurelia L. Rubio
Orthopedic Surgery and Traumatology Service, Hospital Universitario de Getafe, Madrid, Spain

ABSTRACT

Background and objective: To review the number of total hip replacements (THA) performed in our hospital, determine their aetiology and identify how many of them were performed for hip osteoarthritis secondary to Legg-Calvé-Perthes disease (LCPD). **Materials and Methods:** We conducted a retrospective study reviewing all THA surgeries from 2008 to December 2021. We studied the pre-operative radiographs, determining the aetiology of the osteoarthritis, laterality, sex and age of the patient at the time of surgery. **Results:** We reviewed a total of 1103 hips in 935 patients. Primary hip osteoarthritis accounted for 81% of the cases. We gathered a total of 11 hips from 10 individuals (1%), with a mean age of 61 years, for hip osteoarthritis secondary to LCPD. **Conclusions:** There is evidence that femoro-acetabular impingement (FAI), which results in early secondary hip osteoarthritis, may be influenced by changes in the growth of the proximal femoral physis or overgrowth of the greater trochanter, which are characteristics of LCPD. We believe that certain cases of “misclassified” primary hip osteoarthritis may have been incorrectly identified since no additional information was found to support the diagnosis of secondary hip osteoarthritis, hiding the potential of an alternate, evolved aetiology. Furthermore, we suggest monitoring young patients with LCPD after their growth is complete in order to detect early FAI and provide arthroscopic therapeutic options.

Keywords: Secondary hip osteoarthritis; Perthes disease; total hip arthroplasty; femoro-acetabular impingement.

Level of Evidence: III

Cirugía de prótesis de cadera en el adulto con enfermedad de Legg-Calvé-Perthes

RESUMEN

Objetivos: Revisar las cirugías de prótesis totales de cadera realizadas en nuestro hospital, determinar el origen de la artrosis e identificar cuántas se colocaron por coxartrosis secundarias a enfermedad de Legg-Calvé-Perthes. **Materiales y Métodos:** Se realizó un estudio retrospectivo en el que se revisaron todas las cirugías de prótesis totales de cadera desde 2008 hasta diciembre 2021. Se evaluaron las radiografías prequirúrgicas para determinar la etiología de la artrosis, y se consideraron variables, como lateralidad, sexo y edad en el momento de la intervención. **Resultados:** Se revisaron 1103 caderas en 935 pacientes. El 81% correspondía a coxartrosis primaria. En 11 caderas de 10 pacientes (1%), se detectó coxartrosis secundaria a la enfermedad de Legg-Calvé-Perthes. La media de la edad de estos pacientes era de 61 años. **Conclusiones:** Hay evidencia de que las alteraciones del crecimiento de la fisis femoral proximal o el sobrecrecimiento del trocánter mayor, propias de la enfermedad de Legg-Calvé-Perthes, pueden contribuir a la aparición de un choque femoroacetabular, con su consiguiente coxartrosis precoz. Es posible que algunas “mal clasificadas” coxartrosis primarias fueran identificadas así porque no existía otro dato sugerente de coxartrosis secundarias, y escondieran otra etiología evolucionada. Asimismo, proponemos el seguimiento del paciente joven con enfermedad de Legg-Calvé-Perthes, más allá del crecimiento, para identificar el choque femoroacetabular en sus inicios y poder ofrecer opciones terapéuticas artroscópicas.

Palabras clave: Coxartrosis secundaria; enfermedad de Legg-Calvé-Perthes; prótesis total de cadera; choque femoroacetabular.

Nivel de Evidencia: III

INTRODUCTION

Legg-Calvé-Perthes disease (LCPD) is a hip entity characterized by osteonecrosis of the proximal femoral epiphysis in infancy.¹ Treatment of this condition during infancy aims at restoring spherical congruency and total recovery, i.e., restoring the patient's original hip condition.

Received on January 14th, 2023. Accepted after evaluation on June 6th, 2023 • Dr. PATRICIA MARQUETA GONZÁLEZ • patmg1313@hotmail.com  <https://orcid.org/0009-0004-4456-725X>

How to cite this article: Marqueta González P, Bueno Sánchez AM, Rodríguez del Real T, Rubio AL. Total Hip Arthroplasty in Adults with Legg-Calvé-Perthes Disease. *Rev Asoc Argent Ortop Traumatol* 2023;88(6):647-652. <https://doi.org/10.15417/issn.1852-7434.2023.88.6.1709>

Some residual deformities, such as a non-spherical femoral head, overgrowth of the greater trochanter and its overlap with the short femoral neck, and secondary remodeling of the acetabulum, can alter the functional regime of the hip joint and contribute to the development of early secondary hip osteoarthritis.²

The objectives of this study were to evaluate a series of patients who had undergone total hip arthroplasty (THA), determine their etiology, and identify how many of them were treated for hip osteoarthritis secondary to LCPD. We analyzed whether there was any radiographic aspect of sufficient relevance that negatively affected the biomechanics of the hip joint, beyond the deformity and prognosis established by Stulberg, using our own experience and the contributions of the updated literature.

MATERIALS AND METHODS

A retrospective study was performed in which all THAs performed from 2008 to December 2021, in the Orthopedic Surgery and Traumatology Service of our hospital, were reviewed. Patients undergoing primary total hip arthroplasty during the period studied were included, regardless of indication, age or sex. Another inclusion criterion was that the patient had anteroposterior radiographs of the pelvis, and anteroposterior and axial radiographs of the hip. Patients with no previous radiographs were excluded, given the impossibility of confirming the indication for prosthetic surgery and those with partial hip prostheses.

Pre-surgical radiographs were evaluated to determine the origin of the osteoarthritis, and laterality, sex and age at the time of surgery were also analyzed.

The radiographic criteria applied to etiologically diagnose secondary osteoarthritis due to LCPD were: 1) coxa plana and coxa magna, 2) short femoral neck, and 3) ascending greater trochanter, i.e., when it is located above the center of rotation of the femoral head (Figures 1 and 2).

Likewise, a literature search was carried out in databases such as PubMed, Medline, Cochrane, Clinical Key, with keywords such as “total hip arthroplasty”, “Perthes disease” and “secondary hip osteoarthritis”.

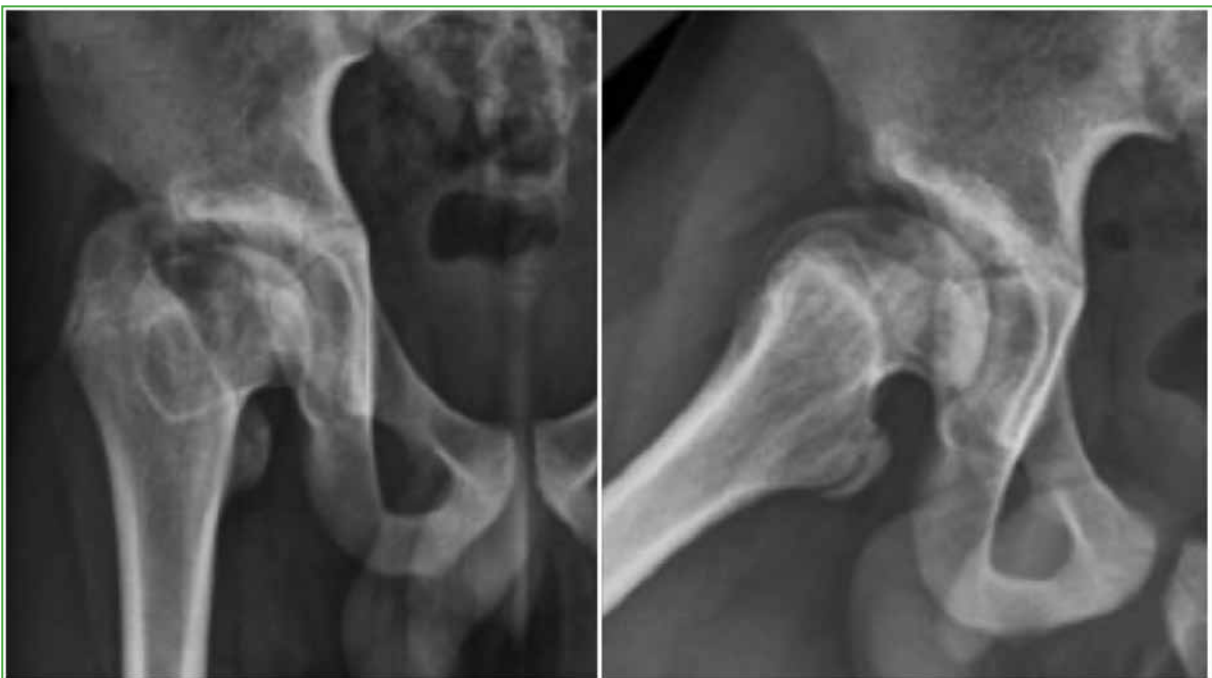

Figure 1. Anteroposterior and axial radiographs of the hip showing residual deformities of Legg-Calvé-Perthes disease.

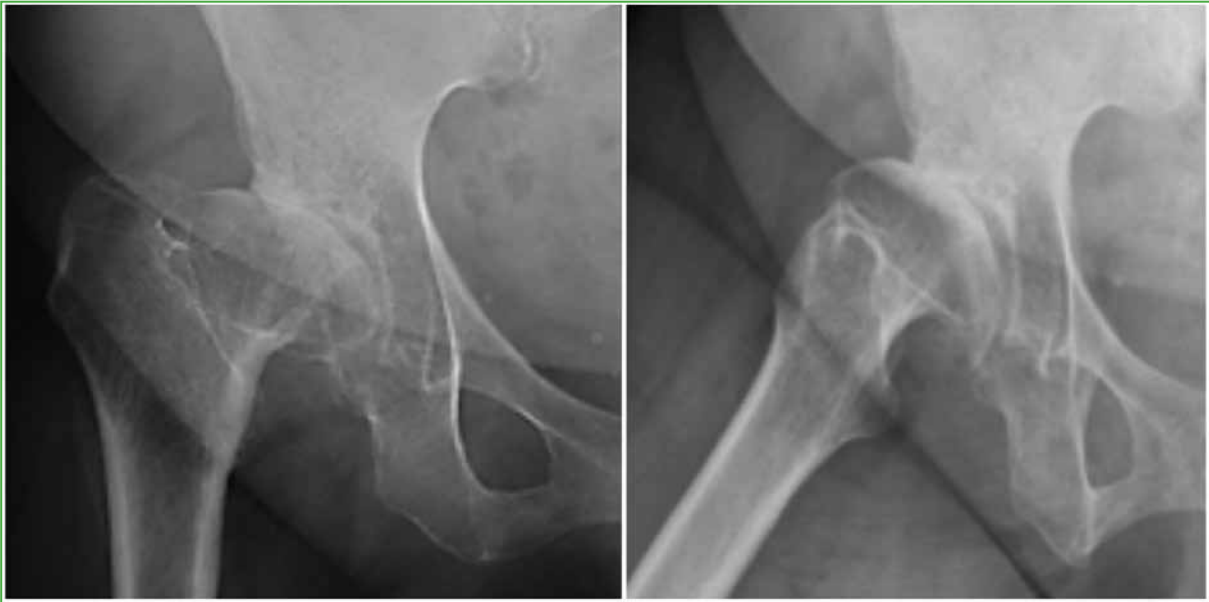

Figure 2. Anteroposterior and axial radiographs of the hip showing hip osteoarthritis secondary to Legg-Calvé-Perthes disease.

RESULTS

A total of 935 patients were included, with a total of 1103 THAs and 168 cases operated bilaterally. Fifty-four percent of the patients were women and 46% were men.

The main diagnosis of patients undergoing THA was primary hip osteoarthritis (81%). In patients with secondary hip osteoarthritis, 9% of the surgeries were due to avascular necrosis of the hip; 7%, due to hip fracture; 1%, due to developmental dysplasia of the hip; 1%, due to LCPD (**Figure 3**) and the remaining 1%, due to various etiologies, such as metastases, acetabular fractures or rheumatoid arthritis.

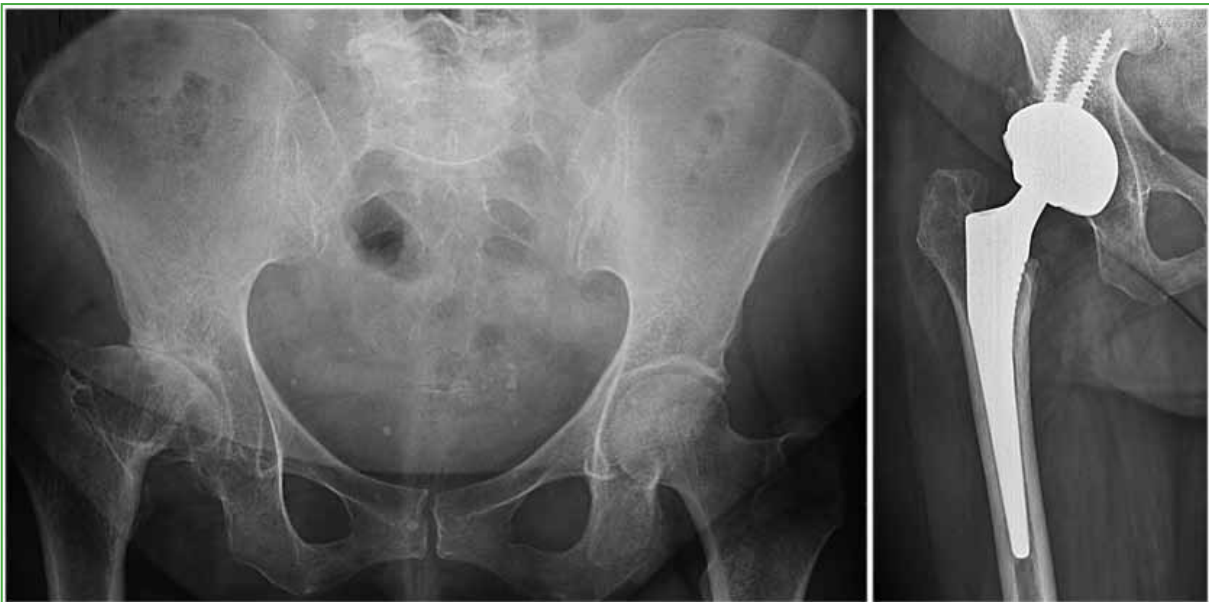


Figure 3. Anteroposterior radiographs of the pelvis and hip showing a total hip prosthesis in a patient with sequelae of Legg-Calvé-Perthes disease.

According to age distribution, the group with the youngest mean age corresponded to patients operated on for developmental dysplasia of the hip (41 years), followed by patients with avascular necrosis (58 years), LCPD (61 years) and hip fracture (71 years).

In the 1% corresponding to THA due to hip osteoarthritis secondary to LCPD (11 THAs in 10 patients), the age range was 40 to 82 years (mean 61), four of them had been operated on before the age of 50. In terms of gender distribution, there were four women (40%) and six men (60%). Five of these 10 patients had undergone surgery on the right hip and four on the left hip, and one case on both (at 45 and 46 years of age).

On all preoperative radiographs, coxa magna and coxa plana were detected. Forty percent had ascending greater trochanter and 70% had a short femoral neck. Three had undergone surgery: one tectoplasty and two valgus osteotomies.

The mean follow-up of these patients was 8.1 years (range 4-13). All of them are followed up annually, except for two who died during the process for reasons unrelated to the study.

DISCUSSION

The specific literature on the incidence of THA due to hip osteoarthritis secondary to LCPD is scarce.

Uluçay et al. reviewed the causes of secondary hip osteoarthritis in 935 operated hips and reported that the rate of THA due to LCPD is 1.7% in females and 4.2% in males. These rates are slightly higher than those in our series, with a similar number of patients.³

Recent studies state that 50% of patients with LCPD will have hip osteoarthritis between the fourth and fifth decade of life⁴ and that 5% will require THA 20 years after initial treatment.⁵

Likewise, in 2016, Shohat et al.⁶ reported that the mean age at the moment of THA due to LCPD is 50.2 years, 10 years younger than our mean.

However, as previously stated, a substantial proportion of prosthetic hips in our hospital are classified as primary etiology. They were so identified because there was no other data suggestive of secondary hip osteoarthritis. This is because, from a radiographic standpoint, it is exceedingly difficult to establish its origin in very advanced stages and in the absence of a previous evolutionary radiography follow-up. In their last arthritic stages, avascular necrosis, acetabular dysplasia, and the already well-consensual femoroacetabular impingement are difficult to identify.

In 2008, Ganz et al.⁷ already questioned many of the primary hip osteoarthritis, which might not be idiopathic, and assumed the existence of some underlying articular cartilage abnormality. These authors put forward the current hypothesis that many of these are actually secondary to subtle anomalies in anatomical development that result in femoroacetabular impingement at a site of excessive contact stress. The most frequent location is the anterosuperior border area and the critical movement is internal rotation of the hip in 90° flexion. Precisely, the degenerative osteoarthritic lesion begins in this area where, on many occasions, avascular necrosis or acetabular dysplasia also begin.⁷

In our review, we were unable to identify these patients with subtle defects in the regeneration and final remodeling of LCPD, who appeared to have had a good result according to the Stulberg classification, but who, despite discharge at the end of growth, consulted for hip joint pain.

In 2011, Kim and Novais² reported their observations on the diagnosis and treatment of femoroacetabular impingement specifically in LCPD. In their article, they explain the origin of residual hip deformities secondary to the disease. On the one hand, LCPD produces an altered growth of the proximal femoral physis with a short femoral neck. On the other hand, overgrowth of the greater trochanter causes mechanical alterations with imbalance in the abduction and rotation forces of the hip. Finally, ossification of the cephalic nucleus results in a non-spherical femoral head and secondary remodeling of the acetabulum. All of these determine the Stulberg stages.²

Sometimes, the loss of sphericity of the femoral head and the modifications of physeal growth are very subtle, they can change the mechanical function of the hip joint contributing to femoroacetabular impingement, without reaching a severe Stulberg stage.

It is necessary to recognize all these deformities and understand their contribution to the patient's symptoms before a therapeutic strategy can be planned.

Lee et al.⁸ also addressed this eventuality and stated that residual hip deformities after LCPD cause mechanical symptoms and are associated with a pathomechanical setting that may present with femoroacetabular impinge-

ment. In these patients, arthroscopy relieved symptoms and improved range of motion, making arthroscopic treatment a good option for LCPD sequelae.⁸

Arthroscopic treatment can resolve symptomatology and limit osteoarthritis progression, as stated in articles published by Amanatullah et al.⁹ in 2015 or, more recently, by Nepple et al.¹⁰ in 2021, and by Chiari et al.¹¹ in early 2022. Prevention is the solution to a more serious evolution. In 2021, Vahedi et al.¹² advocated for early therapeutic arthroscopy in femoroacetabular impingement rather than waiting until advanced age, a prolonged symptomatic period, or radiographic evidence of joint space narrowing, because these are all risk factors for arthroscopy failure and subsequent progression to hip osteoarthritis.⁹⁻¹³

CONCLUSIONS

The current hypothesis, as stated by Ganz et al., is that certain cases of secondary hip osteoarthritis are due to subtle developmental abnormalities that result in femoroacetabular impingement and, in turn, a site of excessive contact stress. The sphericity of the femoral head is a prognostic factor for the development of osteoarthritis.

The results of our study allow us to conclude that THA is rare in the young adult with hip osteoarthritis secondary to LCPD, but it is true that these patients are at increased risk of undergoing prosthetic placement surgery at a young age.

Similarly, we anticipate that these cases may be greater than expected, because an uncertain number of patients appear to have obtained good radiographic outcomes but may develop femoroacetabular impingement in a relatively short period of time.

The natural evolution of some hips with LCPD appears to be the development of femoroacetabular impingement as a consequence of abnormal support at the edge of the acetabulum or overcoverage of the acetabulum, resulting in early hip osteoarthritis.

In the absence of reviews on the evolution of LCPD with a good final radiographic outcome, we propose systematically following up on young patients with closed growth plates after they have reached the end of growth, including periodic clinical and radiographic evaluations to detect early femoroacetabular impingement and offer therapeutic options (e.g., arthroscopic), which may prevent the progression of hip osteoarthritis and thus delay or avoid prosthetic surgery.

Conflict of interest: The authors declare no conflicts of interest.

A. M. Bueno Sanchez ORCID ID: <https://orcid.org/0000-0001-5354-6566>
T. Rodríguez del Real ORCID ID: <https://orcid.org/0009-0007-5879-7058>

A. L. Rubio ORCID ID: <https://orcid.org/0000-0003-0928-1892>

REFERENCES

1. Stulberg SD, Cooperman DR, Wallensten R. The natural history of Legg-Calvé-Perthes disease. *J Bone Joint Surg Am* 1981;63(7):1095-108. PMID: 7276045
2. Kim YJ, Novais EN. Diagnosis and treatment of femoroacetabular impingement in Legg-Calvé-Perthes disease. *J Pediatr Orthop* 2011;31(2 Suppl):S235-40. <https://doi.org/10.1097/BPO.0b013e3182260252>
3. Uluçay C, Ozler T, Güven M, Akman B, Kocadal AO, Altıntaş F. Etiology of coxarthrosis in patients with total hip replacement. *Acta Orthop Traumatol Turc* 2013;47(5):330-3. <https://doi.org/10.3944/aott.2013.3103>
4. Heesakkers N, van Kempen R, Feith R, Hendriks J, Schreurs W. The long-term prognosis of Legg-Calvé-Perthes disease: a historical prospective study with a median follow-up of forty-one years. *Int Orthop* 2015;39(5):859-63. <https://doi.org/10.1007/s00264-014-2589-2>
5. Hanna SA, Sarraf KM, Ramachandran M, Achan P. Systematic review of the outcome of total hip arthroplasty in patients with sequelae of Legg-Calvé-Perthes disease. *Arch Orthop Trauma Surg* 2017;137(8):1149-54. <https://doi.org/10.1007/s00402-017-2741-8>

6. Shohat N, Copeliovitch L, Smorgick Y, Atzmon R, Mirovsky Y, Shabshin N, et al. The Long-Term outcome after varus derotational osteotomy for Legg-Calvé-Perthes disease: A mean follow-up of 42 years. *J Bone Joint Surg Am* 2016;98(15):1277-85. <https://doi.org/10.2106/JBJS.15.01349>
7. Ganz R, Leunig M, Leunig-Ganz K, Harris WH. The etiology of osteoarthritis of the hip: an integrated mechanical concept. *Clin Orthop Relat Res* 2008;466(2):264-72. <https://doi.org/10.1007/s11999-007-0060-z>
8. Lee WY, Hwang DS, Ha YC, Kim PS, Zheng L. Outcomes in patients with late sequelae (healed stage) of Legg-Calvé-Perthes disease undergoing arthroscopic treatment: retrospective case series. *Hip Int* 2018;28(3):302-8. <https://doi.org/10.5301/hipint.5000563>
9. Amanatullah DF, Antkowiak T, Pillay K, Patel J, Refaat M, Toupadakis CA, et al. Femoroacetabular impingement: current concepts in diagnosis and treatment. *Orthopedics* 2015;38(3):185-99. <https://doi.org/10.3928/01477447-20150305-07>
10. Nepple JJ, Fowler LM, Larson CM. Decision-making in the borderline hip. *Sports Med Arthrosc Rev* 2021;29(1):15-21. <https://doi.org/10.1097/JSA.0000000000000298>
11. Chiari C, Lutschounig MC, Nöbauer-Huhmann I, Windhager R. Femoroacetabuläres Impingement-Syndrom bei Adoleszenten – Wie beraten? Wie behandeln? [Femoroacetabular impingement syndrome in adolescents - How to advise? How to treat?]. *Orthopade* 2022;51(3):211-8. [German] <https://doi.org/10.1007/s00132-022-04214-z>
12. Vahedi H, Yacovelli S, Diaz C, Parvizi J. Surgical treatment of femoroacetabular impingement: Minimum 10-year outcome and risk factors for failure. *JB JS Open Access* 2021;6(4):e20.00176. <https://doi.org/10.2106/JBJS.OA.20.00176>
13. Masrouha KZ, Callaghan JJ, Morcuende JA. Primary total hip arthroplasty for Legg-Calvé-Perthes syndrome: 20 year follow-up study. *Iowa Orthop J* 2018;38:197-202. PMID: 30104945