

Hair Tourniquet Syndrome in the Pediatric Population: A Case Report

Florencia Turazza, Joaquín Yunes, J. Javier Masquijo

Department of Pediatric Orthopedics and Traumatology, Sanatorio Allende, Córdoba, Argentina

ABSTRACT

Tourniquet syndrome is a rare condition that usually affects the pediatric population. It consists of a decrease in blood supply due to circumferential strangulation of some parts of the body, mainly fingers or toes, external genitalia or other appendages. In most cases, the causative agent is usually a strand of hair, although other elements have been described, such as synthetic fibers from the patient's clothing. The aim of this study is to report a case of a patient with hair tourniquet syndrome and to review the available literature. The patient is a 3-month-old female with hair tourniquet syndrome, with involvement of the fourth toe of the right foot, who was brought to the emergency department for significant soft tissue edema. The patient evolved favorably after removal of the causative agent (hair strand) from the base of the fourth toe and recovery of irrigation was complete. Although tourniquet syndrome is a rare entity, early diagnosis and treatment is essential to avoid potentially severe complications.

Keywords: Tourniquet syndrome; children; foot.

Level of Evidence: IV

Síndrome del torniquete capilar en la población pediátrica: reporte de un caso

RESUMEN

El síndrome del torniquete es un cuadro poco frecuente que ocurre, por lo general, en la población pediátrica. Consiste en la disminución del aporte sanguíneo por estrangulación circunferencial de algunas partes del cuerpo y suele comprometer dedos de los miembros superiores o inferiores, genitales externos u otros apéndices. En la mayoría de los casos, el agente causal suele ser una hebra de cabello, aunque se han descrito otros elementos, como fibras sintéticas de la indumentaria del paciente. El objetivo de este artículo es presentar el caso de una paciente con síndrome del torniquete y analizar la bibliografía disponible. Se trata de una lactante de 3 meses de edad con síndrome del torniquete por cabello, con compromiso del cuarto dedo del pie derecho, que fue traída al servicio de urgencia por un importante edema de partes blandas. La paciente evolucionó favorablemente luego de la extracción del agente causal (hebra de cabello) de la base del cuarto dígito y la recuperación de la irrigación fue completa. Si bien es un cuadro poco frecuente, es imprescindible tener un alto índice de sospecha y realizar un diagnóstico precoz para indicar un tratamiento oportuno y evitar complicaciones potencialmente graves para el paciente.

Palabras clave: Síndrome del torniquete; niños; pie.

Nivel de Evidencia: IV

INTRODUCTION

Hair tourniquet syndrome is a rare condition that usually occurs in children <1 year of age, with an estimated incidence of 0.02%.¹ It consists of the decrease in blood supply due to circumferential compression of the circulation and often involves appendicular structures of the upper and lower limbs and external genitalia, among other sites.² In most cases, the causative agent is usually a strand of hair, although other elements, such as synthetic fibers from the patient's clothing, have been described.³ Edema and enlarged soft tissues around the tourniquet area make it difficult to directly see the object causing the compression, so a detailed anamnesis and physical examination is important. Failure to diagnose this condition can lead to severe consequences, such as infection or loss of the affected structure due to amputation.⁴ A high index of suspicion should be maintained and early treatment should be administered. Due to its low incidence, there are few published reports describing limb involvement.

The aim of this article is to present the case of a girl with hair tourniquet syndrome and its evolution.

Received on January 12th, 2023. Accepted after evaluation on April 1st, 2023 • Dr. J. JAVIER MASQUIJO • jmasquijo@gmail.com  <https://orcid.org/0000-0001-9018-0612>

How to cite this article: Turazza F, Yunes J, Masquijo JJ. Hair Tourniquet Syndrome in the Pediatric Population: A Case Report. *Rev Asoc Argent Ortop Traumatol* 2023;88(6):676-680. <https://doi.org/10.15417/issn.1852-7434.2023.88.6.1708>

CLINICAL CASE

The patient is a 3-month-old patient, born at 33 weeks gestation, with neonatal anemia, on supplemental iron treatment and neurorehabilitation. The family consulted the emergency department of our institution because the girl had persistent edema of the fourth toe of the right foot, without being able to specify the time of evolution. Physical examination revealed congestive edema of the fourth toe, erythema, and pain to the touch and passive mobilization (Figure 1).

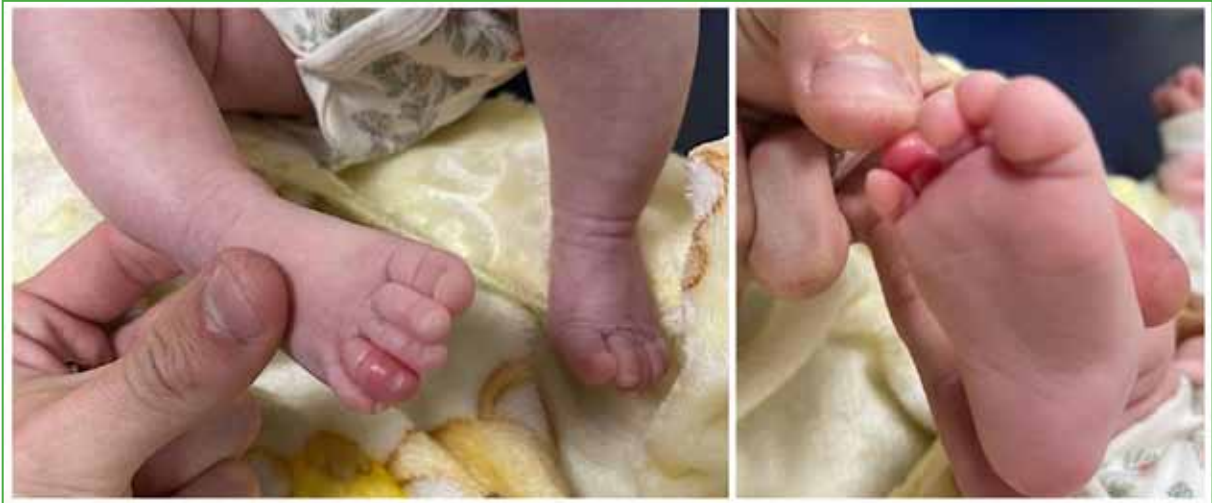

Figure 1. Clinical images at admission.

A strand of hair around the finger was noted as the cause of the strangulation. The strand was extracted under local anesthesia by means of a 1 cm longitudinal cut with a No. 11 scalpel blade, in the dorsomedial region (Figure 2), parallel to the axis of the finger.

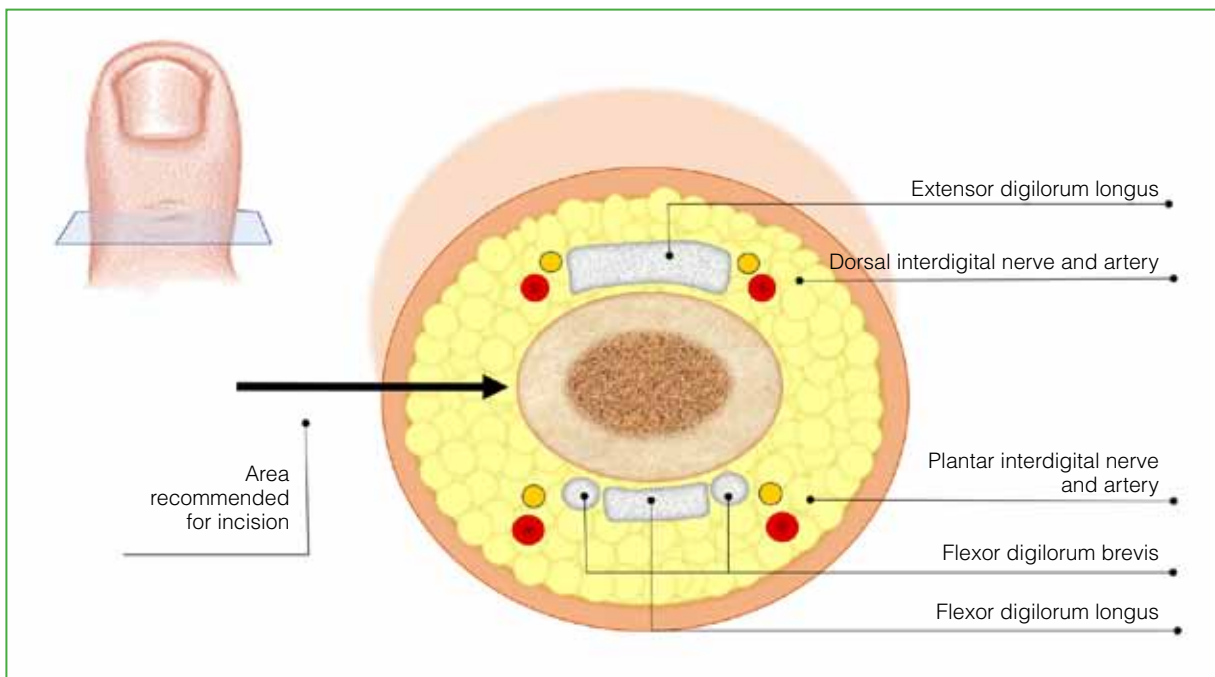


Figure 2. Diagram showing the suggested incision site for tourniquet removal.

After hair removal, distal perfusion improved and edema decreased within a few minutes (Figure 3). The patient was monitored the next day in the outpatient clinic of the Children’s Orthopaedics and Traumatology Service and a good evolution of the condition was confirmed. At the last follow-up at 10 days, the distal circulation of the finger had completely recovered, she had no edema, and she was discharged.

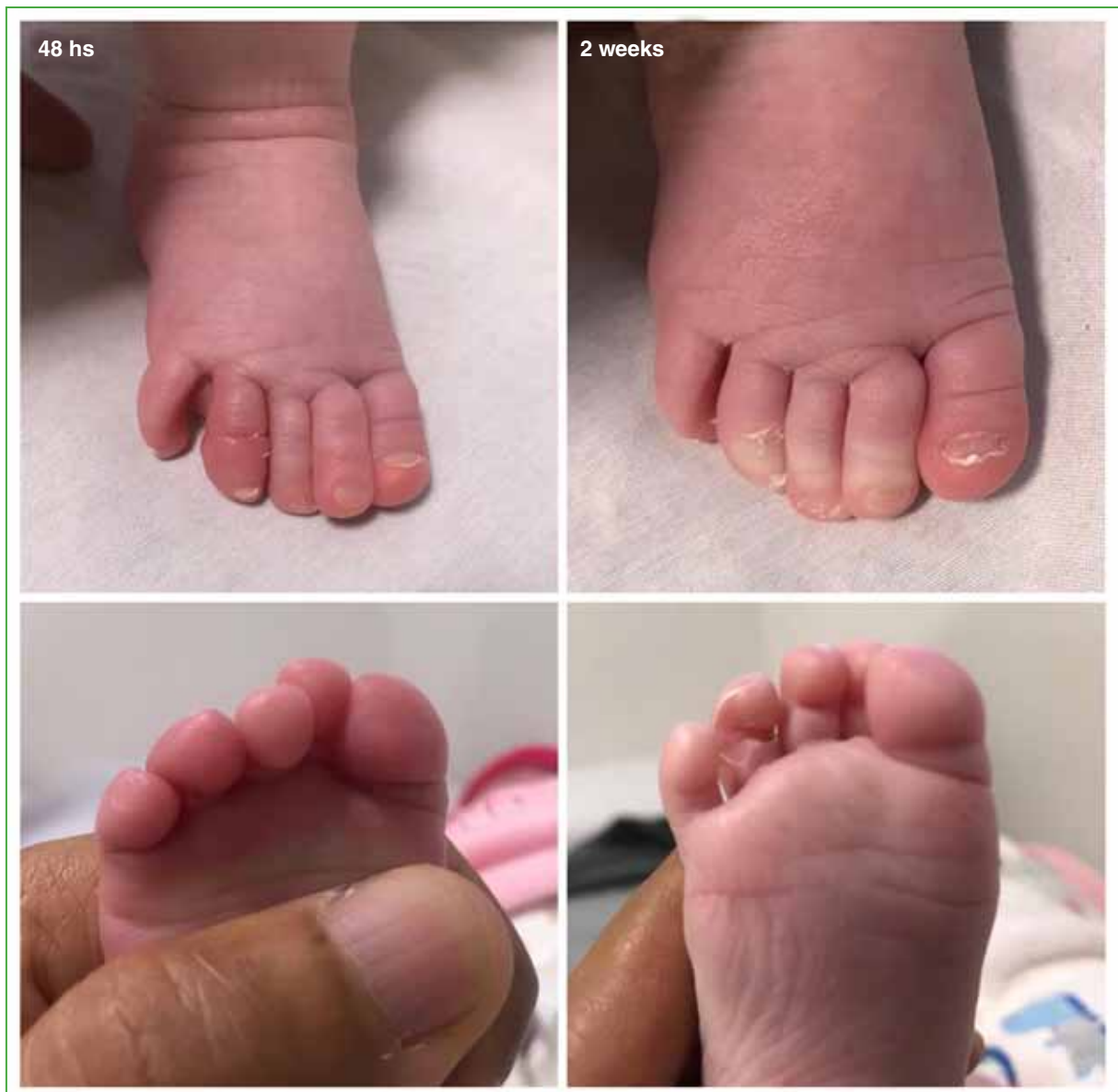

Figure 3. Clinical images during follow-up.

DISCUSSION

In 1971, Quinn⁵ first introduced the concept of “tourniquet syndrome of the fingers”, where he described this condition exclusively on the toes of the lower extremities. However, the term “hair tourniquet syndrome” was coined by Barton et al.⁶ in 1988, in a series of 66 patients, in which they described more broadly the involvement of fingers, toes and external genitalia due to strangulation caused by a strand of hair. Other authors have reported isolated involvement of different structures, such as the base of the neck, the pinna, and components of the oral cavity, such as the tongue and uvula.^{1,7-9}

The incidence is estimated to be around 0.02%.¹ Digit involvement is usually more common in children <1 year of age, in the first months of life, while in older children and the elderly, it usually occurs in other locations, such as external genitalia.¹⁰ In a review of more than 210 cases, Mat Saad et al.¹¹ reported that 44.2% of patients had genital (penile) involvement, 40.4% had toe involvement, 8.57% had finger involvement, and 6.83% had other site involvement. Although it usually presents as an isolated condition (with involvement of a single structure), simultaneous involvement of two or three digits has been described.¹²

It has been proposed that this syndrome occurs when a constrictive agent, mainly a hair from the mother or a thread from the infant's clothing^{3,13} curls around the finger, hinders lymphatic and venous drainage, and causes edema. This would increase the tension of the tourniquet and lead to increased venous congestion and ultimately compromise of arterial circulation with subsequent ischemia and necrosis of the finger.^{14,15} In some more severe cases, the tourniquet can cut the skin and cause bone erosion.¹¹ Strahlman¹⁶ proposed the theory of a direct relationship between the telogen effluvium experienced by the mother in the postpartum period due to hormonal imbalance and hair tourniquet syndrome. It is also believed that it would be related to the type of clothing with which the child is dressed, especially in the winter season.¹⁷ Although its origin is usually accidental, there are some cases associated with child abuse¹⁸ and religious practices of some cultures,^{19,20} which is why it is important to obtain a detailed anamnesis and perform a complete physical examination of each patient. The presence of knots in the strands or threads of the tourniquet should alert the physician to the possibility of abuse.²¹

The diagnosis is clinical and a high index of suspicion should be taken into account in a child with edema, discoloration and pain in any of their digits. Many times the tourniquet may not be visible and irritability may be the only sign, mainly in infants. Treatment should be immediate and consists of complete removal of the causative agent. When the tourniquet cannot be seen due to edema, a small longitudinal incision with a scalpel is indicated in the dorsal region of the finger.²² If there are doubts or if the resection is incomplete, surgical exploration with the use of magnifiers is required in some cases.

According to some published series, the complication rate is approximately 50%¹¹ and is related to the omission or delay in the diagnosis of the syndrome or to insufficient extraction of the hair strand. The most common complications are: infection, necrosis, gangrene and amputation. Differential diagnoses of this condition include: amniotic band syndrome, spontaneous or inhum dactylolysis and some keratodermas.²³

Hair tourniquet syndrome is a rare entity in the pediatric population, but it is potentially dangerous and requires the medical professional involved in the consultation to have a high index of suspicion. Early diagnosis and timely treatment are essential to avoid serious complications; Therefore, it is important to alert caregivers and instruct pediatric health personnel on the detection and management of this syndrome.

Conflict of interest: The authors declare no conflicts of interest.

F. Turazza ORCID ID: <https://orcid.org/0000-0002-8705-0304>

J. Yunes ORCID ID: <https://orcid.org/0000-0002-2487-4592>

REFERENCES

1. Claudet I, Pasian N, Debuissou C, Salanne S, Rekhroukh H. Tourniquet syndrome: Interest of a systematic analysis of families' social conditions to detect neglect situations. *Child Abuse Negl* 2009;33(9):569-72. <https://doi.org/10.1016/j.chiabu.2009.03.003>
2. Cevik Y, Kavalci C. Hair tourniquet syndrome. *Ann Saudi Med* 2010;30(5):416-7. <https://doi.org/10.4103/0256-4947.67088>
3. Uygur E, Çarkçi E, Ünkar E. Can washing socks without flipping inside out cause hair tourniquet syndrome? A claim with two case reports. *J Pediatr Orthop B* 2017;26(2):193-4. <https://doi.org/10.1097/BPB.0000000000000348>

4. García-Mata S, Hidalgo-Ovejero A. Hair tourniquet syndrome of the toe: report of 2 new cases. *J Pediatr Orthop* 2009;29(8):860-4. <https://doi.org/10.1097/BPO.0b013e3181b7ff14>
5. Quinn NJ Jr. Toe tourniquet syndrome. *Pediatrics* 1971;48(1):145-6. <https://doi.org/10.1542/peds.48.1.145>
6. Barton D, Sloan G, Nichter L, Reinisch JF. Hair-thread tourniquet syndrome. *Pediatrics* 1988;82:925-8. PMID: 3186385
7. Dey R, Zameer MM, Vinay C, Rao, S. Hair tourniquet of the uvula. *J Indian Assoc Pediatr Surg* 2022;27(2):261-2. https://doi.org/10.4103/jiaps.JIAPS_365_20
8. Sylwestrzak MS, Fischer BF, Fischer H. Recurrent clitoral tourniquet syndrome. *Pediatrics* 2000;105(4 Pt 1):866-7. <https://doi.org/10.1542/peds.105.4.866>
9. Schneider K, Kennebeck S, Madden L, Campbell A. Hair tourniquet of the circumvallate papillae: a potentially “hairy” situation. *Pediatr Emerg Care* 2013;29(8):924-5. <https://doi.org/10.1097/PEC.0b013e31829ec4c7>
10. Haddad FS. Penile strangulation by human hair: report of 3 cases and review of literature. *Urol Int* 1982;37(6):375-88. <https://doi.org/10.1159/000280843>
11. Mat Saad AZ, Purcell EM, McCann JJ. Hair-thread tourniquet syndrome in an infant with bony erosion: a case report, literature review, and metaanalysis. *Ann Plast Surg* 2006;57(4):447-52. <https://doi.org/10.1097/01.sap.0000222571.98387.71>
12. Mackey S, Hettiarachy S, Dickinson J. Hair-tourniquet syndrome-multiple toes and bilaterality. *Eur J Emerg Med* 2005;12(4):191-2. <https://doi.org/10.1097/00063110-200508000-00009>
13. Alpert JJ, Filler R, Glaser HH. Strangulation of an appendage by hair wrapping. *N Engl J Med* 1965;273(16):866-7. <https://doi.org/10.1056/NEJM196510142731608>
14. Parlak M, Karakaya AE. Hair-thread tourniquet syndrome of the hypertrophic clitoris in a 6-year-old girl. *Pediatr Emerg Care* 2015;31(5):363-4. <https://doi.org/10.1097/PEC.0000000000000341>
15. Corazza M, Carla E, Altieri E, Virgili A. What syndrome is this? Tourniquet syndrome. *Pediatr Dermatol* 2002;19(6):555-6. <https://doi.org/10.1046/j.1525-1470.2002.00233.x>
16. Strahlman RS. Toe tourniquet syndrome in association with maternal hair loss. *Pediatrics* 2003;111(3):685-7. <https://doi.org/10.1542/peds.111.3.685>
17. Martonovich N, Khatib M, Assaf M. Hair tourniquet syndrome: A retrospective study. *Pediatr Dermatol* 2022 Sep 30. <https://doi.org/10.1111/pde.15151>
18. Klusmann A, Lenard HG. Tourniquet syndrome-accident or abuse? *Eur J Pediatr* 2004;163(8):495-8; discussion 499. <https://doi.org/10.1007/s00431-004-1466-1>
19. Singh B, Kim H, Wax S. Strangulation of glans penis by hair. *Urology* 1978;11(2):170-2. [https://doi.org/10.1016/0090-4295\(78\)90100-0](https://doi.org/10.1016/0090-4295(78)90100-0)
20. Thomas AJ, Timmonjs JW, Perlmutter AD. Progressive penile amputation tourniquet injury secondary to hair. *Urology* 1977;9(1):42-4. [https://doi.org/10.1016/0090-4295\(77\)90282-5](https://doi.org/10.1016/0090-4295(77)90282-5)
21. Webley JA, Scheif DR, Coleman J. Tourniquet syndrome: an unusual presentation. *Ann Emerg Med* 1981;10(9):494-5. [https://doi.org/10.1016/s0196-0644\(81\)80288-0](https://doi.org/10.1016/s0196-0644(81)80288-0)
22. Serour F, Gorenstein A. Treatment of the toe tourniquet syndrome in infants. *Pediatr Surg Int* 2003;19(8):598-600. <https://doi.org/10.1007/s00383-003-1034-1>
23. Aslantürk O, Özbey R, Yılmaz Ö, Ergen E. Hair tourniquet syndrome of toes and fingers in infants. *Acta Orthop Traumatol Turc* 2019;53(4):306-9. <https://doi.org/10.1016/j.aott.2019.04.010>