

Supramalleolar Osteotomies for Ankle Osteoarthritis: Clinical and Radiological Outcomes

Leonardo Á. Conti, Jonathan M. Verbner, Pablo Valenti, Ana C. Parise, Daniel S. Villena, María Gala Santini Araujo, Pablo Sotelano, Guillermo Cardone, Facundo Bilbao, N. Marina Carrasco

Foot and Ankle Medicine and Surgery Sector, Orthopedics and Traumatology Service "Dr. Carlos E. Ottolenghi", Hospital Italiano de Buenos Aires, Autonomous City of Buenos Aires, Argentina

ABSTRACT

Introduction: Supramalleolar osteotomies are a treatment option for asymmetric ankle osteoarthritis. Our work aims to describe the clinical, radiographic, and subjective outcomes obtained in patients with ankle osteoarthritis who underwent a supramalleolar osteotomy (SMOT). **Materials and Methods:** Retrospective, observational, and descriptive study on patients who underwent SMOT for ankle osteoarthritis between January 2010 and July 2017. The patients' clinical records were analyzed. **Results:** We included 13 patients who underwent SMOT, 8 patients with valgus (61.5%) and 5 (38.5%) with varus rearfoot and ankle misalignment. The mean varus VAS score decreased from 9 ± 0.45 to 3 ± 1 postoperatively ($p < 0.05$) and, in valgus deformities, from a mean 7.88 ± 0.35 to 2.15 ± 1.64 postoperatively ($p < 0.05$). The mean AOFAS score changed from 32.8 ± 16.2 to 82.1 ± 13.6 postoperatively in the varus deformity group ($p < 0.05$) and from 31 ± 17.3 preoperatively to 93.1 ± 6.20 postoperatively in the valgus deformity group ($p < 0.05$). Twelve patients (92.3%) achieved radiographic union in an average time of 10.4 weeks. **Conclusion:** Supramalleolar osteotomy as a treatment for asymmetric ankle osteoarthritis is a predictable technique with very good clinical and radiological outcomes in the short and medium term.

Keywords: Ankle osteoarthritis; supramalleolar osteotomy; joint preservation.

Level of Evidence: IV

Osteotomías supramaleolares en pacientes con artrosis de tobillo: resultados clínicos y radiográficos

RESUMEN

Introducción: Las osteotomías supramaleolares son una opción terapéutica para la artrosis asimétrica de tobillo. El objetivo de este artículo es describir los resultados clínicos, radiográficos y subjetivos obtenidos en pacientes con artrosis de tobillo sometidos a una osteotomía supramaleolar. **Materiales y Métodos:** Estudio observacional descriptivo retrospectivo de pacientes sometidos a una osteotomía supramaleolar por artrosis de tobillo entre enero de 2010 y julio de 2017. Se analizaron las historias clínicas para recabar datos clínicos y radiográficos preoperatorios y posoperatorios. **Resultados:** Se incluyó a 13 pacientes: 8 con una desalineación del tobillo y retropié en valgo (61,5%) y 5 (38,5%) en varo. El puntaje medio posoperatorio de la escala analógica visual del grupo con deformidad en varo disminuyó de $9 \pm 0,45$ a 3 ± 1 ($p < 0,05$) y de una media de $7,88 \pm 0,35$ a $2,15 \pm 1,64$ ($p < 0,05$) en aquellos con deformidad en valgo. El puntaje medio de la escala de la AOFAS se modificó de $32,8 \pm 16,2$ antes de la cirugía a $82,1 \pm 13,6$ en el posoperatorio, en el grupo con deformidad en varo ($p < 0,05$) y de $31 \pm 17,3$ a $93,1 \pm 6,20$, respectivamente, en aquellos con deformidad en valgo ($p < 0,05$). Se constató la consolidación radiográfica en 12 pacientes (92,3%), en un promedio de 10.4 semanas. **Conclusión:** La osteotomía supramaleolar como tratamiento de la artrosis asimétrica de tobillo es una técnica predecible, con muy buenos resultados clínicos y radiográficos a corto y mediano plazo.

Palabras clave: Artrosis de tobillo; osteotomía supramaleolar; preservación articular.

Nivel de Evidencia: IV

Received on January 4th, 2023 Accepted after evaluation on February 16th, 2024 • Dr. LEONARDO Á. CONTI • leonardoconti@gmail.com  <https://orcid.org/0000-0003-2333-5834>

How to cite this article: Conti LÁ, Verbner J, Valenti P, Parise AC, Villena DS, Santini Araujo MG, Sotelano P, Cardone G, Bilbao F, Carrasco NM. Supramalleolar Osteotomies for Ankle Osteoarthritis: Clinical and Radiological Outcomes. *Rev Asoc Argent Ortop Traumatol* 2024;89(2):121-131. <https://doi.org/10.15417/issn.1852-7434.2024.89.2.1703>

INTRODUCTION

Ankle osteoarthritis is a condition that affects 1% of the adult population worldwide.¹ In most cases, the origin is post-traumatic: due to a deformity as a consequence of a fracture or due to chronic ankle instability leading to abnormal joint loading that damages the cartilage, resulting in varus (most frequently) or valgus ankle and rearfoot misalignment.¹⁻³

It is widely accepted that, for advanced osteoarthritis of the ankle, joint sacrifice surgeries (either joint fusion or arthroplasty) are the definitive treatment of choice.¹ However, in cases of partial or incomplete osteoarthritis (also called “asymmetric” osteoarthritis) in which there are areas of viable cartilage and some alteration of the loading axis of the ankle, supramalleolar ankle osteotomies (SMOT) are an option to consider as joint sparing procedures,^{1,3} as they redistribute the load to areas with preserved cartilage and offload degenerated areas. Thus, they reduce pain, maintain range of motion, restore joint congruence⁴ and delay the progression of osteoarthritis. Supramalleolar osteotomies can be considered as a definitive or intermediate treatment postponing an eventual arthroplasty or joint fusion which, if necessary, are performed on an already aligned limb.^{5,6}

This is a technique described by Speed and Boyd⁷ in 1936, but which gained popularity after the studies of Takakura in the 1990s⁸ and, later, of Hintermann,⁹ and has recently gained significant notoriety. Takakura et al. proposed this surgical technique in patients with a stage lower than IIIB, some authors reported good outcomes in patients with selected stage IIIB injuries.¹⁰ Although the indications for supramalleolar osteotomy are still under discussion,⁵ contraindications include patients with advanced osteoarthritis, unmanageable hindfoot instability, severe vascular or neurological disease, acute or chronic infection of the joint and, relatively speaking, patients >70 years old, with poor bone quality, and smokers.^{11,12}

The aim of this study was to evaluate the functional, radiographic and subjective results obtained in patients with ankle osteoarthritis who underwent SMOT at our institution.

MATERIALS AND METHODS

This study had the prior approval of the institution’s Ethics Committee.

Data were collected for patients treated with supramalleolar osteotomy between January 2010 and July 2017.

A retrospective descriptive observational study was carried out. During that period, 14 patients were operated on and 13 were included, since one did not complete the follow-up.

Inclusion criteria were: patients >18 years old with a diagnosis of asymmetric ankle osteoarthritis with <50% joint involvement, unresponsive to conservative treatment, undergoing SMOT. Patients with incomplete medical records and follow-up <2 years were excluded. Patients were evaluated clinically and radiographically before surgery, at 1 and 4 weeks postoperatively, then at 2, 3 and 12 months and, finally, with annual controls.

Clinical analysis

Comorbidities (smoking, diabetes mellitus, body mass index), habitual sports activity and etiology of ankle osteoarthritis were recorded. The sample was divided into two groups according to varus or valgus hindfoot deformity based on clinical assessment of the deformity and on weight-bearing radiographs. In addition, ankle instability was evaluated with clinical maneuvers in the office (stress tests) and with fluoroscopy in the operating room.

The clinical examination was performed using the visual analog scale (VAS), which assesses pain with images and numbers from 0 “no pain” to 10 “worst possible pain”; it allows pain to be located at all intermediate points between extremes;¹³ and the *American Orthopaedic Foot and Ankle Society (AOFAS)*¹⁴ hindfoot scale, which assesses hindfoot and ankle function, pain, limitation of daily living, gait, joint range of motion, and clinical alignment. Both scales were administered before surgery and at the end of follow-up; patients’ subjective satisfaction was also determined by asking whether they would undergo surgery again.

Complications during follow-up, the need for removal of the osteosynthesis and the need for reconversion to arthrodesis or ankle arthroplasty during follow-up were evaluated.

Radiographic analysis

Anteroposterior and lateral weight-bearing radiographs of the ankle were taken before surgery and at the end of follow-up. In the anteroposterior projection, the following angles were evaluated: intermalleolar (IM) angle (angle between the longitudinal axis of the tibia and a line connecting the ends of the lateral and medial malleoli),¹⁵ anterior distal tibial angle (ADTA) (angle between the tibial diaphysis and the articular surface of the tibial plafond in the anteroposterior view),¹⁶ and talar inclination angle (TIA) (angle between the tibial plafond and the articular surface of the talar dome in the anteroposterior view).¹⁶ In the lateral projection, the lateral distal tibial angle (LDTA) (anterior angle between the tibial diaphysis axis and the articular surface of the tibial diaphysis in the lateral view) was assessed.¹⁷ These angles are used for both preoperative and postoperative planning to evaluate the radiographic surgical outcome (Figure 1).

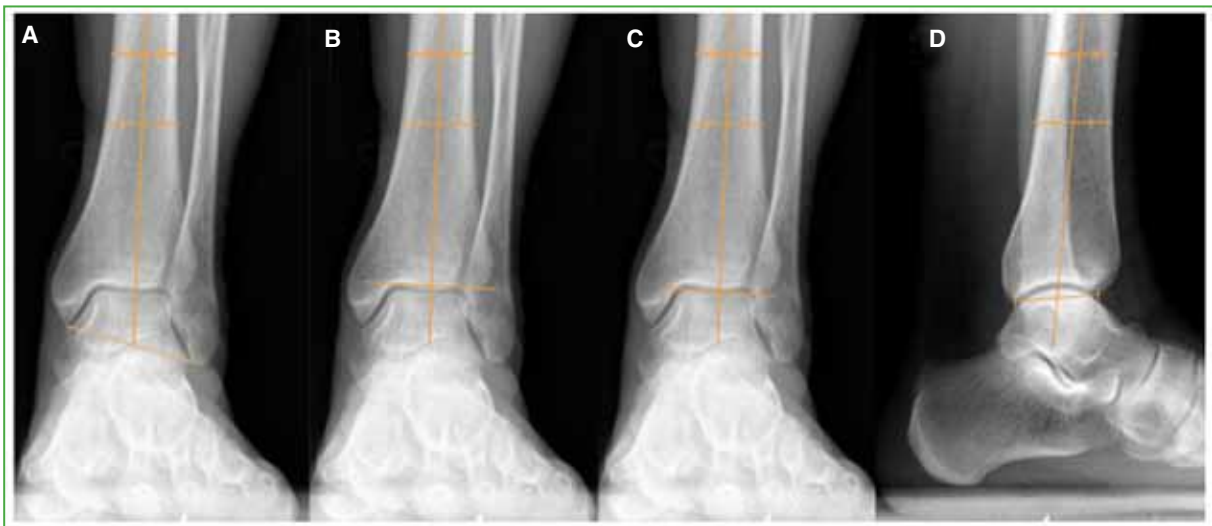


Figure 1. **A.** Intermalleolar angle (angle between the longitudinal axis of the tibia and a line connecting the ends of the lateral and medial malleoli). **B.** Anterior distal tibial angle (angle between the tibial diaphysis and the articular surface of the tibial plafond in the anteroposterior view). **C.** Talar tilt angle (angle between the tibial plafond and the articular surface of the talar dome in the anteroposterior view). **D.** Lateral distal tibial angle (anterior angle between the axis of the tibial diaphysis and the articular surface of the tibial diaphysis in the lateral view).

Osteoarthritis was classified according to the Takakura-Anaka classification on the anteroposterior weight-bearing radiograph. This classification includes four stages; I: no joint space narrowing, but there is subchondral sclerosis of the bone and osteophyte formation; II: narrowing of medial or lateral joint space; IIIa: obliteration of medial or lateral joint space; IIIb: obliteration of medial or lateral joint space extending over the roof of the talar dome; IV: complete obliteration of joint space.¹⁸

Preoperative CT scans were performed on all patients to assess the extent of joint involvement and, postoperatively, the tomographic time to consolidation was also recorded.

Preoperative planning

The patient is examined standing and walking, and the comparative stability and range of motion of the ankle and subtalar joint are assessed. The need for concomitant procedures is planned (ligament plastic surgery, calcaneal osteotomy, etc.), which will then be reevaluated during surgery to determine whether they are necessary.

The deformity in both the coronal and sagittal planes will be assessed on preoperative weight-bearing radiographs when planning the form and extent of the osteotomy. The required correction angle is marked on the preoperative radiographs and the size and orientation of the wedges to be used are calculated.¹¹ The normal angle of the distal tibial surface of the ankle is usually 93°. The LDTA is normally 80°. The height of the wedge to be resected or added is calculated by restoring the normal values and taking into account the values of the contralateral extremity.¹⁹

Surgical technique and postoperative management

The patient was placed in the dorsal decubitus position under regional anesthesia. Lateral and medial stress maneuvers were performed under fluoroscopy to evaluate for ankle instability. The type of osteotomy was defined taking into account the type of deformity and its magnitude. Varus deformities were treated with medial opening-wedge or lateral closing-wedge supramalleolar osteotomies. In minor deformities (<10°), medial opening-wedge osteotomies were performed, and in major deformities (>10°), lateral closing-wedge osteotomies were performed. Valgus deformities were treated with medial closing-wedge supramalleolar osteotomies. The osteosynthesis used was a 4.5 mm locking tibia plate. An allograft was placed if necessary.

In some cases, procedures were added in the same surgical stage. The fibula osteotomy was utilized to shorten in varus cases and lengthen in valgus patients, depending on the degree of joint realignment accomplished following tibial osteotomies. Ligament and tendon reconstruction was performed according to clinical and intraoperative radioscopic evaluation. Calcaneal osteotomies were performed when the hindfoot remained misaligned even after tibial osteotomy. Finally, the limb was immobilized with a short leg cast. All patients were discharged 24 h after surgery. The leg cast was removed four weeks after surgery. A walker boot was indicated for two weeks with no weight-bearing and for two weeks with partial weight-bearing. Patients began to wear their usual footwear two months after surgery. Kinesiotherapy began around the fourth week. The patients were authorized to resume sporting activities progressively according to tolerance, starting six months after the operation.

Statistical Analysis

Continuous variables are presented as means and standard deviation (SD) or median with their interquartile range (IQR) according to the distribution. Categorical variables are expressed as absolute value and percentage. To compare continuous preoperative and postoperative data, Student's t-test for dependent samples or Wilcoxon rank test were used as appropriate. Data were analyzed with STATA version 13 (Statacorp LP College Station Texas).

RESULTS

The study included 13 patients undergoing SMOT: eight with valgus ankle and rearfoot misalignment (61.5%) and five (38.5%) with varus misalignment. The median follow-up was 27 months (IQR 24-48). Six were men (46%), the median age was 58 years (IQR 34-61). The mean body mass index was 24 kg/m² (range 2-26.4). Six patients (46%) practiced physical activity before surgery (Table 1).

Regarding associated foot and ankle pathologies, one (7.6%) had flat feet and two (15.3%) had subtalar osteoarthritis. The mean VAS score decreased from a mean of 9 (SD 0.45) before surgery to 3 (SD 1) postoperatively ($p < 0.05$), in the varus deformity group, and from a mean of 7.88 (SD 0.35) to 2.15 (SD 1.64) ($p < 0.05$), respectively, in the valgus deformity group. The median AOFAS scale score changed from 32.8 (SD 16.23) preoperatively to 82 (SD 13.65) after surgery ($p < 0.05$) in the varus deformity group and from 31 (SD 17.36) to 93.13 (SD 6.20) ($p < 0.05$), respectively, in the valgus deformity group.

When asked if they would undergo surgery again, 12 (92.3%) stated that they would indeed do it again, while only one said that they would not undergo surgery again.

Before surgery, six (46.1%) practiced recreational sports activities and all of them returned to sports. In 12 (92.3%), radiographic consolidation was achieved after surgery, in a median of 10.4 weeks (IQR 8-12) (Figures 2 and 3). Pseudarthrosis was observed in one patient, requiring revision surgery. Twenty-five aggregate procedures were performed (Table 2).

Table 1. Demographic characteristics of the study population.

	Varus (n = 5)	Valgus (n = 8)	Total (n = 13)
Male sex, n (%)	3 (60)	3 (37.5)	6 (46.1)
Body mass index, mean (SD), kg/m ²	27.3 (1.9)	23 (2.8)	24 (2.6)
Age, median (IQR 25-75), years	60 (52-61)	46 (29.5-60.7)	58 (34-61)
Right, n (%)	4 (80)	4 (50)	8 (61.5)
Etiology			
Post-traumatic (fracture), n (%)	2 (40)	6 (75)	8 (61.5)
Post-traumatic (instability), n (%)	2 (40)	2 (25)	4 (30.7)
Idiopathic, n (%)	1 (20)	0	1 (7.69)
Takakura Classification			
Stage I, n (%)	1 (20)	2 (25)	3 (23.1)
Stage II, n (%)	1 (20)	3 (37.5)	4 (30.7)
Stage IIIA, n (%)	0	3 (37.5)	3 (23.1)
Stage IIIB, n (%)	3 (60)	0	3 (23.1)

SD = standard deviation; IQR = interquartile range.

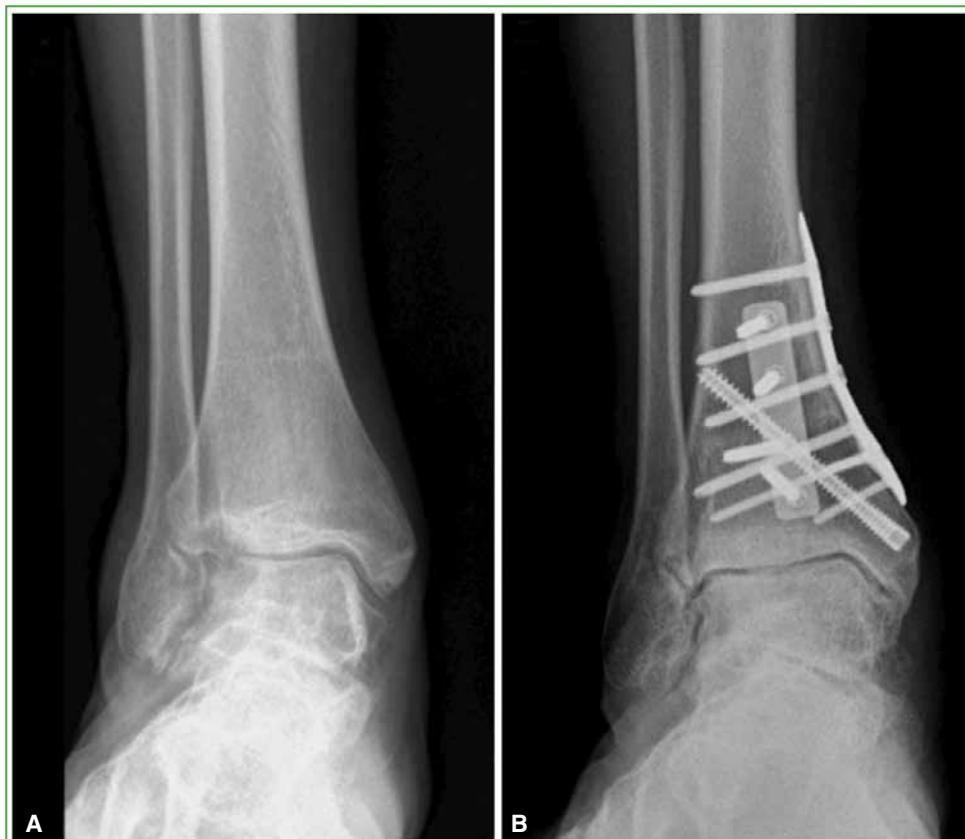

Figure 2. Takakura Stage IIIA. **A.** Preoperative ankle radiograph, AP view. **B.** Anteroposterior ankle radiograph, 6 years after internal supramalleolar closing-wedge varus osteotomy.

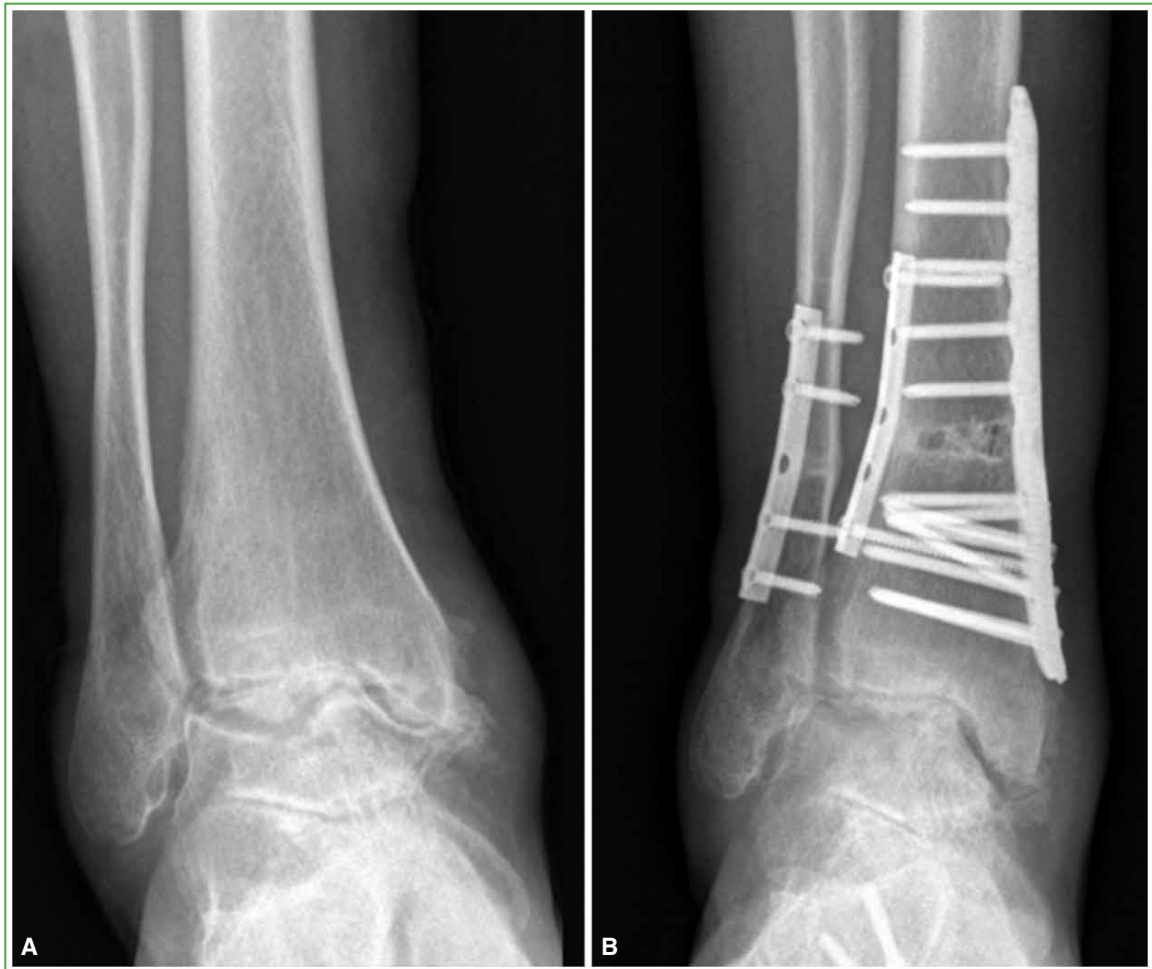

Figure 3. Takakura Stage IIIB. **A.** Preoperative ankle radiograph, AP view. **B.** Anteroposterior ankle radiograph, 2 years after internal supramalleolar opening-wedge valgus osteotomy.

Table 2. Associated procedures

Associated procedures	Varus	Valgus	Total
Fibula osteotomy	4	3	7
External column lengthening	0	1	1
Calcaneal valgus osteotomy	3	1	4
Subtalar arthrodesis	0	2	2
Transfer of lateral peroneus longus tendon to lateral peroneus brevis tendon	1	1	2
Deltoid ligament repair	0	2	2
Bostrom-Gould surgery	2	2	4
Bone graft	2	1	3

Radiographic findings

In the group of patients with varus misalignment, the ADTA was modified from a median of 87.51 (IQR 78.18-89.5) preoperatively to a median of 91.47 (IQR 91.3-94.42) postoperatively ($p < 0.05$); the median LDTA changed from 84.17 (IQR 79.01-88) preoperatively to a median of 77.14 (IQR 76.73-82) postoperatively ($p = 0.57$); the IM angle changed from a median of 106.6 (IQR 102.25-110.65) preoperatively to a median of 96.74 (IQR 96-103.48) postoperatively ($p = 0.06$); and the TIA changed from a median of 5.6 (IQR 4.87-7.42) preoperatively to a median of 5.94 (IQR 1.66-7.56) postoperatively ($p = 0.74$).

With respect to valgus misalignments, the ADTA changed from a median of 91.72 (IQR 85.72-98.32) to a median of 82.52 (IQR 78.24-87.18) ($p < 0.05$); the LDTA, from a median of 87.68 (IQR 85.63-91.11) to a median of 90.6 (IQR 83.61-95.63) ($p = 0.72$); the IM angle, from a median of 98.96 (IQR 90.96-102.35) to a median of 102.77 (IQR 99.52-106.45) ($p < 0.05$); the TIA, from a median of 5.22 (IQR 1.80-7.1) to a median of 5.07 (IQR 1.84-5.13) ($p < 0.05$) (Table 3).

In terms of osteoarthritic changes, Takakura stage II was the most frequent (Table 4).

Table 3. Radiographic outcomes

Parameters	Varus (n = 5)			Valgus (n = 8)		
	Preoperative	Postoperative	p*	Preoperative	Postoperative	p*
Talar tilt angle, median (IQR)	5.6 (4.87-7.42)	5.94 (1.66-7.56)	0.74	5.22 (1.80-7.1)	3.325 (1.83-5.13)	<0.05
Anterior distal tibial angle, median (IQR)	87.51 (78.18-89.5)	91.47 (91.3-94.42)	<0.05	91.72 (85.72-98.32)	82.52 (78.24-87.18)	<0.05
Intermalleolar angle, median (IQR)	106.6 (102.25-110.65)	96.74 (96-103.48)	0.06	98.96 (90.96-102.35)	102.77 (99.51-106.44)	<0.05
Lateral distal tibial angle, median (IQR)	84.17 (79.01-88)	77.14 (76.73-82)	0.57	87.68 (85.63-91.11)	90.60 (83.61-95.63)	0.72

*Statistical significance was established at $p < 0.05$. IQR = interquartile range.

Table 4. Evolution of Takakura stages by patient

Patient	Takakura stage (Preoperative)	Takakura stage (Postoperative)	Stage variation
1	II	II	0
2	IIIA	IIIB	1+
3	II	II	0
4	IIIB	IIIB	0
5	IIIA	IIIA	0
6	I	I	0
7	IIIB	IV	1+
8	I	I	0
9	IIIB	IIIB	0
10	I	I	0
11	II	II	0
12	II	II	0
13	IIIA	IIIA	0

Regarding complications, osteosynthesis was removed in one patient due to implant intolerance. One patient required revision surgery due to lack of consolidation. Four months after the operation, the tibia osteosynthesis broke, so surgical correction was performed with two higher profile plates, PEEK cage and bone substitute.

No arthrodesis or arthroplasty conversion surgery was necessary in any case. One evolved with mild pain in the rearfoot at the level of the peroneal tendons, which disappeared with the use of plantar orthoses. There was one case of delayed healing of the wound that was resolved with advanced wound healing.

DISCUSSION

The results of SMOT for the surgical treatment of asymmetric ankle osteoarthritis have been published in multiple international series.^{2,6,10,20-23} In our region, there are very few series published;²⁴ none in our country. It is a technique that, although it has been described and studied for some time, is still under discussion. In our series, the clinical outcomes were very good, with significant improvement in VAS and AOFAS scores, and a very good subjective perception of the procedure. Regarding the radiographic outcomes, most of the parameters improved in the anteroposterior evaluation of the ankle in both groups. In the valgus misalignment group, the variation of TIA, IM and ADTA angles was statistically significant. In the varus misalignment group, the ADTA showed statistical significance, while the TIA did not significantly improve. Statistical analysis of the results has to be considered in the context of a small sample. The median time to consolidation in our series was 10.4 weeks (IQR 8-12). One patient progressed to pseudarthrosis and required a revision procedure. Postoperative complications were rare. In no case was conversion to arthrodesis or arthroplasty necessary at the end of follow-up.

In the series of Kraähenbühl et al. on medial opening-wedge supramalleolar osteotomies for varus correction, the ADTA and TIA in the ankle mortise view changed significantly compared to the preoperative evaluation. They did not find statistically significant changes for the LDTA.⁹ In their series to correct asymmetric osteoarthritis with varus deformity using a medial opening-wedge SMOT, Tanaka et al. reported correction in all angles preoperatively with respect to postoperatively, but did not mention statistical significance.¹⁸ In the series published by Stamatis et al, varus deformities were corrected using a medial opening-wedge SMOT, while valgus deformities were corrected with a medial closing-wedge SMOT. The ADTA was corrected postoperatively with a statistically significant difference in both varus and valgus misaligned ankles. But, as in our cases with the postoperative LDTA, they found no statistically significant differences from preoperatively.²¹ This seems reasonable given that SMOT corrects the deformity in the coronal plane.

While sagittal plane deformities can be modified, correcting such misalignments requires a correction in the dimension of the wedge in the anteroposterior direction or opting for dome-shaped osteotomies alignment of the ankle are important factors affecting clinical outcomes after SMOT. In agreement with the recommendations of Hintermann et al.,²⁵ we prefer to achieve a slight overcorrection of the osteotomy to change the loading axis and counteract the deforming effect of the soft tissues. On the other hand, although opening-wedge osteotomies can generate a slight loss of correction due to the collapse of the bone graft and the consequent closure of the osteotomy, fixation with a locking plate could add stability, preventing this phenomenon of under-correction from occurring. In our series of patients with varus deformity, we conducted medial opening-wedge osteotomies when the deformity was mild, and lateral closing-wedge osteotomies when the deformity was more severe. Valgus deformities were treated with medial closing-wedge osteotomies, with favorable outcomes in all cases.

Pagenstert et al. indicated fibula osteotomy when the IM angle had a difference of at least 5° compared to the contralateral angle, or in fracture sequelae that, on tomographic evaluation, showed a rotational deformity or subluxation at the level of the syndesmosis; they performed either a shortening or lengthening Z osteotomy.²⁶ Recently, Lim et al. published a series of patients with medial ankle osteoarthritis who were treated with a comparative medial opening-wedge osteotomy with or without the addition of a fibula osteotomy; the results were increased medial gutter space and greater lateral translation of the talus in the fibula osteotomy group.²⁷ In our experience, fibula osteotomy was performed in patients with varus deformity to create more space for the mortise and thus reduce the talus. In patients with valgus deformity, lengthening of the fibula was chosen when the fibula was shorter (because of a history of ankle fracture) and did not adequately hold the talus in its correct position.

In relation to ligament instability of the ankle and hindfoot, it is important to perform joint stress maneuvers under fluoroscopy before starting surgery and repeat them after tibial osteotomy. Some authors explain that the improvement of the distal tibial angle after tibial osteotomy results in better ankle stability, making ligament reconstruction unnecessary in some cases.⁸ In our series, after supramalleolar osteotomy, two (25%) of the ankles with valgus deformity still had medial ligament instability and required a deltoid ligament reconstruction, two (25%) with lateral instability required a lateral anatomic ligament reconstruction, and two (40%) with varus instability required a lateral ligament reconstruction.

In a series with a long follow-up, Krähenbühl et al. reported that the greatest number of complications occurred during the first two years,² which is precisely the minimum follow-up time in our series. Hintermann et al. stated that the complication rates of supramalleolar osteotomies are low.²⁵ It has been reported that opening-wedge osteotomies take longer to heal²³ than closing-wedge osteotomies. Takakura et al.⁸ reported four pseudarthroses in 18 operated ankles. In our series, the only case that evolved with pseudarthrosis was an opening-wedge osteotomy. Hintermann et al. also described a revision rate of 19%, while ours was 7%. In their series of 294 supramalleolar osteotomies, Krähenbühl et al. reported that 38 (12.95%) patients required conversion to arthroplasty or arthrodesis, at an average of five years after surgery (range 2-16).² Therefore, it is not surprising that we have not yet reported reconversions despite our two-year average follow-up period. In their series of nine supramalleolar osteotomies, Harstall et al. reported the need to remove the osteosynthesis in two patients.²³ In our series, the osteosynthesis material had to be removed in only one patient due to intolerance.

The median time to consolidation in our series was 10.4 weeks (IQR 8-12), while other authors report similar average times, from 10 to 15.2 weeks.²¹⁻²³

When analyzing the different series for comparison, the stage of the operated patients must be considered. Hongmou et al. reported that the preoperative Takakura stage with the highest number of cases was IIIA;²² in our sample, it was II. There were no cases of radiographic regression of Takakura stage after surgery, but we did observe two cases of radiographic progression: one from stage IIIA to stage IIIB and one from IIIB to IV; both with initial valgus deformity. Other authors reported that two of the nine operated ankles showed radiographic progression of osteoarthritis, which coincides with our results.²³

In several studies, pain improved by about 3 to 4 points after supramalleolar osteotomy.^{20,21,26,28} In our series, the VAS score improved similarly to other published series, based on greater preoperative pain in patients with varus deformity. As for the evaluation with the AOFAS scale, something similar occurred. This scale has shown statistically significant improvements when comparing scores before and after surgery.^{22,23} In our series, there was also a statistically significant improvement in this score postoperatively for both varus and valgus deformities. Kim et al. stated that 90.6% of patients reported good to excellent postoperative subjective outcomes.²⁸ In our case, 12 (92.3%) reported satisfactory subjective outcomes, and responded that they would undergo surgery again.

Our study has certain limitations. The data were collected retrospectively, the number of patients is small and the follow-up is short; several patients had undergone other added surgical procedures (calcaneal osteotomies, fibula osteotomies, etc.) that could affect the final result of the supramalleolar osteotomy. However, it is difficult to study SMOT in isolation, and this problem is present in all published studies.

Regarding strengths, we have not found a series of cases on this technique published in Argentina. All surgeries were performed by the same surgical team. In the future, the results of series with a larger number of patients, with more homogeneous pathology and longer follow-up should be published. Additionally, the evolution of patients in equal stages treated with ankle arthroplasty or arthrodesis should be compared. The strategy of conducting multicenter studies to increase the number of cases could also be considered.

CONCLUSIONS

SMOT as a treatment for asymmetric ankle osteoarthritis is a predictable technique, with very good clinical and radiographic outcomes in the short and medium term. The results of our series are similar to those published by other studies. This surgical technique had a low complication rate and no re-conversion was necessary during the average 2-year follow-up.

Conflict of interest: The authors declare no conflicts of interest.

J. Verbner ORCID ID: <https://orcid.org/0000-0001-7040-2097>

P. Valenti ORCID ID: <https://orcid.org/0000-0001-6946-4127>

A. C. Parise ORCID ID: <https://orcid.org/0000-0001-7308-3693>

D. S. Villena ORCID ID: <https://orcid.org/0000-0001-5742-1226>

M. G. Santini Araujo ORCID ID: <https://orcid.org/0000-0002-5127-5827>

P. Sotelano ORCID ID: <https://orcid.org/0000-0001-8714-299X>

G. Cardone ORCID ID: <https://orcid.org/0000-0002-7388-9045>

F. Bilbao ORCID ID: <https://orcid.org/0000-0003-4255-3335>

N.M. Carrasco ORCID ID: <https://orcid.org/0000-0002-1251-4936>

REFERENCES

1. Valderrabano V, Horisberger M, Russell I, Dougall H, Hintermann B. Etiology of ankle osteoarthritis. *Clin Orthop Relat Res* 2009;467(7):1800-6. <https://doi.org/10.1007/s11999-008-0543-6>
2. Krähenbühl N, Zwicky L, Bolliger L, Schädelin S, Hintermann B, Knupp M. Mid- to long-term results of supramalleolar osteotomy. *Foot Ankle Int* 2017;38(2):124-32. <https://doi.org/10.1177/1071100716673416>
3. Barg A, Pagenstert GI, Horisberger M, Paul J, Gloyer M, Henninger HB, et al. Supramalleolar osteotomies for degenerative joint disease of the ankle joint: indication, technique and results. *Int Orthop* 2013;37(9):1683-95. <https://doi.org/10.1007/s00264-013-2030-2>
4. Zhao HM, Wen XD, Zhang Y, Liang JQ, Liu PL, Li Y, et al. Supramalleolar osteotomy with medial distraction arthroplasty for ankle osteoarthritis with talar tilt. *J Orthop Surg Res* 2019;14(1):120. <https://doi.org/10.1186/s13018-019-1168-z>
5. Koo JW, Park SH, Kim KC, Sung IH. The preliminary report about the modified supramalleolar tibial osteotomy for asymmetric ankle osteoarthritis. *J Orthop Surg* 2019;27(1):2309499019829204. <https://doi.org/10.1177/2309499019829204>
6. Zhao H, Liang X, Li Y, Yu G, Niu W, Zhang Y. The role of fibular for supramalleolar osteotomy in treatment of varus ankle arthritis: a biomechanical and clinical study. *J Orthop Surg Res* 2016;11(1):127. <https://doi.org/10.1186/s13018-016-0462-2>
7. Speed JS, Boyd HB. Operative reconstruction of malunited fractures about the ankle joint. *J Bone Joint Surg* 1936;18(2):270-86.
8. Takakura Y, Tanaka Y, Kumai T, Tamai S. Low tibial osteotomy for osteoarthritis of the ankle. Results of a new operation in 18 patients. *J Bone Joint Surg Br* 1995;77(1):50-4. PMID: 782235
9. Krähenbühl N, Akkaya M, Deforth M, Zwicky L, Barg A, Hintermann B. Extraarticular supramalleolar osteotomy in asymmetric varus ankle osteoarthritis. *Foot Ankle Int* 2019;40(8):936-47. <https://doi.org/10.1177/1071100719845928>
10. Lee WC, Moon JS, Lee K, Byun WJ, Lee SH. Indications for supramalleolar osteotomy in patients with ankle osteoarthritis and varus deformity. *J Bone Joint Surg Am* 2011;93(13):1243-8. <https://doi.org/10.2106/JBJS.J.00249>
11. Krause F, Veljkovic A, Schmid T. Supramalleolar osteotomies for posttraumatic malalignment of the distal tibia. *Foot Ankle Clin* 2016;21(1):1-14. <https://doi.org/10.1016/j.fcl.2015.09.001>
12. Becker AS, Myerson MS. The indications and technique of supramalleolar osteotomy. *Foot Ankle Clin* 2009;14(3):549-61. <https://doi.org/10.1016/j.fcl.2009.06.002>
13. Huskisson EC. Measurement of pain. *Lancet* 1974;2(7889):1127-31. [https://doi.org/10.1016/s0140-6736\(74\)90884-8](https://doi.org/10.1016/s0140-6736(74)90884-8)
14. Kitaoka HB, Alexander IJ, Adelaar RS, A Nunley J, Myerson MS, Sanders M, et al. Clinical rating systems for the ankle-hindfoot, midfoot, hallux, and lesser toes. *Foot Ankle Int* 1997;18(3):187-8. <https://doi.org/10.1177/107110079401500701>
15. Park BS, Chung CY, Park MS, Sung KH, Choi Y, Park C, et al. Inverse relationship between radiographic lateral ankle instability and osteochondral lesions of the talus in patients with ankle inversion injuries. *Foot Ankle Int* 2019;40(12):1368-74. <https://doi.org/10.1177/1071100719868476>
16. Hayashi K, Tanaka Y, Kumai T, Sugimoto K, Takakura Y. Correlation of compensatory alignment of the subtalar joint to the progression of primary osteoarthritis of the ankle. *Foot Ankle Int* 2008;29(4):400-6. <https://doi.org/10.3113/FAI.2008.0400>
17. Magerkurth O, Knupp M, Ledermann H, Hintermann B. Evaluation of hindfoot dimensions: a radiological study. *Foot Ankle Int* 2006;27(8):612-6. <https://doi.org/10.1177/107110070602700808>

18. Tanaka Y, Takakura Y, Hayashi K, Taniguchi A, Kumai T, Sugimoto K. Low tibial osteotomy for varus-type osteoarthritis of the ankle. *J Bone Joint Surg Br* 2006;88(7):909-13. <https://doi.org/10.1302/0301-620X.88B7.17325>
19. Chopra V, Stone P, Ng A. Supramalleolar osteotomies. *Clin Podiatr Med Surg* 2017;34(4):445-60. <https://doi.org/10.1016/j.cpm.2017.05.003>
20. Kim YS, Youn HK, Kim BS, Choi YJ, Koh YG. Arthroscopic evaluation of persistent pain following supramalleolar osteotomy for varus ankle osteoarthritis. *Knee Surg Sports Traumatol Arthrosc* 2016;24(6):1860-7. <https://doi.org/10.1007/s00167-014-3199-7>
21. Stamatis ED, Cooper PS, Myerson MS. Supramalleolar osteotomy for the treatment of distal tibial angular deformities and arthritis of the ankle joint. *Foot Ankle Int* 2003;24(10):754-64. <https://doi.org/10.1177/107110070302401004>
22. Hongmou Z, Xiaojun L, Yi L, Hongliang L, Junhu W, Cheng L. Supramalleolar osteotomy with or without fibular osteotomy for varus ankle arthritis. *Foot Ankle Int* 2016;37(9):1001-7. <https://doi.org/10.1177/1071100716649926>
23. Harstall R, Lehmann O, Krause F, Weber M. Supramalleolar lateral closing wedge osteotomy for the treatment of varus ankle arthrosis. *Foot Ankle Int* 2007;28(5):542-8. <https://doi.org/10.3113/FAI.2007.0542>
24. Wagner E, Ortiz C, Keller A, Wagner P, Zanolli D, Ahumada X, et al. Artrosis de tobillo localizada: el rol de las osteotomías. *Tobillo y Pie* 2013;5(2):114-88. Available at: <https://jfootankle.com/tobilloypie/article/view/1417>
25. Hintermann B, Knupp M, Barg A. Supramalleolar osteotomies for the treatment of ankle arthritis. *J Am Acad Orthop Surg* 2016;24(7):424-32. <https://doi.org/10.5435/JAAOS-D-12-00124>
26. Pagenstert GI, Hintermann B, Barg A, Leumann A, Valderrabano V. Realignment surgery as alternative treatment of varus and valgus ankle osteoarthritis. *Clin Orthop Relat Res* 2007;462:156-68. <https://doi.org/10.1097/BLO.0b013e318124a462>
27. Lim JW, Kang SJ, Im JM, Kwon SH, Jung HG. Evaluation of clinico-radiological outcome of fibular valgization osteotomy with supra-malleolar osteotomy in patients with ankle osteoarthritis. *Int Orthop* 2023;47(8):2013-21. <https://doi.org/10.1007/s00264-023-05822-w>
28. Kim YS, Kim YB, Koh YG. Prognostic factors affecting correction angle changes after supramalleolar osteotomy using an opening wedge plate for varus ankle osteoarthritis. *J Foot Ankle Surg* 2019;58(3):417-22. <https://doi.org/10.1053/j.jfas.2018.09.003>