

# Use of Endoprosthesis for the Treatment of Non-Neoplastic Pathologies of the Knee

Fernando D. Jorge, José M. Varaona, Lionel Prado, Francisco Tálamo, Pablo Pérez Cortés  
*Orthopedics and Traumatology Service, Hospital Alemán, Autonomous City of Buenos Aires, Argentina.*

## ABSTRACT

**Introduction:** Endoprosthesis is the gold standard for reconstruction after oncological resections. The advances regarding its materials and designs allowed for the expansion of the indications to non-neoplastic pathologies. Its simple and fast intraoperative assembly and its immediate mechanical stability allow for early rehabilitation and functional recovery. However, the failure rate is high, although it is different from oncological pathologies. The predominant causes are varied. **Objectives:** To analyze our experience in the use of knee endoprosthesis and compare it with the literature, evaluating functional outcomes, radiographic outcomes, implant survival and causes of eventual failure. **Materials and Methods:** Patients with complex non-neoplastic knee pathology that required reconstruction with endoprosthesis were selected. Clinical history, anamnesis, physical examination, and radiographs were reviewed. For clinical examination and functional evaluation, the MusculoSkeletal Tumor Society Score (MSTS Score) was used. For implant failures, the modified Henderson et al. classification was used. **Results:** 12 endoprostheses were studied, with an average follow-up of 3.8 years. Failures were recorded in 2 (18%), with a mean time to failure of 47.5 months. One type 2 failure (aseptic loosening) and one type 4 failure (infection) were recorded. No other complications were noted. For the functional evaluation, the mean final score was 76.6%. **Conclusion:** Our results support the use of endoprostheses for complex non-neoplastic knee diseases in carefully selected patients, despite being a complex surgical procedure with many complications.

**Keywords:** Endoprosthesis; knee; infection; complications.

**Level of Evidence:** IV

## Uso de endoprótesis para el tratamiento de enfermedades no neoplásicas de la rodilla

## RESUMEN

**Introducción:** Las endoprótesis son el método de elección para la reconstrucción luego de las resecciones oncológicas. Los avances en los materiales y diseños permitieron expandir las indicaciones a enfermedades no neoplásicas. Su montaje intraoperatorio simple y rápido, y su estabilidad mecánica inmediata permiten una rehabilitación y una recuperación funcional tempranas. Sin embargo, la tasa de fallas es elevada, aunque distinta de la de las enfermedades oncológicas. Las causas predominantes son diferentes. **Objetivos:** Analizar nuestra experiencia con el uso de endoprótesis de rodilla y compararla con los estudios publicados, evaluando los resultados funcional y radiográfico, la supervivencia del implante y las causas de su eventual falla. **Materiales y Métodos:** Se seleccionaron pacientes con enfermedad no neoplásica compleja de rodilla que requirieran una reconstrucción con endoprótesis. Para el examen clínico y la evaluación funcional se utilizó el puntaje de la *Musculoskeletal Tumor Society*, y para las fallas de los implantes, la clasificación de Henderson y cols. modificada. **Resultados:** Se estudiaron 12 endoprótesis, con un seguimiento promedio de 3.8 años. Se registraron 2 fallas (18%), con un tiempo promedio hasta la falla de 47.5 meses. Una fue tipo 2 (aflojamiento aséptico) y la otra, tipo 4 (infección). No hubo otras complicaciones. En la evaluación funcional, el puntaje final medio fue del 76,6%. **Conclusión:** Nuestros resultados respaldan el uso de endoprótesis para enfermedades complejas no neoplásicas de rodilla en pacientes cuidadosamente seleccionados, pese a ser un procedimiento quirúrgico complejo y con muchas complicaciones.

**Palabras clave:** Endoprótesis; rodilla; infección; complicaciones.

**Nivel de Evidencia:** IV

Received on October 15<sup>th</sup>, 2022. Accepted after evaluation on January 6<sup>th</sup>, 2023 • Dr. FERNANDO D. JORGE • fernandodjorge@gmail.com

 <https://orcid.org/0000-0002-2596-9147>

**How to cite this article:** Jorge FD. Use of Endoprosthesis for the Treatment of Non-Neoplastic Pathologies of the Knee. *Rev Asoc Argent Ortop Traumatol* 2023;88(5):466-477. <https://doi.org/10.15417/issn.1852-7434.2023.88.5.1678>

## INTRODUCTION

Since the late 1980s, improvements in the quality and design of orthopedic implants, advances in imaging methods and surgical techniques, and the introduction of chemotherapy made limb-sparing surgery possible for patients with musculoskeletal tumors.<sup>1</sup> As a result, segmental resections of long bones and joints and their subsequent reconstruction became the procedure of choice.

Modular endoprosthesis has been the most widely used system in the last three decades and the method of choice for reconstruction after these segmental resections due to tumor bone disease. This is due to its availability, its relatively simple and fast intraoperative set-up, and the immediate mechanical stability that makes early rehabilitation and functional recovery possible.<sup>1-3</sup>

In recent years, great advances in endoprosthetic materials and designs have gradually expanded the indications for their use in the treatment of non-neoplastic diseases, such as acute trauma with severe bone loss and poor bone quality, post-traumatic failures (nonunion and infection sequelae), large complex bone defects in prosthetic revisions or periprosthetic fractures with loosening of the components and scarce bone stock.<sup>4-8</sup> Endoprosthetic treatment of these conditions has grown in popularity in recent years, particularly for the distal femur and proximal tibia with knee joint involvement.<sup>6</sup>

When used for the treatment of bone tumors, these systems have a high rate of complications and failures due to various factors, which makes revision surgery relatively frequent.<sup>2,3,8-11</sup> In the case of non-neoplastic conditions, the failure rate of endoprostheses is also high, although different from oncologic diseases, and the predominant causes may be different.<sup>6</sup>

The purpose of this study was to evaluate our experience with the use of endoprostheses for the treatment of non-neoplastic conditions affecting the knee joint. The objective was to evaluate the functional, clinical and radiographic outcomes, implant survival, and the causes of eventual failure, comparing them with those reported in the literature.

## MATERIALS AND METHODS

A retrospective, analytical and descriptive study was carried out, in addition to an analysis of the literature on the subject. We selected patients who had undergone knee endoprosthesis placement in our hospital for the treatment of non-neoplastic or post-neoplastic conditions (i.e., patients whose initial disease was a bone tumor but who needed a knee endoprosthesis for reasons other than the disease). The period from January 2012 to December 2019 was taken into account. The minimum accepted follow-up was six months.

The inclusion criteria were: patients of both sexes, without age restriction, with a diagnosis of non-tumor disease (fractures, pseudarthrosis, infections, etc.) or post-neoplastic disease (infection, implant rupture, aseptic loosening, etc.) that compromised the knee joint and required reconstruction with a non-conventional knee prosthesis (endoprosthesis) or its revision. Exclusion criteria were: patients with similarly treated primary or metastatic oncologic disease. The termination criterion was: patients who desired to withdraw from the research protocol of their own free will, as stated in writing on the informed consent withdrawal form.

Sixteen unconventional knee prostheses were evaluated in 14 patients. Three patients (4 prostheses) were excluded because they suffered from oncologic conditions. None discontinued the study. Finally, 12 prostheses were analyzed in 11 patients: nine with non-neoplastic disease and three with post-neoplastic disease (Table 1).

### Patient evaluation

In addition to a thorough assessment of their medical records, all patients were scheduled for an anamnesis and physical examination by the same specialist to objectively assess their functional status.

The patient's medical record was reviewed to establish the date of surgery, the patient's age at the time of surgery, the diagnosis, the location of the disease, the type of implant utilized, the date of revision surgery, if applicable, and any other possible complications.

**Table 1.** Patient characteristics

Patient	Date of surgery	Follow-up (months)	Sex	Age	Diagnosis	Location (Bone)	Side
1	14 Mar 2009	73	F	87	Fracture	Distal femur	Right
2	31 Jan 2014	74	M	72	Prosthetic infection	Distal femur	Right
3	16 Sept 2014	68	M	78	Prosthetic infection	Distal femur	Right
4	06 Nov 2014	66	F	56	Tibial plate fracture	Proximal tibia	Right
5	20 Sept 2010	55	F	65	Prosthetic infection	Distal femur + Proximal tibia	Right
6*	07 Jan 2015	64	F	41	Osteosarcoma	Distal femur	Left
7	30 Apr 2015	61	M	67	Periprosthetic fracture	Distal femur	Right
8‡	15 Nov 2016	42	F	77	Aseptic loosening, bone lymphoma	Distal femur	Right
9#	28 Mar 2016	40	M	77	Nonunion	Distal femur	Left
9	15 Jul 2019	10	M	80	Aseptic loosening, nonunion	Distal femur	Left
10	22 Nov 2016	25	M	25	Tibial mucormycosis of the anterior cruciate ligament	Proximal tibia	Left
11*	17 Nov 2017	30	M	15	Fibrosarcoma	Distal femur	Left
12*	16 Nov 2018	18	M	72	Chondrosarcoma	Distal femur	Right
13‡	20 Nov 2018	18	M	16	Bone graft nonunion, osteosarcoma	Distal femur	Left
14‡	04 Jun 2019	11	F	37	Prosthesis breakage, osteosarcoma	Distal femur	Left

F = female; M = male.

\*Patients with post-neoplastic conditions.

#Patient 9 is included twice, because a non-conventional prosthesis was placed twice.

‡Excluded from the study for having a tumor disease.

Revision surgeries were defined as any operation related to total or partial failure of the prosthesis. All failures were classified according to Henderson<sup>10,12</sup> (Table 2). This system was previously modified for use in non-neoplastic cases and was divided as follows: soft tissue complications (type 1), aseptic loosening (type 2), structural complications (type 3), and periprosthetic infections (type 4).

The clinical examination and functional assessment were performed using the *Musculoskeletal Tumor Society* (MSTS) score.<sup>13</sup> Although it is a score initially designed for tumor disease, given the similarity of treatment (non-conventional prostheses), we believe it is adequate for the evaluation of our patients (Table 3).

All had radiographs taken to assess the condition of the prosthesis at the time of the study as well as the presence of signs or symptoms of implant failure (loosening, rupture, etc.) that were not included in the clinical record.

**Table 2.** Henderson et al. classification for failures in limb-sparing surgery after endoprosthetic reconstruction

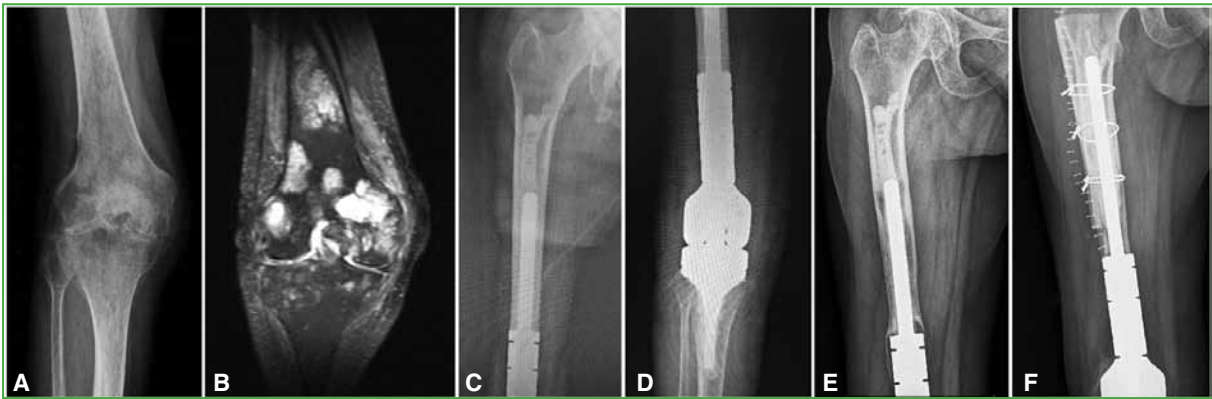General category	Type	Cause	Subtype
Mechanics	1	Soft tissue failure	A - Functional
			B - Coverage
	2	Aseptic loosening	A - Early (<2 years)
			B - Late (>2 years)
	3	Structural failure	A - Implant
			B - Graft
Non-mechanical	4	Infection	A - Early (<2 years)
			B - Late (>2 years)
	5	Tumor progression	A - Soft tissue
			B - Bone
Pediatric patients	6	Pediatric failures	A - Growth arrest
			B - Joint dysplasia

**Table 3.** *Musculoskeletal Tumor Society* score for evaluating patients with segmental long bone resections and unconventional prosthetic reconstruction.

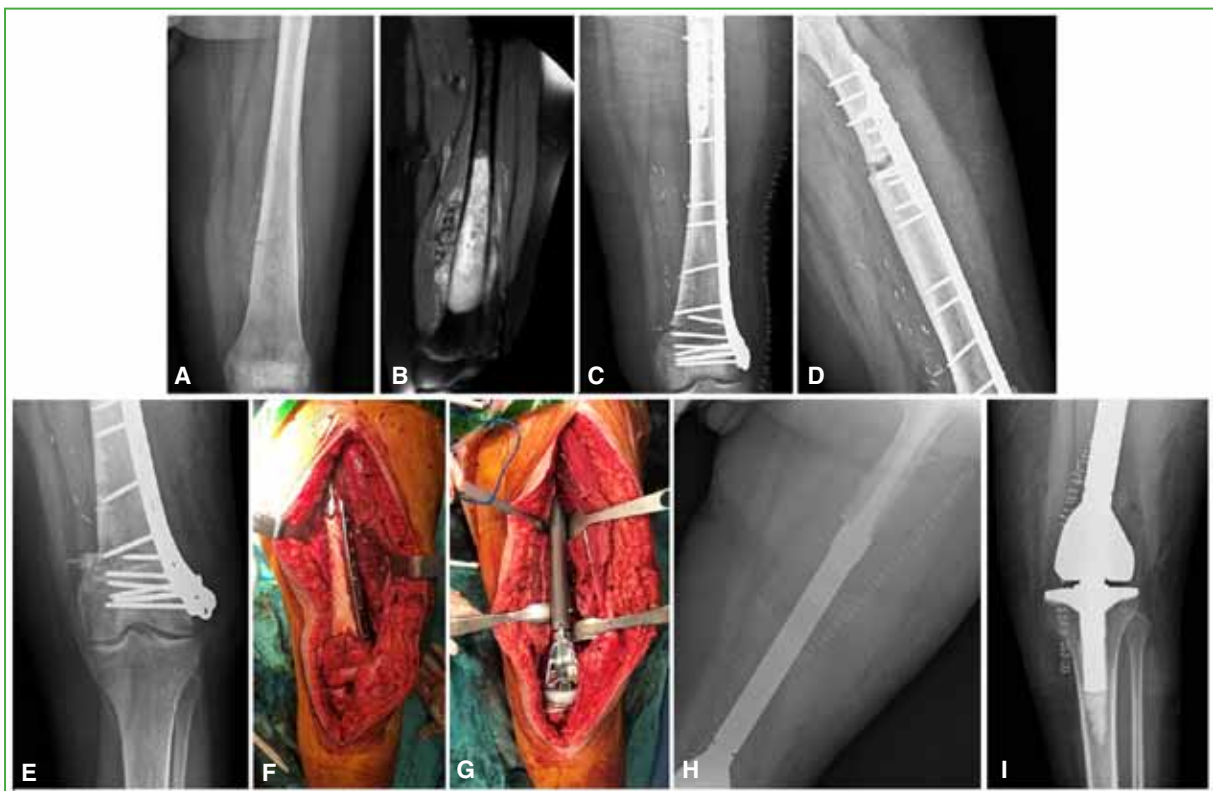
Score of the <i>Musculoskeletal Tumor Society</i>	
Pain	0-5
Range of motion	0-5
Strength	0-5
Stability	0-5
Deformity	0-5
Function	0-5
Acceptance	0-5
Total	0-35
Result (%)	0-100

## RESULTS

Twelve prostheses were analyzed in 11 patients (9 primary and 3 revisions). Six patients were male and five were female. The average age was 60 years (range 16-87). Follow-up ranged from 6.2 years to 11 months (mean 3.8 years). [Table 1](#) lists the diagnoses. In total, nine prostheses had been placed for non-neoplastic conditions and three for post-neoplastic conditions (one aseptic loosening, one pseudarthrosis of the bone graft and one implant rupture) ([Figures 1-3](#)).

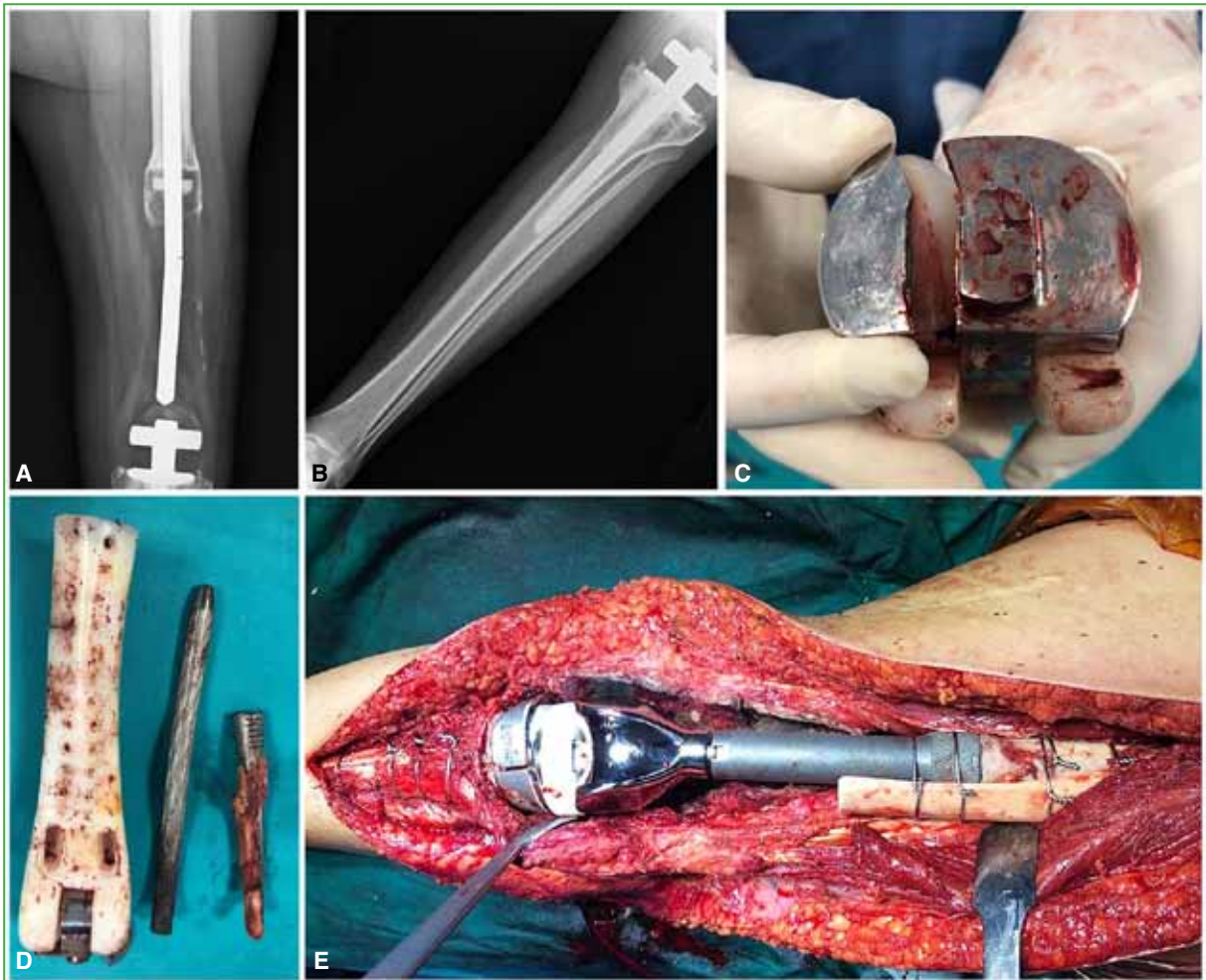


**Figure 1.** Revision for aseptic loosening in a patient with distal femoral bone lymphoma. **A and B.** Initial anteroposterior right knee radiograph and right knee MRI. **C and D.** Postoperative anteroposterior radiographs of the right femur and knee. **E.** Anteroposterior radiograph of the right femur 13 months after surgery. Signs of aseptic endoprosthesis loosening can be observed. **F.** Anteroposterior radiograph of the right femur after the revision.



**Figure 2.** Graft nonunion in a patient with osteosarcoma of the distal femur. The evolution is observed. **A and B.** Initial preoperative anteroposterior left femur radiograph and MRI. **C.** Anteroposterior radiograph of the femur and left knee in the immediate postoperative period. **D and E.** Anteroposterior radiographs of the femur and left knee 12 months after surgery. Signs of prosthetic loosening can be observed. **F and G.** Intraoperative images of the revision. **H e I.** Anteroposterior radiographs of the left femur and knee after the revision.





**Figure 3.** Revision of non-conventional distal femur prosthesis due to implant breakage. **A and B.** Preoperative anteroposterior radiographs of the left femur, knee and tibia. **C and D.** Intraoperative images of the ruptured implant. **E.** Intraoperative image of the final result.

The types of prostheses used for reconstruction had some variation and were: seven IOT-HCFMUSP Modular System prostheses (MDT Implantas, Rio Claro, SP, Brazil), three Megasystem-C prostheses (Waldemar Link GmbH & Co, Hamburg, Germany) and two OSS™ Orthopedic Salvage System (Biomet, Warsaw, IN, USA).

In detail, nine endoprotheses were implanted in the distal femur (75%), two in the proximal tibia (16.7%) and one each in the distal femur and proximal tibia (8.3%). When a proximal tibial prosthesis was implanted, the extensor mechanism was reconstructed by suturing the patellar tendon to the tibial component, which provides fixation holes in its proximal part, and creating a gastrocnemius rotational flap to enhance tendon reattachment. No patellar osteotomies were performed. Cemented stems were always used in both femur and tibia. Hinged prostheses (MDT) were placed in seven cases and a rotating hinge (Waldemar Link GmbH & Co and Biomet) in five.

The average time from primary surgery to implant failure was 47.5 months and ranged from 55 to 40 months.

The implant failed in two patients (18%) and the causes were: infection and aseptic loosening. The first case (patient 5) was a patient who suffered a surgical site infection following primary total knee arthroplasty, and required knee endoprosthesis reconstruction after treating the infection. Finally, due to another infection, the endoprosthesis was removed and an antibiotic-infused spacer was implanted. After this, the patient was lost to follow-up. The

second case (patient 9) was a patient who suffered a distal femur fracture that progressed to pseudarthrosis and had a knee endoprosthesis placed. After 40 months, he underwent revision surgery for aseptic loosening of the prosthesis.

Using Henderson's classification,<sup>10</sup> the types of endoprosthesis failure in our series were: type 2 mechanical failure, i.e., aseptic loosening (n = 1; 50%) and type 4 infection or failure (n = 1; 50%). There were no cases of soft tissue or structural failure, such as implant rupture or periprosthetic fracture.

At the time of this study, one of the 11 patients had died of other causes unrelated to knee disease (patient 1). Nine of the remaining 10 were available for clinical and radiographic evaluation.

Functional assessment was performed in nine patients. Mean scores for individual parameters were: pain 4.3 (range 0-5), range of motion 3.4 (range 0-5), strength 3.6 (range 0-5), stability 3.8 (range 0-5), deformity 4.1 (range 0-5), function 3.4 (range 0-5), and emotional acceptance 4.1 (range 1-5). The mean score was 26.8 (range 19-35), representing a mean final score of 76.6% (Table 4).

**Table 4.** Functional outcome according to the *Musculoskeletal Tumor Society* (MSTS Score)

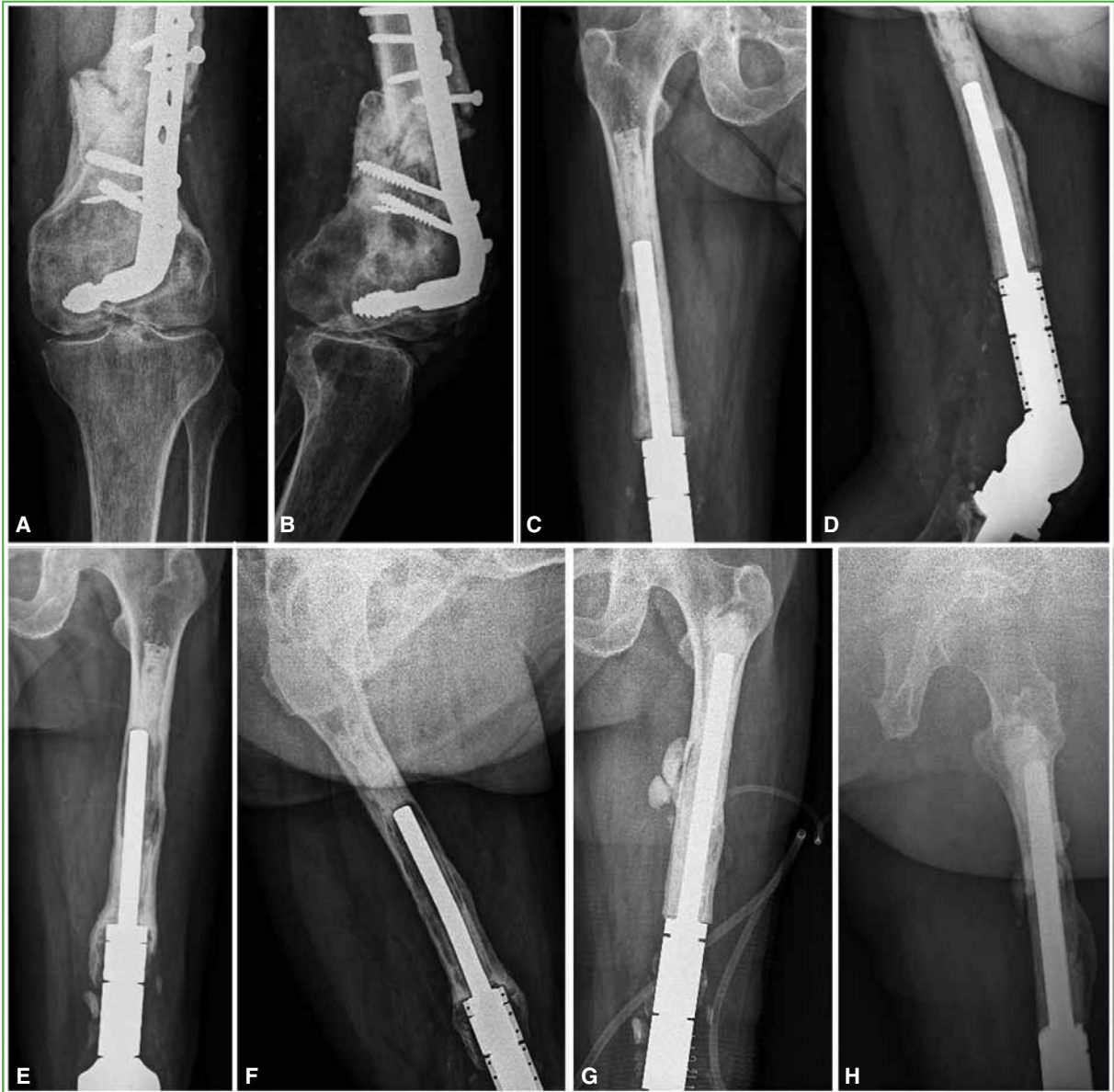MSTS SCORE									
Patient	Pain	Range of motion	Strength	Stability	Deformity	Function	Acceptance	Total	Result (%)
1	-	-	-	-	-	-	-	-	-
2	4	3	3	4	4	3	4	25	71.40%
3	5	3	4	4	4	4	4	28	80%
4	5	3	3	3	3	3	5	25	71.40%
5	-	-	-	-	-	-	-	-	-
7	3	3	3	3	4	3	2	21	60%
8	3	2	3	3	3	2	3	19	54.30%
9	5	5	4	4	5	4	5	32	91.40%
10	4	3	3	3	4	3	4	24	68.60%
13	5	5	5	5	5	5	5	35	100%
14	5	4	4	5	5	4	5	32	91.40%

According to the radiographs, no patient had signs of infection, loosening of the material, prosthesis breakage, periprosthetic fracture, or any other signs of implant failure at the time of analysis. It should be noted that, in patient 9, the radiographs prior to the revision were also evaluated, where signs of aseptic loosening were observed (Figures 4 and 5).

Tables 1 and 4 summarize the data, evolution and MSTS of each patient included in the study.

## DISCUSSION

Endoprostheses or unconventional prostheses have become the method of choice for onco-orthopedic surgeons after major oncologic resections because they provide a very good option for the reconstruction and replacement of skeletal segments.<sup>1</sup> Currently, endoprostheses are also gaining momentum as a useful and effective reconstructive strategy when bone loss is significant after non-neoplastic diseases, such as acute trauma with severe bone loss, nonunion, infections, loss of bone stock in prosthetic revisions, periprosthetic fractures, etc.<sup>4-8</sup>



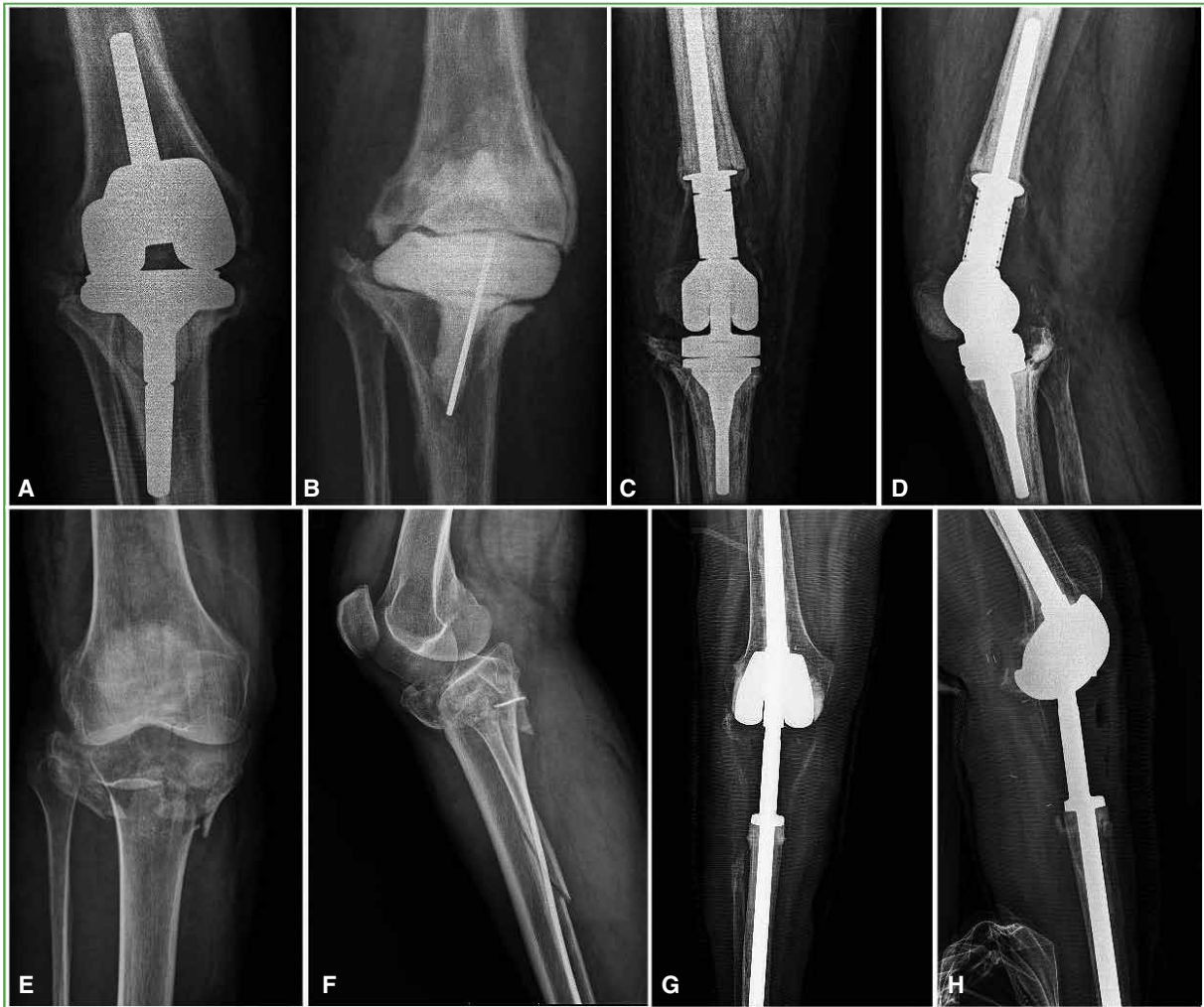**Figure 4.** Distal femur nonunion and subsequent aseptic loosening. The patient's evolution is observed. **A and B.** Initial anteroposterior and lateral radiographs of the left knee. Nonunion of a distal femur fracture. **C and D.** Anteroposterior and lateral radiographs of the left femur in the immediate postoperative period. **E and F.** Anteroposterior and lateral radiographs of the left femur showing signs of aseptic loosening of the endoprosthesis. **G and H.** Anteroposterior and lateral radiographs of the left femur after the revision.

It has been shown that the implant survival rate of endoprostheses does not differ significantly between individuals with post-neoplastic disease and those with non-neoplastic conditions.<sup>14</sup>

In this study, we evaluated patients with non-neoplastic and post-neoplastic conditions who had been treated with knee endoprostheses.

Aside from the increased use and popularity of endoprostheses, implant survival remains the primary concern that may limit the routine use of endoprostheses to manage non-neoplastic conditions.<sup>2,3,6,8-11</sup> In this regard, it should be noted that patients with non-neoplastic conditions such as post-traumatic, infectious, and periprosthetic





**Figure 5.** Examples of knee reconstruction with non-conventional prosthesis. **A-D.** Distal femur. **E-H.** Proximal tibia.

conditions exhibit characteristics that are distinct and different from those of oncologic patients. General condition and comorbidities, soft tissue status, lesion characteristics, previous surgeries, presence of adhesions, and previous infections are factors that should be carefully considered when using the endoprosthesis in these cases. These factors are very important in determining whether or not the prosthesis will fail.<sup>5</sup>

Highly variable and contrasting results have been published on implant survival in these patients. For example, Berend and Lombardi<sup>7</sup> reported an overall reoperation-free survival rate of 97% after 1 year, 95% after 2 years and 83% after 5 years for distal femoral and knee endoprostheses. In contrast, the systematic review by Korim et al. yielded a mean failure rate of 83% after 3.3 years for distal femoral prostheses.<sup>6</sup>

In our study, with a mean follow-up of 3.8 years, the failure rate was 18%. Although the results published on this subject vary widely, our results are encouraging and fall within the range mentioned in the literature.

Infection remains one of the most challenging complications after joint replacement and a major cause of early implant failure.<sup>15</sup> While the overall infection rate is relatively low (about 1% after primary hip and knee arthroplasties),<sup>16</sup> this rate increases dramatically if certain risk factors are present, such as poor health status, extensive soft tissue resection, prolonged surgery times, and the need for multiple blood transfusions.<sup>9,17</sup> In addition, a history of surgical site infection is also considered one of the main risk factors for reinfection after

endoprosthetic reconstruction.<sup>18</sup> All of these factors come into play when performing treatment with a knee endoprosthesis.

A deep infection after knee endoprosthetic replacement can be a devastating complication that increases the need for further surgical procedures and leads to endoprosthesis failure.

The infection rate of endoprostheses following tumor resections or their use in non-tumor conditions is high in both cases but does not differ significantly. In patients with tumor disease, Jeys et al.<sup>11</sup> reported infection rates of 11%, with a high incidence of infection in the first two years. Pala et al.<sup>2</sup> and Mavrogenis et al.<sup>19</sup> published infection rates of 9.3% and 8.6%, respectively. In a systematic review by Racano et al.,<sup>20</sup> the mean periprosthetic infection rate was 10%.

For non-neoplastic conditions, De Gori et al.<sup>14</sup> reported an infection rate of 11.5%, while Korim et al. found a mean rate of 15% for distal femoral prostheses.<sup>6</sup>

In our study, there was only one case of periprosthetic infection (case 5), which represented 9.1% of the total. This corresponds to what has been published in the literature.

In the treatment of non-neoplastic conditions, rates of aseptic loosening of endoprostheses range from 0% to 9.5%.<sup>4</sup> In our series, there was only one case (patient 9) (9.1%).

There is no clear consensus on one fixation method versus another, nor is it clear whether cemented and cementless endoprostheses have comparable survival and complications.<sup>3,21</sup> Regarding aseptic loosening, in some studies, the risk was lower with cementless prostheses,<sup>1,19</sup> while other authors, such as Houdek et al.,<sup>8</sup> did not observe such a difference. In our study, cemented stem endoprostheses were always used in both femur and tibia.

The hinge mechanism is also considered an important factor that could increase the risk of aseptic loosening in knee endoprostheses. Hinge designs in knee endoprostheses cause stress between the prosthesis-cement or prosthesis-bone interface, which increases the incidence of loosening.<sup>22</sup> The addition of the rotating hinge is an important design modification that helps to reduce these mechanical stresses at the implant-bone interface.<sup>23</sup>

In our series, a hinged prosthesis was used in seven patients and a rotating hinge prosthesis in five others. The only case of aseptic loosening (patient 9) occurred with a hinged endoprosthesis.

Another factor to consider is that the long lengths of these prostheses create large bending stresses at the prosthesis-bone interface that can contribute to loosening and periprosthetic fracture or fracture of the prosthesis itself.<sup>22</sup> In our series, there were no structural failures, such as prosthesis breakage or periprosthetic fractures.

Regarding the postoperative assessment of function and quality of life, several studies have shown that treatment with knee endoprostheses results in good function and pain relief, and also significantly improves patients' quality of life.<sup>7,24</sup>

Although it is a score initially designed for tumor disease, given the similarity of the treatment (non-conventional prostheses), we used the MSTs<sup>13</sup> for functional assessment.

According to the literature, the overall mean outcome in MSTs in patients with endoprosthetic reconstructions varies from 78% to 86%,<sup>2</sup> but most studies include patients with tumor disease.

In our series, the average MSTs was 76.6%, comparable to other findings in the literature.<sup>25</sup>

The joint range of motion and function scores were the lowest of all, with an average score of 3.4 (range 2-5). Similarly, Tun et al. and McGoveran et al. also found lower function scores.<sup>25</sup>

We note that there is a correlation between low overall functional scores and low scores in function, joint range of motion and strength, while pain-related and emotional acceptance scores are better.

Our study has certain limitations that must be considered. This is a retrospective, non-randomized study with a small number of patients, which exposes it to biases of various types. Differences in diagnosis and the fact that the prostheses are from different manufacturers and with different implant designs are also factors that can affect the results. Other weaknesses of the study are that the follow-up time was not long enough in all cases and a great diversity of age groups was analyzed. As strengths, we can mention that it is a single-site study with only a few surgeons responsible for the placement of all endoprostheses.

## CONCLUSIONS

Despite the fact that it is a demanding surgical procedure with many complications, our findings support the use of modular endoprostheses as a solution to manage complex non-neoplastic conditions. It is possible to state that our complication rate, such as infection and aseptic loosening, as well as implant survival and functional outcome, are similar to those published.

Endoprostheses deserve to be explored as a limb salvage option in carefully selected patients when other surgical treatments are not feasible, considering the favorable results in published studies.

We recommend this reconstruction method for the treatment of the aforementioned diseases.

Conflict of interest: The authors declare no conflicts of interest.

J. M. Varaona ORCID ID: <https://orcid.org/0000-0003-3540-4809>

L. Prado ORCID ID: <https://orcid.org/0000-0001-6759-3152>

F. Tálamo ORCID ID: <https://orcid.org/0000-0001-9060-6433>

P. Pérez Cortés ORCID ID: <https://orcid.org/0000-0002-3324-7048>

## REFERENCES

1. Capanna R, Scoccianti G, Frenos F, Vilardi A, Beltrami G, Campanacci DA. What was the survival of megaprostheses in lower limb reconstructions after tumor resections? *Clin Orthop Relat Res* 2015;473(3):820-30. <https://doi.org/10.1007/s11999-014-3736-1>
2. Pala E, Trovarelli G, Calabrò T, Angelini A, Abati CN, Ruggieri P. Survival of modern knee tumor megaprostheses: Failures, functional results, and a comparative statistical analysis. *Clin Orthop Relat Res* 2015;473(3):891-9. <https://doi.org/10.1007/s11999-014-3699-2>
3. Ahlmann ER, Menendez LR, Kermani C, Gotha H. Survivorship and clinical outcome of modular endoprosthetic reconstruction for neoplastic disease of the lower limb. *J Bone Joint Surg Br* 2006;88:790-5. <https://doi.org/10.1302/0301-620X.88B6.17519>
4. Windhager R, Schreiner M, Staats K, Apprich S. Megaprostheses in the treatment of periprosthetic fractures of the knee joint: indication, technique, results and review of literature. *Int Orthop* 2016;40(5):935-43. <https://doi.org/10.1007/s00264-015-2991-4>
5. Calori GM, Colombo M, Malagoli E, Mazzola S, Bucci M, Mazza E. Megaprosthesis in post-traumatic and periprosthetic large bone defects: issues to consider. *Injury* 2014;45(6):S105-S110. <https://doi.org/10.1016/j.injury.2014.10.032>
6. Korim MT, Esler CNA, Reddy VRM, Ashford RU. A systematic review of endoprosthetic replacement for non-tumour indications around the knee joint. *Knee* 2013;20(6):367-75. <https://doi.org/10.1016/j.knee.2013.09.001>
7. Berend KR, Lombardi Jr AV. Distal femoral replacement in nontumor cases with severe bone loss and instability. *Clin Orthop Relat Res* 2009;467(2):485-92. <https://doi.org/10.1007/s11999-008-0329-x>
8. Houdek MT, Wagner ER, Wilke BK, Wyles CC, Taunton MJ, Sim FH. Long term outcomes of cemented endoprosthetic reconstruction for periarticular tumors of the distal femur. *Knee* 2016;23(1):167-72. <https://doi.org/10.1016/j.knee.2015.08.010>
9. Harges J, Gebert C, Schwappach A, Ahrens H, Streitburger A, Winkelmann W, et al. Characteristics and outcome of infections associated with tumor endoprostheses. *Arch Orthop Trauma Surg* 2006;126(5):289-96. <https://doi.org/10.1007/s00402-005-0009-1>
10. Henderson ER, Groundland JS, Pala E, Dennis JA, Wooten R, Cheong D, et al. Failure mode classification for tumor endoprostheses: retrospective review of five institutions and a literature review. *J Bone Joint Surg Am* 2011;93(5):418-29. <https://doi.org/10.2106/JBJS.J.00834>
11. Jeys LM, Grimer RJ, Carter SR, Tillman RM. Periprosthetic infection in patients treated for an oncological orthopaedic condition. *J Bone Joint Surg Am* 2005;87(4):842-9. <https://doi.org/10.2106/JBJS.C.01222>

12. Pala E, Henderson ER, Calabrò T, Angelini A, Abati CN, Trovarelli G, et al. Survival of current production tumor endoprostheses: complications, functional results, and a comparative statistical analysis. *J Surg Oncol* 2013;108(6):403-08. <https://doi.org/10.1002/jso.23414>
13. Saebye CKP, Keller J, Baad-Hansen T. Validation of the Danish version of the musculoskeletal tumour society score questionnaire. *World J Orthop* 2019;10(1):23-32. <https://doi.org/10.5312/wjo.v10.i1.23>
14. De Gori M, Scoccianti G, Frenos F, Bettini L, Familiari F, Gasparini G, et al. Modular endoprostheses for nonneoplastic conditions: Midterm complications and survival. *BioMed Res Int* 2016;2016:2606521. <https://doi.org/10.1155/2016/2606521>
15. Willis-Owen CA, Konyves A, Martin DK. Factors affecting the incidence of infection in hip and knee replacement: an analysis of 5277 cases. *J Bone Joint Surg Br* 2010;92(8):1128-33. <https://doi.org/10.1302/0301-620X.92B8.24333>
16. Lamagni T. Epidemiology and burden of prosthetic joint infections. *J Antimicrob Chemother* 2014;69(1):i5-i10. <https://doi.org/10.1093/jac/dku247>
17. Pilge H, Gradl G, von Eisenhart-Rothe R, Gollwitzer H. Incidence and outcome after infection of megaprostheses. *Hip Int* 2012;22(Suppl 8):S83-S90. <https://doi.org/10.5301/HIP.2012.9576>
18. Morii T, Yabe H, Morioka H, Beppu Y, Chuman H, Kawai A, et al. Postoperative deep infection in tumor endoprosthesis reconstruction around the knee. *J Orthop Sci* 2010;15(3):331-9. <https://doi.org/10.1007/s00776-010-1467-z>
19. Mavrogenis AF, Pala E, Angelini A, Calabro T, Romagnoli C, Romantini M, et al. Infected prostheses after lower-extremity bone tumor resection: clinical outcomes of 100 patients. *Surg Infect (Larchmt)* 2015;16(3):267-75. <https://doi.org/10.1089/sur.2014.085>
20. Racano A, Pazonis T, Farrokhyar F, Dehesi B, Ghert M. High infection rate outcomes in long-bone tumor surgery with endoprosthetic reconstruction in adults: a systematic review. *Clin Orthop Relat Res* 2013;471(6):2017-27. <https://doi.org/10.1007/s11999-013-2842-9>
21. Pala E, Mavrogenis AF, Angelini A, Henderson ER, Letson DG, Ruggieri P. Cemented versus cementless endoprostheses for lower limb salvage surgery. *J BUON* 2013;18(2):496-503. PMID: 23818368
22. Taylor SJ, Walker PS, Perry JS, Cannon SR, Woledge R. The forces in the distal femur and the knee during walking and other activities measured by telemetry. *J Arthroplasty* 1998;13(4):428-37. [https://doi.org/10.1016/s0883-5403\(98\)90009-2](https://doi.org/10.1016/s0883-5403(98)90009-2)
23. Pala E, Trovarelli G, Angelini A, Maraldi M, Berizzi A, Ruggieri P. Megaprosthesis of the knee in tumor and revision surgery. *Acta Biomed* 2017;88(2S):129-38. <https://doi.org/10.23750/abm.v88i2-S.6523>
24. Al-Taki MM, Masri BA, Duncan CP, Garbuz DS. Quality of life following proximal femoral replacement using a modular system in revision THA. *Clin Orthop Relat Res* 2011;469(2):470-5. <https://doi.org/10.1007/s11999-010-1522-2>
25. Tunn PU, Pomraenke D, Goerling U, Hohenberger P. Functional outcome after endoprosthetic limb-salvage therapy of primary bone tumours—a comparative analysis using the MSTS score, the TESS and the RNL index. *Int Orthop* 2008;32:619-25. <https://doi.org/10.1007/s00264-007-0388-8>