

Obturator Pyomyositis in a Pediatric Patient Resolved by Ultrasound-Guided Percutaneous Drainage. Case Report

Pablo M. Enríquez Romo,^{*} Erika J. Bonifaz Manzano,^{*} Jamil Cedillo-Balcázar,^{**} Nicolás E. Rodríguez Vélez,^{**} J. Fernando Soto-Alvarado^{**}

^{*}Orthopedic-Traumatology Service, Hospital General "Manuel Ygnacio Monteros", Ecuador

^{**}School of Health Sciences, Universidad Técnica Particular de Loja, Ecuador

ABSTRACT

The objective of this case report is to present the management of a case of pyogenic myositis of the obturator muscle in a pediatric patient using ultrasound-guided percutaneous drainage. The patient is a 5-year-old pediatric patient with clinical and laboratory manifestations of deep muscular infection at the obturator level, an area of difficult surgical access, for which the least invasive treatment possible was used to drain purulent content from the affected area. The use of magnetic resonance imaging studies allows for a more accurate diagnosis in cases of early pyogenic infection, as well as determining the most effective approach to treatment. In some cases, ultrasound guidance can be used to avoid a formal surgical approach, reducing wound complications and morbidity and mortality. The addition of image-guided percutaneous procedures is a very useful tool for the treatment of infectious diseases and a great help to the orthopedist.

Keywords: Pyomyositis; childhood; ultrasound; drainage.

Level of Evidence: V

Piomiositis de los obturadores tratada con drenaje percutáneo guiado por ecografía en un niño. Presentación de un caso

RESUMEN

El objetivo de esta presentación es dar a conocer el manejo de la miositis piógena del músculo obturador interno en un paciente pediátrico que fue tratado mediante un drenaje percutáneo guiado por ecografía. Se trata de un niño de 5 años de edad, con manifestaciones clínicas y valores de laboratorio de infección muscular profunda en el obturador interno. Se identificó específicamente con resonancia magnética, es un área de difícil acceso quirúrgico, por lo cual se realizó un tratamiento percutáneo guiado por ecografía que permitió drenar el contenido purulento de la zona afectada. La resonancia magnética hizo posible lograr un diagnóstico más acertado en los casos de infección piógena temprana y, a su vez, decidir la vía de abordaje más adecuada. En ocasiones, se puede optar por la guía ecográfica con la cual se evita el abordaje quirúrgico formal y así disminuyen las complicaciones de la herida y la mayor morbimortalidad. La adición de procedimientos percutáneos guiados por imágenes es una herramienta muy útil para tratar enfermedades infecciosas y una gran ayuda para el ortopedista.

Palabras clave: Piomiositis; infancia; ecografía; drenaje.

Nivel de Evidencia: V

INTRODUCTION

Pyomyositis of the obturator internus muscle is a rare disease that is difficult to diagnose and treat and can be confused with intra-articular infections. It usually occurs in children and after trauma or muscle injury due to overexertion.¹

Although the exact pathogenesis is not known, pyomyositis is associated with muscle injury and bacteremia. It is believed that transient bacteremia may develop an infection in the context of a pre-existing muscle abnormality affecting the muscle's innate defense to infection, parasitosis, or trauma.^{2,3} Other underlying conditions

Received on October 14th, 2022. Accepted after evaluation on August 7th, 2023 • Dr. PABLO M. ENRÍQUEZ ROMO • pablenq@gmail.com  <https://orcid.org/0000-0002-2327-0025>

How to cite this article: Enríquez Romo PM, Bonifaz Manzano EJ, Cedillo-Balcázar J, Rodríguez Vélez NE, Soto-Alvarado JF. Obturator Pyomyositis in a Pediatric Patient Resolved by Ultrasound-Guided Percutaneous Drainage. Case Report. *Rev Asoc Argent Ortop Traumatol* 2023;88(6):669-675. <https://doi.org/10.15417/issn.1852-7434.2023.88.6.1677>

that may predispose to this disease are: malnutrition, diabetes mellitus, human immunodeficiency virus infection, inflammatory bowel disease, autoimmune diseases, chronic liver diseases, rheumatological conditions or intravenous drug use.⁴

Regardless of age group, *Staphylococcus aureus* is the main cause in 90% of cases; therefore, the initial antibiotic treatment should include a broad-spectrum agent with adequate coverage for *S. aureus*, and should be modified according to the results of the cultures and sensitivity tests; likewise, the treatment will depend on the characteristics of the clinical picture and the structures affected.^{4,5}

As this is an infrequent condition, the diagnosis is often delayed, leading to serious complications and prolonged treatment. The prognosis is directly proportional to the time of detection. Although case history and laboratory tests can guide the diagnosis, the key is diagnostic imaging. Magnetic resonance imaging is preferred to easily delimit and locate abscessed areas, although computed tomography may also be useful. The use of imaging studies makes it easier to exclude intra-articular diseases and to determine the possibility of performing percutaneous draining.^{6,7}

Ultrasound is considered one of the main initial evaluation techniques in patients with muscle disease, because it is easily accessible and allows the radiologist or orthopedist to identify injuries and perform guided procedures.

The objective of this presentation is to present the management of a case of pyogenic myositis of the obturator internus muscle in a pediatric patient who was treated with percutaneous drainage guided by ultrasound.

CLINICAL CASE

The patient is a 5-year-old, mixed race child with no significant personal pathological history. He attended the emergency service with his parents, because, six days before, he had fallen from his own height, which caused minor trauma to the medial side of his thigh. The condition progressed and was accompanied by moderate pain (visual analog scale 5/10) which was continuous and poorly defined, as well as progressive limping associated with an unquantified high temperature.

The physical examination revealed a heart rate of 109 beats/min, a respiratory rate of 20 breaths/min, a temperature of 36.6 °C, oxygen saturation of 96% and anthropometric measures appropriate for age. He had a pale, asthenic appearance and antalgic posture. The gait is claudicant with a flexed hip. There is no erythema in the extremities, but there is slight edema in the left thigh and an increase in volume in comparison to the contralateral thigh, as well as severe pain on superficial and deep palpation in the left groin, with no limitation of flexion or hip rotations, and pain and limitation of extension.

The anteroposterior and axial radiographs of the hip showed no lytic changes or periosteal changes that could indicate an infection (Figure 1).

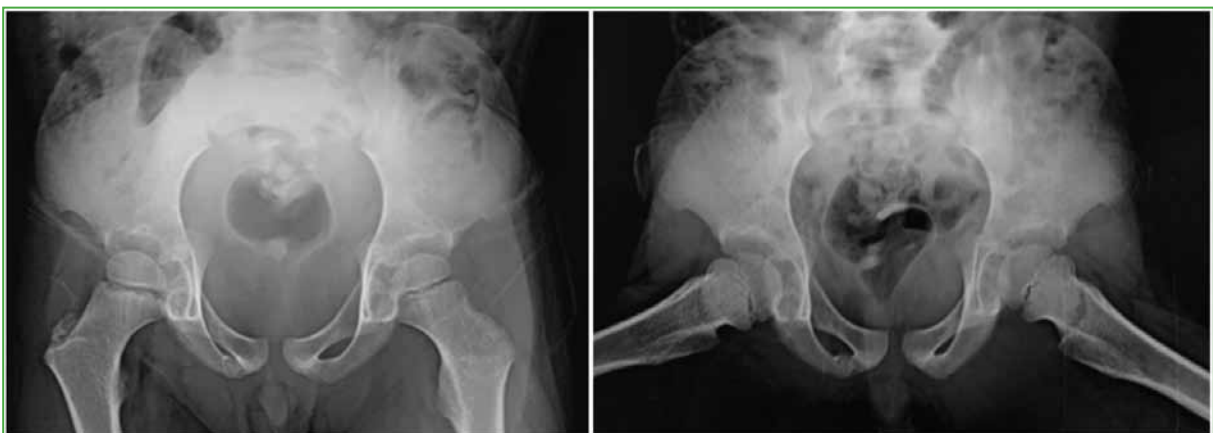

Figure 1. Radiographs of the pelvis (AP) and bilateral hip (axial). There are no signs of bone damage. Preserved osteoarticular relationships.

The results of the laboratory tests were: elevation of acute-phase reactants: C-reactive protein 24 mg/dl, erythrocyte sedimentation rate 19 mm/h; leukocytosis 23,200 g/l, mild neutrophilia 74.8% and mild lymphopenia 19.5%.

An ultrasound and a CT scan were performed to locate a pelvic infectious source, which was identified in the obturator internus muscle. An abscessed injury that could be drained was observed (Figure 2). We did not have the possibility of performing an initial magnetic resonance, since, in our environment, it is not possible to use it early.

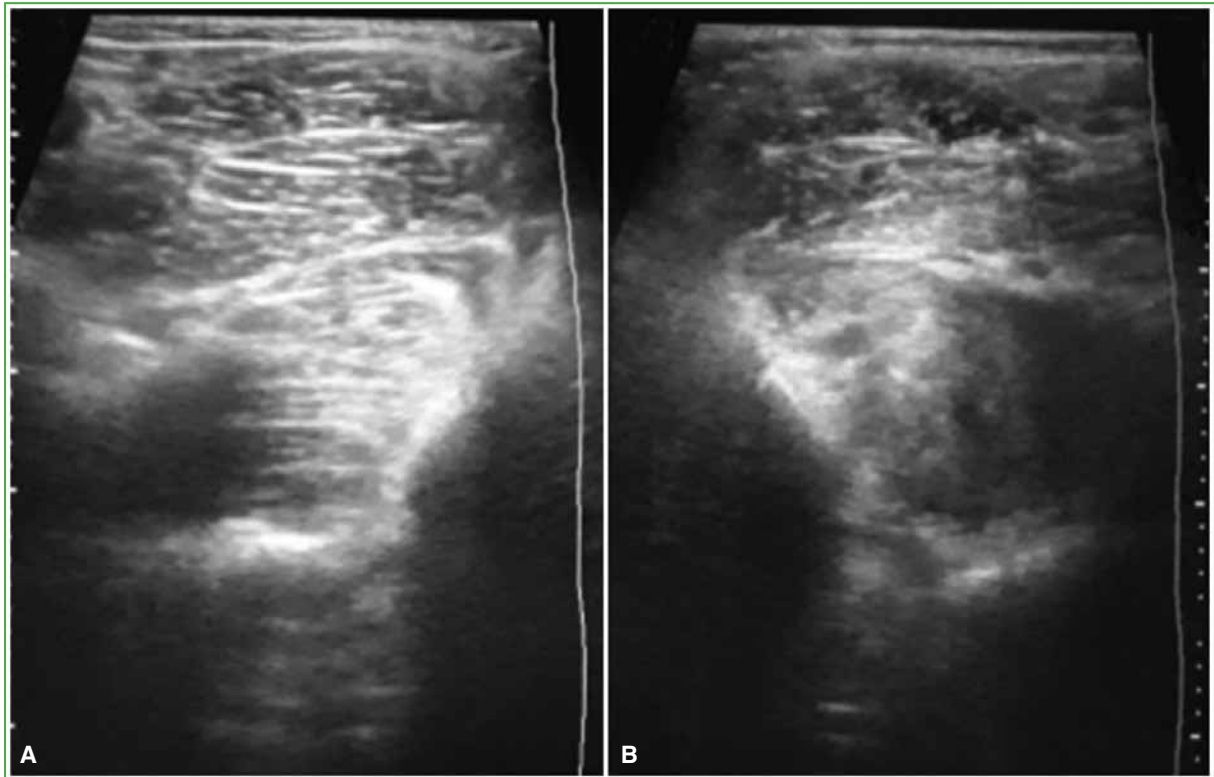


Figure 2. Comparative soft-tissue ultrasound. **A.** Unaltered right obturator externus muscle. **B.** Diffusively heterogeneous left obturator externus muscle, loss of fibrillar echotexture with intramuscular collection.

After characterizing the lesion, an emergency surgical procedure was performed together with the imaging service. Following an ultrasound-guided hip arthrocentesis in which no purulent fluid was collected, an ultrasound-guided percutaneous puncture of the abscess in the deep inguinal area was performed. A frankly purulent thick discharge was obtained from the obturator (5 cc) at the intrasubstance muscle location, which was sent for culture. The procedure was very helpful, because it allowed us to ensure that the infectious condition was extrarticular (Figures 3 and 4). Due to the patient's presenting symptoms, a joint puncture was performed; the first possibility was hip involvement, and the method of choice was arthrocentesis, which ruled out joint involvement. The intramuscular collection was identified using computed tomography; nonetheless, we believe it is necessary for epidemiology to rule out that it comes from the hip; thus, the procedures were carried out in the order listed above.

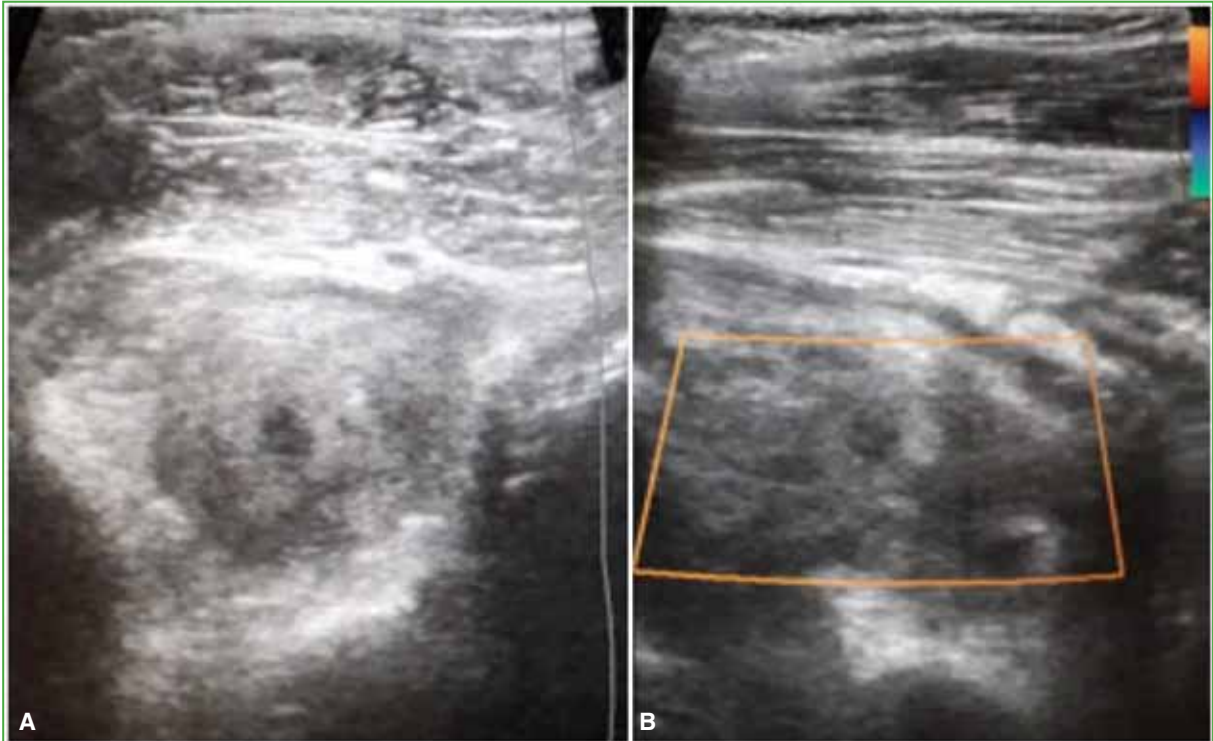


Figure 3. Soft-tissue ultrasound. **A.** Diffusely heterogeneous left obturator externus muscle, loss of fibrillar echotexture with intramuscular collection. **B.** Color Doppler shows no increase in vascularity.

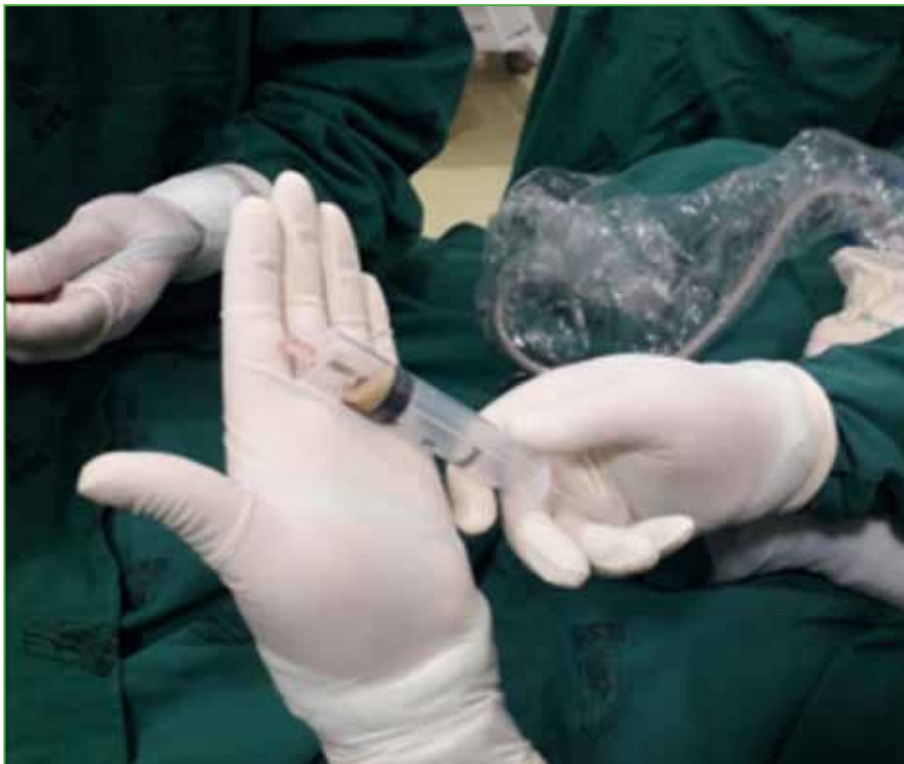

Figure 4. Clinical picture of the contents of the abscess drained by ultrasound.

During hospitalization, blood cultures were negative. Oxacillin 500 mg was administered intravenously every 6 hours. On the third day of treatment, the culture result reported oxacillin-resistant *S. aureus*, so the drug was changed to vancomycin 200 mg, every 6 h and gentamicin 38 mg, every 8 h, for 16 days.

The patient had significant improvement; pain and inflammatory markers decreased considerably, and he had no more fever peaks.

Pain, gait disturbance and periarticular muscle contracture resolved gradually, and inflammatory markers normalized. In the radiographic controls, no relapses were observed. Six days after draining, the MRI revealed an area of edema in the obturator internus muscle, but with no relapse of the collection (Figure 5). The edema gradually decreased after clinical improvement. The patient was discharged with the indication of cephalexin 350 mg, orally, every 8 hours, for 10 days and followed up on an outpatient basis.

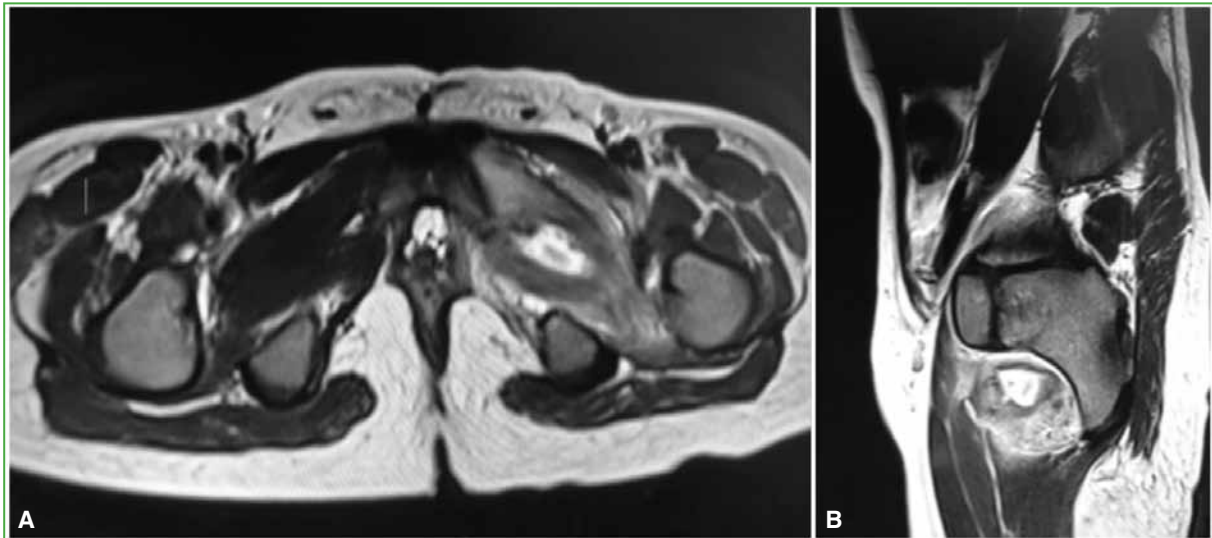


Figure 5. Magnetic resonance imaging of the pelvis enhanced in T2 sequence. **A.** Axial section. **B.** Sagittal section. Pyomyositis of the left obturator muscles, increased signal intensity of the obturator muscles, and intramuscular collection predominantly in the obturator externus muscle.

After 24 hours, hip movements improved considerably. The values of C-reactive protein and erythrocyte sedimentation rate decreased. Within a week, the patient was able to walk without support, and the acute-phase reactants normalized within 10 days.

Ultrasonounds and clinical and laboratory controls at the first, third and sixth months showed no alterations in the fibrillar pattern of the obturator internus muscle, nor did they show signs of a recurrence of the infection. A gradual reduction in muscle edema was observed. The ultrasound at six months was normal and, after a year of follow-up, the patient had no symptoms and the condition had healed.

Despite ultrasound and computed tomography of the abdomen, pelvis and lower back area, as well as laboratory tests to detect rheumatological and autoimmune diseases, including human immunodeficiency virus infection, no findings related to immunosuppression were found. Joint fluid cultures to detect tuberculosis were also negative.

DISCUSSION

Pyomyositis is a disease in tropical climates that is difficult to diagnose due to its nonspecific presentation. Its prevalence is higher in males during childhood, as in the above case.⁷⁻⁹

Muscle damage occurs during trauma, falls or strenuous exercise and is the most common predisposing factor in immunocompetent patients (25-50%).¹⁰ The most common pathogens are *S. aureus* (90%) and group A beta-hemolytic streptococcus, so initial antimicrobial treatment should be covered for gram-positive cocci.¹¹

The difficulty posed by the diagnosis of pyomyositis is due to the variety of differential diagnoses of intra-articular and extra-articular infections that must be taken into account. Multifocal involvement is considered to be common (46.34%).^{12,13} However, in this patient, this was not the case, possibly due to early diagnosis.

The time between the clinical manifestations of pyomyositis and the start of antibiotic therapy has a substantial influence on the patient's prognosis. The clinical presentation and inflammatory markers perform poorly to distinguish different types of infections (pyomyositis, septic arthritis, osteomyelitis, among others). If pyomyositis is suspected, an MRI should be performed, given its high sensitivity, to detect this infection in the early stages.¹² In the institution where the patient was treated, as well as in many hospitals, it is not immediately possible to count on this imaging study. In order to evaluate an acute musculoskeletal infectious disease, basic studies, such as radiographs and ultrasound, should be requested based on appropriate clinical suspicion.¹³ When magnetic resonance imaging is not available, computed tomography is useful by weighing the high dose of radiation a pediatric patient can receive and using it only when ultrasound is not diagnostic. The key distinction is between intraarticular and extraarticular infectious diseases. In this case, arthrocentesis and ultrasound-guided puncture confirmed the definitive diagnosis of obturator pyomyositis and excluded extraarticular conditions.¹⁴

Treatment depends on the stage of the infection at the time of diagnosis. In the initial stage, characterized by the absence of specific muscle alterations, antibiotic therapy is sufficient, then, when abscess formation is confirmed or bacteremia develops, together with antibiotics, image-guided percutaneous drainage or surgery are required.⁷

Ultrasound in the diagnosis and management of pyogenic pyomyositis has been little studied, despite the fact that it is an emerging condition that can cause catastrophic complications. In a study of 47 children with a suspected skin and tissue infection based on physical examination, ultrasound changed therapeutic management in nine of these patients.¹³ In another study with 50 patients, therapeutic management changed in 11 patients after ultrasound.¹⁴

According to a systematic review with 361 patients, the administration of antibiotics for seven days was effective in 143 cases and 218 required drainage. When the collection is <1 cm, outpatient antibiotic therapy is recommended, and drainage is advised when the collection is >1.¹⁵

CONCLUSIONS

Early management of this disease is essential for a good outcome; likewise, it is essential to exclude an intra-articular condition to avoid inadequate treatment. Ultrasound-guided drainage is an effective, low-risk method for obtaining samples for culture, draining purulent contents, and guiding antibiotic therapy. We consider that ultrasound is a safe, low-cost study with great diagnosis-therapeutic applicability that should be included in orthopedist training.

Conflict of interest: The authors declare no conflicts of interest.

E. J. Bonifaz Manzano ORCID ID: <https://orcid.org/000900077247334>
J. Cedillo-Balcázar ORCID ID: <https://orcid.org/0000-0003-1468-0628>

N. E. Rodríguez Vélez ORCID ID: <https://orcid.org/0000-0001-7333-5790>
J. F. Soto-Alvarado ORCID ID: <https://orcid.org/0000-0002-4313-9710>

REFERENCES

1. Pannunzio ME, Praino ML, Carballo CM, Medranda AC, Orlando MN, Biondi EJ, et al. Piomiositis en niños: experiencia en un hospital pediátrico de referencia en Argentina. *Rev Chil Infectol* 2019;36(3):371-5. <https://doi.org/10.4067/S0716-10182019000300371>
2. Planchet J, Urbina Y, Barreto O, Correa J. Piomiositis, artritis séptica y osteomielitis aguda por *Staphylococcus aureus* meticilino resistente de la comunidad en paciente pediátrico. *Rev Digit Postgrado* 2021;10(3): e321. <https://doi.org/10.37910/RDP.2021.10.3.e321>
3. Altmayer S, Verma N, Dicks EA, Oliveira A. Imaging musculoskeletal soft tissue infections. *Semin Ultrasound, CT MRI* 2019;41(1):85-98. <https://doi.org/10.1053/j.sult.2019.09.005>
4. Kavukçu S, Koşay C, Çakmakçı H, Öztürk Y, Anal Ö. Primary pyomyositis mimicking transient synovitis of the hip in a child: A case report. *Turkish J Rheumatol* 2012;27(2):128-31. <https://doi.org/10.5606/tjr.2012.019>
5. Elzohairy MM. Primary pyomyositis in children. *Orthop Traumatol Surg Res* 2018;104(3):397-403. <https://doi.org/10.1016/j.otsr.2017.12.005>
6. Valderrama-Beltrán S, Cortés JA, Caro MA, Cely-Andrade L, Osorio-Pinzón JV, Gualtero SM, et al. Guía de práctica clínica para el diagnóstico y manejo de las infecciones de piel y tejidos blandos en Colombia. *Infectio* 2019;23(4): 318-46. <https://doi.org/10.22354/in.v23i4.805>
7. Karakatsanis A, Lykoudis P, Nastos C, Chronopoulos E, Koutoulidis V, Polymeneas G, et al. Bilateral obturator pyomyositis with visceral involvement in an immunocompetent adult patient treated without surgery. *Surg Infect (Larchmt)* 2014;15(5):651-5. <https://doi.org/10.1089/sur.2012.147>
8. Henríquez-Camacho C. La ecografía clínica en el diagnóstico diferencial de las infecciones del aparato locomotor. *Acta Reum* 2018;4(1):1-2. <https://doi.org/10.3823/1330>
9. Yahalom G, Guranda L, Meltzer E. Internal obturator muscle abscess caused by *Klebsiella pneumoniae*. *J Infect* 2007;54:157-60. <https://doi.org/10.1016/j.jinf.2006.09.011>
10. King R, Laugharne D, Kerslake R, Holdsworth B. Primary obturator pyomyositis: A diagnostic challenge. *J Bone Joint Surg Br* 2003;85(6):895-8. PMID: 12931815
11. Bertrand SL, Lincoln ED, Prohaska MG. Primary pyomyositis of the pelvis in children: a retrospective review of 8 cases. *Orthopedics* 2011;34(12):e832-e840. <https://doi.org/10.3928/01477447-20111021-07>
12. Angelis S, Trellopoulos A, Kondylis AK, Mirtsios H, Katsimantas A, Solakis EP, et al. Multifocal osteomyelitis localization after pyomyositis in children: Importance of timely response. *Cureus* 2019;11(4):e4463. <https://doi.org/10.7759/cureus.4463>
13. Levitt DL, Byer R, Milleret AF. Point-of-care ultrasound to diagnose pyomyositis in a child. *Pediatr Emerg Care* 2019;35(1):69-71. <https://doi.org/10.1097/PEC.0000000000001711>
14. Sivitz AB, Lam SHF, Ramirez-Schremp D, Valente JH, Nagdev AD. Effect of bedside ultrasound on management of pediatric soft-tissue infection. *J Emerg Med* 2010;39(5):637-43. <https://doi.org/10.1016/j.jemermed.2009.05.013>
15. Vij N, Ranade AS, Kang P, Belthur MV. Primary bacterial pyomyositis in children: A systematic review. *J Pediatr Orthop* 2021;41(9):e849-e854. <https://doi.org/10.1097/BPO.0000000000001944>