

# Nonunion After Chevron Osteotomy: Incidence, Treatment, Follow-up, and Outcomes

María Alejandra Córdoba, Carlos Mendoza Puello, Eduardo Costanza, Matías Devoto, Alejandro Iglesias, Fernando Rodríguez Castells

Foot, Ankle, and Leg Unit, CEMIC University Hospital, Autonomous City of Buenos Aires, Argentina

## ABSTRACT

**Introduction:** Hallux valgus is the most common disorder of the first toe. It causes pain, functional impairment, and alters gait patterns. Mild to moderate deformities are typically corrected with distal osteotomies of the first metatarsal, such as the chevron osteotomy, a safe procedure, but not without complications. The objectives of this study were to determine the incidence of pseudoarthrosis following this osteotomy and report our therapeutic method, follow-up, and outcomes. **Materials and Methods:** A retrospective multicenter study was carried out, which included patients operated on between 2009 and 2018. A total of 1156 chevron osteotomies were evaluated as a treatment for mild to moderate hallux valgus in 1017 patients (age range 16–83 years; average 57.5 years) performed by 4 experienced surgeons. The inclusion criterion was that the patient had imaging studies compatible with pseudoarthrosis six months after surgery. **Results:** We evaluated five patients who met our criterion. The average AOFAS (American Orthopedic Foot and Ankle Society) scores were 51 before hallux valgus treatment and 87.8 after pseudoarthrosis treatment. **Conclusion:** The incidence of pseudoarthrosis was 0.4% in the distant postoperative period. Our approach and treatment of pseudoarthrosis achieved excellent clinical and functional improvements in all operated patients.

**Keywords:** Hallux valgus; Chevron osteotomy; nonunion.

**Level of Evidence:** III

## Seudoartrosis después de una osteotomía en chevron: incidencia, tratamiento, seguimiento y evolución

## RESUMEN

**Introducción:** El hallux valgus es el trastorno más común del primer dedo del pie. Provoca dolor, discapacidad funcional y altera los patrones de la marcha. Las deformidades leves o moderadas se han corregido con osteotomías distales del primer metatarsiano, como la osteotomía en chevron, un procedimiento seguro, pero no exento de complicaciones. Los objetivos de este estudio fueron determinar la incidencia de seudoartrosis por dicha osteotomía y comunicar nuestro método terapéutico, el seguimiento y la evolución. **Materiales y Métodos:** Se realizó un estudio multicéntrico, retrospectivo que incluyó a pacientes operados entre 2009 y 2018. Se evaluaron 1156 osteotomías en chevron como tratamiento del hallux valgus leve o moderado en 1017 pacientes (rango etario 16-83 años; promedio 57.5) realizadas por 4 cirujanos experimentados. El criterio de inclusión fue que el paciente contara con estudios por imágenes compatibles con seudoartrosis a los 6 meses de la cirugía. **Resultados:** Se evaluó a 5 pacientes con diagnóstico de seudoartrosis después de una osteotomía en chevron para tratar el hallux valgus. Los puntajes promedio de la AOFAS fueron 51 antes del tratamiento del hallux valgus y 87,8 después del tratamiento de la seudoartrosis. **Conclusiones:** La incidencia de seudoartrosis fue del 0,4% en el posoperatorio alejado. Nuestro abordaje y el tratamiento de la seudoartrosis lograron una excelente mejoría clínica y funcional en todos los pacientes operados.

**Palabras clave:** Hallux valgus; osteotomía en chevron; seudoartrosis.

**Nivel de Evidencia:** III

Received on September 7<sup>th</sup>, 2022. Accepted after evaluation on January 17<sup>th</sup>, 2023 • Dr. MARÍA ALEJANDRA CÓRDOBA • mariaalejandra.cordoba85@gmail.com  <https://orcid.org/0000-0003-2887-6226>

**How to cite this article:** Córdoba MA, Mendoza Puello C, Costanza E, Devoto M, Iglesias A, Rodríguez Castells F. Nonunion After Chevron Osteotomy: Incidence, Treatment, Follow-up, and Outcomes. *Rev Asoc Argent Ortop Traumatol* 2023;88(2):177-186. <https://doi.org/10.15417/issn.1852-7434.2023.88.2.1664>



## INTRODUCTION

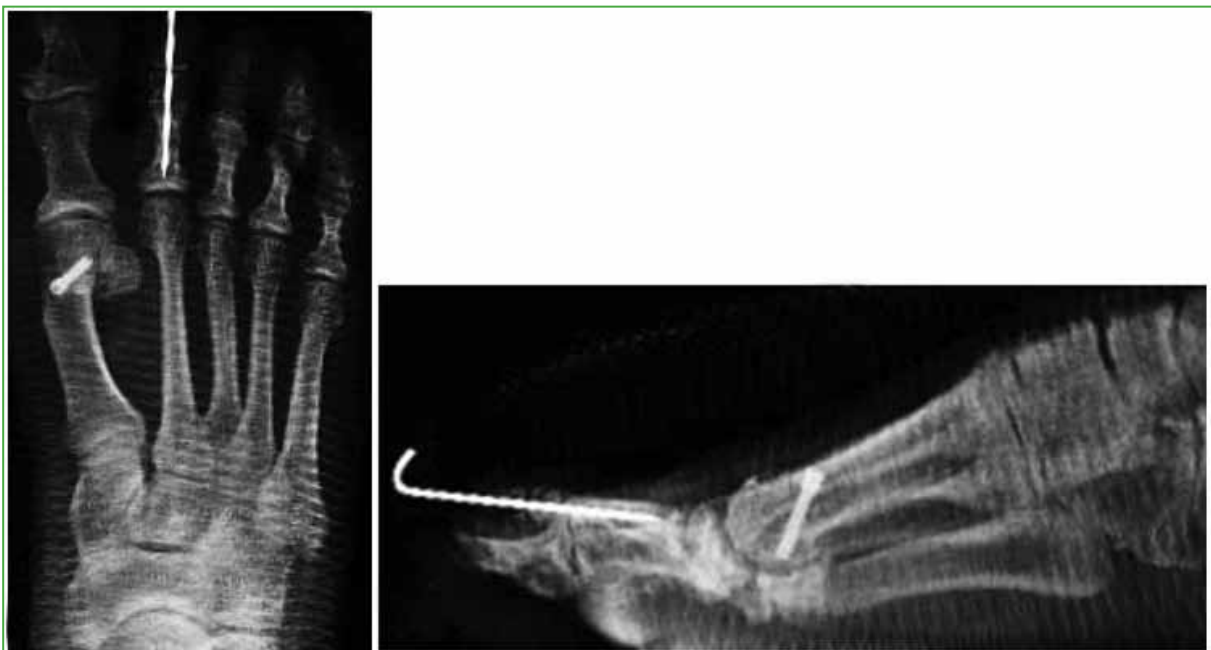Hallux valgus is the most clinically relevant foot deformity, with a prevalence of 2-4%,<sup>1</sup> and it predominates in the female sex.<sup>2</sup> It can be due to extrinsic (footwear) and intrinsic (heredity) causes.<sup>3</sup> It often causes pain, functional disability, and alterations in gait patterns.<sup>4,5</sup>

Traditionally, mild and moderate deformities have been treated with a distal osteotomy procedure.<sup>7</sup> The first reports of this type of technique in the area of the first metatarsal for the correction of hallux valgus can be attributed to Reverdin (1881), who described a subcapital closing wedge osteotomy. Other reports appear in the context of a horizontally directed "V" displacement osteotomy of the first metatarsal, described by Austin and Leventen.<sup>8</sup> Good primary stability was obtained with this procedure due to the type of osteotomy and it was Johnson who coined the term *chevron osteotomy* in 1979.<sup>9</sup> This technique provides stability, allows rapid recovery, and achieves minimal shortening of the first metatarsal.<sup>10</sup> A low rate of complications has been reported, such as avascular necrosis of the metatarsal head, one of the most feared complications, with a frequency of 0.8%; restricted range of motion (12.1%), recurrence of hallux valgus (6.9%), hallux varus (4.8%), transfer metatarsalgia (3.2%), nonunion (3.1%), wound healing disorders (1.8%) and infections (1.5%).<sup>11</sup>

As nonunion is a rare complication and there are few published cases, our objective was to determine the incidence of nonunion after chevron osteotomy and to report our therapeutic method, follow-up, and outcome.

## MATERIALS AND METHODS

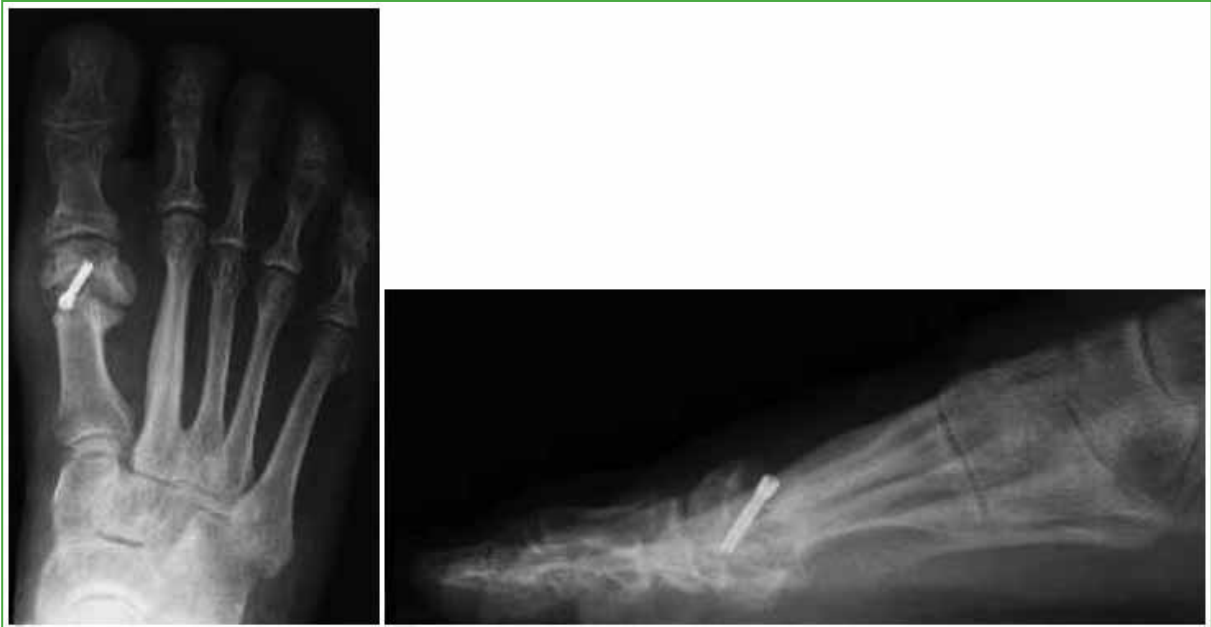A retrospective, multicenter study was conducted that included patients who underwent chevron and Akin osteotomy (Figure 1) for the treatment of mild or moderate hallux valgus, between 2009 and 2018. A total of 1156 chevron osteotomies were evaluated in 1017 patients (355 bilateral). 95% were women and 5% men, the age ranged from 16 to 83 years (average 57.5). The procedure was carried out by four experienced surgeons. Johnson's modified V-shaped osteotomy was performed. The osteotomy was stabilized with a 3.0 mm screw directed from proximal to distal and from medial to lateral. Radiographs of all patients were taken in the immediate postoperative period, at one month, and at three and six months. Patients with radiographic signs of osteotomy consolidation were discharged six months after surgery.



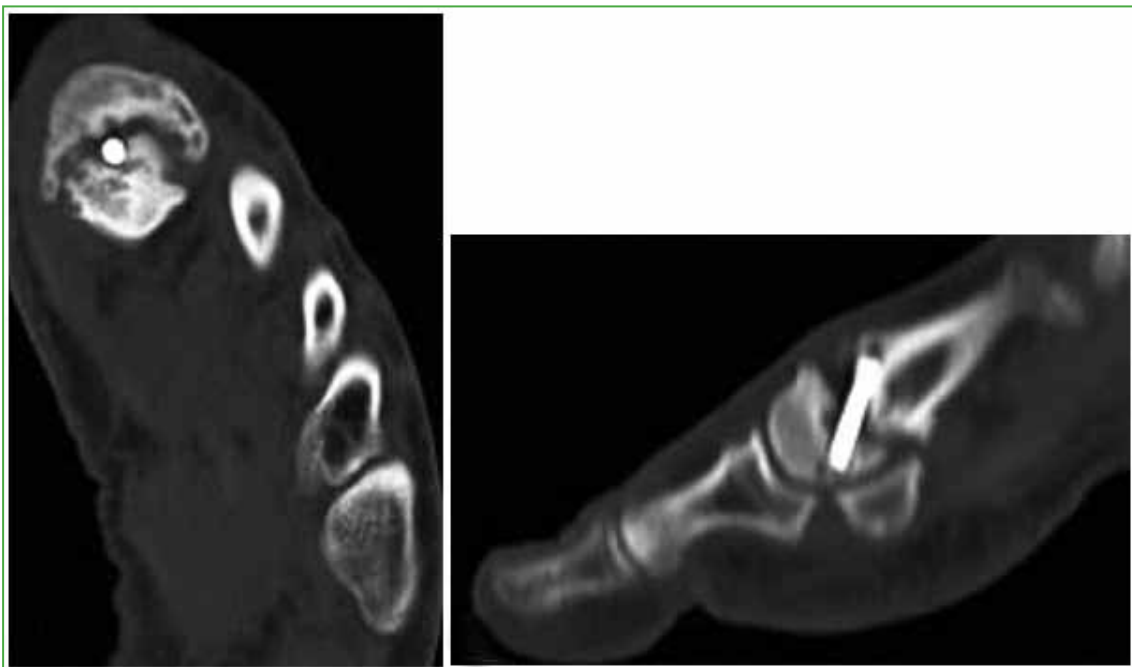
**Figure 1.** Anteroposterior and lateral foot radiographs in the immediate postoperative period. Chevron osteotomy, Akin osteotomy, and distal interphalangeal arthrodesis of the second toe.

The inclusion criteria were patients with clinical and radiographic alterations compatible with signs of pseudarthrosis.

Thus, the series was made up of five patients (4 female and 1 male) who had imaging studies compatible with pseudarthrosis six months after the operation (Figures 2 and 3). The AOFAS (*American Orthopaedic Foot and Ankle Society*) score was used before and after both procedures (initial hallux valgus surgery and nonunion surgery).

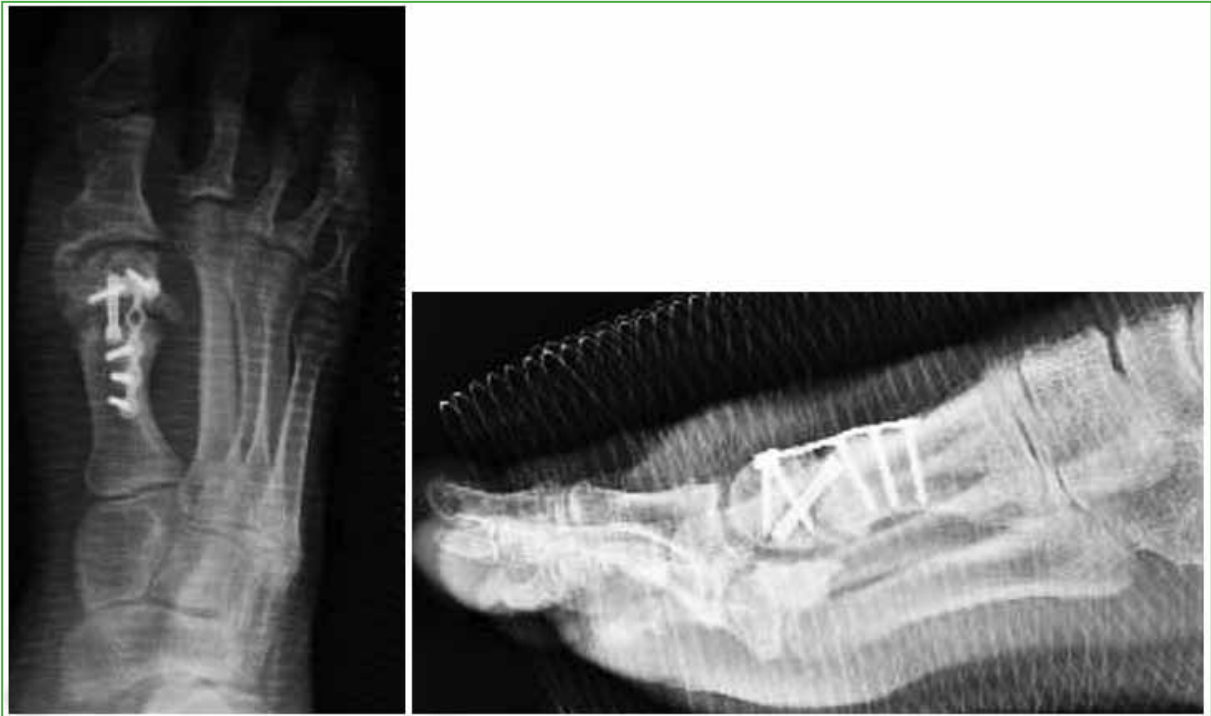

**Figure 2.** Anteroposterior and lateral radiographs of the foot, three months after the operation. A nonunion focus is observed at the level of the chevron osteotomy.

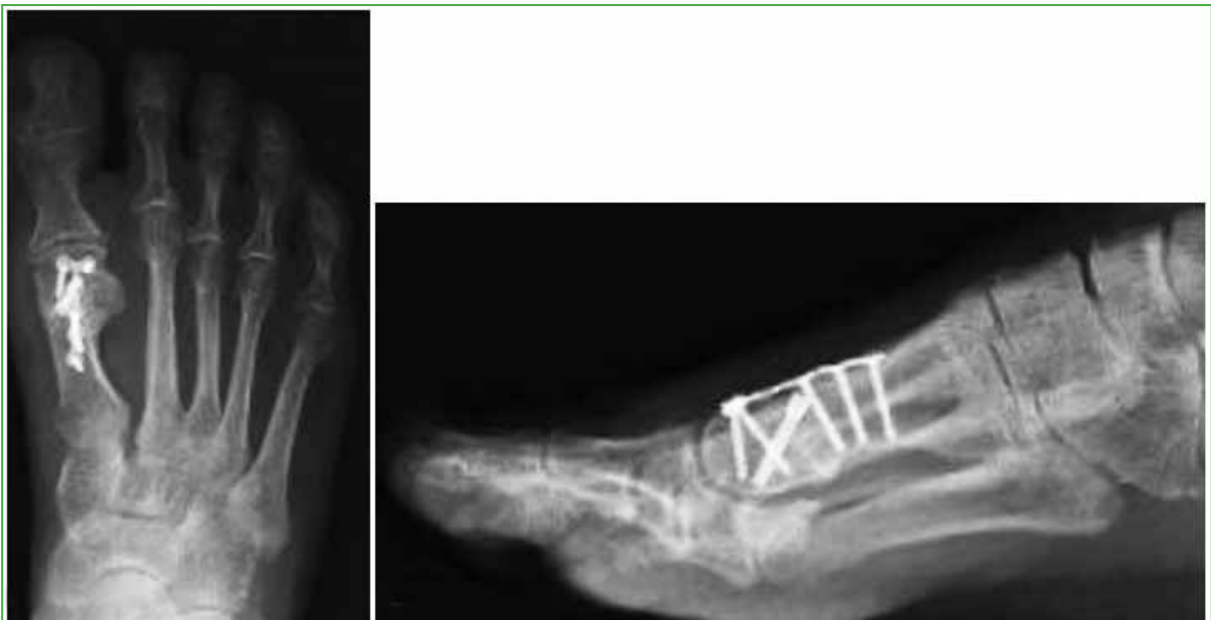

**Figure 3.** Computed tomography of the foot, axial and sagittal slices. The nonunion focus is observed at the level of the chevron osteotomy.

All patients were treated with surgery (Figures 4 and 5). Follow-up for this treatment was >24 months.



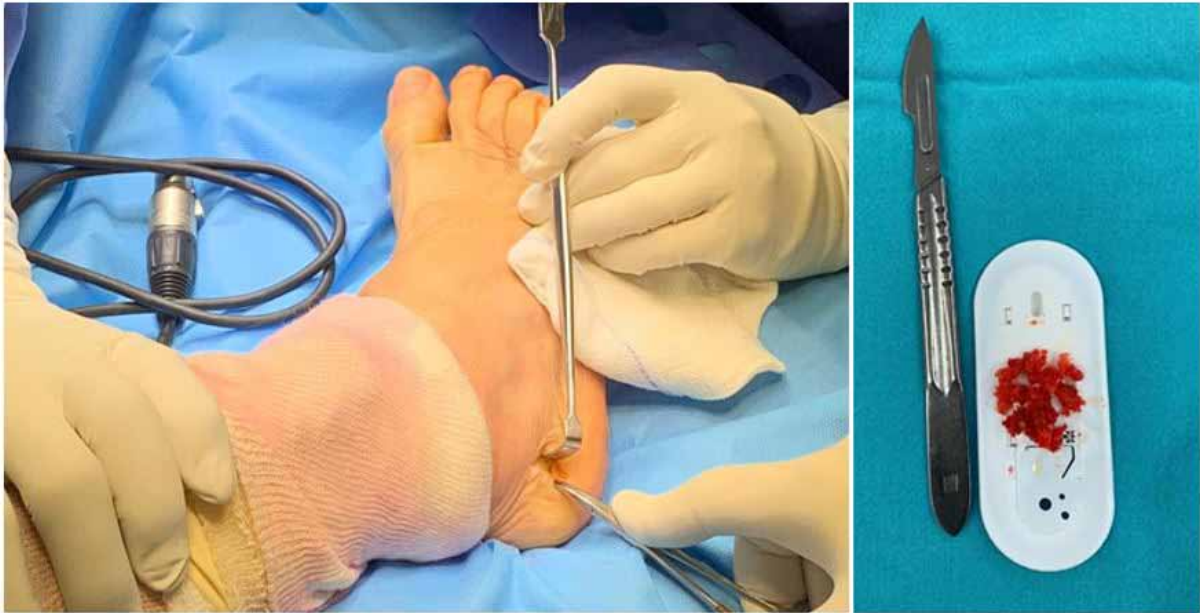**Figure 4.** Anteroposterior and lateral foot radiographs in the immediate postoperative period. Plate and screw osteosynthesis is shown for the treatment of nonunion.



**Figure 5.** Radiographic control 2 months after surgery. Consolidation of the nonunion focus is visualized.

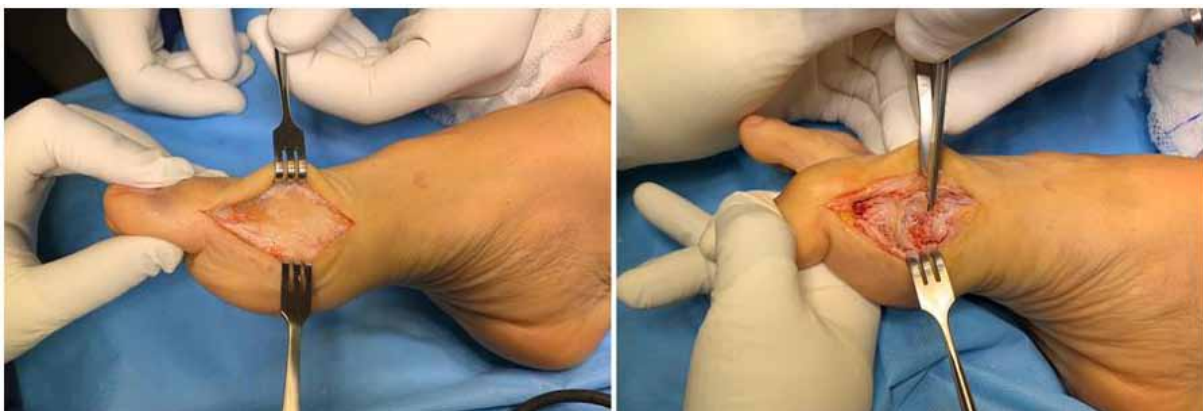### Surgical technique and postoperative period.

The patient is placed in dorsal decubitus position on the general surgery table. Antibiotic prophylaxis is administered at anesthetic induction, after decontamination with 2% chlorhexidine gluconate mixed with 70% isopropyl alcohol. Double fields are placed according to technique and an Esmarch bandage is applied to the ankle. A lateral incision is made over the calcaneus to harvest the autologous bone graft (Figure 6).



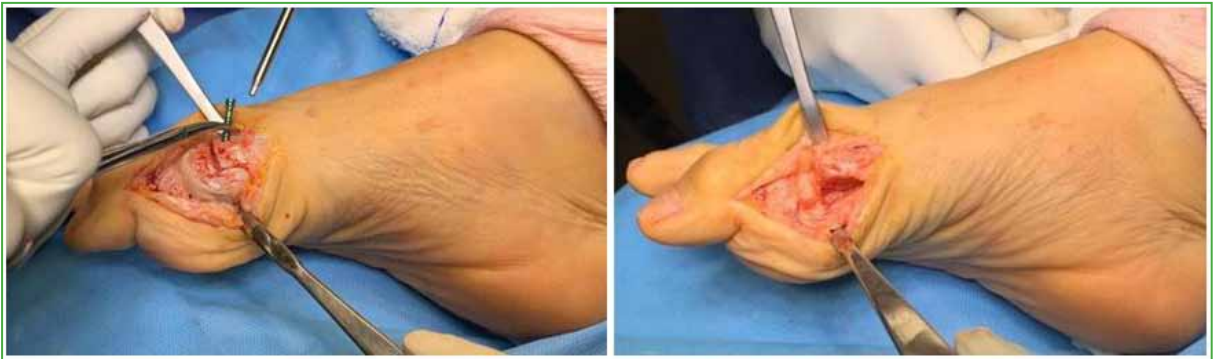**Figure 6.** Lateral incision on the calcaneus to harvest the autologous bone graft.

A medial longitudinal approach to the hallux is made over the anterior incision, the capsulotomy is carried out, and the focus of nonunion is identified (Figure 7).



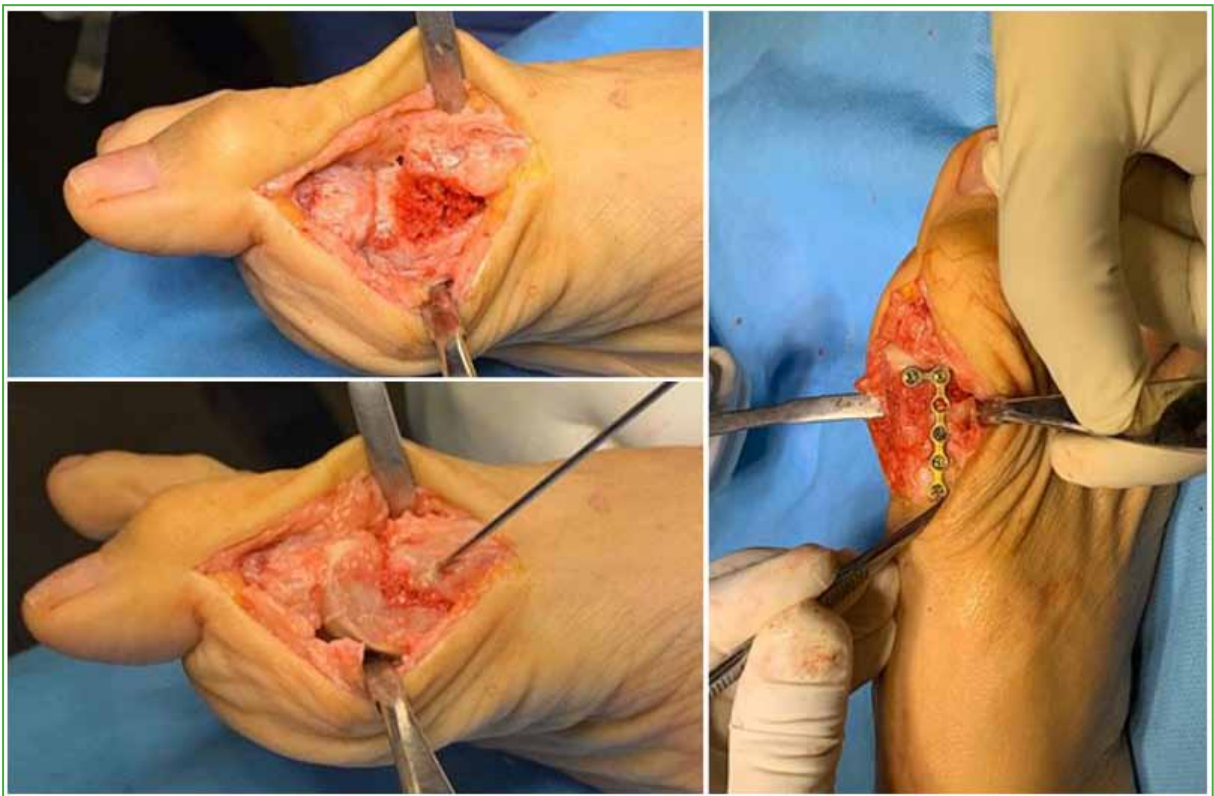
**Figure 7.** Medial longitudinal approach to the hallux over the previous incision, capsulotomy, and identification of the nonunion focus.

The osteosynthesis material is removed and bone curettage is performed (Figure 8).



**Figure 8.** Removal of osteosynthesis material and subsequent bone curettage.

An autologous calcaneal graft is placed over the nonunion focus and secured with a pin before being reduced and stabilized with an anatomical plate and screws (Figure 9). We then perform capsulorrhaphy, Esmarch bandage removal, careful hemostasis, skin closure, and flat dressing. An elastic bandage is applied, and the limb is placed in a walker boot.



**Figure 9.** Placement of an autologous calcaneal graft over the nonunion focus, temporary fixation with a pin, reduction and stabilization with an anatomical plate and screws.

Post-surgical control is performed for healing during the first week. In the third week, the sutures are removed, and in the fourth week, control radiographs are taken and the Walker boot is removed. From then on, the patients wear a rigid-soled sandal for four more weeks, and a clinical and radiographic control is carried out in the third and sixth months to verify the consolidation of the nonunion focus.

## RESULTS

The AOFAS scale (Table) was used before treatment for hallux valgus and after treatment for nonunion. This scale values the operated hallux, in percentage, with respect to the function of a normal hallux (100%). By applying this score, an absolute numerical value is obtained, which is nothing more than the recovery percentage of the operated foot with respect to a normal foot.

The AOFAS scale assesses pain (40 points) and function (60 points). This last item is subdivided into: activity limitation, insole requirements, metatarsophalangeal and interphalangeal range of motion, metatarsophalangeal stability, calluses, and final alignment.

Of the five patients evaluated for the nonunion complication (Table), four were women and one was a man (age range 55-75 years).

An average of 51 points was obtained before treatment for hallux valgus and 87.8 after treatment for pseudarthrosis.

Regarding pain, one patient reported that it had completely subsided, three continued with mild pain and one with moderate pain.

Regarding the function of the operated hallux, four patients had no limitation of activity and one patient, limitation of recreational sports activity. One patient could wear fashionable footwear and four, comfort footwear.

Metatarsophalangeal range of motion was preserved in three of the patients, one presented a mild restriction and the other evolved with severe metatarsophalangeal osteoarthritis that required arthrodesis. The same results were obtained when analyzing the interphalangeal joint. The joint was stable in 100% of the cases.

It should be noted that none of the patients operated on for hallux valgus presented pseudarthrosis of the Akin osteotomy.

**Table.** Series of patients with pseudarthrosis

	Age	Sex	Initial treatment	AOFAS score (Preoperative)	AOFAS score (Postoperative)	Comorbidities	Smoking
1	73	Female	Chevron + Akin	63	90	Hypothyroidism, arterial hypertension	No
2	61	Female	Chevron + Akin	58	88	Arterial hypertension	No
3	55	Female	Chevron + Akin	57	89	Diabetes	No
4	75	Female	Chevron + Akin	10	87	Asthma, gout, high blood pressure	No
5	73	Male	Chevron + Akin	70	85	High blood pressure, diabetes	No

AOFAS = American Orthopaedic Foot and Ankle Society.

## DISCUSSION

Joint stiffness, recurrence of hallux valgus, hallux varus, transfer metatarsalgia, avascular necrosis of the metatarsal head, impaired wound healing, and infection are some of the documented complications after chevron osteotomy for the treatment of hallux valgus.<sup>8</sup> Pseudarthrosis is a rare complication with few reports in the literature. It is defined as the absence of definitive bone consolidation of a fracture or arthrodesis, whose pathological

process corresponds to the formation of a scar through non-ossified fibrous tissue, the pathological alteration appears when there is no osteoblastic integration that confers fibrous scar tissue the characteristics of bone tissue. This occurs due to a lack of perfect and uninterrupted immobilization, excessive separation of bone fragments, interposition of soft tissue, insufficient vascularization or pathological bone fracture.<sup>11</sup>

There are other factors that have been classified as mechanical and biological. The latter include the clinical and pharmacological antecedents that present with alterations of bone metabolism and, consequently, of the normal consolidation process.<sup>11</sup> Therefore, their identification and consideration are relevant, both due to the added cost and the additional number of surgical interventions required by patients with pseudarthrosis, without leaving aside the associated complications that interfere with both personal and work daily activities.<sup>12,13</sup>

Smoking has been associated with delayed fracture union in numerous studies. One of the mechanisms causing this effect is the decrease in bone mineralization.<sup>14</sup> Smokers, who commonly require more time to heal a fracture or osteotomy, suffer a greater number of complications during recovery (2.5 to 3 times those of nonsmokers) and need more healing time, according to studies made in different joints and bones.<sup>14</sup> However, there are studies that do not show this association; W-Dahl and Toksvig-Larsen published that they did not observe a direct relationship between smoking and the genesis of nonunion.<sup>15</sup>

The precise location of the distal osteotomy of the first metatarsal, as well as the effects of the temperature increase during bone cutting with the microsaw, could be linked to the appearance of this complication.<sup>16-20</sup>

The location of the osteotomy is an important determining factor in the incidence of nonunion. Distal osteotomies receive minimal weight-bearing forces that favor a low incidence of nonunion secondary to biomechanical displacement. However, one of the disadvantages of these osteotomies is that the proximity to the metatarsophalangeal joint limits its ability to rotate. On the other hand, proximal osteotomies receive greater weight-bearing force, and this leads to a significantly higher incidence of pseudarthrosis.<sup>21,22</sup>

It is known that exposure of bone to excessive temperature increases during drilling or cutting can cause thermal necrosis of bone. Temperatures above 50° C for 60 seconds cause irreversible changes in the structure and physical properties of bone, such as osteocyte degeneration, increased osteoclastic activity, the appearance of fibrosis and bone necrosis.<sup>18</sup> The use of cutting blades in poor condition or at inappropriate revolutions generates an increase in temperature for a prolonged time that causes local alterations and can lead to delayed consolidation and pseudarthrosis.<sup>18-20</sup>

Metatarsal nonunions after hallux valgus surgery are often symptomatic and can cause pain and insufficiency in the first ray leading to transfer metatarsalgia. Treatment of this can restore a mechanically healthy first ray. In most cases, removal of the osteosynthesis material, debridement of the nonunion site, bone grafting, realignment, and stable fixation help promote healing.<sup>20,21</sup>

One of the strengths of this study is its multicenter design and that it is the first national series of cases on the subject, with a large patient sample. However, this is a retrospective study, surgeries were performed by four different foot surgeons, and a single functional score was used to assess patients.

## CONCLUSIONS

Given the low specific prevalence of this condition, there are very few national literature reports on its incidence, diagnosis, and surgical management. In this paper, we discuss how important it is to consider pseudarthrosis as a real complication following a chevron osteotomy for the treatment of hallux valgus and the importance of diagnosis for its appropriate surgical treatment.

Given this, it is easy to see that, in order to have a casuistry that allows us to know the true cause of this complication, all patients must be registered and retrospectively analyzed, allowing us to increase the number of cases evaluated.

From the epidemiological point of view, there are estimators that predispose to pseudarthrosis, such as smoking, the anatomical site of the osteotomy, increased temperature, and the condition of the saw. However, it is only an approximation, so the prediction may fail and it is more difficult to study given the low incidence.

Our experience shows us that chevron osteotomy for the treatment of hallux valgus is a safe technique with a low rate of complications and an incidence of pseudarthrosis of 0.4% in a sample of 1017 patients, compared



to the 3.1 % published. We believe that our therapeutic method, which consists of removing the osteosynthesis material, curettage of the nonunion focus, decortication, and the use of autologous calcaneal graft with adequate fixation with a plate and screw, is a safe and effective procedure that requires a relatively short surgical time.

The patients who underwent this procedure had a good evolution beyond 24 months after surgery, and favorable radiographic images, with consolidation of the nonunion focus.

Conflict of interest: The authors declare no conflicts of interest.

C. Mendoza Puello ORCID ID: <https://orcid.org/0000-0003-4655-4896>  
 E. Costanza ORCID ID: <https://orcid.org/0000-0002-7632-6088>  
 M. Devoto ORCID ID: <https://orcid.org/0000-0002-4216-8296>

A. Iglesias ORCID ID: <https://orcid.org/0000-0002-6487-436X>  
 F. Rodríguez Castells ORCID ID: <https://orcid.org/0000-0002-8207-5852>

## REFERENCES

1. Wanivenhaus A, Bock B, Gruber F, Ivanic G, Klein C, et al. Associated treatment of the hallux valgus complex. *Orthopäde* 2009;38(11):1117-26. <https://doi.org/10.1007/s00132-009-1526-3>
2. Coughlin MJ, Smith BW. Hallux valgus and first ray mobility. Surgical technique. *J Bone Joint Surg Am* 2008; 90(Suppl 2, Pt 2):153-70. <https://doi.org/10.2106/JBJS.H.00095>
3. Coughlin MJ, Roger A. Mann Award. Juvenile hallux valgus: Etiology and treatment. *Foot Ankle Int* 1995;16(11):682-97. <https://doi.org/10.1177/107110079501601104>
4. Bai LB, Lee KB, Seo CY, Song EK, Yoon TR. Distal chevron osteotomy with distal soft tissue procedure for moderate to severe hallux valgus deformity. *Foot Ankle Int* 2010;31(8):683-8. <https://doi.org/10.3113/FAI.2010.0683>
5. Chuckpaiwong B. Comparing proximal and distal metatarsal osteotomy for moderate to severe hallux valgus. *Int Orthop* 2012;36(11):2275-8. <https://doi.org/10.1007/s00264-012-1656-9>
6. Yee G, Lau J. Current concepts review: hallux rigidus. *Foot Ankle Int* 2008;29(6):637-46. <https://doi.org/10.3113/FAI.2008.0637>
7. Deenik A, van Mameren H, de Visser E, de Waal Malefijt M, Draijer F, et al. Equivalent correction in scarf and chevron osteotomy in moderate and severe hallux valgus: a randomized controlled trial. *Foot Ankle Int* 2008;29(12):1209-15. <https://doi.org/10.3113/FAI.2008.1209>
8. Austin D, Leventen E. A new osteotomy for hallux valgus. *Clin Orthop Relat Res* 1981;(157):25-30. PMID: 7249456
9. Wirth CJ, Mutschler W-E, Bischoff H-P. *Komplikationen in Orthopädie und Unfallchirurgie*. Stuttgart: Thieme; 2010.
10. Schneider W, Aigner N, Pinggera O, Knahr K. Chevron osteotomy in hallux valgus. Ten-year results of 112 cases. *J Bone Joint Surg Br* 2004;86(7):1016-20. <https://doi.org/10.1302/0301-620x.86b7.15108>
11. Cueva-del Castillo JF, Valdés-Gutiérrez GA, Elizondo-Vázquez F, Pérez-Ortiz O, Piña BMC. Tratamiento de pérdidas óseas, pseudoartrosis, artrodesis y tumores óseos benignos con un xenoimplante mexicano (estudio clínico). *Cir Ciruj* 2009;77(4):287-91. Available at: <https://www.medigraphic.com/pdfs/circir/cc-2009/cc094f.pdf>
12. Rodríguez-Merchan EC, Forriol F. Nonunion: general principles and experimental data. *Clin Orthop Relat Res* 2004;(419):4-12. PMID: 15021125
13. Gelalis ID, Politis AN, Arnaoutoglou CM, Korompilias AV, Pakos EE, Vekris MD, et al. Diagnostic and treatment modalities in nonunions of the femoral shaft: A review. *Injury* 2012;43(7):980-8. <https://doi.org/10.1016/j.injury.2011.06.030>
14. Benazzo F, Mosconi M, Bove F, Quattrini F. Treatment of femoral diaphyseal non-unions: Our experience. *Injury* 2010; 41(11):1156-60. <https://doi.org/10.1016/j.injury.2010.08.010>

15. W-Dahl A, Toksvig-Larsen S. Cigarette smoking delays bone healing: A prospective study of 200 patients operated on by the hemicallotaxis technique. *Acta Orthop Scand* 2004;75(3):347-51. <https://doi.org/10.1080/00016470410001303>
16. Kempf I, Grosse A, Rigaut P. The treatment of noninfected pseudarthrosis of the femur and tibia with locked intramedullary nailing. *Clin Orthop Relat Res* 1986;(212):142-54. PMID: 3769280
17. Salinas Gilabert JE, Lajara Marco F, Ruiz Herrera M. La osteotomía distal percutánea en el tratamiento de la metatarsalgia de los radios menores. *Rev Esp Cir Ortop Traumatol* 2009;53(3):192-7. <https://doi.org/10.1016/j.recot.2008.04.001>
18. Mifsut D, Franco E, Turowicz M, Subías A, Cutillas B. Osteotomía de Weil percutánea en el tratamiento de las metatarsalgias: correlación clínico-radiológica. *Rev Esp Cir Osteoart* 2009;44(237):30-5. Available at: <http://hdl.handle.net/10550/40727>
19. Piqué-Vidal C. The effect of temperature elevation during discontinuous use of rotatory burrs in the correction of hallux valgus. *J Foot Ankle Surg* 2005;44(5):336-44. <https://doi.org/10.1053/j.jfas.2005.07.009>
20. Krause WR, Bradbury DW, Kelly JE, Lunceford EM. Temperature elevations in orthopaedic cutting operations. *J Biomech* 1982;15(4):267-75. [https://doi.org/10.1016/0021-9290\(82\)90173-7](https://doi.org/10.1016/0021-9290(82)90173-7)
21. Richardson EG. Complications after hallux valgus surgery. *Instr Course Lect* 1999;48:331-42. PMID: 10098059
22. Vora AM, Myerson MS. First metatarsal osteotomy nonunion and malunion. *Foot Ankle Clin* 2005;10(1):117-27. <https://doi.org/10.1016/j.fcl.2004.10.001>