

Oral Versus Intra-articular Corticosteroid in the Treatment of Adhesive Capsulitis

Byron Torres, Carlos Chaves Lara

Orthopedics and Traumatology Service, Centro de Especialidades Ortopédicas, Hospital Metropolitano de Quito, Ecuador

ABSTRACT

Introduction: Adhesive capsulitis is a condition defined by thickening of the shoulder joint capsule, which clinically translates into discomfort and progressive loss of range of motion, with conservative therapy being the initial option. In this study, we evaluate the use of intra-articular corticosteroid injections for the treatment of this condition. **Materials and Methods:** A retrospective analysis was conducted between 2015 and 2020, assessing the outpatient records of patients diagnosed with adhesive capsulitis or frozen shoulder and treated with corticosteroids either orally or intra-articularly. **Results:** A total of 19 patients were analyzed, 8 received oral treatment and 11 received intra-articular injection, with both groups showing considerable improvement, with the difference that the patients in the articular corticosteroid group reported long-term improvement. **Conclusion:** Corticosteroids have been found to be effective in the treatment of adhesive capsulitis both orally and by intra-articular injection; however, intra-articular corticosteroids have proved to be more effective in the long term.

Keywords: Adhesive capsulitis of the shoulder; oral corticosteroid; corticosteroid injection; pain; range of motion.

Level of Evidence: III

Corticoesteroides oral vs. intrarticular en el tratamiento de la capsulitis adhesiva

RESUMEN

Introducción: La capsulitis adhesiva es una enfermedad que se caracteriza por el engrosamiento de la cápsula articular del hombro, lo que se traduce clínicamente en dolor y una pérdida progresiva de la movilidad. El tratamiento conservador es la primera opción. En este estudio, se evaluó el uso de corticoesteroides articulares para el manejo de este cuadro. **Materiales y Métodos:** Se llevó a cabo un estudio retrospectivo entre 2015 y 2020. Se evaluaron los registros de consulta externa de pacientes con diagnóstico de capsulitis adhesiva u hombro congelado, que recibieron tratamiento con corticoesteroides por vía oral o articular. **Resultados:** Se analizó a 19 pacientes, 8 recibieron tratamiento por vía oral y 11, por vía articular. Hubo una mejoría importante en ambos grupos, pero los pacientes que recibieron corticoesteroides articulares comunicaron una mejoría a largo plazo. **Conclusiones:** La administración de corticoesteroides tanto por vía oral como intrarticular para tratar la capsulitis adhesiva fue eficaz; sin embargo, a largo plazo, los corticoesteroides articulares resultaron más eficaces.

Palabras clave: Capsulitis adhesiva del hombro; corticoesteroides oral; inyección de corticoesteroides; dolor; rango de movilidad.

Nivel de Evidencia: III

INTRODUCTION

The term adhesive capsulitis or frozen shoulder refers to a condition characterized by thickening of the joint capsule resulting in progressive loss of both active and passive range of motion.^{1,2} The degree of thickening is directly related to the loss of range of motion; however, it is not related to the perception of pain.³

This disease does not have a specific cause; in general, it has an idiopathic origin, and it is a self-limiting condition. It begins with a “freezing” phase in which joint pain and stiffness increase, which may last for several months, followed by a stable stage in which it remains “frozen”, after which it progresses to a “thawing” phase, and it tends to resolve spontaneously.^{4,5}

Received on August 8th, 2022. Accepted after evaluation on February 17th, 2023 • Dr. BYRON TORRES • byrontorres78@gmail.com  <https://orcid.org/0000-0002-7365-5927>

How to cite this article: Torres B, Chaves Lara C. Oral Versus Intra-articular Corticosteroid in the Treatment of Adhesive Capsulitis. *Rev Asoc Argent Ortop Traumatol* 2023;88(4):386-391. <https://doi.org/10.15417/issn.1852-7434.2023.88.4.1647>

Some diseases may predispose to the development of adhesive capsulitis, such as a contralateral shoulder condition, immobilization, hypothyroidism and hyperthyroidism, diabetes, obesity, Parkinson's disease, cerebrovascular events, Parsonage-Turner syndrome or Dupuytren's disease, and should be taken into account when diagnosing this condition.⁶

Adhesive capsulitis has been classified on the basis of arthroscopic and histological evaluation, as described by Neviaser and Hannafin, and comprises four stages:⁷

- Stage 1: pre-adhesive phase, with fibroblast proliferation without adhesion formation, without alteration of ranges of motion, but with the appearance of pain.
- Stage 2: acute adhesive synovitis, characterized by synovial hypertrophy and early adhesion formation, pain and mild loss of range of motion.
- Stage 3: maturation phase, the transition from synovitis to fibrosis occurs, the axillary recess adheres to the joint capsule.
- Stage 4: chronic phase, significant loss of range of motion and dense adhesions, but with mild or no pain.

In order to facilitate patient understanding, the natural course of the disease has been divided into three phases that correlate with the findings described in the Neviaser and Hannafin classification.⁷ Phase 1 correlates with stage 1 and is characterized by the onset of pain, with no ROM restriction; in phase 2, a combination of acute pain and loss of ROM correlating with Neviaser and Hannafin stages 2 and 3 is detected; and phase 3 correlates with stage 4, there is a frank loss of ROM, albeit with mild pain or no pain at rest.⁸

The usual clinical presentation of this condition includes pain of insidious onset, lasting several months. Once symptoms are established, they tend to occur in increasingly frequent episodes.⁹ The pain is typically nocturnal and the patient describes being unable to sleep on the affected side; loss of range of motion appears with the natural evolution of the condition and rarely precedes the typical clinical presentation.^{10,11}

Imaging studies are inconclusive in diagnosing adhesive capsulitis. Conventional radiographs tend to be normal, MRI may reveal thickening of the coracohumeral ligament, poor capsular distension, contrast media extravasation, synovial hypertrophy, and scar formation in the rotator interval.^{12,13}

Although the condition is known to be self-limiting and tends to heal spontaneously, this is not always the case, so numerous types of treatments have been proposed, ranging from pharmacological and non-pharmacological options to the surgical alternative.¹⁴ Treatment can be symptomatic with the administration of analgesics and anti-inflammatory drugs or corticosteroids to modify the natural evolution of the disease.^{7,15} Physical therapy has been indicated as the first line of treatment, alone or concomitantly, and has been effective in alleviating this condition.¹⁶

The administration of intra-articular corticosteroids produces significant relief of pain and restoration of ROM on the affected side after 12 weeks when compared to placebo.^{17,18}

Surgery is considered if pain or limited range of motion persists after a minimum of 3-6 months of conservative management including medication, local injections or physical therapy.¹⁹

MATERIALS AND METHODS

A retrospective study was conducted to identify all patients with a diagnosis of adhesive capsulitis or frozen shoulder seen in the outpatient area of the Orthopedic Specialty Center, between 2015 and 2020. An electronic interview was conducted. Patients gave their consent to participate in the study.

Demographic data, such as age and sex, were collected and patients who received an oral corticosteroid were compared with those treated with an intra-articular corticosteroid for the management of adhesive capsulitis. A pre-treatment and post-treatment evaluation was performed using the Simple Shoulder Test (SST). Follow-up was up to 12 months.

The oral corticosteroid protocol included methylprednisolone 4 mg, one dose daily, for 15 days, followed by 2 mg daily, for 15 days and finally a dose of 2 mg, every 48 h, until completing two months of treatment.

The intra-articular corticosteroid protocol consisted of methylprednisolone 80 mg plus 8 ml lidocaine without epinephrine, one dose every week, for three weeks, via a posterior, ultrasound-guided route.

All patients treated at our center underwent physical therapy at approximately the third or fourth week after diagnosis, once relief of pain had been achieved, for a period of 2-4 months. This consisted of progressive work on passive range of motion, assisted active range of motion, and active range of motion against resistance.

Inclusion criteria were: clinical records mentioning the diagnosis of adhesive capsulitis, no age range, conservative treatment with oral or intra-articular corticosteroid.

Patients with previous surgery, those who refused to participate in this study, or who were not interested in taking part in scientific research were excluded.

A sample of 92 patients was obtained and, after applying the exclusion criteria, a final sample of 19 patients was obtained.

The SST is a subjective scale consisting of 12 questions with Yes/No answers, including daily activities. It is easy to apply and it must be completed by the patient, which allows eliminating biases. The answer 'Yes' adds up to one point, and the final result is multiplied by 100 and divided by the number of questions, thus obtaining a result in percentage.²⁰

RESULTS

Nineteen patients met the inclusion criteria, eight of them had been treated with oral corticosteroids and 11 with intra-articular corticosteroids.

Physical therapy alone is not referred to, as our treatment is followed by a physical therapy protocol, and is mentioned more as an adjunctive treatment in the management of adhesive capsulitis.²¹

The eight orally treated patients had a baseline SST score of 4.16%. Two of them improved within three months, with an average of approximately 95.8% six months after starting treatment; in one, symptoms improved completely (100% in SST); the remaining five patients required more time to obtain a positive result, the average value in SST was 66.66% after one year of treatment (Figure 1).

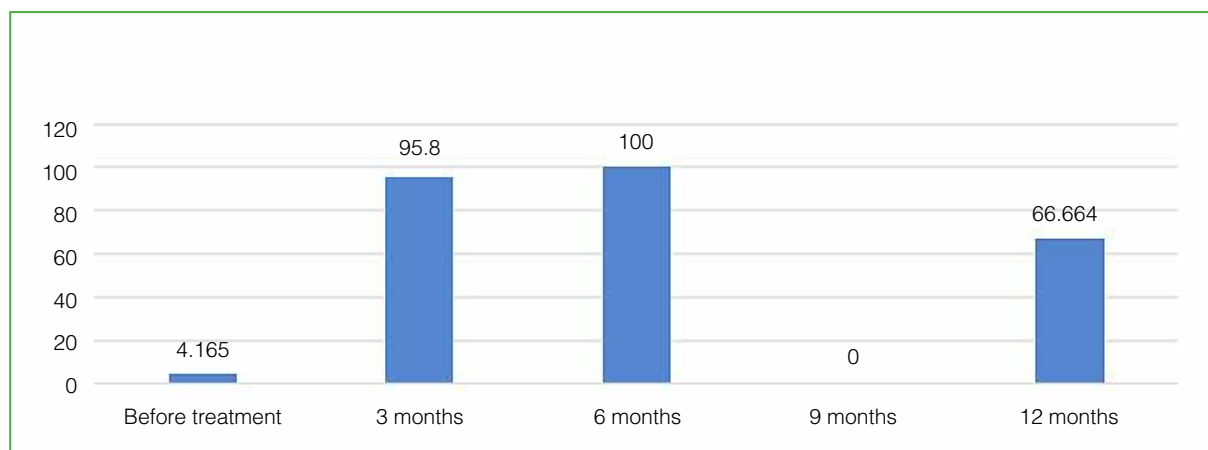


Figure 1. Simple Shoulder Test in the group treated with oral corticosteroid.

In the group treated by the intra-articular route (11 patients), the average SST was 11.36% at the first consultation. Eight of them had substantial improvement over a three-month period, with an average SST value of approximately 93.74%. The remaining three obtained 97.22% in the SST after one year of treatment (Figure 2).

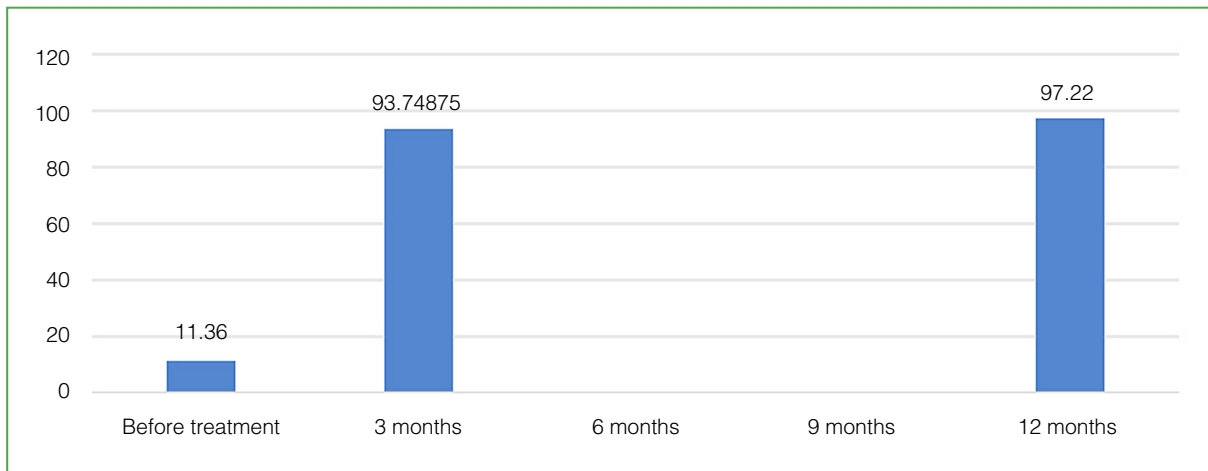


Figure 2. Simple Shoulder Test in the group treated with intraarticular corticosteroid.

As mentioned above, patients undergoing surgery were excluded; however, it would be important to assess the specific indications for surgery because, as has been indicated in international series, this type of treatment is reserved for young, high-demand individuals or those who need to return to work quickly, as well as for those suffering from metabolic diseases that have been shown to respond poorly to conservative treatment.^{11,12}

No psychological assessment had been performed prior to the start of this study, despite the fact that it has been demonstrated that this disease has a significant emotional component, and that inadequate management can lead to a slow progression or noncompliance with therapy.

DISCUSSION

Our literature review showed that multiple therapeutic options are available for adhesive capsulitis and one of the best known and effective is the use of oral or intra-articular corticosteroids, as described by Redler et al. in 2019.³ These authors report a significant improvement in perceived pain in patients with adhesive capsulitis treated with intra-articular corticosteroids; the drug begins to work after six weeks. Pain intensity improves significantly, as well as rotations, especially external rotation. They also point out that the success rate increases if ultrasound is used to perform the infiltration.

In 2017, Wang et al.⁵ demonstrated the efficacy of intra-articular corticosteroids for pain management in the short term, with no difference in the long term, and noted that they achieve substantial improvement in passive and active ranges of motion in the short and long term.

A systematic review by Koh¹⁷ compared the efficacy of corticosteroid injection with various types of treatment, such as placebo, physiotherapy alone, and non-steroidal anti-inflammatory drugs, and concluded that intra-articular corticosteroids have proven efficacy, relieving pain at 12 weeks and improving ranges of motion, although we know that, because of their self-limiting nature, they make no difference to the long-term course of the disease. However, the application of corticosteroids at an early stage of the disease helps to greatly improve its natural evolution.

In 2019, Shang et al.¹⁴ conducted a systematic review comparing the efficacy of intra-articular or subacromial corticosteroid injection to treat adhesive capsulitis. They found no significant differences in terms of site of application. Pain was relieved in an average of three weeks and ranges of motion increased at approximately 12 weeks, although the authors reported that there was no long-term evaluation and follow-up. In addition, they mentioned the probable advantages of subacromial application that avoids the adverse side effects of joint application of corticosteroids.

We are aware that a retrospective study may have limitations, such as lack of data or recall bias; however, we take this study as a starting point for future research, to strengthen research in our field and to be able to provide findings with greater scientific weight to our daily practice.

CONCLUSIONS

According to the results of our study, it is suggested that the best option for the management of adhesive capsulitis is the application of intra-articular corticosteroids, which achieves a higher recovery rate in less time; in addition, the functional scale yielded a better score in the group treated with intra-articular corticosteroids.

Although the results indicate that corticosteroid therapy is effective in the management of adhesive capsulitis, this is a retrospective study with a small sample size; however, it correlates well with larger studies.

Finally, this study incorporates an adequate clinical perspective comparing the two treatment methods used, and shows that the most effective option is intra-articular corticosteroids.

Conflict of interest: The authors declare no conflicts of interest.

C. Chaves Lara ORCID ID: <https://orcid.org/0000-0003-2984-2263>

REFERENCES

1. Alsubheen SA, Nazari G, Bobos P, MacDermid JC, Overend TJ, Faber K. Effectiveness of nonsurgical interventions for managing adhesive capsulitis in patients with diabetes: A systematic review. *Arch Phys Med Rehabil* 2019;100(2):350-65. <https://doi.org/10.1016/j.apmr.2018.08.181>
2. Candela V, Giannicola G, Passaretti D, Venditto T, Gumina S. Adhesive capsulitis of the shoulder: pain intensity and distribution. *Musculoskelet Surg* 2017;101(Suppl 2):153-8. <https://doi.org/10.1007/s12306-017-0488-6>
3. Redler LH, Dennis ER. Treatment of adhesive capsulitis of the shoulder. *J Am Acad Orthop Surg* 2019;27(12):e544-e554. <https://doi.org/10.5435/JAAOS-D-17-00606>
4. Ewald A. Adhesive capsulitis: a review. *Am Fam Physician* 2011;83(4):417-22. PMID: 21322517
5. Wang W, Shi M, Zhou C, Shi Z, Cai X, Lin T, et al. Effectiveness of corticosteroid injections in adhesive capsulitis of shoulder: A meta-analysis. *Medicine (Baltimore)* 2017;96(28):e7529. <https://doi.org/10.1097/MD.00000000000007529>
6. Ramirez J. Adhesive capsulitis: Diagnosis and management. *Am Fam Physician* 2019;99(5):297-300. PMID: 30811157
7. Neviasser AS, Hannafin JA. Adhesive capsulitis: a review of current treatment: A review of current treatment. *Am J Sports Med* 2010;38(11):2346-56. <https://doi.org/10.1177/0363546509348048>
8. Kelley MJ, Shaffer MA, Kuhn JE, Michener LA, Seitz AL, Uhl TL, et al. Shoulder pain and mobility deficits: adhesive capsulitis: Clinical practice guidelines linked to the international classification of functioning, disability, and health from the orthopaedic section of the American physical therapy association. *J Orthop Sports Phys Ther* 2013;43(5):A1-31. <https://doi.org/10.2519/jospt.2013.0302>
9. Hsu JE, Anakwenze OA, Warrender WJ, Abboud JA. Current review of adhesive capsulitis. *J Shoulder Elbow Surg* 2011;20(3):502-14. <https://doi.org/10.1016/j.jse.2010.08.023>
10. Neviasser AS, Neviasser RJ. Adhesive capsulitis of the shoulder. *J Am Acad Orthop Surg* 2011;19(9):536-42. <https://doi.org/10.5435/00124635-201109000-00004>
11. Yip M, Francis AM, Roberts T, Rokito A, Zuckerman JD, Virk MS. Treatment of adhesive capsulitis of the shoulder: A critical analysis review. *JBJS Rev* 2018;6(6):e5-e5. <https://doi.org/10.2106/JBJS.RVW.17.00165>
12. Kingston K, Curry EJ, Galvin JW, Li X. Shoulder adhesive capsulitis: epidemiology and predictors of surgery. *J Shoulder Elbow Surg* 2018;27(8):1437-43. <https://doi.org/10.1016/j.jse.2018.04.004>
13. Noten S, Meeus M, Stassijns G, Van Glabbeek F, Verborgt O, Struyf F. Efficacy of different types of mobilization techniques in patients with primary adhesive capsulitis of the shoulder: A systematic review. *Arch Phys Med Rehabil* 2016;97(5):815-25. <https://doi.org/10.1016/j.apmr.2015.07.025>
14. Shang X, Zhang Z, Pan X, Li J, Li Q. Intra-articular versus subacromial corticosteroid injection for the treatment of adhesive capsulitis: A meta-analysis and systematic review. *BioMed Res Int* 2019;2019:1274790. <https://doi.org/10.1155/2019/1274790>

15. Fields BKK, Skalski MR, Patel DB, White EA, Tomasian A, Gross JS, et al. Adhesive capsulitis: review of imaging findings, pathophysiology, clinical presentation, and treatment options. *Skeletal Radiol* 2019;48(8):1171-84. <https://doi.org/10.1007/s00256-018-3139-6>
16. Struyf F, Meeus M. Current evidence on physical therapy in patients with adhesive capsulitis: what are we missing? *Clin Rheumatol* 2014;33(5):593-600. <https://doi.org/10.1007/s10067-013-2464-3>
17. Koh KH. Corticosteroid injection for adhesive capsulitis in primary care: a systematic review of randomised clinical trials. *Singapore Med J* 2016;57(12):646-57. <https://doi.org/10.11622/smedj.201614>
18. Sun Y, Lu S, Zhang P, Wang Z, Chen J. Steroid injection versus physiotherapy for patients with adhesive capsulitis of the shoulder: A PRIMSA systematic review and meta-analysis of randomized controlled trials. *Medicine (Baltimore)* 2016;95(20):e3469. <https://doi.org/10.1097/MD.0000000000003469>
19. Cho CH, Bae KC, Kim DH. Treatment strategy for frozen shoulder. *Clin Orthop Surg* 2019;11(3):249-57. <https://doi.org/10.4055/cios.2019.11.3.249>
20. Angst F, Schwyzer H-K, Aeschlimann A, Simmen BR, Goldhahn J. Measures of adult shoulder function: Disabilities of the arm, shoulder, and hand questionnaire (DASH) and its short version (QuickDASH), shoulder pain and disability index (SPADI), American shoulder and elbow surgeons (ASES) society standardized shoulder. *Arthritis Care Res (Hoboken)* 2011;63(Suppl 11):S174-S188. <https://doi.org/10.1002/acr.20630>
21. Jain TK, Sharma NK. The effectiveness of physiotherapeutic interventions in treatment of frozen shoulder/adhesive capsulitis: a systematic review. *J Back Musculoskeletal Rehabil* 2014;27(3):247-73. <https://doi.org/10.3233/BMR-130443>