

Endoscopic Spring Ligament Repair. Anatomic Evaluation of Portal Safety

Héctor Masaragian, Leonel A. Rega, Fernando Perin, Nicolás Ameriso, Hernán E. Coria, César M. Fabrego, Johann L. Veizaga Velasco

Cirurgiadelpie.net, Autonomous City of Buenos Aires, Argentina

ABSTRACT

Introduction: Calcaneonavicular ligament injury has been described as a cause of adult flat foot deformity. The objective of this study is to describe modified portals for the diagnosis and treatment of injuries to the superomedial bundle of the calcaneonavicular ligament and to evaluate the safety of the portals used. **Materials and Methods:** We performed a cadaveric specimen study on 6 feet, where we reproduced a lesion of the superomedial bundle of the calcaneonavicular ligament with a radiofrequency ablation device and repaired it endoscopically. Two modified portals were created for the approach and an anatomical dissection was performed to assess the safety of the portals in relation to the anatomical structures. The first portal was placed immediately proximal to a line drawn from the tip of the medial malleolus toward the center of the heel; the second portal was placed 0.5 cm proximal to the posterior tibial tendon insertion into the navicular bone, guided by transillumination. If needed, an accessory portal was placed halfway between the two previously described portals immediately dorsal to the posterior tibial tendon. **Results:** In all cases, ligament repair was achieved with the endoscopic procedure. In the anatomical dissection of the portals, we observed an average distance of 11.83 mm from the proximal portal and 9.66 mm from the distal portal to neurovascular structures. **Conclusion:** Modified portals are safe and allow direct visualization of the superomedial bundle of the calcaneonavicular ligament to perform endoscopic repair.

Keywords: spring ligament, posterior tibial tendon dysfunction, endoscopic repair of the spring ligament, tondoscopy, progressive collapsing foot deformity, adult flatfoot

Level of Evidence: IV

Seguridad de los portales para la reparación endoscópica del ligamento calcaneonavicular: estudio cadavérico

RESUMEN

Introducción: La lesión del ligamento calcaneonavicular ha sido descrita como una de las causas de la deformidad en el pie plano del adulto. El objetivo de este artículo es describir portales modificados para el diagnóstico y la reparación endoscópica de las lesiones del fascículo superomedial del ligamento calcaneonavicular y evaluar la seguridad de los portales utilizados. **Materiales y Métodos:** Se llevó a cabo un estudio cadavérico con seis preparados reproduciendo una lesión del fascículo superomedial del ligamento calcaneonavicular con una punta de corte de radiofrecuencia y la posterior reparación endoscópica. Se crearon dos portales modificados para el abordaje. Luego se procedió a la disección anatómica para evaluar la seguridad de los portales en relación con las estructuras anatómicas. El primer portal se realiza inmediatamente proximal a una línea trazada desde la punta del maléolo medial dirigida al centro del talón, el segundo portal se emplaza 0,5 cm proximal a la inserción del tendón tibial posterior en el escafoides por transiluminación. Si es necesario, se coloca un portal accesorio inmediatamente dorsal al tendón tibial posterior a mitad de camino entre los dos portales antes descritos. **Resultados:** En todos los casos, fue posible la reparación del ligamento con el procedimiento endoscópico. En la disección anatómica de los portales, se observó una distancia promedio a las estructuras vasculonerviosas de 11,83 mm del portal proximal y de 9,66 mm del portal distal. **Conclusión:** Los portales modificados, son seguros y permiten la visualización directa del haz superomedial del ligamento calcáneo-navicular y su reparación endoscópica.

Palabras clave: Ligamento calcaneonavicular; disfunción del tendón tibial posterior; reparación endoscópica; tondoscopy; colapso progresivo del arco; pie plano del adulto.

Nivel de Evidencia: IV

Received on August 7th, 2022. Accepted after evaluation on December 5th, 2022 • Dr. HÉCTOR MASARAGIAN • masa@cirugiadelpie.net  <https://orcid.org/0000-0001-5971-5121>

How to cite this article: Masaragian H, Rega LA, Perin F, Ameriso N, Coria HE, Fabrego CM, Veizaga Velasco JL. Endoscopic Spring Ligament Repair. Anatomic Evaluation of Portal Safety. *Rev Asoc Argent Ortop Traumatol* 2023;88(1):113-122. <https://doi.org/10.15417/issn.1852-7434.2023.88.1.1645>

INTRODUCTION

The calcaneonavicular ligament complex or *spring ligament* is usually formed by two components, the superomedial ligament and the inferior ligament.¹⁻³ The superomedial ligament is quadrangular in shape and merges with the inferior ligament. It also fuses with components of the deltoid ligament and talonavicular ligament. It has a fibrocartilage surface in its central area that supports the talus head, clearly differentiable during the endoscopic procedure. The inferior ligament is trapezoidal and supports the inferior side of the talus head, with a triangular surface of dorsal fibrocartilage.¹ Taniguchi et al. described a third fiber ligament that is independent of the other two ligaments, also known as the medioplantar oblique ligament. Its origin lies in the coronoid fossa between the anterior and medial facets of the calcaneus and goes towards its insertion at the edge of the navicular.²

Functionally, the spring ligament acts as a main stabilizer of the medial arch and is the first static support of the talonavicular joint.⁴

The sequelae of spring ligament injury are described in the literature.^{5,6} The involvement of this ligament is frequent and even as important as that of the posterior tibial tendon (PTT).⁴ PTT dysfunction could lead to stress on the deltoid ligament or the spring ligament, which is lengthened and eventually injured. On the other hand, an initial injury to the spring ligament increases the strain on the PTT, which causes PTT dysfunction.⁶ The same happens in ankle and foot misalignments that produce a medial overload on structures that maintain the position of the arch of the foot and predispose to long-term mechanical failure.

In this study, an endoscopic repair technique is described, using modified portals for spring ligament repair and eventual PTT lesions.

The objective of this study was to evaluate the safety of modified portals for endoscopic spring ligament repair.

MATERIALS AND METHODS

An anatomical investigation was performed on six fresh frozen cadaveric pieces; four (66.67%) were left and two (33.33%) were right. The specimens were prepared by the technical staff of the laboratory. They had been amputated at the infrapatellar level, with preservation of the proximal insertion of the PTT.

An injury was caused to the superomedial ligament of the spring ligament with a radiofrequency ablation device and endoscopic repair was performed. The portals were made as described in the surgical technique. After entering the PTT sheath, the spring ligament was identified and repaired. All cadaveric pieces were dissected to evaluate the effectiveness of the suture performed, the portals, and their relationship with the vital structures of the studied anatomical region.

Surgical technique

The procedure is carried out with a 4 mm scope at a 30° angle, allowing a much wider field of view (a 2.7 mm scope can also be used). For the surgical technique, a Mini Scorpion suture passer clamp (Arthrex® Inc., Naples, Florida, USA) is used.

The first portal is located just behind the tip of the medial malleolus, proximal to a line drawn from the end of the inner malleolus to the central area of the heel. First, saline is injected into the PTT sheath (Figure 1). Skin is cut only with a No. 15 scalpel and a straight Halstead mosquito clamp is used to open the tendon sheath. At this point, it is important to check if we are inside the correct sheath (posterior tibial tendon), as the clamp might slip inside the sheath of the flexor digitorum longus tendon. Moving the toes is a simple maneuver to verify the correct location of the scopes.

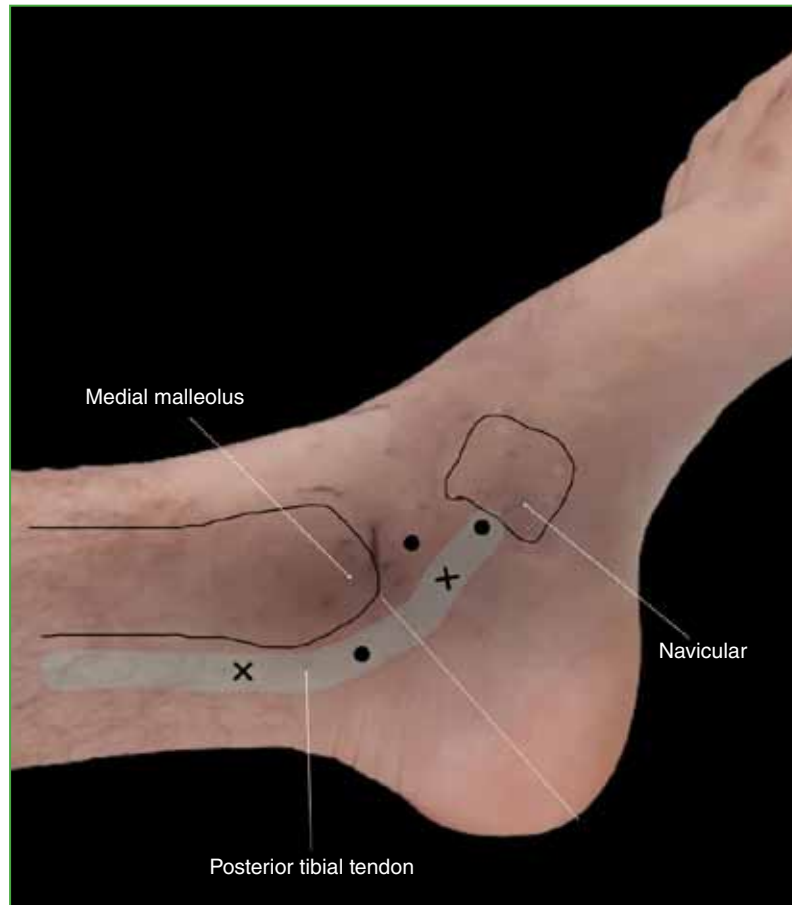


Figure 1. Classic location of portals for posterior tibial tendoscopy (crosses). Modification of the classic tendoscopy portals, recommended for better visualization of the calcaneonavicular ligament or *spring ligament*. Accessory dorsal portal to the posterior tibial tendon (dots).

The second portal is placed 0.5 cm proximal to the distal insertion of the PTT by transillumination and with the help of an intramuscular needle in the endoscopic vision for a correct location (Figure 2).

If the ligament injury is difficult to repair or it is not possible to maneuver with the Mini Scorpion® clamp within the tendon sheath, a third accessory portal, immediately dorsal to the tendon path, can be placed midway between the portals already described, to facilitate repair with the suture-passer clamp (Figure 3) (Video ▶).

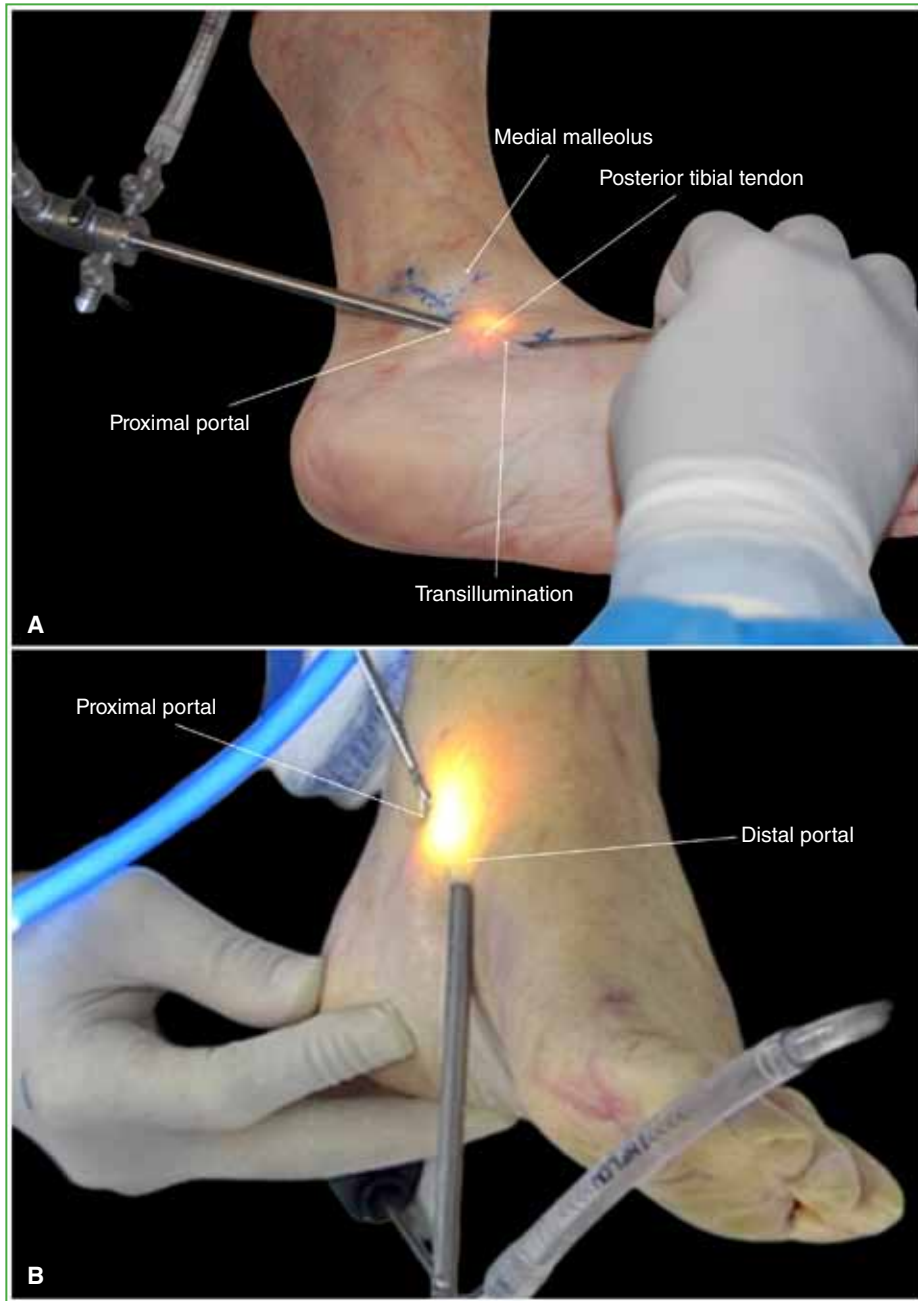


Figure 2. Location of the portals. **A.** Location of the distal portal guided by transillumination. Note the needle for endoscopic guidance. **B.** Location of the scope in the proximal portal. Note the hand position to provide a more stable grip, as described by van Dijk et al.

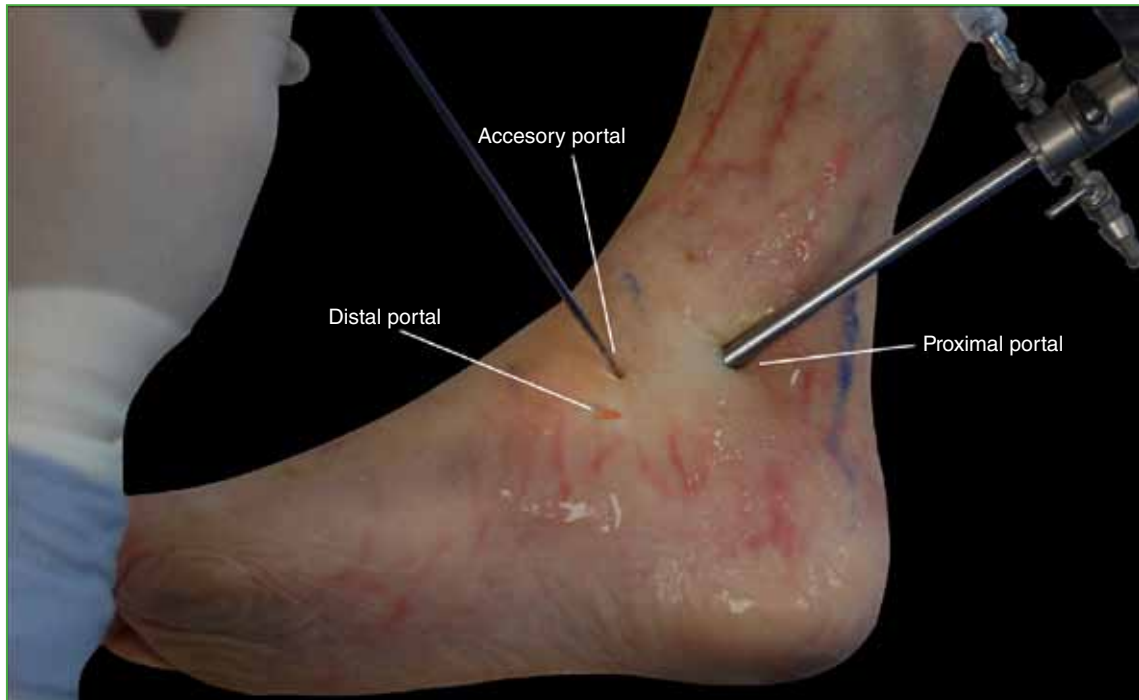


Figure 3. Location of the accessory portal. The probe entering through the portal allows the mobilization of the posterior tibial tendon or, eventually, the entry of the suture passer clamp to repair the calcaneonavicular ligament. Nylon 4-0 is used to close the portals.

RESULTS

Endoscopic repair with two portals could be performed on all specimens used. Only in one, an accessory portal was used to allow better maneuverability with the suture-passer clamp in ligament repair.

In the medial region of the ankle and the hindfoot, there are usually two communicating branches of the great saphenous vein: the anastomosis between the medial plantar vein and the great saphenous vein, and a distal vascular branch that corresponds to the perinavicular venous plexus.^{7,8} All the samples in our series had this vascular anastomosis, while 50% had a perinavicular venous plexus.

The saphenous nerve is posterior to the saphenous vein and is divided into two branches, a small one ending at the level of the ankle joint and a second sensory branch passing in front of the tibial malleolus and giving superficial endings on the medial side of the foot to the hallux.⁵ The medial sensory branch of the internal saphenous nerve could be observed in all specimens and the average distance was >30 mm from the portals used (Figure 4A).

The average distance from the vital vascular elements to the proximal portal was 11.83 mm (range 5-20) and, to the distal portal, 9.66 mm (range 3-22) (Figure 4B and C).

In a single anatomical sample, it was necessary to use the accessory portal to improve the suturing maneuver with the suture passer clamp. In the dissection, it was observed that it was located 2 mm from the branches named above (Figure 5). The results are summarized in the Table.

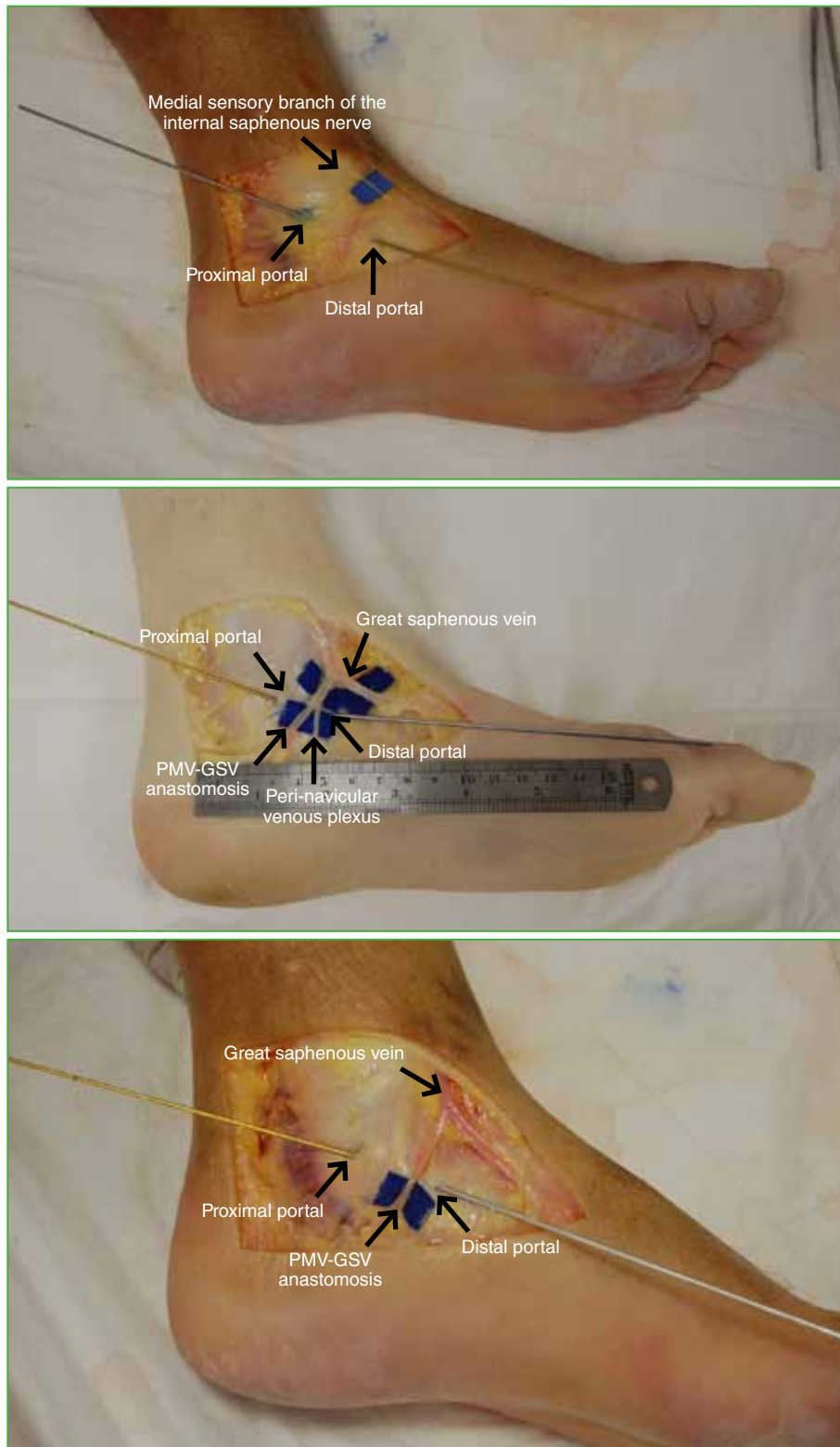


Figure 4. Vital structures near the portals. **A.** Sensitive branch of the internal saphenous nerve. **B.** In this anatomical specimen, anastomosis of the plantar medial vein (PMV) with the great saphenous vein (GSV) can be observed, as well as part of the peri-navicular venous plexus, and the distance from the portals. **C.** PMV-GSV anastomosis, without the presence of the peri-navicular venous plexus.

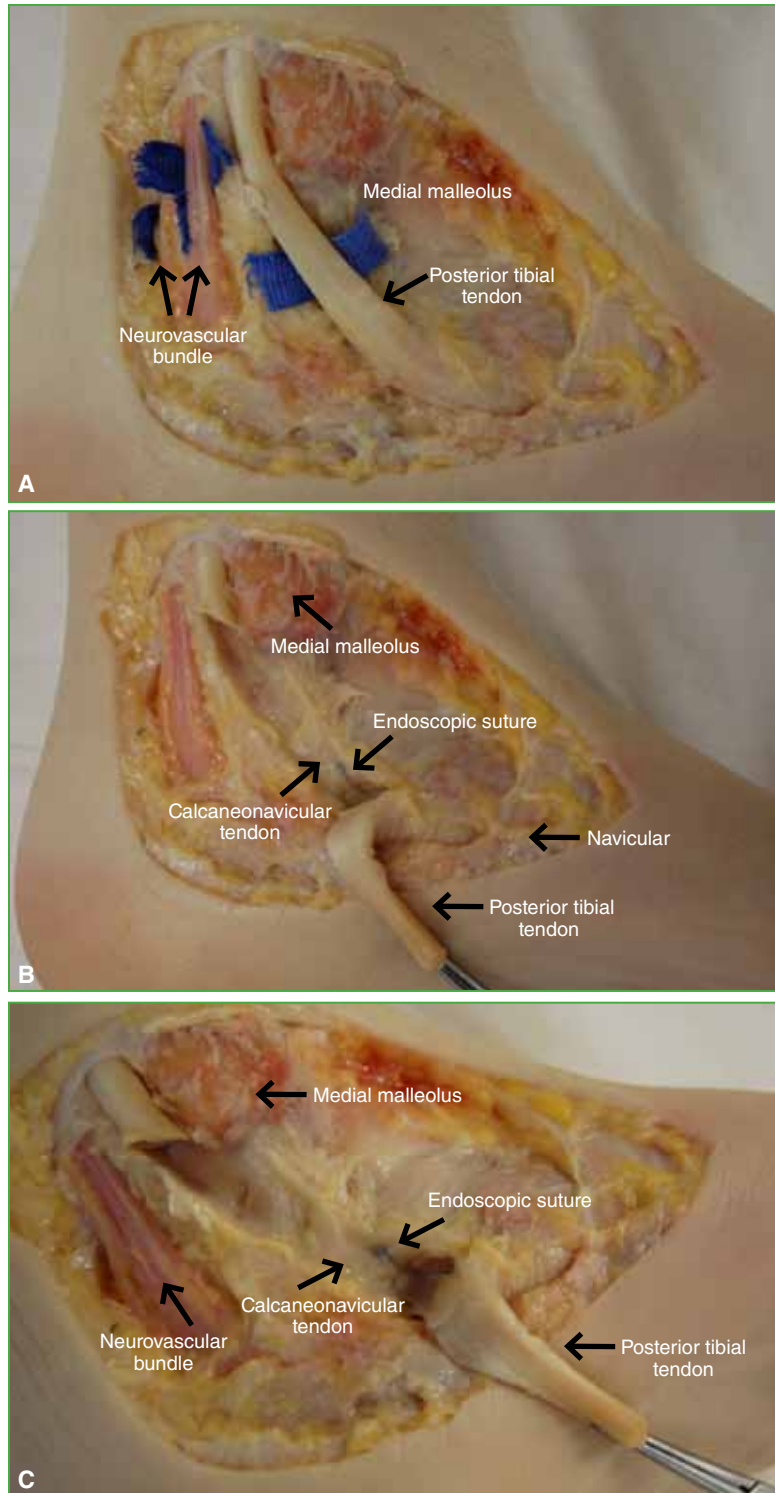


Figure 5. A. Anatomical relationship with the posterior tibial neurovascular bundle. **B and C.** Endoscopic repair of the calcaneonavicular ligament. In these specimens, the final result of endoscopic suturing of the calcaneonavicular ligament is shown. Perpendicular to the arrow is the suture thread that closes the ligament gap and the knot proximal to it. Below, the ligament lesion line is closed by the suture

Table. Results of the study

Specimen	Foot	Perinavicular venous plexus	PMV-GSV anastomosis	Distance to the proximal portal (mm)	Distance to the distal portal (mm)	Accessory portal	Spring ligament repair
1	Left	Yes	Yes	5	5	No	Yes
2	Right	Yes	Yes	10	6	Yes	Yes
3	Right	No	Yes	20	15	No	Yes
4	Left	No	Yes	20	7	No	Yes
5	Left	Yes	Yes	13	3	No	Yes
6	Left	No	Yes	3	22	No	Yes

PMV = plantar medial vein; GSV= great saphenous vein

DISCUSSION

In recent studies, it has been proposed that degenerative or traumatic injuries to the spring ligament and deltoid ligament may be precursor injuries to the complete pathology of the adult flatfoot.^{5,6,9} With new imaging techniques and a clearer clinical presentation, these injuries can be detected and diagnosed early.

In biomechanical studies, it has been shown that spring ligament injury, cyclic foot loading, and bone factors that compromise ankle and hindfoot alignment are all causes of deformity and, over time, can lead to progressive collapsing foot deformity or acquired adult flatfoot.⁴ Spring ligament involvement has been noted as a primary causal factor in peritalar subluxation.^{10,11} Because of this, surgical ligament repair or reconstruction has become an important factor in treatment. On numerous occasions, it requires extensive soft tissue dissection because the ligament is a deep structure. The evaluation and endoscopic treatment of the ligament can avoid unnecessary open exploration and have the advantage of achieving better aesthetic results, with lower morbidity and postoperative pain.^{12,13}

Wertheimer was the first to describe, in 1995, a technique to perform a PTT endoscopy on a patient; the site of the portals was 2 cm proximal to the medial malleolus and 2 cm distal to it, the classics for PTT tendoscopy.¹⁴

In their 1997 dissection study, van Dijk et al. pointed out that the tendon can be accessed through any part of its path, and described both portals 2 or 1.5 cm from the medial malleolus to proximal and distal. In their research, they used a 2.7 mm scope.¹⁵

In 2007, Lui introduced a technique of endoscopic repair of the PTT with an anterior tibial hemigraft, for grade II dysfunctions, where the distal portal is performed 1 cm from the navicular and uses a 2.7 mm scope; he also recommended the possible use of a 4.0 mm scope.¹²

Another report by the same author in 2016 describes a variant in the surgical technique for endoscopic repair of the spring ligament by adding a plantar medial accessory portal to the classic tendoscopy portals and a suture-passing instrument (Viper Suture Passer®, (Arthrex® Inc., Naples, Florida, USA)).^{16,17} The author also points out the safety of the portals, especially the plantar accessory portal to the path of the PTT, and reports that the only structure at risk when using this accessory portal is the medial or internal plantar branch of the posterior tibial nerve. He also described the possibility of spring ligament repair through arthroscopy of the talonavicular joint.¹⁶

In our study, with the portals made in the way we describe them in our surgical technique, the possibility of causing the nerve injuries already mentioned is minimized, because we do not use any plantar portal for access to the spring ligament or PTT, but a dorsal accessory portal located midway between the other two described.

We recommend this procedure for experienced surgeons, as it has a medium learning curve and requires specific knowledge of foot anatomy and special instrumentation, in addition to the ability to resolve any complications that arise during the procedure.

The limitations of this study are due to the use of cadaveric specimens and the number of pieces used. For future lines of research, we propose to carry out clinical, prospective, randomized and comparative studies with more specimens that allow better statistical analysis and a final evaluation of the technical results.

CONCLUSIONS

Endoscopy is an effective technique for the diagnosis and treatment of spring ligament superomedial ligament lesions. According to the results of our anatomical dissection, we can conclude that the portals used are safe for the surgical technique described and also for the endoscopic repair of the spring ligament. It was reproducible in all specimens, it was possible to close the gap produced, artificially, in all cases, without any injury to the regional vital structures, which remained at a sufficiently safe distance from the portals used for the procedure.

Conflict of interest: The authors declare no conflicts of interest.

L. A. Rega ORCID ID: <https://orcid.org/0000-0002-6850-5318>
 F. Perin ORCID ID: <https://orcid.org/0000-0001-7921-7576>
 N. Ameriso ORCID ID: <https://orcid.org/0000-0002-8191-7616>

H. E. Coria ORCID ID: <https://orcid.org/0000-0002-0532-4763>
 C. M. Fabrego ORCID ID: <https://orcid.org/0000-0002-3626-3916>
 J. L. Veizaga Velasco ORCID ID: <https://orcid.org/0000-0002-4998-2944>

REFERENCES

1. Golano P, Fariñas O, Sáenz I. The anatomy of the navicular and periarticular structures. *Foot Ankle Clin* 2004;9(1):1-23. [https://doi.org/10.1016/S1083-7515\(03\)00155-4](https://doi.org/10.1016/S1083-7515(03)00155-4)
2. Taniguchi A, Tanaka Y, Takakura Y, Kadono K, Maeda M, Yamamoto H. Anatomy of the spring ligament. *J Bone Joint Surg Am* 2003;85(11):2174-8. <https://doi.org/10.2106/00004623-200311000-00018>
3. Acevedo J, Vora A. Anatomical reconstruction of the spring ligament complex: "Internal brace" augmentation. *Foot Ankle Spec* 2013;6(6):441-5. <https://doi.org/10.1177/1938640013499404>
4. Deland JT, Ellis SJ, Day J, Netto CDC, Hintermann B, Myerson MS, et al. Indications for deltoid and spring ligament reconstruction in progressive collapsing foot deformity. *Foot Ankle Int* 2020;41(10):1302-6. <https://doi.org/10.1177/1071100720950742>
5. Orr JD, Nunley JA. Isolated spring ligament failure as a cause of adult-acquired flatfoot deformity. *Foot Ankle Int* 2013;34(6):818-23. <https://doi.org/10.1177/1071100713483099>
6. Jennings MM, Christensen JC. The effects of sectioning the spring ligament on rearfoot stability and posterior tibial tendon efficiency. *J Foot Ankle Surg* 2008;47(3):219-24. <https://doi.org/10.1053/j.jfas.2008.02.002>
7. Kelikian AS, Sarrafian SK. *Sarrafian's anatomy of the foot and ankle: descriptive, topographic, functional*. Philadelphia: Lippincott Williams & Wilkins; 2011.
8. Testut L, Latarjet A. *Tratado de anatomía humana*. Barcelona: Salvat; 1964, vol. 9.
9. Tryfonidis M, Jackson W, Mansour R, Cooke PH, Teh J, Ostlere S, et al. Acquired adult flat foot due to isolated plantar calcaneonavicular (spring) ligament insufficiency with a normal tibialis posterior tendon. *Foot Ankle Surg* 2008;14(2):89-95. <https://doi.org/10.1016/j.fas.2007.11.005>
10. Masaragian HJ, Massetti S, Perin F, Coria H, Cicarella S, Mizdraji L, et al. Flatfoot deformity due to isolated spring ligament injury. *J Foot Ankle Surg* 2020;59(3):469-78. <https://doi.org/10.1053/j.jfas.2019.09.011>
11. Masaragian HJ, Ricchetti HO, Testa C. Acute isolated rupture of the spring ligament: A case report and review of the literature. *Foot Ankle Int* 2013;34(1):150-4. <https://doi.org/10.1177/1071100712460222>
12. Lui TH. Endoscopic assisted posterior tibial tendon reconstruction for stage 2 posterior tibial tendon insufficiency. *Knee Surg Sport Traumatol Arthrosc* 2007;15(10):1228-34. <https://doi.org/10.1007/s00167-006-0282-8>
13. Lui TH. Posterior tibial tendoscopy: Endoscopic synovectomy and assessment of the spring (calcaneonavicular) ligament. *Arthrosc Tech* 2015;4(6):e819-23. <https://doi.org/10.1016/j.eats.2015.08.006>

14. Wertheimer SJ, Frascone ST, Loder BG, Calderone DR, Calderone DR, Frascone ST. The role of endoscopy in treatment of stenosing posterior tibial tenosynovitis. *J Foot Ankle Surg* 1995;34(1):15-22. [https://doi.org/10.1016/S1067-2516\(09\)80097-5](https://doi.org/10.1016/S1067-2516(09)80097-5)
15. van Dijk CN, Kort N, Scholten PE. Tendoscopy of the posterior tibial tendon. *Arthroscopy* 1997;13(6):692-8. [https://doi.org/10.1016/s0749-8063\(97\)90002-5](https://doi.org/10.1016/s0749-8063(97)90002-5)
16. Lui TH. Arthroscopic repair of superomedial spring ligament by talonavicular arthroscopy. *Arthrosc Tech* 2017;6(1):e31-5. <https://doi.org/10.1016/j.eats.2016.08.034>
17. Lui TH. Endoscopic repair of the superficial deltoid ligament and spring ligament. *Arthrosc Tech* 2016;5(3):e621-5. <https://doi.org/10.1016/j.eats.2016.02.004>