

Olecranon Fracture. A New Therapeutic Alternative

Marcos N. Cabrera, Luciano N. Caló

Upper Limb Team, Sanatorio Güemes, Autonomous City of Buenos Aires, Argentina

ABSTRACT

Objective: Displaced olecranon fractures mostly require surgical fixation. The most commonly used techniques are tension band wiring and plate fixation, but they are associated with high rates of discomfort due to soft tissue irritation. An alternative surgical option is fixation with high-strength sutures with intramedullary screws. The aim of this study is to evaluate the range of motion, bone healing and complications using this technique. **Materials and Methods:** Six patients with type IIA fractures with an average age of 43 years (range 24-60 years) treated with high strength suture and intramedullary screw between January 2020 - April 2021 were included. Post-operative range of motion, bone healing and complications were evaluated. All were evaluated up to 6 months postoperatively. **Results:** At the 6th postoperative month, the average flexion was 143° (range 90°-160°), average extension 19° (0°-55°), there was bone healing in 5 patients, and 1 nonunion with joint stiffness (complication 16.6%). There were no second surgeries. **Conclusion:** Simple displaced olecranon fractures treated with high-strength suture with intramedullary screws is a simple, reproducible and economical technique since it does not require a second surgery, as is the case with traditional fixation methods for this pathology. **Keywords:** Olecranon fracture; high strength suture; intramedullary screw.

Level of Evidence: IV

Fractura de olécranon. Nueva alternativa terapéutica

RESUMEN


Introducción: Las fracturas de olécranon desplazadas mayoritariamente requieren de fijación quirúrgica. Las técnicas más usadas son las clavijas con alambre en 8 y las placas anatómicas, pero están asociadas a altas tasas de insatisfacción por irritación de las partes blandas. Una nueva opción quirúrgica es la fijación con suturas de alta resistencia y tornillo canulado. El objetivo de este estudio fue evaluar los rangos de movilidad, la consolidación ósea y las complicaciones utilizando esta técnica. **Materiales y Métodos:** Se presenta a 6 pacientes con fracturas tipo IIA y un promedio de la edad de 43 años (rango 24-60) tratados con suturas de alta resistencia y tornillo canulado intramedular entre enero de 2020 y abril de 2021. Se evaluó el rango de movilidad posoperatorio, la consolidación ósea y las complicaciones. Todos fueron evaluados hasta el mes 6 posoperatorio. **Resultados:** A los 6 meses de la cirugía, el promedio de flexión fue de 143° (rango 90°-160°) y la extensión promedio, de 19° (0°-55°). Se logró la consolidación ósea en 5 pacientes y hubo un retraso de la consolidación con rigidez articular (complicación 16,6%). No hubo segunda intervenciones. **Conclusión:** La fijación con suturas de alta resistencia y tornillo canulado para las fracturas simples desplazadas de olécranon es una técnica simple, reproducible y económica, ya que no necesitaría de segunda intervenciones, como sí sucede con las fijaciones tradicionales.

Palabras clave: Fractura; olécranon; sutura de alta resistencia; tornillo canulado intramedular.

Nivel de Evidencia: IV

INTRODUCTION

Olecranon fractures represent 10% of upper limb fractures, and the most frequent is type IIA of the Mayo Classification.^{1,2} These occur as a result of a direct (impact on the dorsal aspect of the olecranon) or indirect traumatic mechanism (impact of the humeral trochlea in the greater sigmoid cavity of the ulna during a fall with the elbow in extension added to triceps traction).³ Although there are grounds for conservative treatment in elderly patients with low demand, these fractures are typically surgically resolved.⁴ Multiple surgical options have been described

Received on June 25th, 2022. Accepted after evaluation on July 9th, 2022 • Dr. MARCOS N. CABRERA • dochnahuel@hotmail.com  <https://orcid.org/0000-0001-9632-9211>

How to cite this article: Cabrera MN, Caló LN. Olecranon Fracture. A New Therapeutic Alternative. *Rev Asoc Argent Ortop Traumatol* 2022;87(4):526-533. <https://doi.org/10.15417/issn.1852-7434.2022.87.4.1608>

for the treatment of olecranon fractures (tension band wiring, anatomical plates, cannulated intramedullary screws alone or with wire, intramedullary nails, and tension band with sutures only).⁵⁻⁷ All of these fixation methods result in anatomic reduction, restoration of the range of motion, and fracture union.

Tension band wiring and anatomical plates are the most widely used therapeutic options for simple displaced type IIA fractures.² Tension band wiring converts triceps distraction forces into compression at the articular surface (tension band principle), with excellent functional outcomes similar to those achieved by absolute reduction with anatomical plates. However, both methods are associated with several complications (prominence of the material, discomfort, pin or wire discomfort, pain, bursitis, infection) which raises the reoperation rate to 46-65%.⁸ The skin and subcutaneous tissue are thin at the proximal end of the ulna and cause soft tissue irritation, requiring implant removal in 68-82% of patients.⁹⁻¹¹ So, it is imperative to reduce these complications. Biomechanically, polyester and polyethylene sutures have similar strength to wire,¹² and cannulated screws are generally used for olecranon osteotomies.^{13,14} Therefore, the combined use of high-strength sutures with an intramedullary screw provides satisfactory stability without soft tissue irritation, greatly reducing the reoperation rate. These combined methods were only reported in cadaveric studies¹² and in olecranon osteotomies for distal humerus fractures.¹⁵

The objective of this case series study was to evaluate functionality, bone consolidation and complications in type IIA olecranon fractures treated with this new technique of high-strength sutures and cannulated screw.

MATERIALS AND METHODS

A retrospective study was carried out that included patients with non-comminuted displaced olecranon fractures type IIA of the Mayo Classification, between January 2020 and April 2021. Diagnosis was made with anteroposterior and lateral radiographs. Patients with extra-articular fractures, fractures combined with a forearm fracture, comminuted fractures, fractures treated conservatively, and fractures treated with tension band wiring or anatomical plates were excluded. Considering these inclusion criteria, six patients with type IIA fracture were identified who were treated with high-strength sutures plus intramedullary partial-thread cannulated screw with a 6.5-mm washer. All were operated on by the same surgeon.

Surgical technique

The patient is under general anesthesia in the supine position with a hemostatic cuff. A posterior approach is used for open reduction and internal fixation (incision 3 cm superior from the proximal end of the olecranon to approximately 4 cm distal to the fracture). The curettage of the fracture focus and its reduction with instruments are performed. The intramedullary guide pin is placed in the proximal ulna, then intramedullary reaming is performed with a 4.5-mm cannulated drill (from the superior aspect of the transtricipital olecranon toward the medullary canal, approximately 8-10 cm). Next, 4 cm distal to the fracture site, a hole is made with a 2.0 mm wick or pin in the posterior cortex of the ulna, from side to side, in a transverse trajectory. The high-strength sutures are inserted through said hole and a figure-of-eight suture is made at the level of the fracture, passing the sutures proximally below the triceps at its distal insertion. The fracture is again reduced with instruments to tie the closure and tension knots with the high-strength sutures. Subsequently, the 6.5 mm partially threaded cannulated screw with a washer is placed to increase the compression of the fracture site. Its length will be decided taking into account that all the threads of the cannulated screw must pass the fracture line and the width of the medullary canal from the proximal ulna distally to the fracture site (about 80-100 mm) to achieve a stable fixation. Finally, the end of the cannulated screw with its washer is covered with soft tissue to prevent future irritation of the subcutaneous cellular tissue. The entire procedure is carried out and controlled by radioscopy (Figure 1). (Video ►)

Patients begin functional rehabilitation early, without immobilization of the elbow in the immediate postoperative period. They are allowed passive and active functional motion, but without load or force until week 6 after surgery. Clinical follow-up is carried out at weeks 2, 6 and 10, evaluating the postoperative range of motion, bone consolidation by means of radiographs, and the presence of complications.

The data were collected in Numbers version 11.1. All the patients signed the informed consent which clarified that the surgical procedures could be used for study or academic purposes.

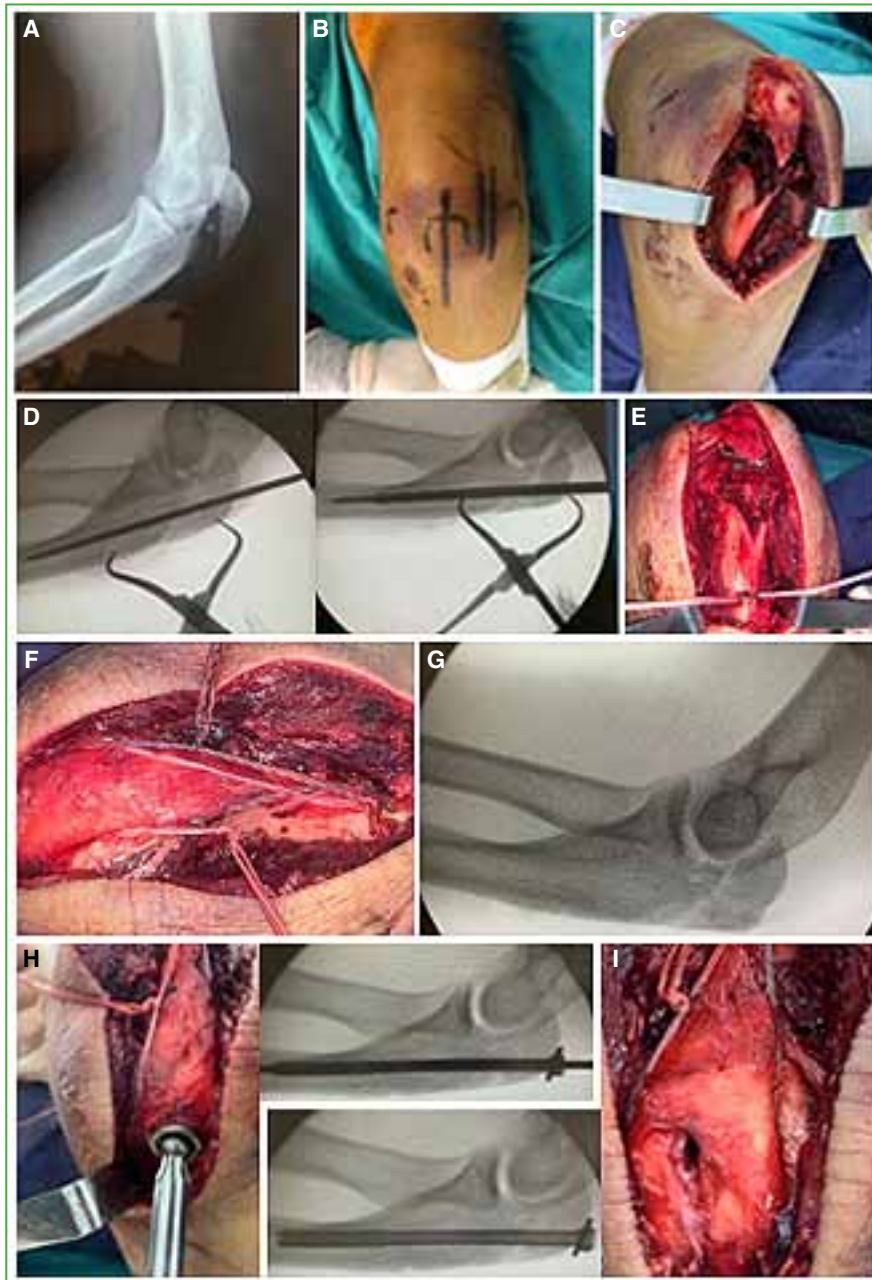


Figure 1. A. Radiograph of a type IIA fracture. B. Approach. C. Fracture focus. D. Reduction and intramedullary reaming. E. Posterior cortical hole for sutures. F. Figure-of-eight suture. G. Figure-of-eight suture reduction. H. Placement of the cannulated screw. I. Final reduction.

RESULTS

Six patients with simple displaced type IIA fracture of the olecranon were identified and were treated with high-strength sutures and an intramedullary partial-thread cannulated screw with a 6.5 mm washer. Four patients were men and two were women, and the average age was 43 years (range 24-60). Immediate postoperative radiographic controls were performed, and at weeks 2, 6 and 10 (Figure 2).

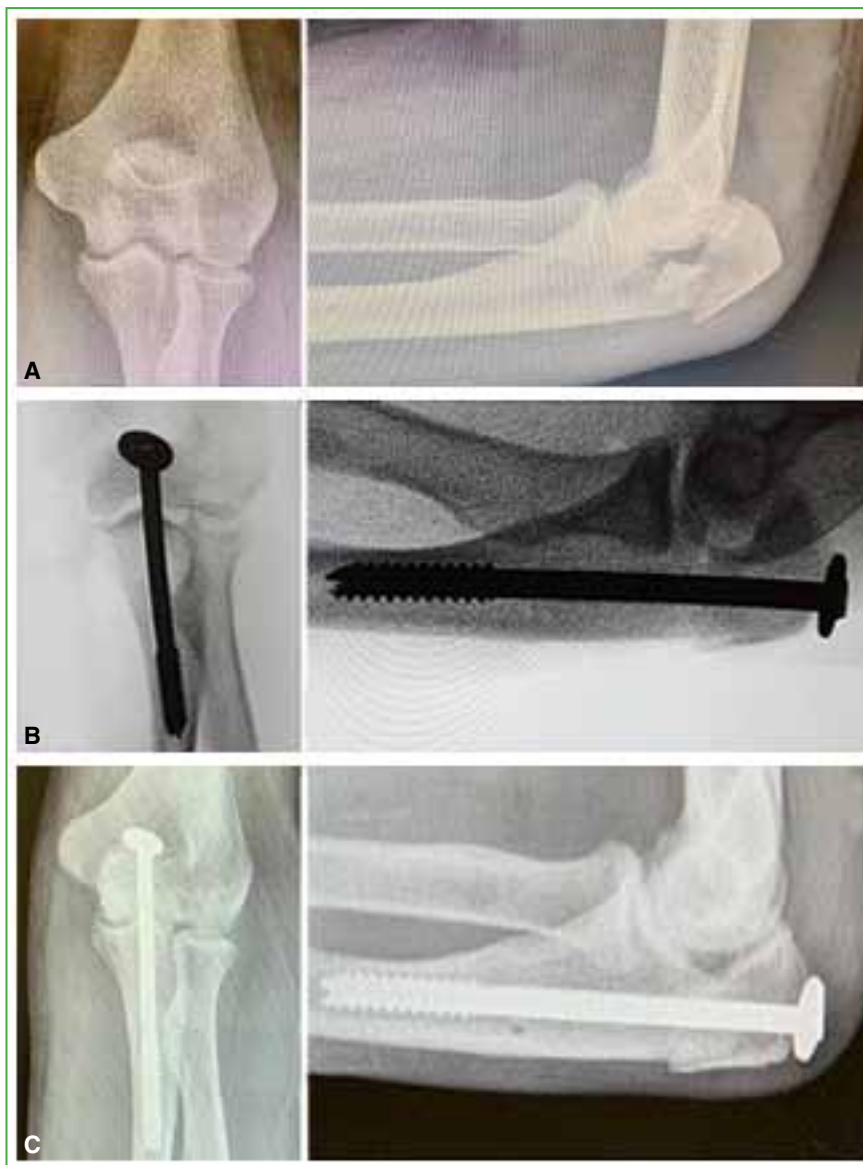

Figure 2. A. Anteroposterior and lateral radiographs of a fracture. B. Immediate postoperative period. C. Consolidated fracture at week 10.

Bone consolidation was confirmed in all patients, except for one who developed elbow joint stiffness due to poor follow-up with delayed consolidation (16.6%). He continued with occupational therapy and achieved bone consolidation and recovery of the range of motion. There were no wound complications nor revision surgeries. The average flexion was 143° (range 160°-90°) and the average extension was 19° (range 0°-55°). All reached full pronosupination (Figure 3 and Table).

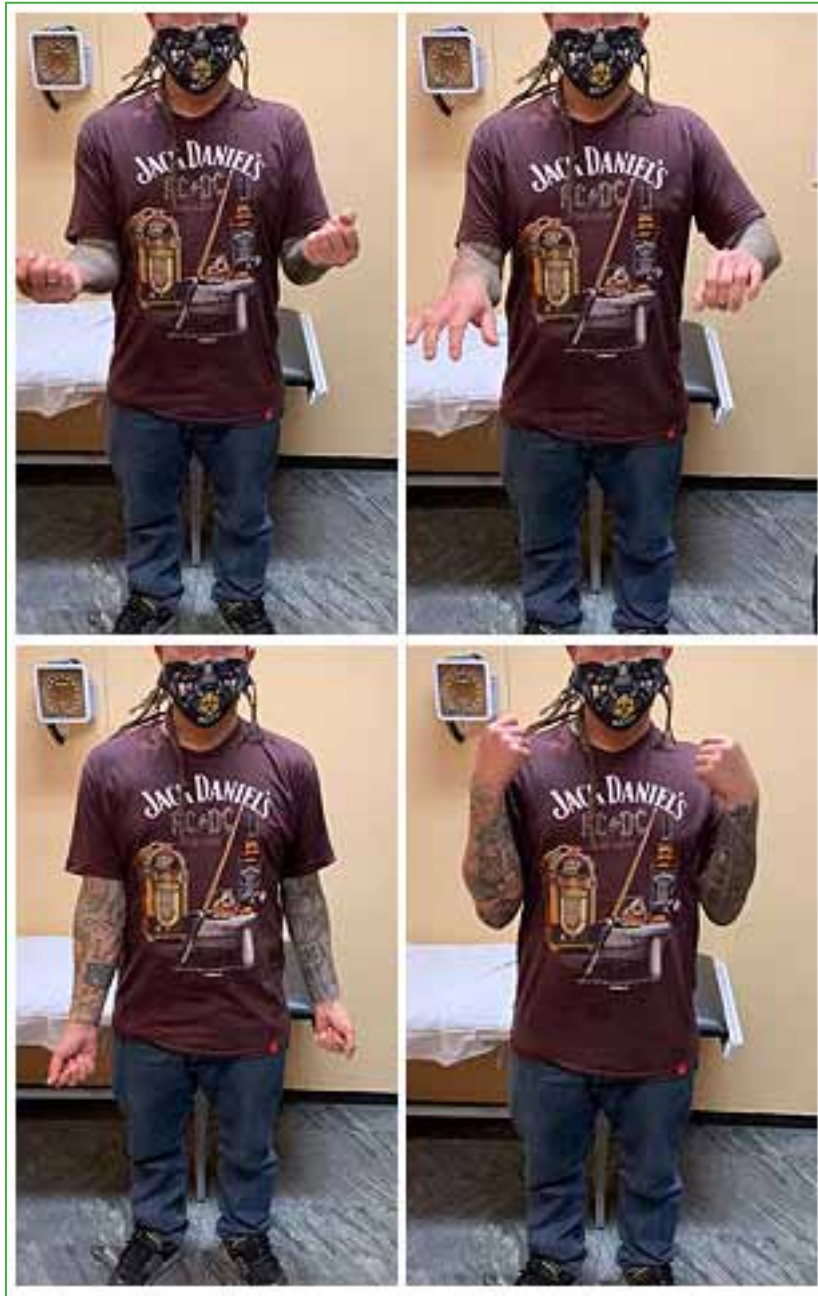

Figure 3. Postoperative range of motion - 6 weeks.

DISCUSSION

Tension band wiring and anatomical plates are the most widely used therapeutic options to treat simple displaced olecranon fractures. This new alternative with high-strength sutures and a 6.5 mm partially threaded cannulated screw with a washer is a reasonable surgical option according to the results presented. Multiple studies show that tension band wiring and anatomical plates achieve similar bone union and functional outcomes,¹⁶⁻¹⁸ but with a high reoperation rate (mainly removal of material due to discomfort) ranging between 30% and 80%,^{8,9,19-21} Clearly, this detail increases costs and patient morbidity.⁹

Lallis and Branstetter²² compared three sutures (Ethibon® No. 2, No 5 and high-strength suture) to cerclage wire. They showed that high-strength sutures obtain results similar to those of wire when subjected to distraction forces; therefore, it becomes an alternative for the fixation of these fractures.

Carofino et al.¹² compared high-strength sutures with wire, using pins or cannulated screws that were tested under active motion, and found no differences in fixation, either with pins or cannulated screws.

Bosman et al.²³ treated 15 patients with simple olecranon fractures with cannulated screws alone and achieved an adequate range of motion (average flexion 145°, extension 11°), excellent bone consolidation results, and a lower rate of complications than with traditional treatments.

Nazifi et al.⁷ carried out a systematic review of studies with level IV evidence on the use of strong sutures and anchors for olecranon fractures. They only found nine published articles, and concluded that the use of sutures is a cost-effective alternative to wire, since it greatly reduces the rate of reoperation.

The therapeutic option described in this case series, which uses low-profile implants (which do not need to be removed) with acceptable functional outcomes is the strength of this technique. Patients benefited from early range of motion. One patient developed joint stiffness due to poor follow-up, with delayed union. With occupational therapy, his range of motion increased and he did not require surgical intervention.

This study has severe limitations: its retrospective design, the lack of a control group and the small number of patients that determine that the results do not have a statistical impact.

However, publications of this technique have only been on cadavers¹² and Chevron osteotomies in distal humerus fractures.¹⁵ There have been no publications on its use for simple fractures.

Future studies should increase the number of patients and follow-up time, compare this technique with other fixation options, and study other possible indications for its use.

Table. Patient characteristics

Age	Flexion	Extension	Bone union	Complications
28	150	10	Yes	No
24	160	5	Yes	No
60	140	25	Yes	No
57	90	55	Delay	Stiffness
35	155	20	Yes	No
56	160	0	Yes	No

CONCLUSION

High-strength suture with a cannulated screw is a simple, reproducible, and cost-effective technique from an economic point of view, since it would avoid second interventions (removal of the implant) and would reduce costs compared to traditional techniques. It offers adequate stability, with bone consolidation and acceptable ranges of motion.

Conflict of interest: The authors declare no conflicts of interest.

L. N. Caló ORCID ID: <https://orcid.org/0000-0002-8702-4819>

REFERENCES

1. Duckworth AD, Clement ND, Aitken SA, Court-Brown CM, McQueen MM. The epidemiology of fractures of the proximal ulna. *Injury* 2012;43(3):343-6. <https://doi.org/10.1016/j.injury.2011.10.017>
2. Wiegand L, Bernstein J, Ahn J. Fractures in brief: olecranon fractures. *Clin Orthop Relat Res* 2012;470(12):3637-41. <https://doi.org/10.1007/s11999-012-2393-5>
3. Amis AA, Miller JH. The mechanisms of elbow fractures: an investigation using impact tests in vitro. *Injury* 1995;26(3):163-8. [https://doi.org/10.1016/0020-1383\(95\)93494-3](https://doi.org/10.1016/0020-1383(95)93494-3)
4. Duckworth AD, Bugler KE, Clement ND, Court-Brown CM, McQueen M. Nonoperative management of displaced olecranon fractures in low-demand elderly patients. *J Bone Joint Surg Am* 2014;96(1):67-72. <https://doi.org/10.2106/JBJS.L.01137>
5. Labrum JT 4th, Foster BD, Weikert DR. Augmented intramedullary screw tension band construct for olecranon fracture reduction and fixation: a review of literature and surgical technique. *JSES Int* 2020;4(3):470-7. <https://doi.org/10.1016/j.jseint.2020.04.005>
6. Nimura A, Nakagawa T, Wakabayashi Y, Sekiya I, Okawa A, Muneta T. Repair of olecranon fractures using fiberWire without metallic implants: report of two cases. *J Orthop Surg Res* 2010;5:73. <https://doi.org/10.1186/1749-799X-5-73>
7. Nazifi O, Gunaratne R, D'Souza H, Tay A. The use of strength sutures and anchors in olecranon fractures: A systematic review. *Geriatric Orthop Surg Rehab* 2021;12:2151459321996626. <https://doi.org/10.1177/2151459321996626>
8. Snoddy M, Gunaratne R, D'Souza H, Tay A. Olecranon fractures: factors influencing re-operation. *Int Orthop* 2014;38(8):1711-6. <https://doi.org/10.1177/2151459321996626>
9. Duckworth AD, Clement ND, White TO, Court-Brown CM, McQueen MM. Plate versus tension-band wire fixation for olecranon fractures: a prospective randomized trial. *J Bone J Surg Am* 2017;99(15):1261-73. <https://doi.org/10.2106/JBJS.16.00773>
10. Nork SE, Jones CB, Henley MB. Surgical treatment of olecranon fractures. *Am J Orthop (Belle Mead NJ)* 2001;30:577-86. PMID: 11482514
11. Claessen FMAP, Braun Y, Peters RM, Dyer G, Doornberg JN, Ring D. Factors associated with reoperation after fixation of displaced olecranon fractures. *Clin Orthop Relat Res* 2016;474(1):193-200. <https://doi.org/10.1007/s11999-015-4488-2>
12. Carofino BC, Santangelo SA, Kabadi M, Mazzocca AD, Browner BD. Olecranon fractures repaired with Fiberwire or metal wire tension banding: a biomechanical comparison. *Arthroscopy* 2007;23(9):964-70. <https://doi.org/10.1016/j.arthro.2007.03.008>
13. Coles CP, Barei DP, Nork SE, Taitzman LA, Hanel DP, Bradford Henley M. The olecranon osteotomy: a six-year experience in the treatment of intraarticular fractures of the distal humerus. *J Orthop Trauma* 2006;20(3):164-71. <https://doi.org/10.1097/00005131-200603000-00002>
14. Woods BI, Rosario BL, Siska PA, Gruen GS, Tarkin IS, Evans AR. Determining the efficacy of screw and washer fixation as a method for securing olecranon osteotomies used in the surgical management of intraarticular distal humerus fractures. *J Orthop Trauma* 2015;29(1):44-9. <https://doi.org/10.1097/BOT.0000000000000131>
15. Wagener M, Dezillie M, Hoendervangers Y, Eygendaal D. Clinical results of re-fixation of a Chevron olecranon osteotomy using an intramedullary cancellous screw and suture tension band. *Strategies Trauma Limb Reconstr* 2015;10(1):1-4. <https://doi.org/10.1007/s11751-015-0211-9>
16. De Giacomo AF, Tornetta P 3rd, Sinicrope BJ, Cronin PK, Althausen PL, Bray TJ, et al. Outcomes after plating of olecranon fractures: a multicenter evaluation. *Injury* 2016;47(7):1466-71. <https://doi.org/10.1016/j.injury.2016.04.015>

17. Delsole EM, Pean CA, Tejwani NC, Egol KA. Outcome after olecranon fracture repair: does construct type matter? *Eur J Orthop Surg Traumatol* 2016;26(2):153-9. <https://doi.org/10.1007/s00590-015-1724-0>
18. Gathen M, Jaenisch M, Peez C, Weinhold L, Schmid M, Welle K, et al. Plate fixation and tension band wiring after isolated olecranon fracture comparison of outcome and complications. *J Orthop* 2020;18:69-75. <https://doi.org/10.1016/j.jor.2019.09.017>
19. Newman SDS, Mauffrey C, Krikler S. Olecranon fractures. *Injury* 2009;40:575-81. <https://doi.org/10.1016/j.injury.2008.12.013>
20. Ren Y-M, Qiao H-Y, Wei Z-J, Lin W, Fan B-Y, Liu J, et al. Efficacy and safety of tension band wiring versus plate fixation in olecranon fractures: a systematic review and meta-analysis. *J Orthop Surg Res* 2016;11(1):137. <https://doi.org/10.1186/s13018-016-0465-z>
21. Brolin TJ, Throckmorton T. Olecranon fractures. *Hand Clin* 2015;31(4):581-90. <https://doi.org/10.1016/j.hcl.2015.07.003>
22. Lalliss SJ, Branstetter JG. The use of three types of sutures and stainless-steel wire tension banding for the fixation of simulated olecranon fractures: a comparison study in cadaver elbows. *J Bone Joint Surg Br* 2010;92(2):315-9. <https://doi.org/10.1302/0301-620X.92B2.22596>
23. Bosman W, Emmink B, Bhashyam A, Houwert R, Keizer J. Intramedullary screw fixation for simple displaced olecranon fractures. *Eur J Trauma Emerg Surg* 2020;46(1):83-9. <https://doi.org/10.1007/s00068-019-01114-4>