

# Case Resolution

Rodrigo Re<sup>\*</sup>, Christian Allende Nores<sup>\*\*</sup>

<sup>\*</sup>Diagnostic Imaging Service, Osteoarticular/Musculoskeletal Area - Interventionism, Sanatorio Allende, Córdoba, Argentina

<sup>\*\*</sup>Orthopedics and Traumatology Service, Sanatorio Allende, Córdoba, Argentina

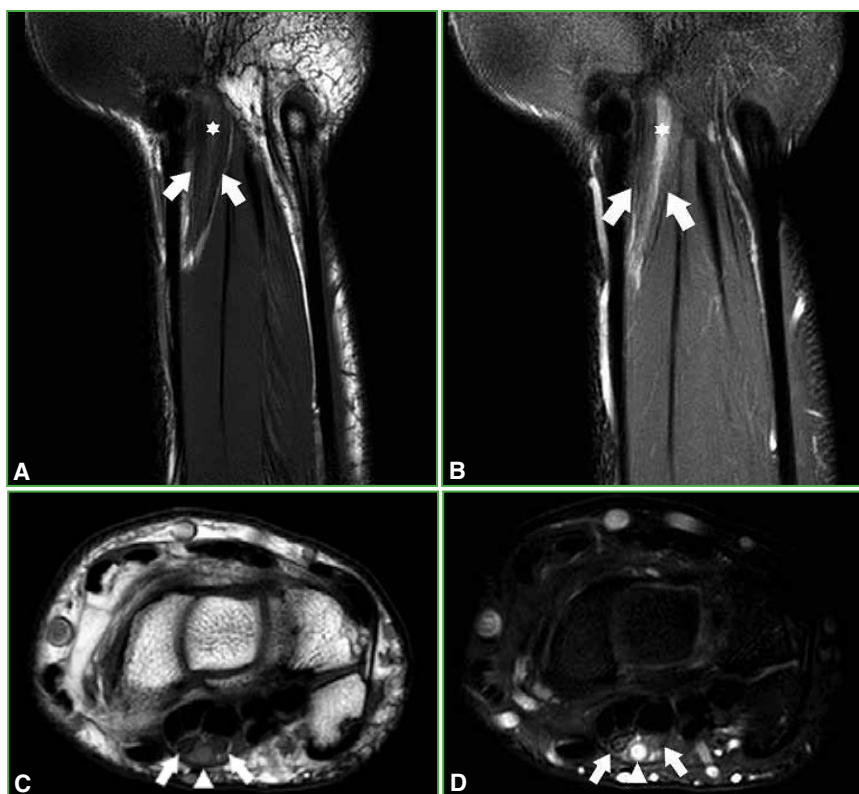
Case presentation on page 745.

**DIAGNOSIS:** Persistent median artery thrombosis

## DISCUSSION

In the magnetic resonance of the right wrist (**Figure 3**) thrombosis of a vascular structure that runs in close contact with the median nerve is observed, producing, at the level of the carpal canal, its dissection, with a marked surrounding inflammatory process. The thrombosis shows hyperintensity both on T1 and fat suppression sequences, and is surrounded by the two components of the median nerve at the level of the carpal tunnel.

Due to the ultrasound and magnetic resonance findings, surgical treatment was decided.



**Figure 3.** Non-contrast magnetic resonance imaging of the right wrist. **A and B.** Coronal T1 and STIR sequences, respectively. Median nerve with bifid morphology (arrows) with a hyperintense tubular image (asterisk). **C and D.** Axial T1 and STIR sequences, respectively. Divided median nerve (arrows) with rounded mass in the middle (arrowhead).

Dr. RODRIGO RE • rodrigo\_re@hotmail.com  <https://orcid.org/0000-0001-7382-9459>

**How to cite this article:** Re R, Allende Nores C. Postgraduate Orthopedic Instruction - Imaging. Case resolution. Rev Asoc Argent Ortop Traumatol 2022;87(6):858-861. <https://doi.org/10.15417/issn.1852-7434.2022.87.6.1605>

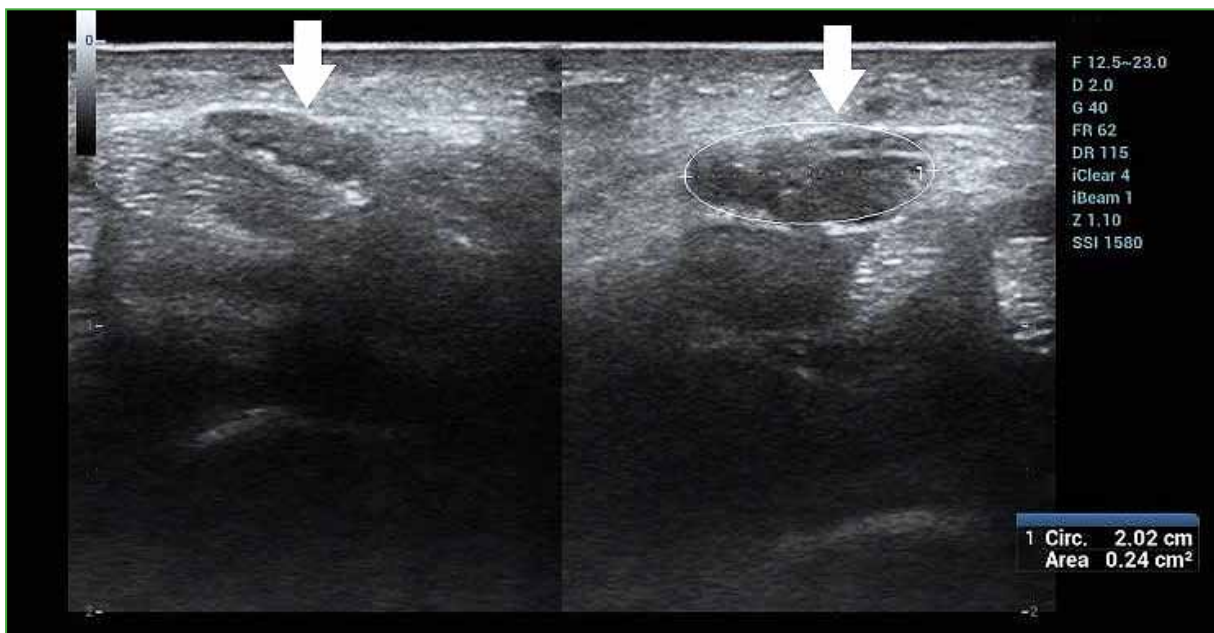
## DIAGNOSIS

With all these findings, a persistent median artery thrombosis with bifid median nerve is diagnosed.

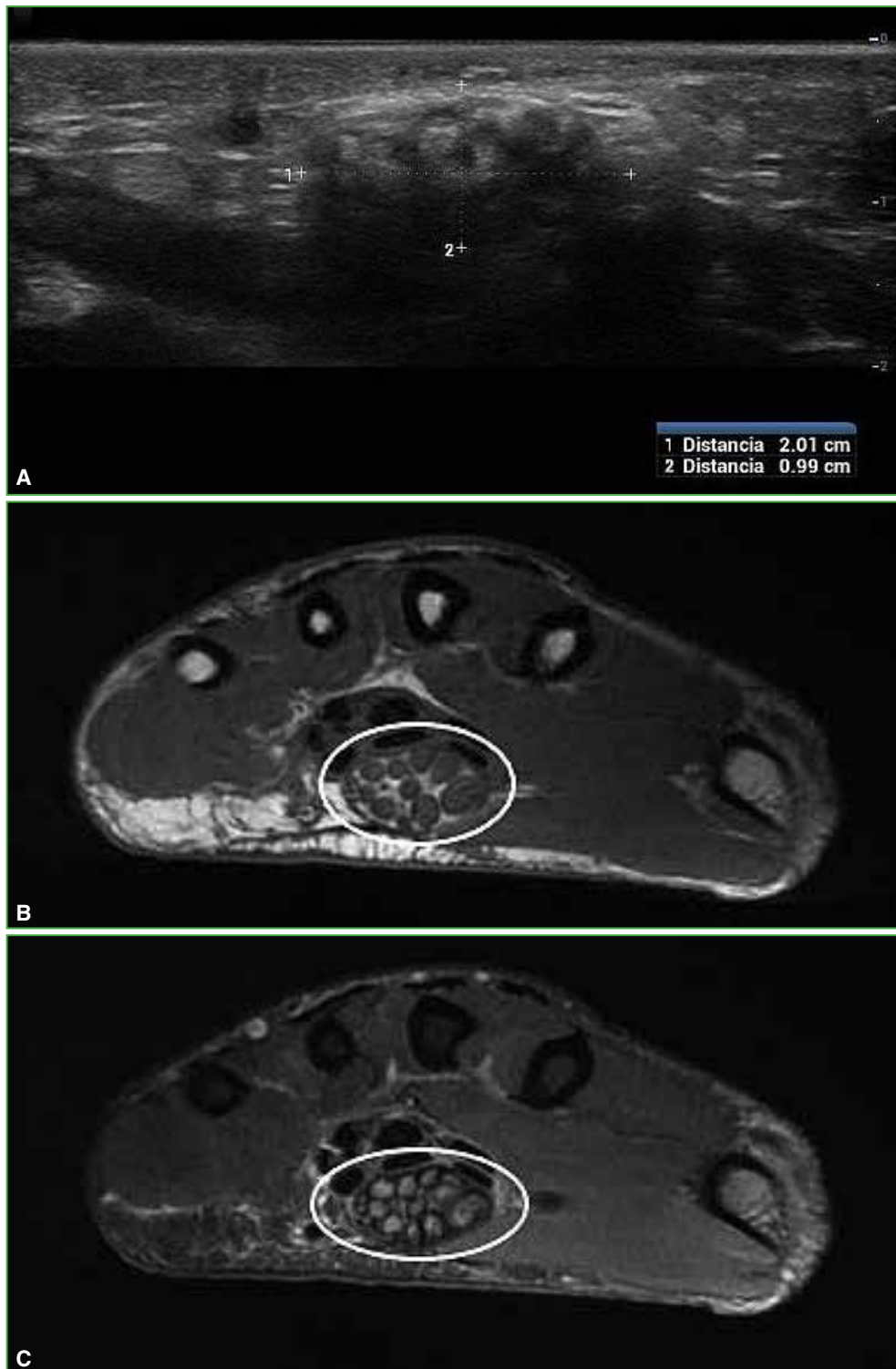The vascular system of the upper limb is very complex and can give rise to numerous anomalies, such as the absence of arteries, alterations in their origins and courses, or the persistence of embryonic arteries. One of these variants is the persistence of the median artery. Structures associated with a persistent median artery may also be abnormal. The presence of a median artery is associated with an anatomical variation of the median nerve, which can present a bifid morphology.

When the persistent median artery exceeds 1.5 mm in diameter, symptoms of median nerve compression may appear. The artery can increase in size due to the presence of calcifications, thrombosis, atherosclerosis, trauma, and dilation.

The most common differential diagnoses are carpal tunnel syndrome (Figure 4) or fibrolipomatous hamartoma of the median nerve (Figure 5).

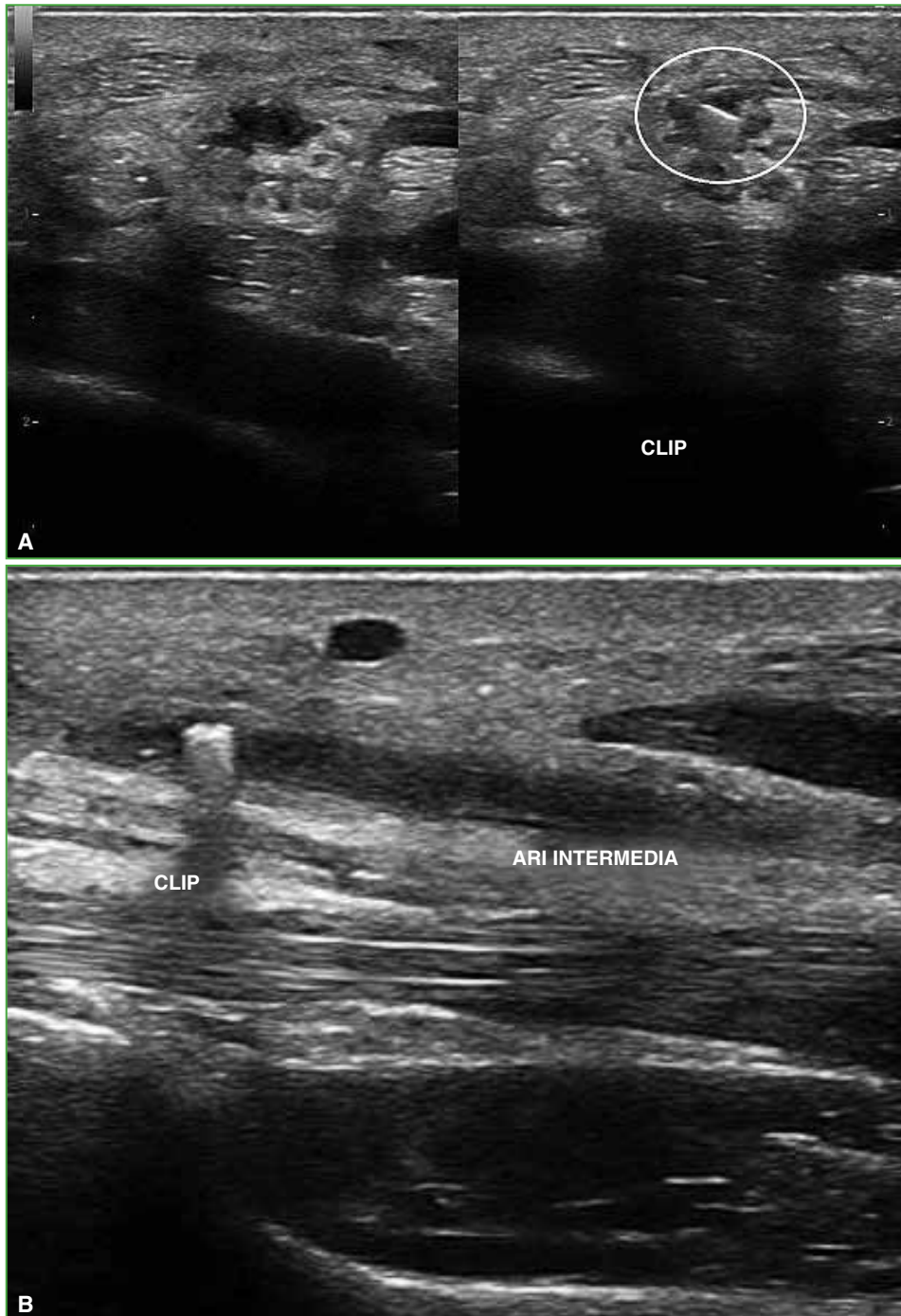


**Figure 4.** Comparative left and right wrist ultrasound showing the enlarged left median nerve, measuring 24 mm<sup>2</sup>.



**Figure 5.** A. Ultrasound of the right wrist with a heterogeneous tumor in the carpal canal. Alternating hypo and hyperechogenic areas. **B and C.** MRI of the right wrist, axial slice, on T1-weighted and STIR sequences, respectively, showing a marked thickening of the median nerve fibers, which shows hypointensity on T1 sequences and slight hyperintensity on fat suppression sequences, with interspersed linear images which are hyperintense on T1 and hypointense on STIR, compatible with fat. Lipomatous hamartoma of the median nerve.

Given the significant symptoms presented by our patient, surgical treatment was decided with the placement of a clip in the artery and the release of the median nerve (Figure 6).



**Figure 6.** Post-surgical ultrasound of the right wrist showing the presence of a clip in the artery and release of the median nerve. **A.** Transverse slice. Right: persistent median artery before clip placement. Left: clip placement site. **B.** Longitudinal slice; clip inside the artery.