

# ‘Irreparable’ Rotator Cuff Tears: Tips and Tricks to Achieve Arthroscopic Repair

Cristina Sánchez-Losilla,\*# Alfred Ferré-Aniorte,\*# Jorge Ramírez-Haua,\*\* Pedro Álvarez-Díaz,\*## Ramón Cugat,\*## Eduard Alentorn-Geli\*##

\*Cugat Institute, García-Cugat Foundation, Barcelona, Spain

\*\*Mutualidad Española de Futbolistas, Federación Española de Fútbol – Delegación Cataluña, Barcelona, Spain

#García-Cugat Foundation, Barcelona, Spain

## ABSTRACT

Irreparable rotator cuff tears are major injuries that can drastically affect the quality of life of the patients. Despite the complexity of the procedure and the high rates of re-tear, surgical repair is justified due to the lack of less aggressive and palliative alternatives. If a repair is not achieved, surgical alternatives are considered including tendon transfer, superior capsular reconstruction, or even reverse shoulder arthroplasty. Accordingly, arthroscopic repair must be performed in order to save the severely injured rotator cuff. The aim of this study is to summarize some of the arthroscopic techniques for repairing the so-called irreparable rotator cuff tears.

**Key words:** Tendon injury; rotator cuff; tendon repair; arthroscopy.

**Level of evidence:** V. Expert opinion

## Roturas “irreparables” del manguito rotador: trucos y consejos para conseguir una reparación artroscópica

## RESUMEN

Las roturas irreparables del manguito rotador son lesiones graves que pueden conllevar consecuencias drásticas en la calidad de vida de los pacientes. Pese a que su reparación es compleja y la tasa de re-rotura es alta, el intento de reparación se justifica por la ausencia de alternativas poco agresivas o paliativas. Cuando no se consigue una reparación, la alternativa es la transferencia tendinosa, la reconstrucción capsular superior o incluso la prótesis invertida de hombro. Por tanto, en muchos casos de cirugía primaria, se debe intentar la reparación artroscópica con el fin de “salvar” el manguito rotador gravemente lesionado. El objetivo de este artículo es resumir algunas de las técnicas artroscópicas para conseguir una reparación de roturas “irreparables” del manguito rotador.

**Palabras clave:** Lesión tendinosa; manguito rotador; reparación tendinosa; artroscopia.

**Nivel de Evidencia:** V Opinión de expertos

## INTRODUCTION

According to Patte, massive rotator cuff tears are those that are within groups III and IV of his classification, that is, they present a full-thickness tear of two or more tendons, with involvement >4 cm in length.<sup>1</sup> A tear is defined as irreparable when the degree of retraction prevents the native tendon from approximating its insertion footprint in the proximal humerus, despite the mobilization of the tissue and the release of the adhesions. Tears with little healing potential are also considered irreparable, that is, those in which the acromiohumeral interval is <6 mm in an anteroposterior radiograph (Hamada-Fukuda grade 2),<sup>2</sup> grade III tears according to the Patte<sup>1</sup> classification and ruptures with severe muscle hypotrophy (fat infiltration >50%) (Goutallier type 3-4)<sup>3,4</sup>. Thus, a massive tear is considered to be irreparable when a compromise of two or more tendons is combined with a retraction of the cuff in the coronal plane up to the glenoid rim and, in addition, it associates a fatty infiltration >50%, with a vertical migration of the humeral head.<sup>1-4</sup>

Received on June 17<sup>th</sup>, 2022. Accepted after evaluation on June 21<sup>st</sup>, 2022 • Dr. CRISTINA SÁNCHEZ-LOSILLA • csanchez@institutocugat.com  <https://orcid.org/0000-0002-0444-8684>

**How to cite this article:** Sánchez-Losilla C, Ferré-Aniorte A, Ramírez-Haua J, Álvarez-Díaz P, Cugat R, Alentorn-Geli E. 'Irreparable' Rotator Cuff Tears: Tips and Tricks to Achieve Arthroscopic Repair. *Rev Asoc Argent Ortop Traumatol* 2022;87(4):559-569. <https://doi.org/10.15417/issn.1852-7434.2022.87.4.1604>

We must keep in mind that not all massive tears are irreparable and not all irreparable tears are massive. According to published studies, the prevalence of irreparable massive tears is 40% of all rotator cuff tears<sup>5</sup> and up to 40% of these tears are symptomatic, causing pain and difficulty in performing basic activities of daily living. This clinical presentation is usually accompanied by loss of strength and limitations in range of motion. In these patients, different treatment alternatives can be proposed to improve symptoms and prevent progression to joint damage that would require the implantation of a reverse shoulder arthroplasty.

Multiple techniques are currently available for the treatment of irreparable rotator cuff tears, although none is clearly superior to the others. To choose the best treatment, it is essential to consider the clinical characteristics and the functional needs and demands of each patient, as well as the characteristics of each tendon tear.

The purpose of this article is to describe various tips and tricks that can be applied when performing an arthroscopic repair of an 'irreparable' rotator cuff tear.

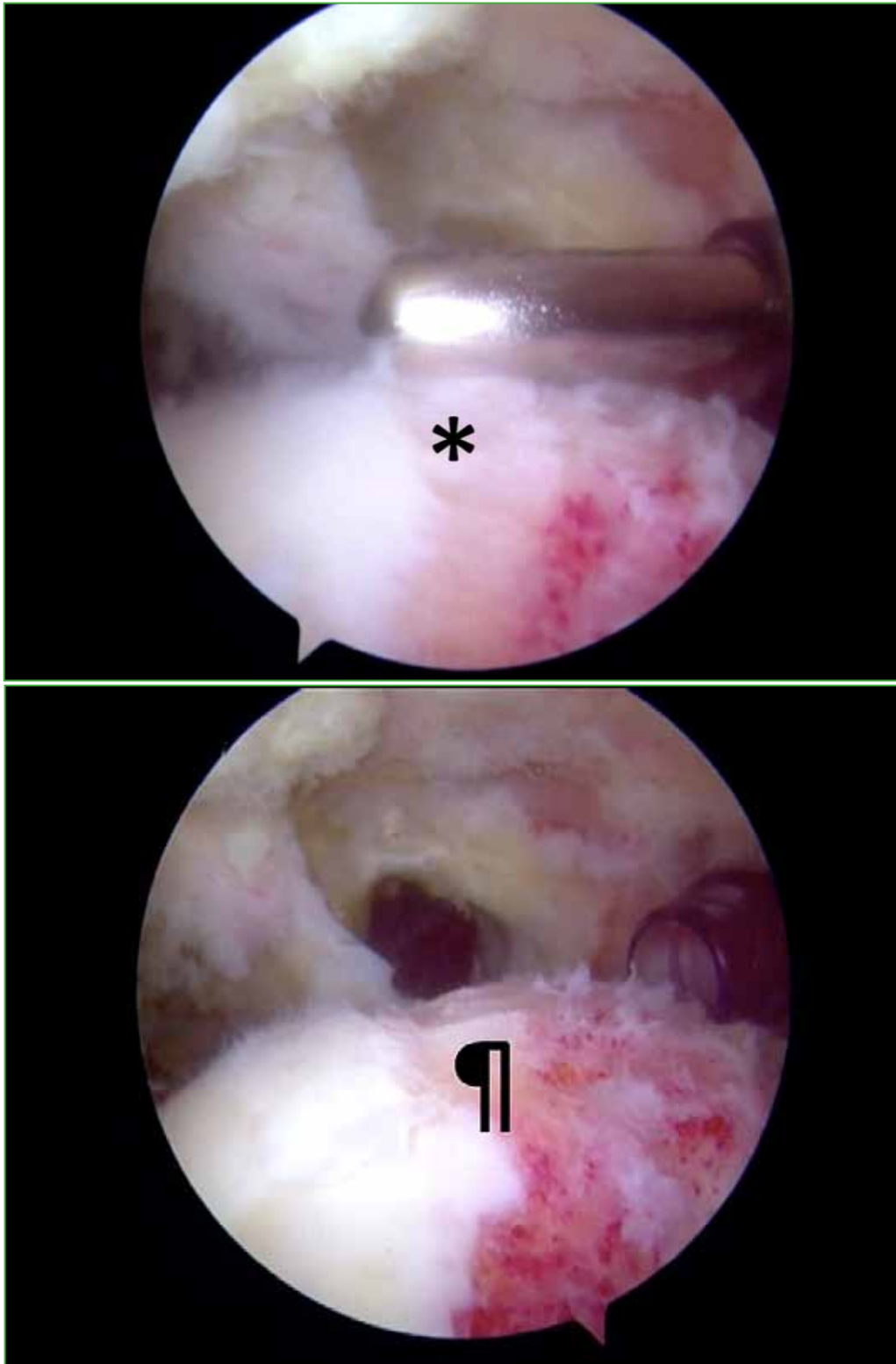
## TIPS AND TRICKS

### Footprint medialization

It is used in patients with a retracted rotator cuff tear (usually medial to the apex of the head) which, once debrided in a standard manner, does not cover the greater tuberosity and sometimes even barely reaches the bone. In these cases, the only option to increase the chances of repair and healing of the tendon is medialization of the footprint. This technique consists of the removal of a part of the most lateral cartilage of the humeral head in order to expose an extra amount of bone in the greater tuberosity (Figure 1). This allows repair of the retracted supraspinatus to be made to the bone. The amount of cartilage that can be resected is not well studied, but it is accepted that up to 8-10 mm can be removed without risk of creating an internal space conflict between the repaired tendon and the superior labrum/biceps long head insertion. Footprint medialization could produce biomechanical alterations due to the shorter distance between the insertion (in case of healing) and the point of rotation of the shoulder in abduction maneuvers. However, it seems logical that function will be better with a repaired and medially healed tendon than with an unrepaired or unhealed tendon. Through partial repair with footprint medialization, it is also possible to avoid tension on the suture and thus be able to restore rotator cuff stability following Burkhart's suspension bridge theory.<sup>6</sup> By reconstructing the rotator cuff cable, balance is restored and the humeral head is kept centered in order to improve symptoms, function and also delay, as far as possible, the progression towards subacromial arthropathy of the rotator cuff.<sup>6</sup>

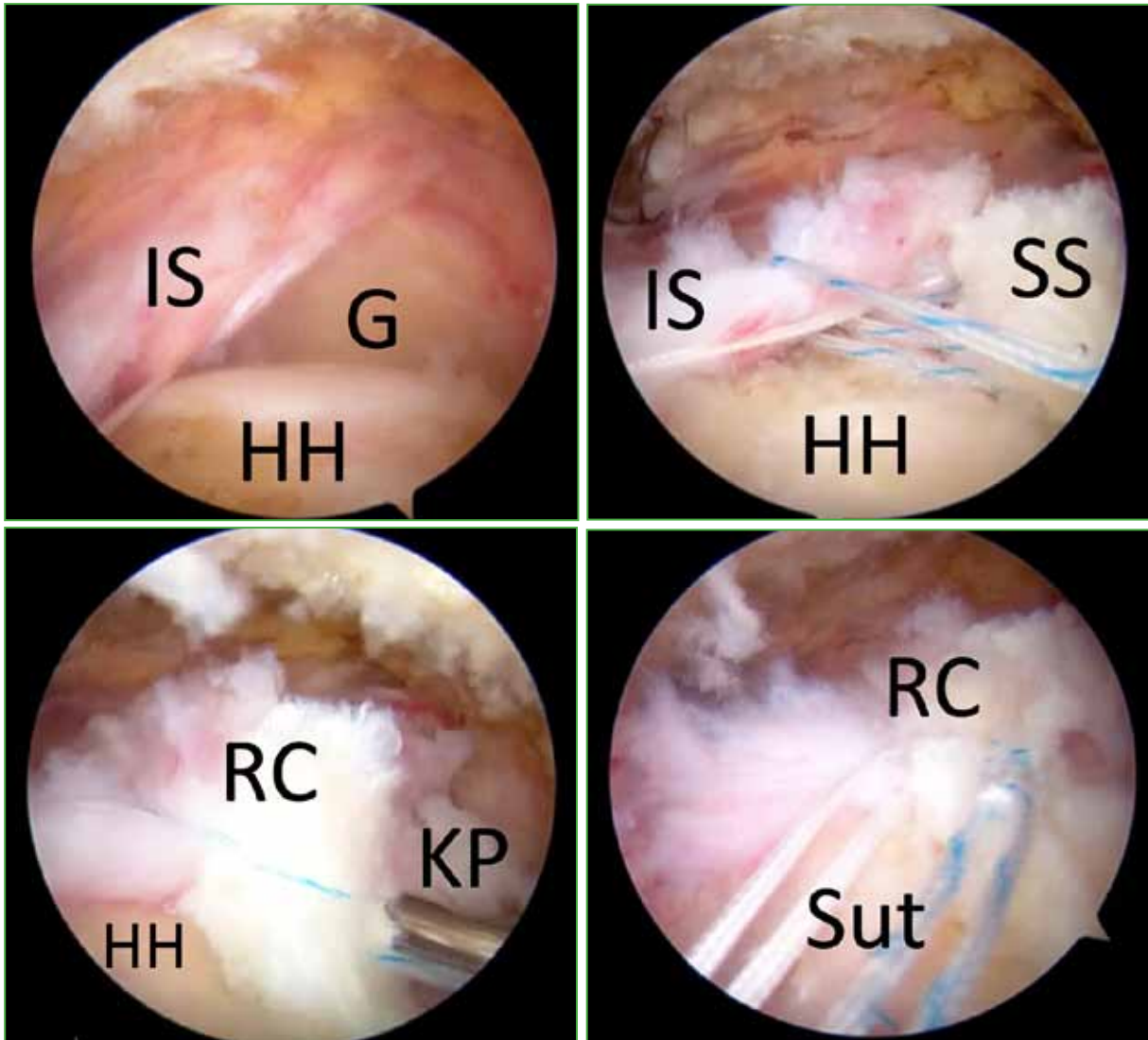
### Margin convergence

Margin convergence is a technique that consists of an approximation closure of the tendon margins of the remaining rotator cuff, either as a primary technique or as an adjuvant technique to a repair. In the former, it is typically used over an extensive tear, normally in a U (or L) shape retracted to the glenoid, but with a movable tendon remnant that allows approximation between the anterior and posterior tendon ends. In the technique we use, a single high-strength suture is used that is entered and retrieved from the posterolateral and anterolateral portals, with a view from the lateral portal. With a tissue penetrator entering posteriorly, grasping half of the suture (leaving two long and equivalent ends), the posterior rotator cuff is penetrated from superior to inferior, and the same is done with another tissue penetrator from superior to inferior in the anterior rotator cuff. The anterior penetrator retrieves the posterior suture loop and exits retrogradely from the anterior part of the rotator cuff. At this time, the tissue penetrator enters the loop that protrudes from the anterior part of the tendon and retrieves one of the loose strands coming out of the posterior part of the rotator cuff, and this strand is brought out of the anterolateral portal. In this instance, the posterior tissue penetrator grasps the posterior suture and retraces the posterior aspect of the tendon from superior to inferior at a point slightly more lateral to the one previously traversed. The anterior tissue penetrator also crosses the anterior part of the tendon from superior to inferior, and recovers the posterior suture that remained grasped by the posterior penetrator, traversing the anterior part of the tendon retrogradely, in the same way that it was previously done. After passing through it, there will be another loop created and, then, the anterior penetrator will enter through this loop and grab the free suture that exits through the anterolateral portal, causing it to pass through this second loop.



**Figure 1.** Complete retracted tear of the supraspinatus with view from the posterior portal. Removal of 5 mm of the most superior cartilage of the humeral head (\*) and final appearance of the bleeding bone once the cartilage has been removed (P).

This maneuver will be repeated as many times as necessary until reaching the most lateral part of the tendon. The free strand coming from the posterolateral portal will then be retrieved from the anterolateral portal, and can be tied with a non-slip knot, completely closing the existing tendon defect (Figure 2).

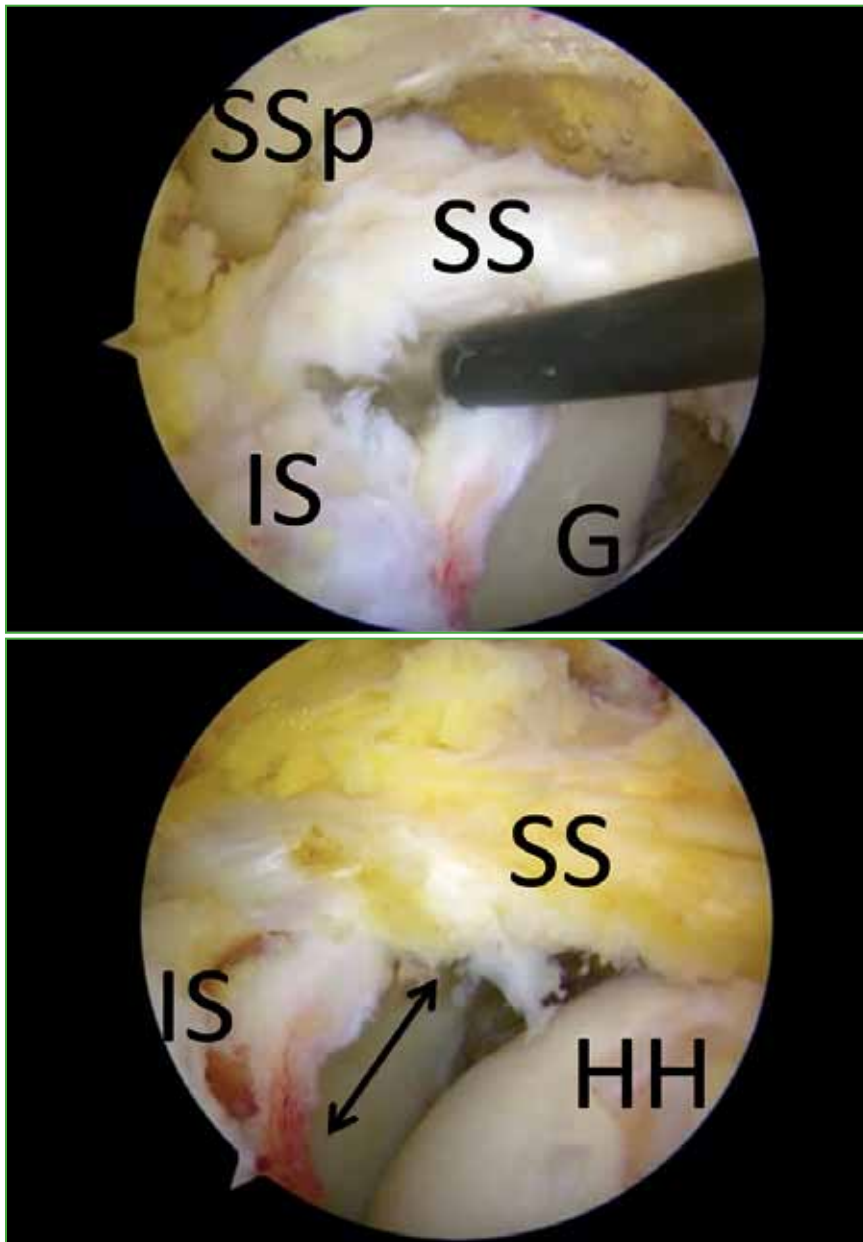

**Figure 2.** Complete retracted supraspinatus tear with lateral view. The glenoid (G), the infraspinatus (IS) and the humeral head (HH) can be seen. Once the sutures have been passed, the approximation of both tendons is achieved, obtaining closure of the rotator cuff (RC) once the suture of the margin convergence with the knot pusher (KP) has been tied. Finally, the convergence and medial anchor sutures (Sut) can be attached through a lateral knotless anchor to complete the repair.

It is important to mention that the convergence of margins must be fixed to the bone. This technique essentially makes an irreparable tear repairable, but then the tendon must be anchored to the bone for better kinetics and kinematics. Our method of choice for bone anchoring would be equivalent to a double row. Before closing the defect, a suture anchor is placed in the bone medially, on the greater tuberosity, and one end of each suture is passed on each side of the converging tendon (or 2 sutures if the anchor has double sutures) to then tie it once the closure by convergence is completed. The convergence and anchor sutures can then be incorporated into a knotless anchor laterally. When this technique is used, it is essential to repair the tendon without creating tension in the pillars (infraspinatus and subscapularis), and maximum biological respect is necessary.

### Interval slide

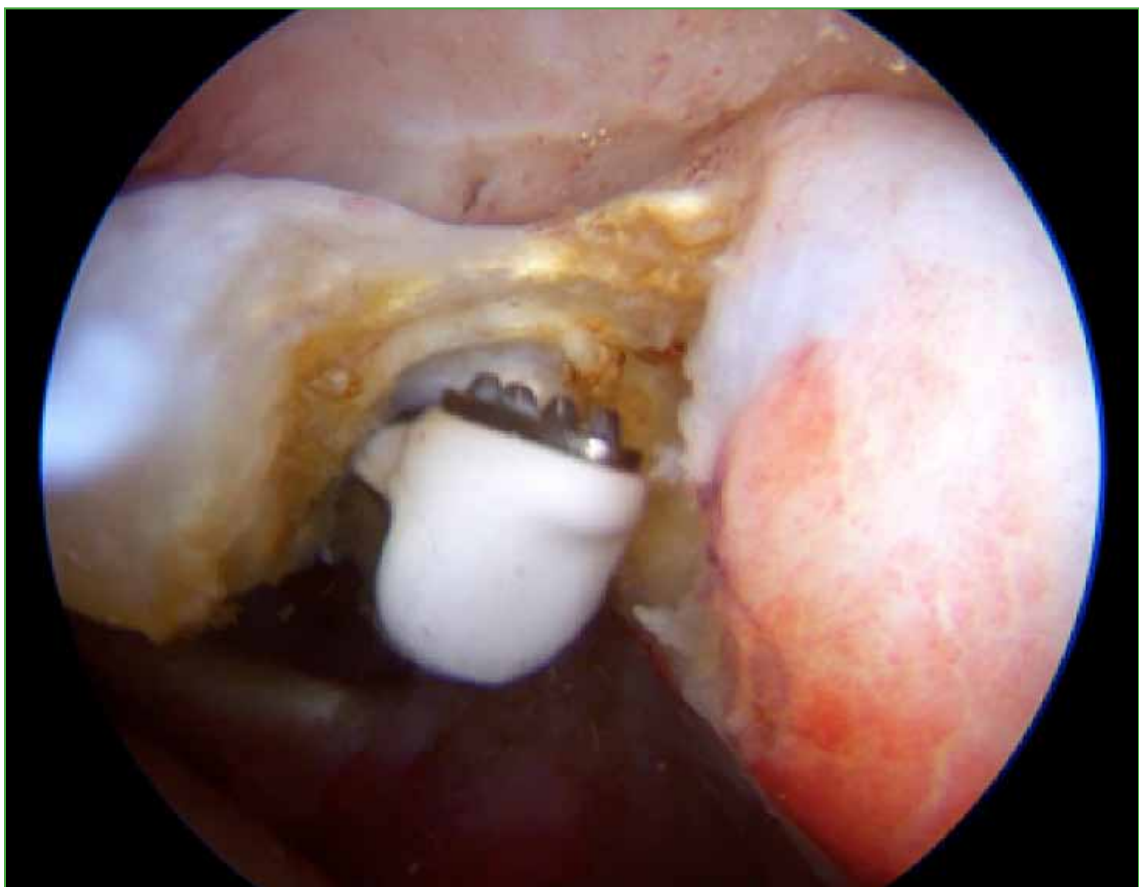
Interval slide is a technique described by Burkhart to increase the lateral excursion of a retracted rotator cuff and thus allow a tension-free repair.<sup>7</sup> The opening of the posterior interval consists of the separation between the supraspinatus and the infraspinatus to facilitate the reduction of the tendon to its footprint (Figure 3).



**Figure 3.** Complete retracted tear of the supraspinatus (SS) with posterior view. The glenoid (G), the infraspinatus (IS) and the exposure of the scapular spine (SSp) are shown after an interval slide is made between the supraspinatus and the infraspinatus. It can be seen how the supraspinatus is capable of reaching the humeral head (HH). Ultimately, margin convergence should be performed to close the space created between the infraspinatus and supraspinatus (double arrow).

The opening of the anterior interval consists of the separation between the supraspinatus and the subscapularis, as in the opening of the posterior interval, to be able to facilitate the reduction of the tendon to its footprint, although these actions have the risk of causing devascularization of the tendons which can hinder healing. Likewise, it is worth mentioning that the interval slides can produce maladjustments in the adaptations of the coupling of forces that have occurred over time. Therefore, it is necessary to ensure that the technique will actually allow a healing repair of the tendon, especially in its anterior portion. To favor biology and not injure the vascularization while reducing the possibilities of creating biomechanical alterations, Lo and Burkhart described the opening of the anterior interval in continuity, which consists of the section of the coracohumeral ligament from the base of the coracoid, so that, when repairing the subscapularis, repair of the supraspinatus is facilitated with less tension, avoiding the division of the junction between the subscapularis and the supraspinatus.<sup>7</sup> It is worth mentioning that, often, the three techniques must be combined, since the interval slide, on occasions, only allows reaching the bone if the footprint is medialized. In addition, the posterior interval opening must sometimes be carried out to the base of the scapular spine and, therefore, it is advisable to perform a posterior margin convergence afterwards. It is also important to point out that the posterior interval slide must be performed with care so as not to injure the supra-scapular nerve as it passes through the spinoglenoid notch.

The surgeon can opt for a tenotomy of the long head of the biceps as an addition to the techniques described above with the aim of improving pain (Figure 4).<sup>8</sup>

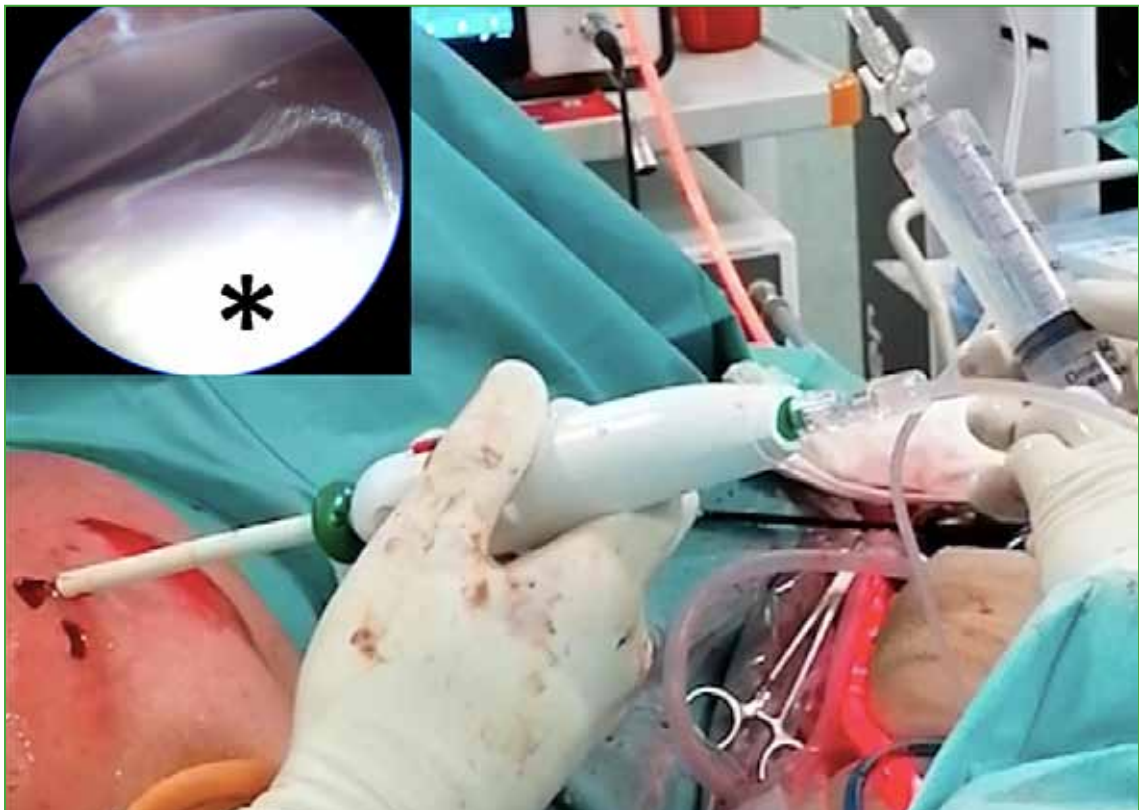


**Figure 4.** Intra-articular posterior view during a biceps tenotomy using a radiofrequency device.

## Additional measures to promote healing

### *Subacromial spacer*

The subacromial spacer is a biodegradable device that is placed between the acromion and the proximal epiphysis of the humerus (acromiohumeral joint) and allows the humeral head to descend, thus reducing friction during shoulder motion (Figure 5). This implies better pain control and an increase in the range of motion by avoiding a possible elevation of the humeral head.<sup>9</sup> This is a rescue technique in patients >65 years of age with a massive and irreparable rotator cuff tear without associated arthropathy, but with full passive range of motion and correct glenohumeral stability, when seeking to perform a previous alternative to a more invasive procedure due to the general conditions of the patient. It can also be applied to relieve subacromial pain caused by humeral head elevation until the cuff has healed or pain improvement has allowed a better balance of forces in the shoulder. Cases have also been described in which the subacromial spacer is used as a protection system associated with a tendon suture in order to reduce the rate of tear.<sup>10,11</sup>

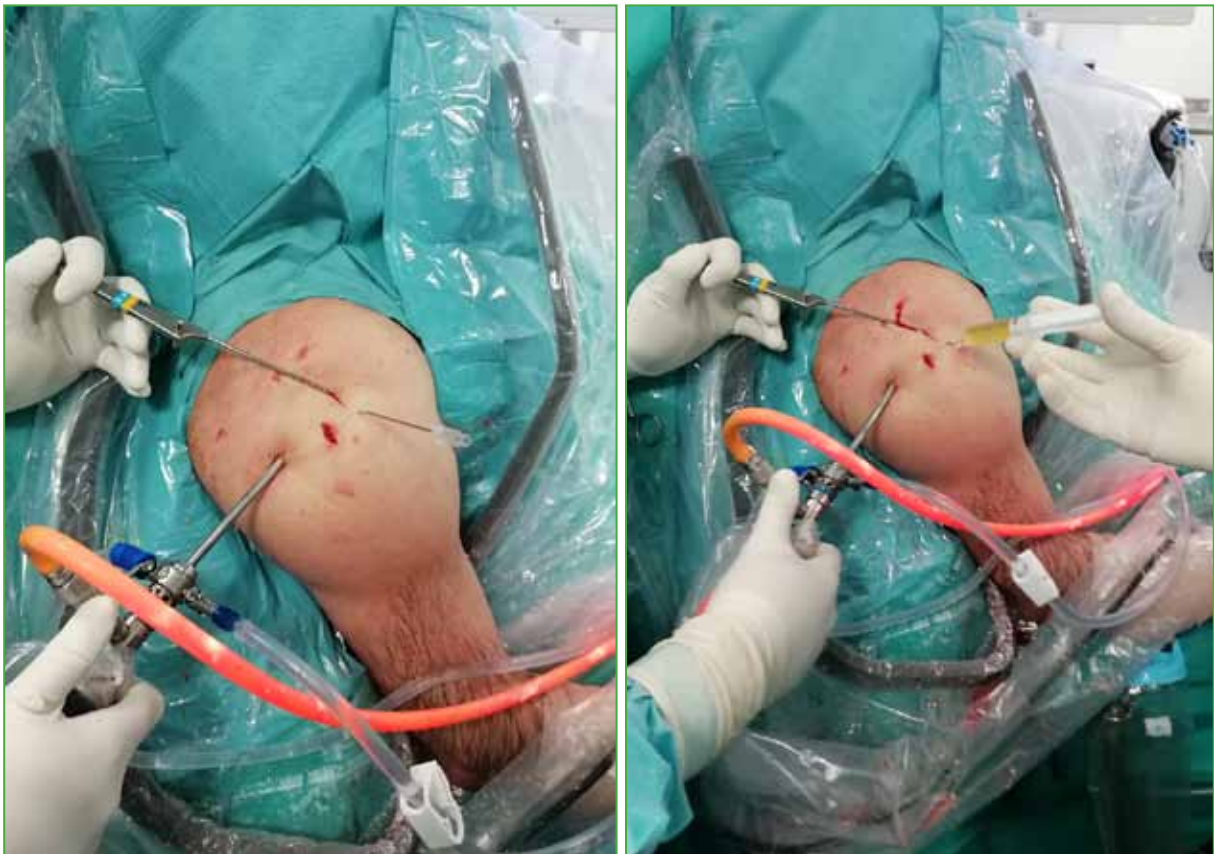


**Figure 5.** External view of the placement of a subacromial spacer on a patient's left shoulder in a beach chair position. The image in the box (\*) shows the interior aspect (subacromial view from the posterior portal) of the balloon once inflated with sterile saline.

### *Intratendinous and intraosseous platelet-rich plasma*

Due to the reparative potential of platelet-rich plasma, it can be used as an adjuvant treatment for some of the techniques described above. Our preference is the intraosseous infiltration as opposed to the intratendinous or tendon-bone interface, since, in most cases, the biological problem lies in the subchondral bone and the enthesis. The growth factor applied at the interface (tendon-bone junction) leaks, in most cases, to the subacromial or intra-articular space, thus escaping from the area where these proteins are most interesting. Even when the growth factor is applied in the subacromial or intra-articular space, we have seen cases of joint stiffness in the setting of

postoperative immobilization as a result of delicate rotator cuff repair. This may be due to the presence of platelet-rich plasma as opposed to platelet-poor plasma, since the former has a greater profibrotic potential. However, even applying platelet-poor plasma (with lower risk of postoperative stiffness), the fact that the factor escapes the place where it is of interest means that the interface application is not our choice. Instead, we opt for intraosseous infiltration just at the level of the repair (Figure 6).



**Figure 6.** Intraosseous application of growth factors on the left shoulder in a patient in a beach chair position. The placement of a number 14 Abbocath catheter can be seen and how it allows the intraosseous administration of the growth factor once it is connected to the syringe containing the drug.

This can be done in two ways. On the one hand, we have a motorized system composed of a trocar with an internal male needle that can be removed, connected to a motor (Arrow On Control Powered Bone Access System, Teleflex Medical Europe Ltd, Dublin, Ireland) covered with a sterile plastic sheath. The trocar is introduced and when the desired point is reached, the inner male needle or sleeve is removed and the growth factor is infiltrated. Should the position of the needle be changed, the sleeve or male needle is screwed on again, and it is reconnected to the motor. Another less expensive alternative is to use a 0.8-mm Kirschner wire that is inserted by motor laterally at the level of the cortical bone of the greater tuberosity, under direct vision, and advanced about 2 cm. The Kirschner wire is then left in place and a #14 Abbocath catheter is used to cannulate the needle. Once the Abbocath is inserted into the bone, the Kirschner wire is removed and the growth factor is infiltrated. It is important to point out that the subacromial space should not be filled with growth factor, but it is important that it remains at the level of the greater tuberosity.



### Micro perforations

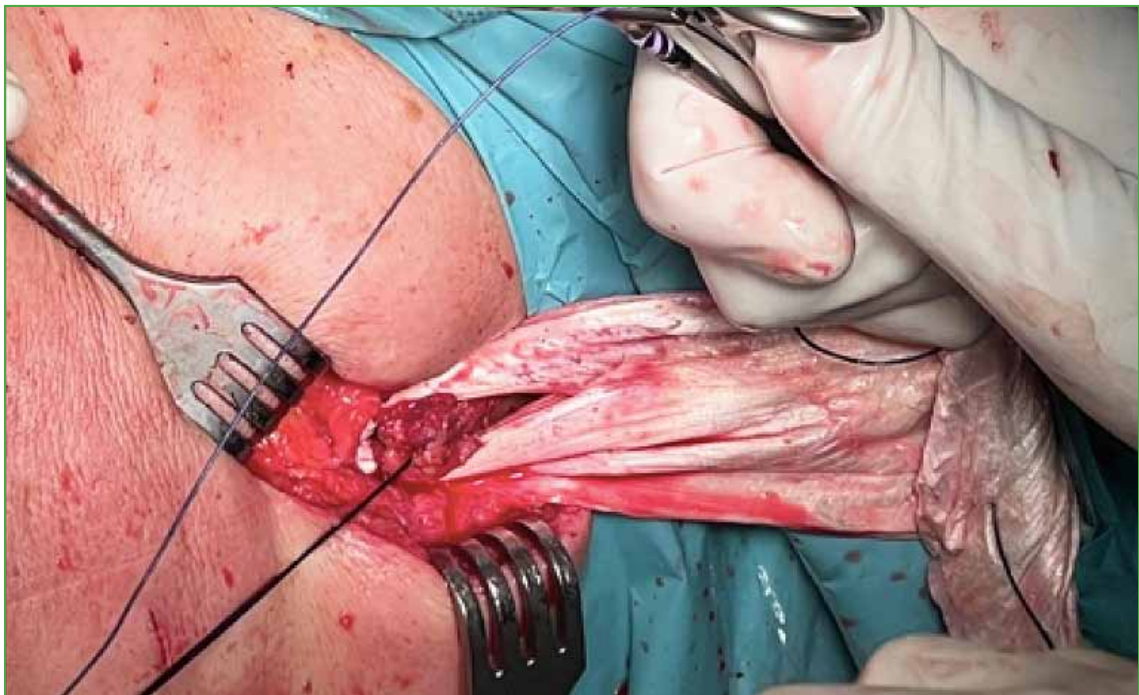
The creation of micro perforations in the humeral footprint before tendon repair improves the biological environment by providing a greater local flow of stem cells and other factors that favor tendon healing.<sup>12</sup> However, this technique would be discouraged when the humeral head is highly osteoporotic, because there is a risk of further weakening the bone and producing a failure of the tendon to bone anchorage.

### Postoperative Instructions - Immobilizer in Abduction

The abduction orthosis is a tool that can be used after a rotator cuff repair to reduce tension on the suture. In biomechanical and *in vitro* studies, the amount of stress borne by the rotator cuff has been shown to be influenced by the position of the shoulder. Therefore, we can reduce the stress supported in the repaired area by leaving the arm in abduction and thus reducing the rate of re-tears and promoting prompt healing.<sup>13,14</sup> The degrees of abduction can decrease as the weeks go by. Normally, it will start with an abduction of around 60° for about two weeks, decreasing by 10° per week thereafter. This is only of interest in those more retracted tears and with a more delicate repair.

### Rescue techniques: tendon transfer

Following the repair of massive rotator cuff tears, tendon re-tear rates range from 40% to 70%.<sup>15</sup> For this reason, we sometimes recommend performing a tendon transfer in addition to a borderline repair. Our tendon transfer of choice for irreparable tears of the posterosuperior cuff is the Elhassan transfer, which consists of transferring the lower trapezius to the greater tuberosity with Achilles tendon allograft augmentation. The addition of this transfer to a borderline repair is important in the setting of active external rotation deficiency or even preoperative pseudoparalysis. With this technique we achieve an improvement in both pain reduction and shoulder strength (Figure 7).<sup>16,17</sup>



**Figure 7.** Lower trapezius tendon transfer for the reconstruction of an irreparable rotator cuff tear. Posterior photograph showing the connection between the Achilles tendon allograft and the lower trapezius.

## CONCLUSIONS

There are different arthroscopic techniques that increase the chances of repairing ‘irreparable’ complex tears of the supraspinatus tendon. These include footprint medialization, margin convergence, interval slides, subacromial spacers, biological therapies (platelet-rich plasma), micro perforations, or spatial immobilizers in abduction. It must be taken into account that these tears have a high rate of re-tearing due to poor healing. The patient must know the real expectations to which he or she should aspire. However, these are some of the tricks that will increase the chances of success in the face of a complex repair. All this can enable clinical improvement and patient functionality, as well as prevent progression to glenohumeral osteoarthritis and thus the subsequent placement of an inverted arthroplasty.

Conflict of interest: The authors declare no conflicts of interest.

C. Sánchez-Losilla ORCID ID: <https://orcid.org/0000-0002-0444-8684>  
 A. Ferré-Aniorte ORCID ID: <https://orcid.org/0000-0003-0940-4557>  
 J. Ramírez-Haua ORCID ID: <https://orcid.org/0000-0001-8011-3248>

P. Álvarez-Díaz ORCID ID: <https://orcid.org/0000-0002-2230-4860>  
 R. Cugat ORCID ID: <https://orcid.org/0000-0003-4870-2944>  
 E. Alentorn-Geli ORCID ID: <https://orcid.org/0000-0002-8979-8404>

## REFERENCES

1. Patte D. Classification of rotator cuff lesions. *Clin Orthop Relat Res* 1990;(254):81-6. PMID: 2323151
2. Hamada K, Yamanaka K, Uchiyama Y, Mikasa T, Mikasa M. A radiographic classification of massive rotator cuff tear arthritis. *Clin Orthop Relat Res* 2011;469:2452-60. <https://doi.org/10.1007/s11999-011-1896-9>
3. Goutallier D, Postel J-M, Bernageau J, Lavau L, Voisin M-C. Fatty muscle degeneration in cuff ruptures. *Clin Orthop Relat Res* 1994;78-83. PMID: 8020238
4. Khair MM, Gulotta LV. Treatment of irreparable rotator cuff tears. *Curr Rev Musculoskelet Med* 2011;4(4):208-13. <https://doi.org/10.1007/s12178-011-9098-3>
5. Peláez DP, Ortega AE, Flores A, Barón MG. Espaciador subacromial para el tratamiento artroscópico del desgarramiento masivo del manguito rotador. *An Med (Mex)* 2017;62(1):69-73. Available at: <https://www.topdoctors.mx/pdf/public/1c5b943a650f1ebe1090052081d6fba/espaciador-subacromial-para-el-tratamiento-artroscopico-del-desgarro-masivo-del-manguito-rotador-presentacion-de-un-caso.pdf>
6. Burkhart SS, Esch JC, Jolson RS. The rotator crescent and rotator cable: an anatomic description of the shoulder’s “suspension bridge”. *Arthroscopy* 1993;9(6):611-6. [https://doi.org/10.1016/s0749-8063\(05\)80496-7](https://doi.org/10.1016/s0749-8063(05)80496-7). Erratum in: *Arthroscopy* 1994;10(2):239. [https://doi.org/10.1016/S0749-8063\(05\)80104-5](https://doi.org/10.1016/S0749-8063(05)80104-5)
7. Lo IK, Burkhart SS. The interval slide in continuity: a method of mobilizing the anterosuperior rotator cuff without disrupting the tear margins. *Arthroscopy* 2004;20(4):435-41. <https://doi.org/10.1016/j.arthro.2004.01.016>
8. Boileau P, Baqué F, Valerio L, Ahrens P, Chuinard C, Trojani C. Isolated arthroscopic biceps tenotomy or tenodesis improves symptoms in patients with massive irreparable rotator cuff tears. *J Bone Joint Surg Am* 2007;89(4):747-57. <https://doi.org/10.2106/JBJS.E.01097>
9. Savarese E, Romeo R. New solution for massive, irreparable rotator cuff tears: The subacromial “biodegradable spacer”. *Arthrosc Tech* 2012;1(1):e69-e74. <https://doi.org/10.1016/j.eats.2012.02.002>
10. Senekovic V, Poberaj B, Kovacic L, Mikek M, Adar E, Dekel A. Prospective clinical study of a novel biodegradable sub-acromial spacer in treatment of massive irreparable rotator cuff tears. *Eur J Orthop Surg Traumatol* 2013;23(3):311-6. <https://doi.org/10.1007/s00590-012-0981-4>
11. Szöllösy G, Rosso C, Fogerty S, Petkin K, Lafosse L. Subacromial spacer placement for protection of rotator cuff repair. *Arthrosc Tech* 2014; 3(5):e605-e609. <https://doi.org/10.1016/j.eats.2014.06.017>
12. Ruiz Ibán MA, Sanchez Alepuz E, Diaz Heredia J, Hachem AI, Ezagüi Bentolila L, Calvo A, et al. Footprint preparation with nanofractures in a supraspinatus repair cuts in half the retear rate at 1-year follow-up. A randomized controlled trial. *Knee Surg Sports Traumatol Arthrosc* 2021;29(7):2249-56. <https://doi.org/10.1007/s00167-020-06073-7> Erratum in: *Knee Surg Sports Traumatol Arthrosc* 2022;30(3):1122. <https://doi.org/10.1007/s00167-020-06118-x>

13. Jackson M, Sylvestre E, Bleau J, Allard P, Begon M. Estimating optimal shoulder immobilization postures following surgical repair of massive rotator cuff tears. *J Biomech* 2013;46(1):179-82. <https://doi.org/10.1016/j.jbiomech.2012.09.026>
14. Jerosch J, Castro WH. [Stress on the rotator cuff sutures in relation to joint position]. *Z Orthop Ihre Grenzgeb* 1993;131(4):317-22. <https://doi.org/10.1055/s-2008-1040032> [In German]
15. DeOrto JK, Cofield RH. Results of a second attempt at surgical repair of a failed initial rotator-cuff repair. *J Bone Joint Surg Am* 1984;66(4):563-7. PMID: 6707035
16. Elhassan BT, Alentorn-Geli E, Assenmacher AT, Wagner ER. Arthroscopic-assisted lower trapezius tendon transfer for massive irreparable posterior-superior rotator cuff tears: surgical technique. *Arthrosc Tech* 2016;5(5):e981-88. <https://doi.org/10.1016/j.eats.2016.04.025>
17. Elhassan BT, Sánchez-Sotelo J, Wagner ER. Outcome of arthroscopically assisted lower trapezius transfer to reconstruct massive irreparable posterior-superior rotator cuff tears. *J Shoulder Elbow Surg* 2020;29(10):2135-42. <https://doi.org/10.1016/j.jse.2020.02.018>