

Arthroscopic Decompression in Suprascapular Neuropathy. Case Report and Anatomical Review

Matías L. Cullari, Diego J. Gómez, Daniel Veloz Serrano, Daniel Moya

Orthopedics and Traumatology Service, Hospital Británico de Buenos Aires, Autonomous City of Buenos Aires, Argentina

ABSTRACT

Suprascapular neuropathy is a rare cause of shoulder pain and weakness and is therefore often misdiagnosed. As a consequence, misdiagnosis may lead to inappropriate conservative treatment or a failed surgical procedure. A case of a 55-year-old man suffering from suprascapular nerve entrapment syndrome is presented. The patient underwent shoulder arthroscopy, where the compression of the suprascapular nerve by the superior transverse scapular ligament was diagnosed. Arthroscopic release of the suprascapular nerve relieved pain, weakness, and atrophy of the supraspinatus and infraspinatus muscles.

Keywords: Suprascapular neuropathy; decompression; entrapment.

Level of Evidence: IV

Descompresión artroscópica para la neuropatía de nervio supraescapular. Reporte de un caso y revisión anatómica

RESUMEN

La neuropatía del nervio supraescapular es una causa poco común de dolor y debilidad en el hombro y, por lo tanto, a menudo, es mal diagnosticada. Como consecuencia, el diagnóstico erróneo puede llevar a indicar un tratamiento conservador inapropiado o un procedimiento quirúrgico fallido. Se presenta el caso de un hombre de 55 años con síndrome de atrapamiento del nervio supraescapular. El paciente fue sometido a una artroscopia de hombro y se le diagnosticó una compresión del nervio supraescapular por el ligamento transversal escapular superior. La liberación artroscópica del nervio supraescapular alivió el dolor, la debilidad y la atrofia de los músculos supraespinoso e infraespinoso.

Palabras clave: Neuropatía supraescapular; descompresión artroscópica; atrapamiento nervioso.

Nivel de Evidencia: IV

INTRODUCTION

Suprascapular neuropathy is a rare condition,¹ first described in 1959 by Thompson and Koppel.² The most common etiology is compression of the nerve in the suprascapular notch by the superior transverse scapular ligament or spinoglenoid compression by a ganglion cyst.³

Clinically, it may present as localized pain on the posterior and lateral sides of the shoulder, or as weakness, with little or no pain, and it may also cause no symptoms.^{1,4}

The diagnosis of neuropathy is based primarily on clinical history and physical examination.⁵ Conventional radiography is usually normal. Magnetic resonance imaging (MRI) can reveal acute changes related to denervation, such as edema and muscle hypotrophy, depending on the time of evolution of the compression.⁶ In the subacute stage, edema and the onset of hypotrophy can be observed, and in the chronic stage, hypotrophy and fatty infiltration as a result of denervation. Other useful studies include electromyography, which should show the denervation of both the supraspinatus and infraspinatus muscles,⁷ and MRI neurography, which allows the compression to be visualized and guides the specific treatment.

Received on June 13th, 2022. Accepted after evaluation on August 22nd, 2022 • Dr. MATÍAS L. CULLARI • matiascullari@gmail.com

 <https://orcid.org/0000-0002-6058-6686>

How to cite this article: Cullari ML, Gómez DJ, Veloz Serrano D, Moya D. Arthroscopic Decompression in Suprascapular Neuropathy. Case Report and Anatomical Review. *Rev Asoc Argent Ortop Traumatol* 2023;88(4):435-443. <https://doi.org/10.15417/issn.1852-7434.2023.88.4.1603>

The treatment of compressive neuropathy is based on nerve decompression, preferably arthroscopically, depending on the cause of compression.⁸

Anatomical review

The suprascapular nerve is a mixed nerve that emerges from the ventral ramus of the spinal nerve (C5) or from the upper trunk of the brachial plexus (C5-C6) and often receives an additional supply from C4.³ From its origin, the nerve runs, covered by the trapezius and omohyoid muscles, through the posterior triangle of the neck, following the course of the suprascapular artery, until it reaches the scapular notch, converted into an osteofibrous hole by the superior transverse scapular ligament. In certain cases, the notch is observed to be almost or completely closed by bone tissue and it turns, then, into a bone hole (Figure 1), these are enthesopathic changes in the lateral and medial insertions of the superior transverse scapular ligament.^{6,9}



Figure 1. Anterior view of the right scapula. The red arrow indicates the ossified transverse scapular ligament.

The nerve thus reaches the supraspinatus fossa where it provides two motor branches for the supraspinatus muscle, while providing a sensory branch for the coracoclavicular and coracohumeral ligaments, the acromioclavicular joint and the subacromial bursa.⁸ Following these branches, the nerve runs deep into the supraspinatus muscle, in the direction of the emergence of the spine of the scapula, to surround it and thus reach the infraspinatus fossa, ending in 2-4 motor branches that innervate the infraspinatus muscle.¹⁰ Due to its long and complex

anatomical path, the suprascapular nerve is highly susceptible to entrapment, which usually occurs at the level of the scapular notch.³

Depending on the morphology of the notch, the movements of the shoulder can cause the nerve to angle, pressing it against the superior scapular ligament or against the edge of the bone that limits the notch, causing nerve irritation.³ This possible mechanism was proposed by Rengachary et al., under the name of the 'hammock effect'.^{11,12}

The morphological variations of the superior transverse scapular ligament consist of the number of bands that make up the ligament (two, three or multiple in the proximal-distal direction) and that decrease the passage space of the suprascapular nerve at the level of the scapular notch, thus contributing to increasing the possibility of compression or entrapment.^{6,11}

CLINICAL CASE

A 55-year-old man who practiced field hockey and had no relevant pathology history. He had developed a dull pain in his shoulder and scapula three months prior to the consultation. The pain had permanently increased (7/10 according to the visual analog scale) and, after a few weeks, was associated with hypotrophy of the supraspinatus and infraspinatus muscles. This caused severe external rotation paresis (M3 according to the Daniels scale). It is important to mention that he did not have a limited range of motion, but rather pain and motor weakness. Initially, an MRI of the shoulder and scapular region without contrast medium was requested, which showed subacute changes in muscle denervation with an increase in signal in the STIR sequence related to changes in edema (Figure 2).

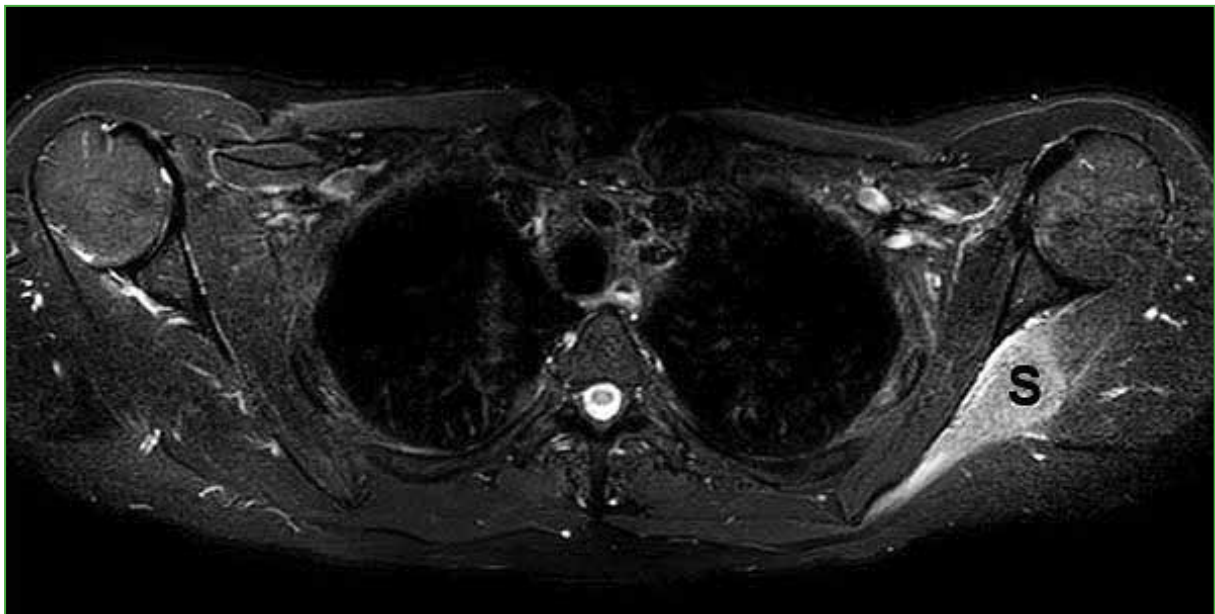

Figure 2. MRI of the left shoulder, axial section, STIR sequence. Edema is observed in relation to the supraspinatus muscle (S).

The rest of the rotator cuff muscles showed a normal signal. Electromyography showed involvement of the suprascapular nerve in isolation (Figure 3).

MRI neurography revealed that the suprascapular nerve branch was diffusely thickened reaching the supraspinatus notch. In this way, the diagnosis of suprascapular nerve entrapment was confirmed.

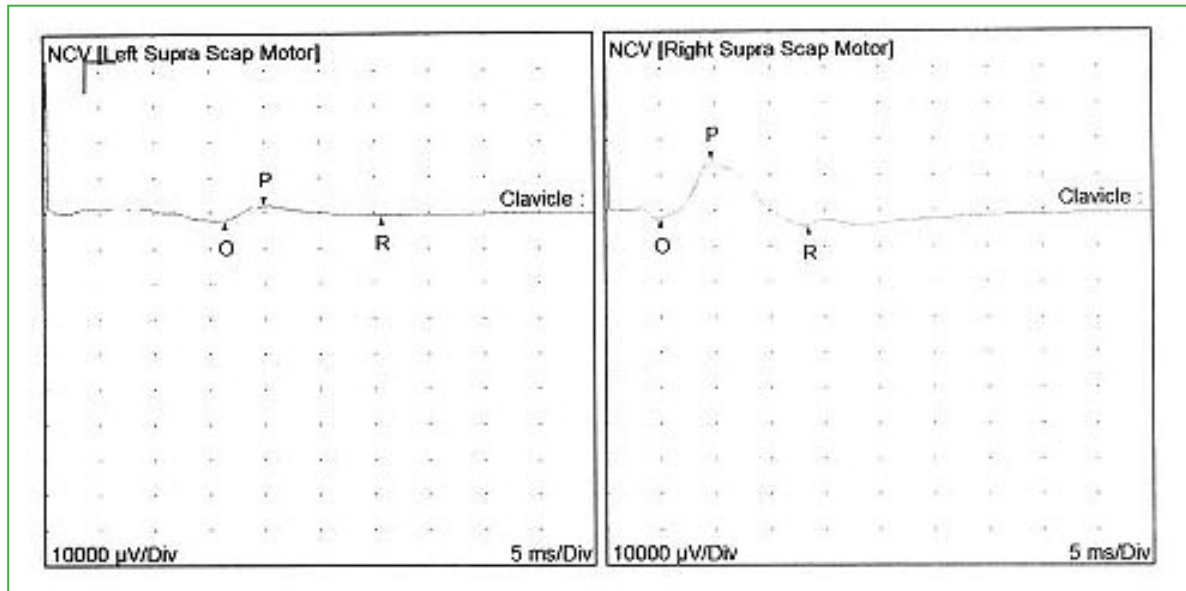


Figure 3. Electromyography of both suprascapular nerves. The reduction in the motor amplitude of the left suprascapular nerve compared to the contralateral one can be observed.

At first, the patient refused surgical treatment and underwent kinesiotherapy. After 12 months without improvement, he consulted again. A new MRI and neurography were indicated, and signs of subacute denervation with fatty infiltration and a decrease in the volume of the supraspinatus-infraspinatus muscle (hypotrophy) were detected in the T1-weighted sequence (**Figure 4**).

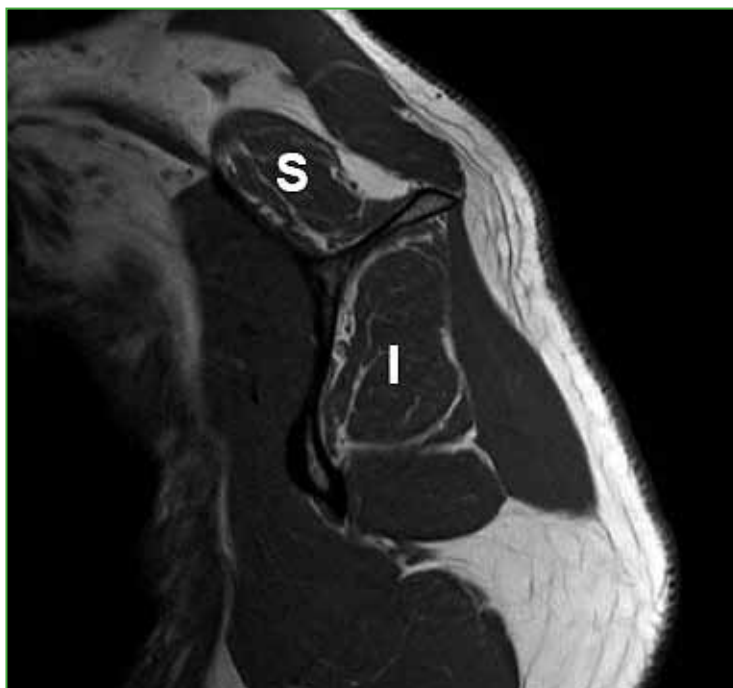

Figure 4. MRI of the left shoulder, sagittal view, T1-weighted sequence. Fatty infiltration of the supraspinatus (S) and infraspinatus (I) muscles can be observed.

Finally, arthroscopic decompression of the suprascapular nerve in the notch was performed.

The patient had no postoperative complications and was discharged within 24 hours. 14 days after surgery, kinesiology rehabilitation began. Scapular pain disappeared (1/10 according to the visual analog scale). After one month, a gradual recovery of muscle strength for external rotation was observed and, after three months, a partial recovery of muscle tropism was observed.

Surgical technique

Arthroscopic decompression was performed based on the original Lafosse technique.¹³ The patient was placed in a modified beach chair position, under general anesthesia and interscalene block. The initial visualization was carried out through a posterior portal and an anterolateral work portal. An extensive bursectomy was performed, identifying the anterior border of the supraspinatus, using it as a guide to move forward with the medial dissection, until the base of the coracoid was identified. The body and base of the coracoid were then cleaned. Then, the conoid ligament was identified medially and posteriorly to the trapezoid ligament. At the base of the conoid, a retroclavicular portal was created with the help of a spinal needle, called the 'suprascapular nerve portal'. This portal was created 7 cm from the acromial and retroclavicular region. A trocar was then used as a retractor and a second suprascapular nerve portal was created 1.5 cm lateral to the first. The transverse ligament shares an insertion at the base of the coracoid with the conoid ligament, approximately 3.5 cm from the acromioclavicular joint. Using the medial suprascapular nerve portal, the base of the conoid and the transverse ligament were cleaned with a blunt tip trocar, taking care not to injure the suprascapular artery that runs above the ligament and the nerve below it. In this step, nerve compression between the suprascapular notch and the superior transverse ligament was observed (Figure 5).

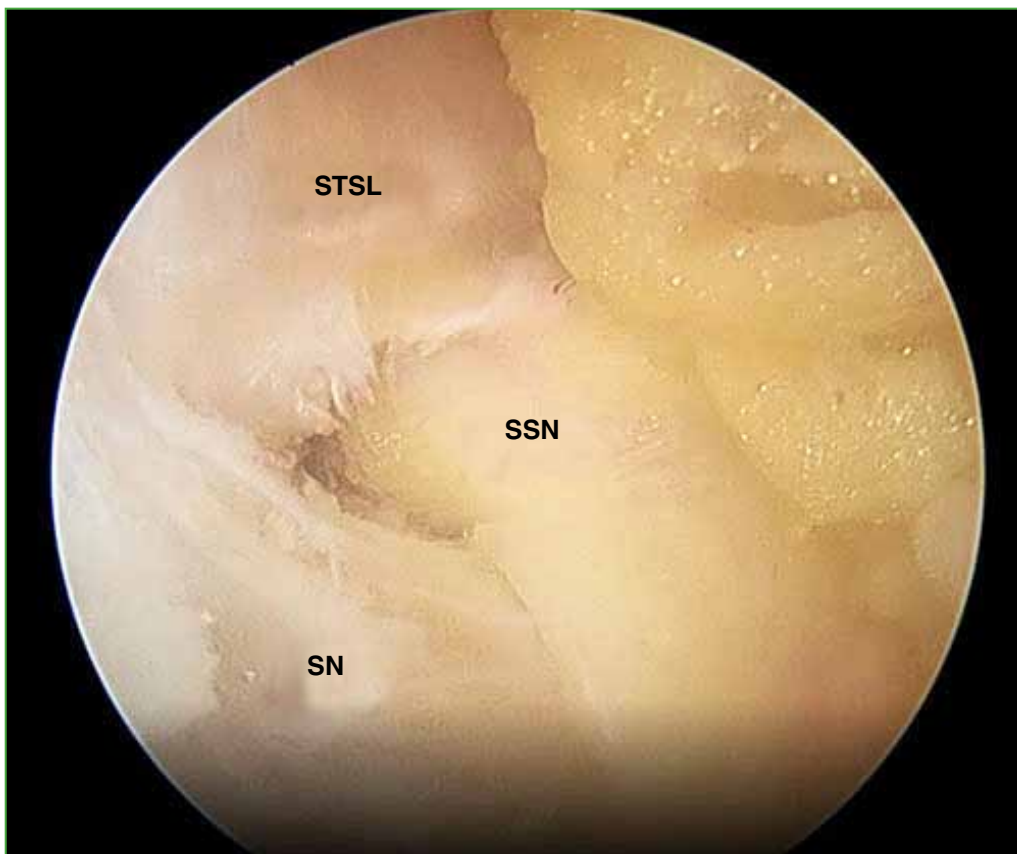


Figure 5. Arthroscopic image of the suprascapular nerve compressed by the superior transverse scapular ligament. SSN = suprascapular nerve; STSL = superior transverse scapular ligament. SN = suprascapular notch.

Using a blunt trocar through the medial suprascapular nerve portal, as a retractor of the trapezius muscle, the transverse ligament was cut with arthroscopic scissors through the lateral suprascapular nerve portal. Then, it was possible to visualize the released and uncompressed suprascapular nerve (Figure 6).

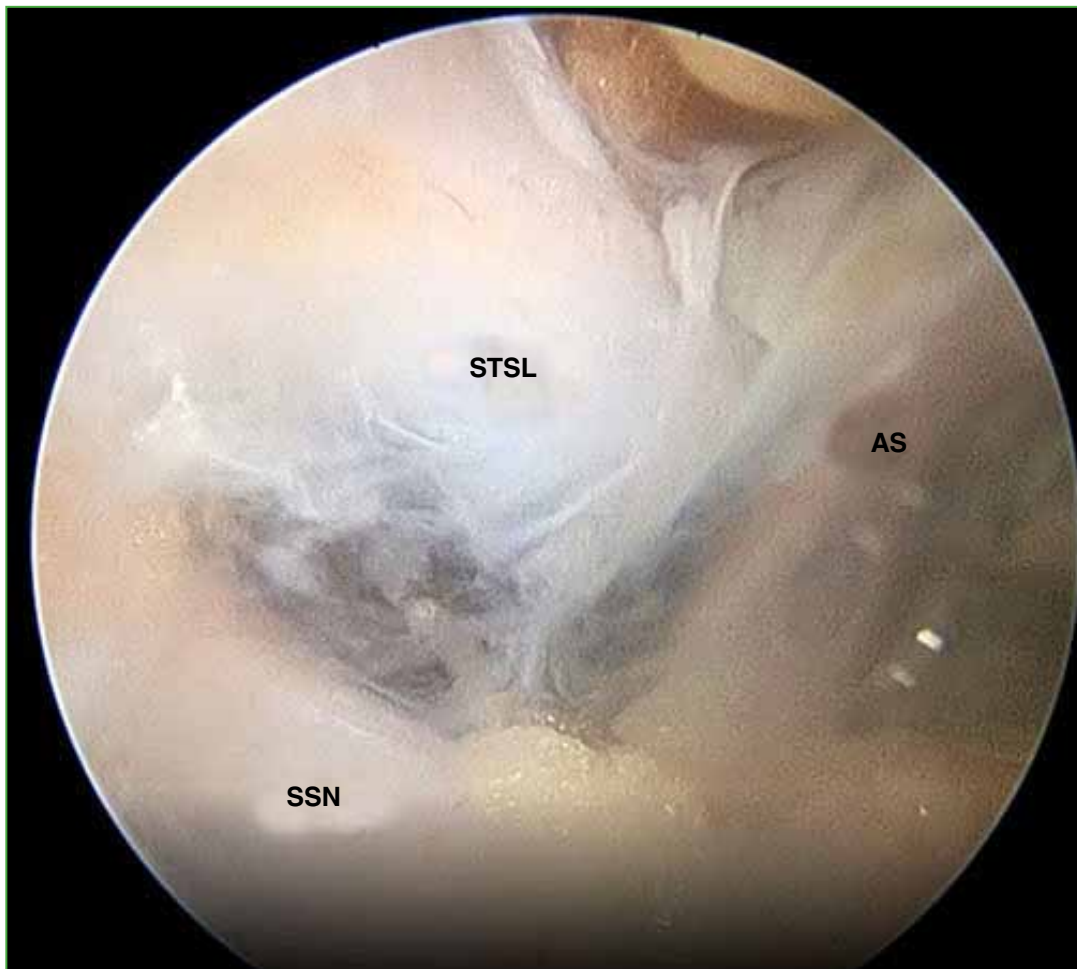

Figure 6. Arthroscopic imaging. Arthroscopic scissors were used to cut the transverse scapular ligament. SSN = suprascapular nerve; STSL = superior transverse scapular ligament. AS = arthroscopic scissors.

Adequate nerve decompression was confirmed by careful mobilization of the nerve outside the scapular notch (Figure 7).¹⁴ We believe it is important to perform this maneuver, especially because of presence of the anterior coracoscapular ligament identified by Avery et al.¹⁵

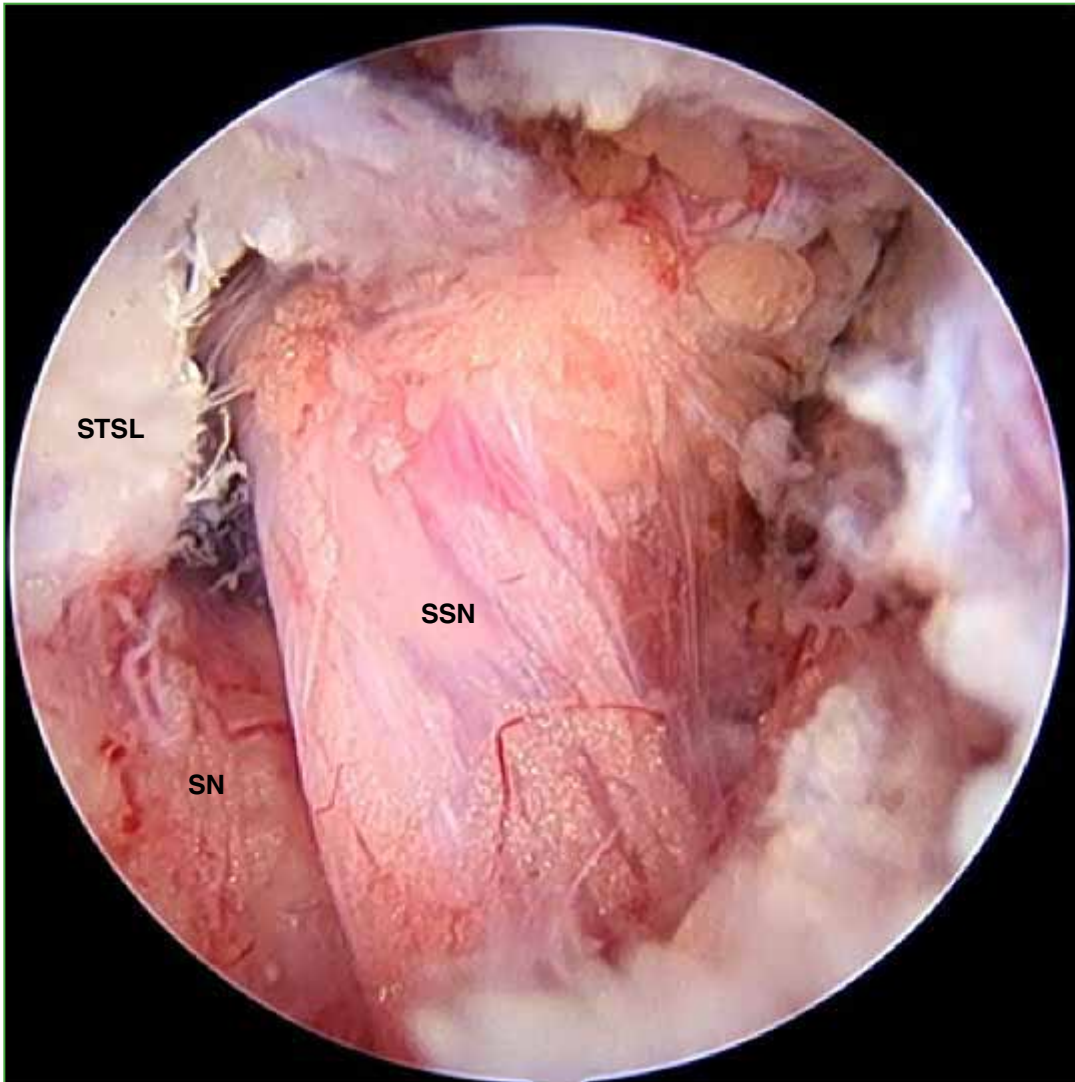


Figure 7. Arthroscopic imaging. The fully released suprascapular nerve can be visualized. SSN = suprascapular nerve; STSL = superior transverse scapular ligament; SN = suprascapular notch.

DISCUSSION

Suprascapular nerve entrapment in the suprascapular notch is a rare condition that is difficult to diagnose clinically and requires a high level of suspicion.^{16,17} Most cases are idiopathic, but it commonly affects athletes who perform overhead activities. The sequelae of scapular fracture and ossified suprascapular ligament are also factors that increase the likelihood of nerve entrapment. Although there are several open and arthroscopic approaches to decompress the suprascapular nerve, all depend on the location of the coracoclavicular ligaments that lead to the superior transverse scapular ligament. The study by Harris et al.¹⁸ provided insight into the importance of the coracoclavicular ligaments as a landmark to the superior transverse scapular ligament. These authors evaluated the variation of the coracoclavicular ligaments and found that, despite the variability of the shape, length and insertion area of the coracoclavicular ligaments, the conoid ligament and the supraspinatus muscle tendon shared, in all their studied cases, the same insertion site on the coracoid process. In addition, they found that the fibers of the conoid component blend with the fibers of the supraspinatus tendon.¹⁸ The potential space surrounding the

suprascapular nerve and coracoclavicular ligaments is a fatty connective plane, which makes arthroscopic visualization technically demanding. This step is usually the most time-consuming in surgery, prioritizing at all times the protection of the suprascapular artery to avoid bleeding.

CONCLUSION

Suprascapular neuropathy is a rare disease whose diagnosis is usually delayed. Maintaining a high index of suspicion is possibly the most important aspect of the treatment of this condition. Arthroscopic decompression offers a valid therapeutic alternative.

Conflict of interest: The authors declare no conflicts of interest.

D. J. Gómez ORCID ID: <https://orcid.org/0000-0003-0258-6802>
D. Veloz Serrano ORCID ID: <https://orcid.org/0000-0003-3350-2157>

D. Moya ORCID ID: <https://orcid.org/0000-0003-1889-7699>

REFERENCES

1. Bozzi F, Alabau-Rodriguez S, Barrera-Ochoa S, Ateschrang A, Schreiner AJ, Monllau JC, et al. Suprascapular neuropathy around the shoulder: a current concept review. *J Clin Med* 2020;9(8):2331. <https://doi.org/10.3390/jcm9082331>
2. Thompson WAL, Koppel HP. Peripheral entrapment neuropathies of the upper extremity. *N Engl J Med* 1959;260(25):1261-5. <https://doi.org/10.1056/NEJM195906182602503>
3. Fankhauser F, Schippinger G. Suprascapular nerve entrapment by a ganglion cyst: an alternative method of treatment. *Orthopedics* 2002;25(1):87-8. <https://doi.org/10.3928/0147-7447-20020101-24>
4. Gosk J, Urban M, Rutowski R. Entrapment of the suprascapular nerve: anatomy, etiology, diagnosis, treatment. *Ortop Traumatol Rehabil* 2007;9(1):68-74. PMID: 17514177
5. Padua L, Conti V, Pazzaglia C, Caliendo P. About neurophysiological evaluation in suprascapular nerve entrapment and methods of review. *Int Orthop* 2003;27(3):194. <https://doi.org/10.1007/s00264-003-0431-3>
6. Rizzello G, Longo UG, Trovato U, Fumo C, Khan WS, Maffulli N, et al. Bilateral suprascapular nerve entrapment by ganglion cyst associated with superior labral lesion. *Open Orthop J* 2013;7:129-32. <https://doi.org/10.2174/1874325001307010129>
7. Zehetgruber H, Noske H, Lang T, Wurnig C. Suprascapular nerve entrapment. A meta-analysis. *Int Orthop* 2002;26(6):339-43. <https://doi.org/10.1007/s00264-002-0392-y>
8. Cummins CA, Messer TM, Nuber GW. Suprascapular nerve entrapment. *J Bone Joint Surg Am* 2000;82(3):415-24. <https://doi.org/10.2106/00004623-200003000-00013>
9. Hrdlicka A. The scapula: Visual observations. *Am J Phys Anthropol* 1942;29:73-94. <https://doi.org/10.1002/ajpa.133029010>
10. Moriggl B, Jax P, Milz S, Büttner A, Benjamin M. Fibrocartilage at the entheses of the suprascapular (superior transverse scapular) ligament of man – a ligament spanning two regions of a single bone. *J Anat* 2001;199(Pt 5):539-45. <https://doi.org/10.1046/j.1469-7580.2001.19950539.x>
11. Warner JP, Krushell RJ, Masquelet A, Gerber C. Anatomy and relationships of the suprascapular nerve: Anatomical constraints to mobilization of the supraspinatus and infraspinatus muscles in the management of massive rotator-cuff tears. *J Bone Joint Surg Am* 1992;74(1):36-45. PMID: 1734012
12. Rengachary SS, Burr D, Lucas S, Hassanein KM, Mohn MO, Matzke H. Suprascapular nerve entrapment neuropathy: A clinical, anatomical and comparative study. Part 2: Anatomical study. *Neurosurgery* 1979;5(4):447-51. <https://doi.org/10.1227/00006123-197910000-00007>
13. Lafosse L, Tomasi A. Technique for endoscopic release of suprascapular nerve entrapment at the suprascapular notch. *Tech Shoulder Elbow* 2006;7:1-6. Available at: https://journals.lww.com/shoulderelbowsurgery/Abstract/2006/03000/Technique_for_Endoscopic_Release_of_Suprascapular.1.aspx

14. Lafosse L, Tomasi A, Corbett S, Baier G, Willems K, Gobezie R. Arthroscopic release of suprascapular nerve entrapment at the suprascapular notch: technique and preliminary results. *Arthroscopy* 2007;23(1):34-42. <https://doi.org/10.1016/j.arthro.2006.10.003>
15. Krishnan SG. Suprascapular nerve release: the anterior approach. Presented at the Nice Shoulder Course, France, 2010. Available at: <http://www.niceshoulder-course.com/program.html>
16. Hahn M, Müller A, Valderrabano V, Vavken P, Rosso C. Der Karpaltunnel der Schulter/the carpal tunnel of the shoulder: Die arthroskopische Dekompression des N. suprascapularis. *Sports Orthopaed Traumatol* 2014;30:215-9. <https://doi.org/10.1016/j.orthtr.2014.07.003>
17. Lafosse L, Piper K, Lanz U. Arthroscopic suprascapular nerve release: indications and technique. *J Shoulder Elbow Surg* 2011;20(2 Suppl):S9-S13. <https://doi.org/10.1016/j.jse.2010.12.003>
18. Harris RI, Vu DH, Sonnabend DH, Goldberg JA, Walsh WR. Anatomic variance of the coracoclavicular ligaments. *J Shoulder Elbow Surg* 2001;10(6):585-8. <https://doi.org/10.1067/mse.2001.118480>