

# Standardized Rotator Cuff Repair. Classification of Fundación Santa Fe de Bogotá

**Guido Fierro, Mercedes Salas, Andrés Jiménez, Jorge Rojas, Juan Carlos González**

*Shoulder and Elbow Section, Department of Orthopedics and Traumatology, Hospital Universitario Fundación Santa Fe de Bogotá, Bogotá, Colombia*

## ABSTRACT

Rotator cuff surgery has become more popular in recent years, transitioning from an open technique to arthroscopic surgery. Although multiple techniques for bone fixation have been described, the steps to perform this repair have not been standardized, leading to inconsistencies and heterogeneity in the outcomes. This article proposes a new classification of rotator cuff injuries that will help surgeons make decisions during arthroscopic rotator cuff repair surgery.

**Keywords:** Rotator cuff repair; arthroscopy; classification; surgery.

**Level of Evidence:** IV

## Reparación sistemática del manguito rotador: Clasificación de la Fundación Santa Fe de Bogotá

## RESUMEN

La cirugía de manguito rotador se ha popularizado en los últimos años y pasó de realizarse mediante una técnica abierta, en la mayoría de los casos, a la reparación artroscópica. Se han descrito múltiples técnicas para la fijación del hueso, pero no se han estandarizado el orden y los pasos para llevar a cabo esta reparación, lo que generó inconsistencias y heterogeneidad en los resultados de la reparación. En este artículo, se propone una nueva clasificación de las lesiones del manguito rotador que les permitirá a los cirujanos tomar decisiones durante la cirugía de reparación artroscópica del manguito rotador.

**Palabras clave:** Reparación del manguito rotador; artroscopia; clasificación; cirugía.

**Nivel de Evidencia:** IV


## INTRODUCTION

Rotator cuff surgery has grown in popularity in recent years, transitioning from an open procedure to arthroscopic treatment in the majority of patients.<sup>1</sup> Multiple techniques for bone fixation have been described,<sup>2-5</sup> but the order and steps for repair have not been standardized, leading to inconsistencies and heterogeneity in repair outcomes.

This article proposes a new classification of rotator cuff injuries that will allow surgeons to make decisions during arthroscopic rotator cuff repair surgery.

## CURRENT CLASSIFICATIONS

The current classifications of rotator cuff injury are based on its morphology, size, number of tendons affected, location of the tear, degree of atrophy, and degree of compromise in the insertion (partial/complete) of the tendon, and have been used as a reference to compare results between studies.<sup>6-13</sup> These classifications described do not guide the surgeon during the operation, they do not allow the repair to be standardized for the vast majority of patients, and they do not describe the degree of repair achieved at the end of the surgery, since, in many cases, total repair of the defect is not possible.

Received on June 3<sup>rd</sup>, 2022. Accepted after evaluation on June 26<sup>th</sup>, 2022 • Dr. MERCEDES SALAS • mercedeselenasalas@gmail.com  <https://orcid.org/0000-0002-0282-7904>

**How to cite this article:** Fierro G, Salas M, Jiménez A, Rojas J, González JC. Standardized Rotator Cuff Repair. Classification of Fundación Santa Fe de Bogotá. *Rev Asoc Argent Ortop Traumatol* 2023;88(4):457-463. <https://doi.org/10.15417/issn.1852-7434.2023.88.4.1595>

## Classification of Fundación Santa Fe de Bogotá (FSFB)

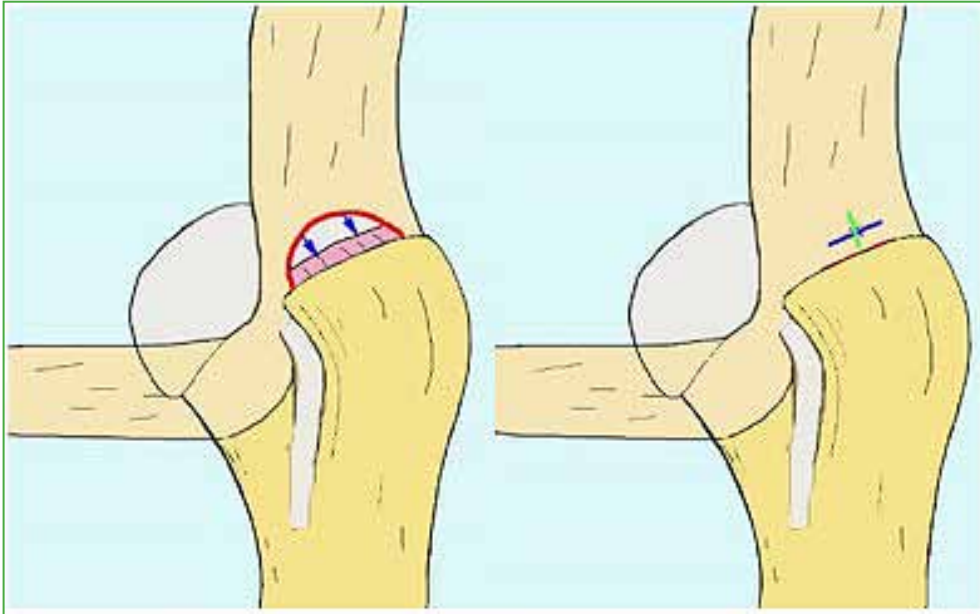
The FSFB classification seeks to standardize rotator cuff repair by providing the orthopedist with management guidance according to the type of injury and describing the degree of repair achieved (Table). It is based on two principles. The first is the repair of the limits of the rotator interval (proximal limit: most anterior portion of the supraspinatus tendon and distal limit: most superior portion of the subscapularis tendon). The second is to achieve an anatomic rotator cuff repair (tension-free tendon repair without folds plus converging sutures in the rotator cuff traction vector; from posteromedial to anterolateral).<sup>14,15</sup>

**Table.** Classification of Fundación Santa Fe de Bogotá for complete rotator cuff injuries

Type	Definition	Treatment
0	All the tendons are inserted into the bone	Do not repair/End of surgery
I	Tendon disinserted from bone Anteroposterior diameter greater than medial-lateral diameter Crescent-shaped lesion/No apex	Bring the tendon directly to the bone. Use anchors or tunnels  Does not require convergence sutures
II	Identifiable apex  Proximal rotator interval limit identifiable and inserted into the bone	Requires convergence sutures  Posteromedial to anterolateral or anteromedial to posterolateral convergence sutures to close the injury apex  Then repair as a type I lesion
III	Injury to the proximal limit of the rotator interval  The distal rotator interval limit is inserted into the bone	Fix the apex of the proximal limit to the most superior and lateral part of the subscapularis or to its insertion zone in the most anterior portion of the greater tuberosity  Then repair as a type II lesion  Then repair as a type I lesion
IV	Injury to the distal limit of the rotator interval	Fix the apex of the distal limit to the lesser tuberosity  Then repair as a type III lesion  Then repair as a type II lesion  Then repair as a type I lesion

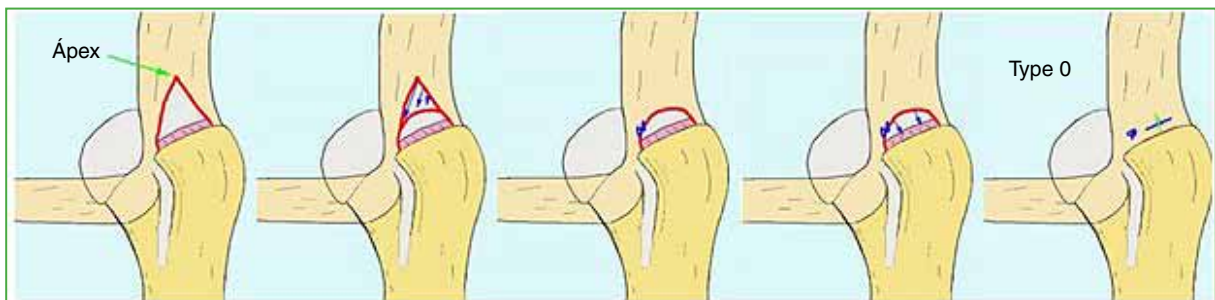The FSFB classification does not refer to the fixation method used (single or double row, anchors or bone tunnels) and is considered an intraoperative classification, which can be extrapolated to pre-surgical magnetic resonance imaging findings.

During surgery, it is possible to classify injuries into five types according to their characteristics and the arthroscopic repair that should be performed. Type 0 injuries refer to a rotator cuff without injury or with all tendons repaired, that is, the injury has already been repaired. Complete repairs with an anchor or repairs to the medial half of the footprint are considered type 0 injuries. An injury is classified as type I when the supraspinatus or infraspinatus tendon is not attached to the greater tuberosity, the anterior portion of the supraspinatus tendon is intact, and there is no apex in the area of tendon injury. In type I lesions, the anteroposterior diameter is usually larger than the mediolateral diameter and they have a crescent shape. The treatment of type I injuries involves bringing the tendon to the bone, and fixing it. It does not require additional convergences or releases (Figure 1).



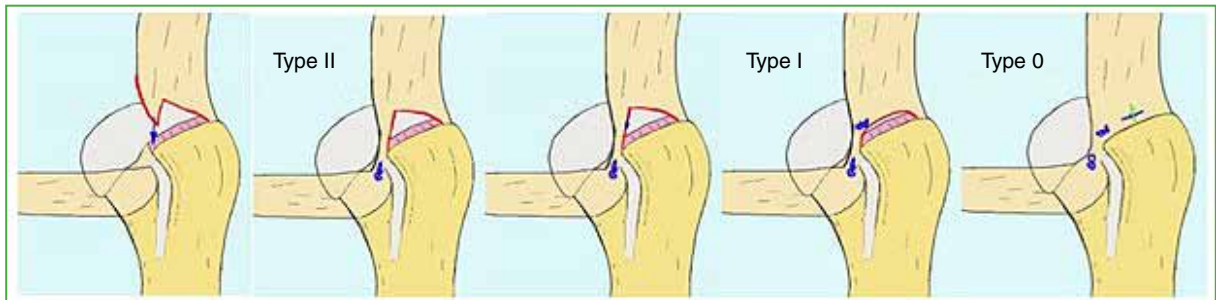
**Figure 1.** Type I injury: The supraspinatus or infraspinatus tendon is not attached to the greater tuberosity, the proximal limit is intact, and there is no apex in the area of tendon injury (crescent shape). Treatment: bring the tendon to the bone, and fix it.

Type II injuries have an apex in the tendon lesion and the limits of the rotator interval remain intact. Treatment of type II lesions is based on convergence from posteromedial to anterolateral, which converts the lesion to type I and allows it to be repaired as if it were type I (Figure 2).

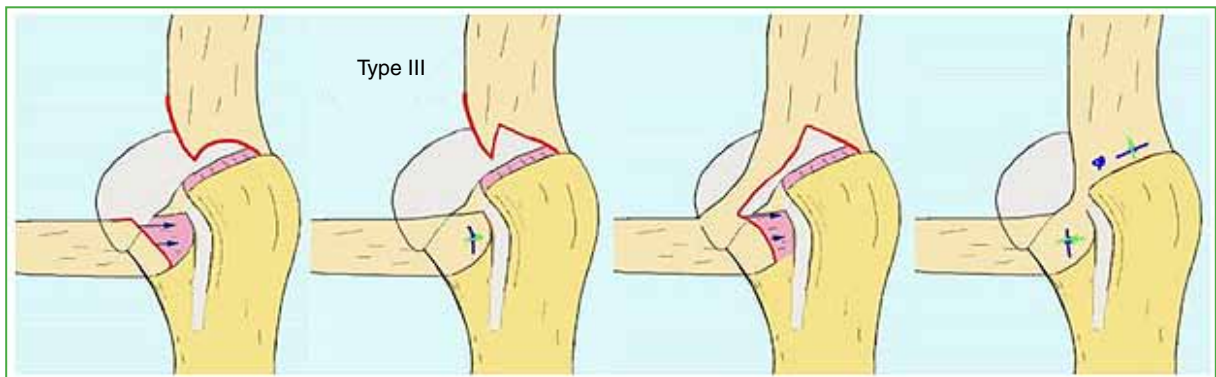


**Figure 2.** Type II injury: there is an apex in the tendon injury and the limits of the rotator interval are intact. Treatment: converge from posteromedial to anterolateral, making the lesion type I, then repair it as a type I lesion.

Type III injuries are those with a tear in the proximal limit of the rotator interval and with the distal limit attached to the bone. Treatment consists of fixation of the proximal limit, then, it is treated as a type II injury. If there is no apex in the lesion after fixation of the proximal limit, the injury is treated as type I (Figure 3). A type IV lesion is considered when there is a tear of the distal limit of the rotator interval and also isolated injuries to the subscapularis tendon. Management of type IV injuries consists of repairing the subscapularis tendon to the lesser tuberosity and then repairing it as a type III injury (Figure 4). There is not enough evidence to support the separation of the supraspinatus tendon from the subscapularis when they are attached.<sup>16</sup>



**Figure 3.** Type III injury: tear of the proximal limit of the rotator interval with the distal limit attached to the bone. Treatment: fixation of the proximal limit, then repair as a type II lesion. If there is no apex in the lesion after fixation of the proximal limit, it is repaired as a type I lesion.



**Figure 4.** Type IV injury: lesion of the distal limit of the rotator interval. Includes isolated injuries to the subscapularis tendon. Treatment: repair the subscapularis tendon to the lesser tuberosity, then repair as a type III injury.

## Surgical procedure

To systematically repair the rotator cuff, surgery can be divided into two components: “non-cuff” and “rotator cuff”.

### “Non-cuff” components of rotator cuff surgery

The “non-cuff” component refers to all the different procedures for bringing the tendon to the bone. Among the “non-cuff” components, we find the following procedures:

- Tenotomy or tenodesis of the long head of the biceps, includes all types of tenodesis described. The decision between performing a tenotomy or a tenodesis depends on the surgeon’s preference for each patient.<sup>17-19</sup>
  - Rotator interval release, which includes resection of the capsule and bursa in the anterior region of the rotator interval, allows better access and facilitates procedures in FSFB type III and IV lesions.<sup>20</sup>
  - Synovitis associated with rotator cuff injuries may increase the likelihood of postoperative stiffness; therefore, in patients with synovitis, we recommend partial or total synovectomy.<sup>21</sup>
  - The joint capsule plays a fundamental role in rotator cuff disease. Its release allows an excursion of the tendon to the footprint with less tension.<sup>22</sup> For type II lesions, we recommend superior, posterior, and inferior capsulotomy and, for type IV lesions, anterior capsule release.

- The subacromial, subdeltoid, and subscapular bursae have a protective and nutritious function, and their dissection is required to perform cuff repair surgery. As a result, we urge that the amount of bursa resected be as minimal as possible unless the patient has extensive bursitis, in which case the release should be substantial.<sup>23</sup>
- In order to allow the excursion of the retracted tendon to the footprint, it must be released at the spine of the scapula in type II injuries and at the lateral aspect of the coracoid, at the level of the coracohumeral ligament, in type IV injuries.
- The decision to modify the shape of the acromion and the amount of acromion resected is chosen based on the patient. There is no solid evidence to support the routine use of acromioplasty in patients with rotator cuff injuries undergoing repair surgery.<sup>24</sup>
- The objective of the debridement of the cuff's footprint on the humerus is to provide a bleeding bed in which to repair the tendon, as this promotes healing. In some published articles, a perforation of the footprint with more than 1 cm depth and less than 2 mm of diameter is suggested for each perforation to promote tendon healing. However, recent studies have not found a statistically significant difference from the above.<sup>25</sup>
- In patients with symptomatic acromioclavicular osteoarthritis, distal clavicle resection surgery is associated with rotator cuff repair.<sup>26</sup>

Once the “non-cuff” component of rotator cuff surgery has been completed, we proceed with the “rotator cuff” component, which consists of planning its repair and fixation to the bone, depending on the characteristics of the lesion.

## DISCUSSION

Recent anatomy studies have shown, in more detail, the form of insertion of the rotator cuff tendons, which has allowed us to understand the patterns of retraction and progression of the disease.<sup>27</sup> The distribution of the rotator cuff fibers is not exclusively medial to lateral, but rather fan-shaped with a posteromedial to anterolateral distribution. The repair must reproduce the anatomy of the cuff, so the direction of convergence must be from posteromedial to anterolateral before attaching the tendon to the bone.<sup>14,15</sup>

Numerous studies have been published on techniques for fixing the injured tendon to the bone, but there are no studies that standardize the repair sequence of the rotator cuff tendon, partly because of the extensive variation in tear morphologies and the surgeon's level of skill.<sup>2-5</sup> The current classifications on which the available studies are based do not guide the surgeon during the operation, resulting in very variable decisions made during the operation.<sup>6-13</sup> For this reason, the external validity of the studies is low, given that patients with the same type of injury are treated differently, with varying results from one center to another. Integrative classifications have been described, such as the one proposed by the *International Society of Arthroscopy, Knee Surgery and Orthopaedic Sports Medicine* (ISAKOS), in which the classifications described above are grouped in order to better describe the injury,<sup>13</sup> but it does not guide the surgeon during the operation or standardize the way in which rotator cuff repair should be performed.

The FSFB classification emerged in response to the need for a classification that would allow for a systematic and standardized surgical approach to rotator cuff injuries. This classification was designed to guide the surgeon during rotator cuff repair in a homogeneous and standardized way based on the morphology and involvement of the tendons in rotator cuff injuries.

## CONCLUSION

The FSFB classification, which is based on the morphology of the injury and tendon involvement, aims to provide the surgeon with a repair process that is simple and standardized, and thus guarantees external validity, allowing the results of the medical literature to be homogenized.

---

Conflict of interest: The authors declare no conflicts of interest.

## REFERENCES

1. Ensor KL, Kwon YW, DiBeneditto MR, Zuckerman JD, Rokito AS. The rising incidence of rotator cuff repairs. *J Shoulder Elbow Surg* 2013;22(12):1628-32. <https://doi.org/10.1016/j.jse.2013.01.006>
2. Burkhart SS, Lo IKY. Arthroscopic rotator cuff repair. *J Am Acad Orthop Surg* 2006;14(6):333-46. <https://doi.org/10.5435/00124635-200606000-00003>
3. Cole BJ, ElAttrache NS, Anbari A. Arthroscopic rotator cuff repairs: An anatomic and biomechanical rationale for different suture-anchor repair configurations. *Arthroscopy* 2007;23(6):662-9. <https://doi.org/10.1016/j.arthro.2007.02.018>
4. Garrigues GE, Lazarus MD. Arthroscopic bone tunnel augmentation for rotator cuff repair. *Orthopedics* 2012;35(5):392-7. <https://doi.org/10.3928/01477447-20120426-04>
5. Chillemi C, Mantovani M. Arthroscopic trans-osseous rotator cuff repair. *Muscles Ligaments Tendons J* 2017;7(1):19-25. <https://doi.org/10.11138/mltj/2017.7.1.019>
6. Lädermann A, Burkhart SS, Hoffmeyer P, Neyton L, Collin P, Yates E, et al. Classification of full-thickness rotator cuff lesions: A review. *EFORT Open Rev* 2016;1(12):420-30. <https://doi.org/10.1302/2058-5241.1.160005>
7. Patte D. Classification of rotator cuff lesions. *Clin Orthop Relat Res* 1990;(254):81-6. PMID: 2323151
8. Somerson JS, Hsu JE, Gorbaty JD, Gee AO. Classifications in brief: Goutallier classification of fatty infiltration of the rotator cuff musculature. *Clin Orthop Relat Res* 2016;474(5):1328-32. <https://doi.org/10.1007/s11999-015-4630-1>
9. Brolin TJ, Updegrove GF, Horneff JG. Classifications in brief: Hamada classification of massive rotator cuff tears. *Clin Orthop Relat Res* 2017;475(11):2819-23. <https://doi.org/10.1007/s11999-017-5340-7>
10. Malavolta EA, Assunção JH, de Araujo AO, Seito CA, Gracitelli MEC, Bordalo-Rodrigues M, et al. Full-thickness supraspinatus tendon tears: correlation of findings by arthroscopy and magnetic resonance imaging. *Int Orthop* 2015;39(2):227-32. <https://doi.org/10.1007/s00264-014-2490-z>
11. Lafosse L, Jost B, Reiland Y, Audebert S, Toussaint B, Gobezie R. Structural integrity and clinical outcomes after arthroscopic repair of isolated subscapularis tears. *J Bone Joint Surg Am* 2007;89(6):1184-93. <https://doi.org/10.2106/JBJS.F.00007>
12. Gumina S, Borroni M. Classifications of the rotator cuff tears. En: Gumina S. *Rotator cuff tear: pathogenesis, evaluation and treatment*. Springer Cham; 2016, pp. 123-31.
13. Calvo E, Guardado CR, Morcillo D, Arce G. Diagnosis and classification of rotator cuff tears. En: Imhoff AB, Savoie FH (eds.). *Rotator cuff across the life span. ISAKOS Consensus Book*. Heidelberg: Springer Berlin; 2019, pp. 3-10.
14. Nimura A, Kato A, Yamaguchi K, Mochizuki T, Okawa A, Sugaya H, et al. The superior capsule of the shoulder joint complements the insertion of the rotator cuff. *J Shoulder Elbow Surg* 2012;21(7):867-72. <https://doi.org/10.1016/j.jse.2011.04.034>
15. Cha SW, Lee CK, Sugaya H, Kim T, Lee SC. Retraction pattern of delaminated rotator cuff tears: Dual-layer rotator cuff repair. *J Orthop Surg Res* 2016;11(1):1-10. <https://doi.org/10.1186/s13018-016-0407-9>
16. Kim SJ, Jung M, Lee JH, Kim C, Chun YM. Arthroscopic repair of anterosuperior rotator cuff tears: In continuity technique vs. disruption of subscapularis supraspinatus tear margin comparison of clinical outcomes and structural integrity between the two techniques. *J Bone Joint Surg Am* 2014;96(24):2056-61. <https://doi.org/10.2106/JBJS.N.00293>
17. Zalneraitis BH, Milam BP, Turner EK, Gasbarro G, Galvin JW. Biceps squeeze tenotomy: Technique to improve efficiency of arthroscopic biceps tenotomy. *Arthrosc Tech* 2020;9(11):e1851-3. <https://doi.org/10.1016/j.eats.2020.08.009>
18. Belk JW, Kraeutler MJ, Houck DA, Chrisman AN, Scillia AJ, McCarty EC. Biceps tenodesis versus tenotomy: a systematic review and meta-analysis of level I randomized controlled trials. *J Shoulder Elbow Surg* 2021;30(5):951-60. <https://doi.org/10.1016/j.jse.2020.11.012>
19. Haupt ET, O'Keefe K, Farmer K. Arthroscopic all-inside biceps tenodesis: Technique and outcomes. *Arthrosc Tech* 2019;8(12):e1485-9. <https://doi.org/10.1016/j.eats.2019.07.034>

20. Tauro JC. Arthroscopic rotator cuff repair with interval release for contracted rotator cuff tears. En: Abrams J, Bell LH (eds.). *Arthroscopy rotator cuff surgery*. New York: Springer; 2008, pp: 208-17.
21. Tan Z, Hendy BA, Zmistowski B, Camp RS, Getz CL, Abboud JA, et al. Glenohumeral synovitis score predicts early shoulder stiffness following arthroscopic rotator cuff repair. *J Orthop* 2020;22:17-21. <https://doi.org/10.1016/j.jor.2020.03.050>
22. Giuseffi S, Field LD, Giel TV, Brislin BT, Savoie FH. Arthroscopic rotator cuff repair with concomitant capsular release. *Arthrosc Tech* 2016;5(4):e833-7. <https://doi.org/10.1016/j.eats.2016.04.002>
23. Nam JH, Park S, Lee HR, Kim SH. Outcomes after limited or extensive bursectomy during rotator cuff repair: Randomized controlled trial. *Arthroscopy* 2018;34(12):3167-74. <https://doi.org/10.1016/j.arthro.2018.06.056>
24. Sun Z, Fu W, Tang X, Chen G, Li J. Systematic review and meta-analysis on acromioplasty in arthroscopic repair of full-thickness rotator cuff tears. *Acta Orthop Belg* 2018;84:54-61. PMID: 30457500
25. Toro F, Pinochet F, Ruiz F, Moraga C, Pozo R, Oliva JP, et al. Functional and radiologic results of the crimson duvet procedure in rotator cuff treatment: a randomized controlled clinical trial. *J Shoulder Elbow Surg* 2022;31(6):1200-7. <https://doi.org/10.1016/j.jse.2021.12.004>
26. Gallinet D, Barth J, Labattut L, Collin P, Metais P, Bonneville N, et al. Benefits of distal clavicle resection during rotator cuff repair: Prospective randomized single-blind study. *Orthop Traumatol Surg Res* 2020;106(8):S207-11. <https://doi.org/10.1016/j.otsr.2020.08.006>
27. Sahu D, Phadnis A. Revisiting the rotator cuff footprint. *J Clin Orthop Trauma* 2021;21:101514. <https://doi.org/10.1016/j.jcot.2021.101514>