

Use of 3D Cups in Severe Acetabular Defects

Ignacio Troncoso, Carlos Sabatella, Gonzalo J. Blanco O'dena

Hip Unit, Hospital Naval "Cirujano Mayor Dr. Pedro Mallo", Autonomous City of Buenos Aires, Argentina

ABSTRACT

Introduction: Given the increase in hip arthroplasties in the last century, serious acetabular defects are increasingly frequent events. Their treatment represents a real challenge, due to the bone deficit and poor bone quality that these patients usually present. **Materials and Methods:** Six patients treated between 2016 and 2021 are presented. Five cases of pelvic discontinuity due to failed revisions, classified as Paprosky type IIIB, and one transverse fracture of the acetabulum, a possible treatment option in cases of osteoporotic patients. **Results:** The patients treated with this multidisciplinary technique were followed up for an average of 20 months, and none of them presented postoperative complications. The results evaluated by analogous scales are promising and invite us to establish this procedure as the gold standard. **Conclusions:** Strict evaluation is necessary for acetabular defects. The inclusion of medical IT makes it possible to study the need to use bank grafting and to manufacture custom-made multiporous trabecular titanium/tantalum implants, which is ideal for achieving osseointegration, added to the possibility of planning the direction and length of the screws to the remaining bone, according to its quality. The cementation of a dual mobility cup inside the customized implant reduces the risk of dislocation and overload of the latter, by eliminating metal-metal friction.

Keywords: Pelvic discontinuity; 3D cup; dual mobility; reconstructive acetabular revision; severe acetabular defects

Level of Evidence: IIIB

Utilización de cotilos 3D en defectos acetabulares graves

RESUMEN

Introducción: Ante el aumento de las artroplastias de cadera en el último siglo, los defectos acetabulares graves son eventos cada vez más frecuentes. Su tratamiento representa un verdadero desafío, debido al déficit y pobre calidad ósea, con la que cuentan habitualmente estos pacientes. **Materiales y Métodos:** Se presentan 6 pacientes tratados entre 2016 y 2021. Cinco casos de disrupción pélvica por revisiones fallidas, clasificadas como tipo IIIB de Paprosky y una fractura transversal de acetábulo, posible opción de tratamiento en casos de pacientes osteoporóticos. **Resultados:** Los pacientes tratados con esta técnica multidisciplinaria fueron seguidos durante un promedio de 20 meses, ninguno presentó complicaciones postoperatorias. Los resultados valorados por escalas análogas son prometedores e invitan a establecer éste procedimiento como el estándar de oro. **Conclusiones:** La evaluación estricta es necesaria en los defectos acetabulares. La inclusión de ingeniería informática médica permite estudiar la necesidad de utilización de injerto de banco, fabricar implantes a medida de titanio/tantalio trabecular multiporoso lo que es ideal para lograr la osteointegración, sumado a la posibilidad de planificar dirección y longitud de tornillos al hueso remanente, según su calidad. La cementación de un cotilo de doble movilidad, dentro del implante customizado, disminuye el riesgo de luxación y de sobrecarga de este último, al eliminar la fricción metal-metal.

Palabras clave: Disrupción pélvica; cotilo 3D; doble movilidad; revisión acetabular reconstructiva; defectos acetabulares graves.

Nivel de Evidencia: IIIB

INTRODUCTION

Hip arthroplasty is one of the most successful surgeries of the 20th century, as it relieves pain, corrects deformities, and improves joint function.

Acetabular component failure is a frequent and complex scenario faced by the hip surgeon. Most failures occur due to aseptic loosening, but other possible causes include infection, recurrent dislocation, periprosthetic fracture, component incompatibility, wear, and osteolysis.

Received on April 14th, 2022. Accepted after evaluation on August 19th, 2022 • Dr. IGNACIO TRONCOSO • itroncosopesoa@gmail.com  <https://orcid.org/0000-0002-7879-0992>

How to cite this article: Troncoso I, Sabatella C, Blanco O'dena GJ. Use of 3D Cups in Severe Acetabular Defects. *Rev Asoc Argent Ortop Traumatol* 2022;87(5):676-684. <https://doi.org/10.15417/issn.1852-7434.2022.87.5.1567>

The revision has become a challenge, due to the loss of bone tissue and its quality. The difficulty in reconstruction is related to identifying the location and characteristics of residual viable bone. Once the pattern of the bone defect has been identified by radiographic analysis, its staging facilitates the appropriate choice of treatment.

Paprosky classified acetabular defects into three types. We will focus on type III, which is subclassified into IIIA, and is characterized by superior migration of the femoral component of more than 3 cm, moderate lysis of the teardrop, and intact Kohler's line; unlike type IIIB, which typically presents a medial migration that causes a discontinuity of Kohler's line, associated with severe lysis of the teardrop and the ischium.¹ In our series, we include the description of an acetabulum fracture in an elderly man.

Some of the most widely used techniques to solve these serious bone defects are the use of block structural allograft, antiprotrusio cage, and custom implants. With regard to antiprotrusio cages, mechanical failures have been published with rates of up to 15% in a medium-term follow-up, in addition to sciatic nerve neuropraxia, loss of implant fixation, and fracture of the fixation wing. Acetabular reconstruction with structural allograft achieves variable outcomes, with rates of mechanical failure of up to 70% of the component and migration.²

The high failure rates generated the need to develop new implants with enhanced biological and mechanical properties.

Faced with this problem, a technique was developed which is capable of analyzing the defect in detail and reconstructing the acetabulum using a custom-made implant, with trabecular titanium, which fits into the remaining anatomy, in order to achieve implant stability and restore the functionality of the joint.³

The objective of this study was to carry out a literature search on the characteristics of acetabular revision with custom 3D components, associated with the cementation of a dual mobility cup, and its functional and radiographic outcomes, regarding the cases treated in our hospital, for Paprosky type IIIB defects and acetabulum fractures.

MATERIALS AND METHODS

Between 2016 and 2021, five cases of pelvic discontinuity due to failed revisions, classified as Paprosky type IIIB, and one transverse fracture of the acetabulum were treated.

We included patients with failed acetabular reconstructions and bone defects of such magnitude that the use of classical methods, such as grafts or antiprotrusio cages, was not possible. The average age of the patients was 75.3 years and the average follow-up is 20 months (continues today).

In the preoperative interviews, the Harris Hip Score and the Merle d'Aubigné and Postel evaluation scale were applied.^{3,4}

According to the protocol, panoramic anteroposterior radiographs of both hips, as well as inlet and outlet, alar oblique, and obturator oblique pelvic radiographs were taken (Figure 1A, C, E, G, H, I, K).

Subsequently, a computed tomography with 1-2 mm slices of the entire pelvis was performed. The images were analyzed with a program to represent it three-dimensionally.

The next step was to calculate the acetabular radial bone loss: it was performed using a computerized method that uses computed tomography, processing the image and generating a 3D anatomical reconstruction.⁵ This reconstruction allows studying the density and quality of the remaining bone tissue, thus determining the bone support of the implant to be created. In addition, the direction and length of the fixation screws to be used in the ischium, ilium and pubis sectors were programmed, taking into account the quality of the bone and its possible fixation.

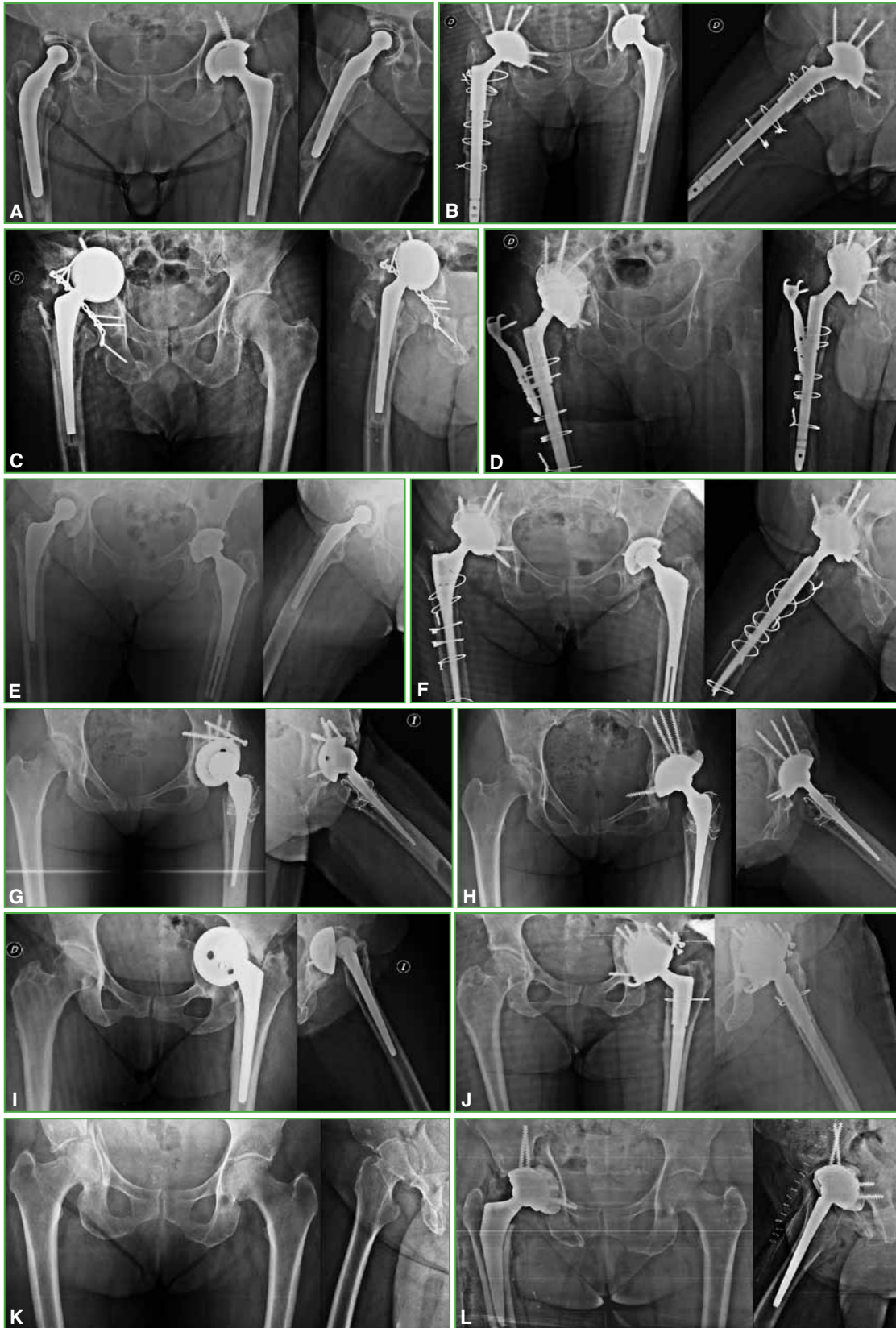

Figure 1. Preoperative anteroposterior and lateral hip radiographs of the treated cases. **A and B.** Case 1. **C and D.** Case 2. **E and F.** Case 3. **G and H.** Case 4. **I and J.** Case 5. **K and L.** Case 7. The description of each patient is detailed in [Table 1](#).

Table. Description of the six cases treated with 3D implants and dual mobility cups.

Patient/sex/age	Revision cause	Paprosky classification	Number of revision	Stem revision	Use of graft	Preoperative HHS	Preoperative Merle d'Aubigné and Postel score	Complications to date	Postoperative HHS	Postoperative Merle d'Aubigné and Postel score
1/F/45	Aseptic loosening	IIIB	1	Yes	Yes	39	7	X	87	15
2/F/76	Septic loosening	IIIB	3	Yes	Yes	29	4	X	80	13
3/F/84	Aseptic loosening	IIIB	1	Yes	Yes	23	3	X	91	17
4/M/92	Septic loosening	IIIB	3	Yes	Yes	22	4	X	78	12
5/M/82	Aseptic loosening	IIIB	1	Yes	Yes	21	3	X	83	14
6/F/73	Acetabular fracture	X	X	X	Yes	X	X	X	86	15

M = male, F = female, HHS = *Harris Hip Score*.

It was an interdisciplinary work, during which the surgeon carried out a constant exchange with the computer engineers, focused especially on optimizing the inclination and anteversion, and determining the center of rotation (Figure 2).

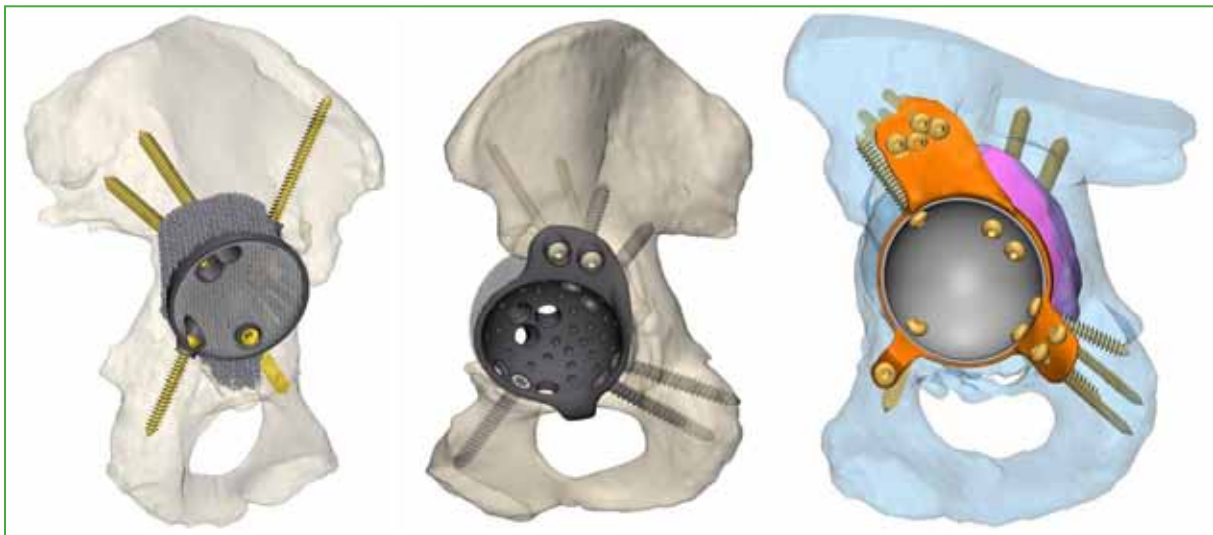


Figure 2. 3D rendering and planning of the 3D cup and example fixation screws.

In all cases, the posterolateral approach was used and the femoral component was revised. After a careful release and dissection of the soft tissues, the acetabular defect was exposed and filled with bone graft, always from a bone bank. In this way, the comorbidity of taking the iliac crest graft is avoided, providing bone structure to the deficit.

During surgery, the surgeon is provided with a trial anatomical mold, the 3D monitors allow locating the defect, the position of the custom component, the screws to be placed, the length and the direction (Figure 3).

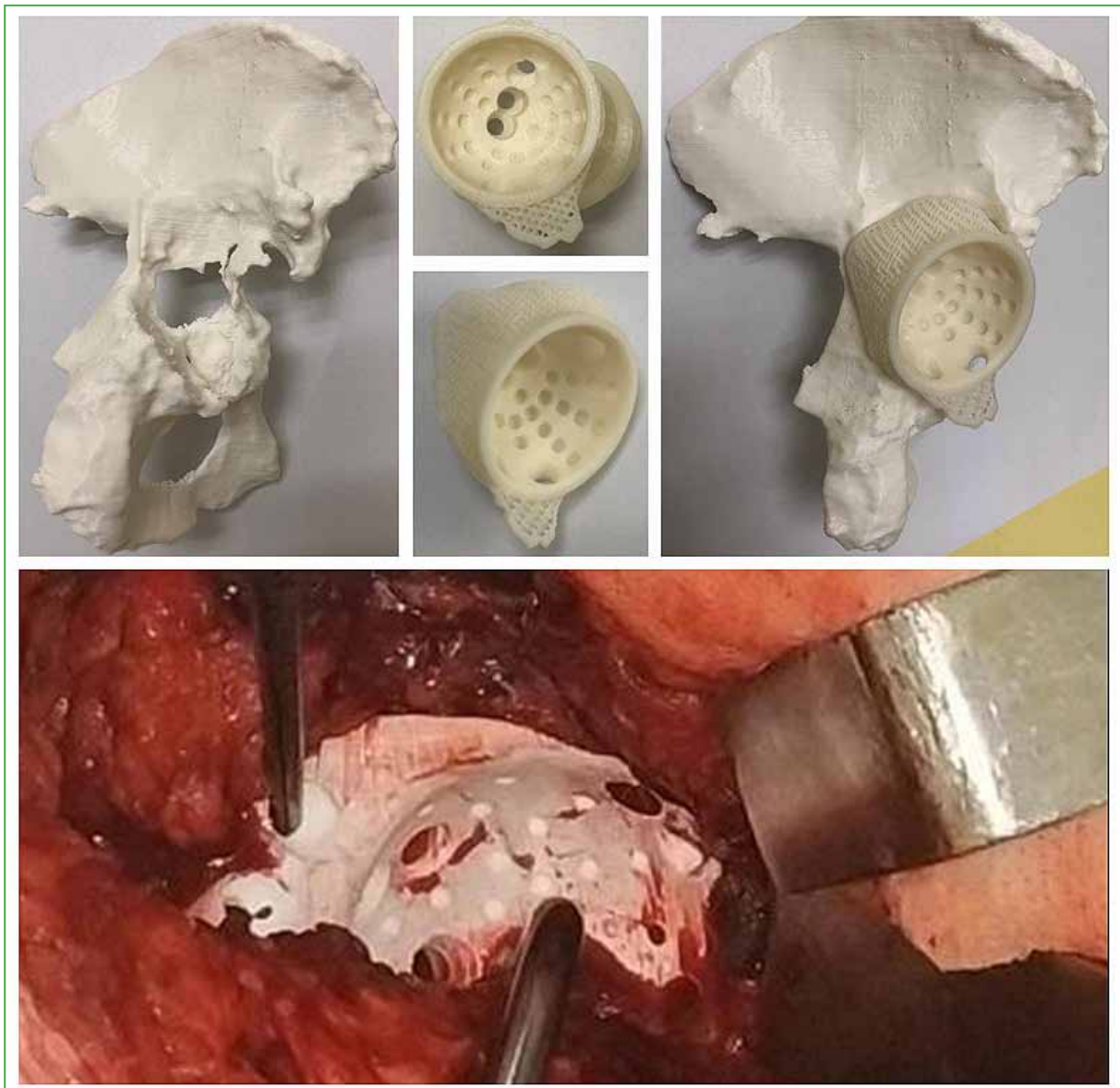

Figure 3. Example of a mold for preoperative planning and the mold used in Case 1 surgery.

The material used for the construction of the custom cups was always trabecular titanium, due to its high coefficient of friction that allows it to provide initial primary stability and, subsequently, due to its high three-dimensional porosity, osseointegration, and secondary biological fixation (Figure 4).^{2,6,7}

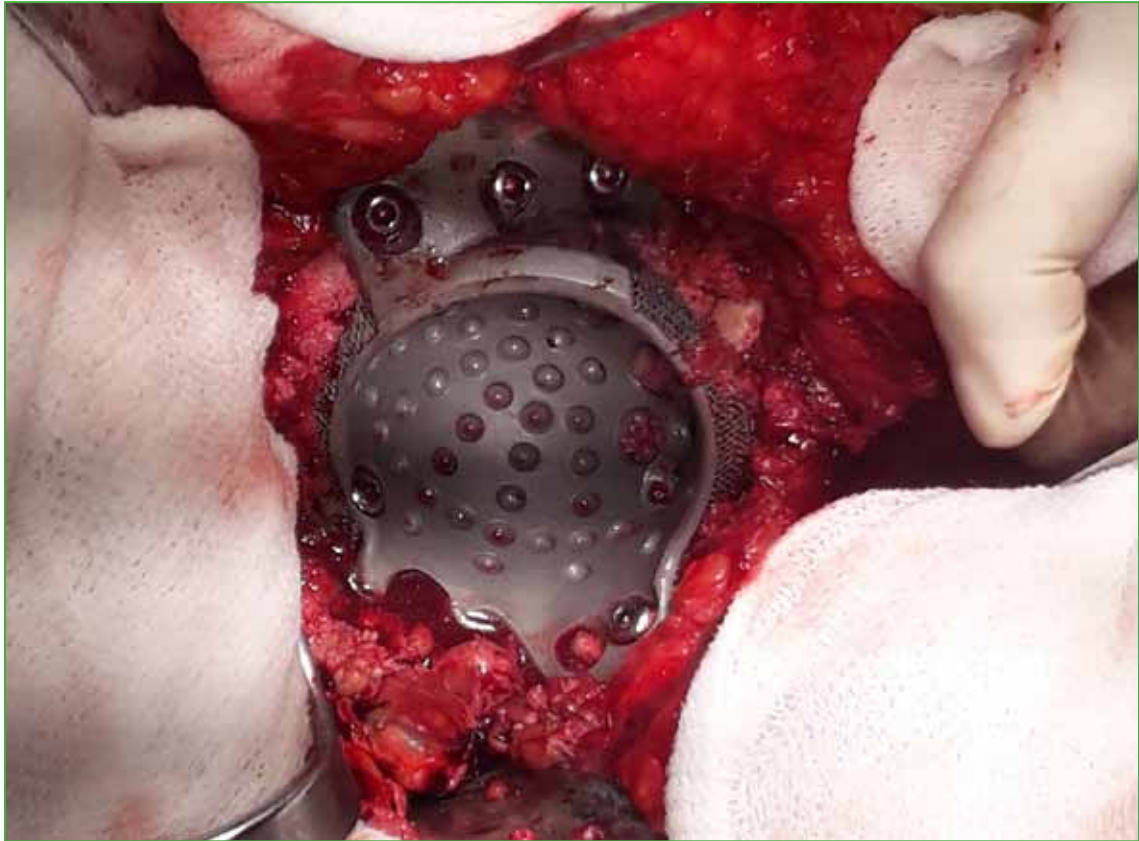


Figure 4. Intraoperative image of the three-dimensional cup used as a restrictor. It allows to fill spaces and provides biological fixation due to its manufacture in tantalum (Case 3).

Next, in the custom acetabulum, a dual mobility cup was cemented, increasing the head-neck ratio and establishing two articulating surfaces that provided greater stability, preventing overloading of the 3D acetabular implant and reducing targeted wear of the cross-linked polyethylene liner (Figure 5).

The dual mobility cup has an important use in patients with a high risk of dislocation, for example, those undergoing oncological resection surgeries,⁸ with hip-spine pathology or previous lumbosacral arthrodesis,⁹ with intracapsular fractures¹⁰ and revision cases such as those presented in this study.¹¹ An intact gluteus medius muscle is essential; if affected, the use of a constrained cup is suggested. In all cases, the correct length and joint range of motion were confirmed, and the reinsertion of the gluteus medius was performed.

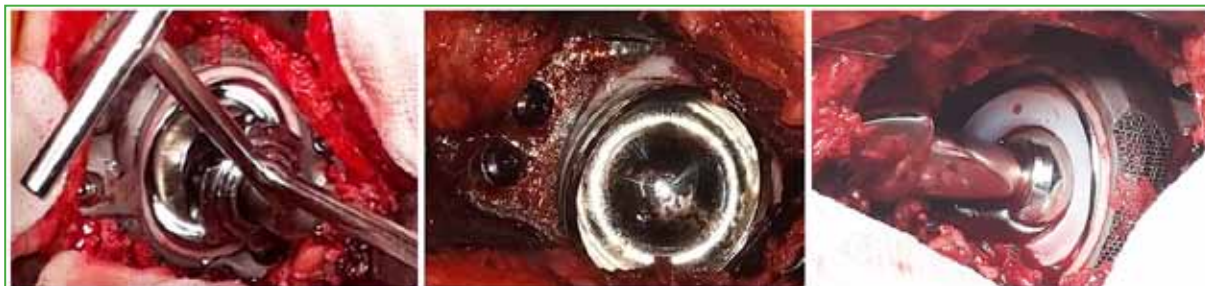

Figure 5. Intraoperative image of the cementation of the dual mobility cup within the three-dimensional implant. This makes it possible to reduce the overload on the latter and reduce the risk of dislocation, one of the most frequent complications when using the 3D cup.

RESULTS

The average hospitalization time was three days and the clinical-surgical evolution of the patients was good. Six of them started weight-bearing 24 h after surgery, assisted by a walker, supplemented with active-passive range of motion exercises and muscle strengthening. Upon discharge, anti-dislocation measures, physiotherapy treatment, analgesics and anticoagulation/aggregation agents were prescribed as appropriate.

The first control was performed three weeks after surgery and, at that time, the mechanical sutures were removed given the good evolution of the surgical wound. Preventive measures for dislocation were maintained until the next consultation.

The following controls were performed with radiographs at 6 weeks, 2 and 3 months. The discontinuation of the walker and the use of Canadian crutches with weight-bearing were indicated. At the sixth month, weight-bearing support was withdrawn and controls were established every six months (Figure 1B, D, F, H, J, L). So far, no post-operative complications have been recorded.

DISCUSSION

The treatment of a massive acetabular bone deficit is a complex scenario in hip revision. The way to treat this defect is a matter of controversy; the multiple procedures described, such as the use of Jumbo cups,¹² structural grafts,¹³ or reconstruction cells,¹⁴ among others, have not achieved favorable long-term outcomes.

On the other hand, custom-made acetabular implants have the advantage of providing stability to these large defects, while at the same time allowing the use of bone graft as a complement with the expectation of biological fixation.

Christie et al. followed up 67 patients treated with 3D implants for 53 months. The Harris Hip Score improved from 33 before surgery to 82 at the end of follow-up. The authors stated that revision was not necessary in any case; however, the main complication was instability and dislocation of the prosthesis.¹⁵

On the other hand, Holt and Dennis published data on 26 patients with Paprosky type IIIB deficiency. The Harris Hip Score improved from 39 to 78 and the success rate was 88%. Three patients presented aseptic loosening due to failed fixation of the ischial screws and two due to dislocations treated by closed reduction.¹⁶

Joshi et al. carried out revisions on 27 patients with an average evolution of 2.3 to 5.3 years, according to the Charnley score modified by Merle d'Aubigné and Postel. They described the great complexity of the procedure, but reported fewer dislocations after including femoral revision in all cases.¹⁷

Lastly, Wind et al. published a retrospective review of 19 patients treated for Paprosky types IIIA and B acetabular deficits, five of whom suffered prosthesis dislocation. 65% of the cases in their cohort were successful, which the authors considered an unfavorable result.¹⁸

According to what has been published, the dislocation of the prosthesis is one of the possible and frequent complications of the treatment of acetabular defects using 3D implants, in addition to loosening.

In this situation, the use of dual mobility cups, as described in this series of patients, will reduce the overload of the customized implant, provide a greater range of motion and less polyethylene wear, and reduce the risk of dislocation of the prosthesis, one of the main complications described in the literature.

The treatment of Paprosky type IIIA and B acetabular bone defects has become a real challenge in total hip replacement revision surgeries.

Historically, the literature has described high rates of complications, especially loosening, in the results of the reconstruction of these massive defects using classic techniques, such as the use of Jumbo cups, bone grafts or reconstruction cages, among others.

The management of this condition through 3D implants created with computer engineering have founded a new paradigm. This procedure requires a deeper study of each case, preoperative planning, and high technical demand. The published results are encouraging, since it practically eliminates the typical loosening of other types of procedures. However, instability has become its main complication.

Based on this problem, the cementation of dual mobility cups in 3D implants was implemented, practically eliminating the risks of instability and, in turn, reducing overload. The international literature in this regard is minimal. Baauw et al. published a series of 12 cases with a minimum follow-up of 18 months. None of the patients presented loosening and only one suffered a dislocation, in which the femoral stem had not been revised.

In Argentina, too, the literature is scarce; there is a study by Belzino et al. from 2020.¹⁹ The main limitation of this study is the limited series of cases, directly attributable to the fact that it is a rare condition. The standardization and streamlining of this therapeutic method are of vital importance given the exponential increase in hip arthroplasties in the world, as a possible resolution in cases of catastrophic progression.

CONCLUSIONS

This article described a detailed approach to the analysis carried out by the hip team and its medical IT collaborators to develop a customized titanium implant that allowed optimal bone anchors to be placed with screws in the areas of greatest fixation, depending on the particular remaining bone tissue of each patient, and the use of dual mobility cup cementation to reduce the incidence of instability, the main complication in the treatment of Paprosky type IIIA and B acetabular defects with custom-made implants.

Conflict of interest: The authors declare no conflicts of interest.

C. Sabatella ORCID ID: <https://orcid.org/0000-0001-8269-3661>

G. J. Blanco O'dena ORCID ID: <https://orcid.org/0000-0002-1019-369X>

REFERENCES

1. Paprosky WG, Perona PG, Lawrence JM. Acetabular defect classification and surgical reconstruction in revision arthroplasty. A 6-year follow-up evaluation. *J Arthroplasty* 1994;9(1):33-44. [https://doi.org/10.1016/0883-5403\(94\)90135-x](https://doi.org/10.1016/0883-5403(94)90135-x)
2. Callaghan J, Rosenberg A, Rubash HE. *Cadera*, 2ª ed. Madrid: Marban; 2017
3. Gelaude F, Clijmans T, Delpont H. Quantitative computerized assessment of the degree of acetabular bone deficiency: Total radial acetabular bone loss (TrABL). *Adv Orthop* 2011;2011:494382. <https://doi.org/10.4061/2011/494382>
4. Nilsson A, Bremander A. Measures of hip function and symptoms: Harris Hip Score (HHS), Hip Disability and Osteoarthritis Outcome Score (HOOS), Oxford Hip Score (OHS), Lequesne Index of Severity for Osteoarthritis of the Hip (LISOH), and American Academy of Orthopedic Surgeons. *Arthritis Care Res* 2011;63(Suppl 11): S200-7. <https://doi.org/10.1002/acr.20549>
5. Ugino FK, Righetti CM, Alves DP, Guimarães RP, Honda EK, Ono NK. Evaluation of the reliability of the modified Merle d'Aubigné and Postel Method. *Acta Ortop Bras* 2012;20(4):213-7. <https://doi.org/10.1590/S1413-78522012000400004>

6. Bobynd JD, Stackpool GJ, Hacking S, Tanzer M, Krygier JJ. Characteristics of bone ingrowth and interface mechanics of a new porous tantalum biomaterial. *J Bone Joint Surg Br* 1999;81:907-14. <https://doi.org/10.1302/0301-620X.81B5.9283>
7. Meneghini RM, Meyer C, Buckley CA, Hanssen AD, Lewallen DG. Mechanical stability of novel highly porous metal acetabular components in revision total hip arthroplasty. *J Arthroplasty* 2010;25(3):337-41. <https://doi.org/10.1016/j.arth.2009.03.003>
8. Philippeau JM, Durand JM, Carret JP, Leclercq S, Waast D, Gouin F. Dual mobility design use in preventing total hip replacement dislocation following tumor resection. *Orthop Traumatol Surg Res* 2010;96(1):2-8. <https://doi.org/10.1016/j.rcot.2009.12.011>
9. Mudrick CA, Melvin JS, Springer BD. Late posterior hip instability after lumbar spinopelvic fusion. *Arthroplast Today* 2015;1(2):25-9. <https://doi.org/10.1016/j.artd.2015.05.002>
10. Adam P, Philippe R, Ehlinger M, Roche O, Bonnomet F, Molé D, Fessy MH; French Society of Orthopaedic Surgery and Traumatology (SoFCOT). Dual mobility cups hip arthroplasty as a treatment for displaced fracture of the femoral neck in the elderly. A prospective, systematic, multicenter study with specific focus on postoperative dislocation. *Orthop Traumatol Surg Res* 2012;98(3):296-300. <https://doi.org/10.1016/j.otsr.2012.01.005>
11. Baauw M, van Hellemond GG, Spruit M. A custom-made acetabular implant for Paprosky type 3 defects. *Orthopedics* 2017;40(1):e195-e198. <https://doi.org/10.3928/01477447-20160902-011>
12. Whaley AL, Berry DJ, Harmsen WS. Extra-large uncemented hemispherical acetabular components for revision total hip arthroplasty. *J Bone Joint Surg Am* 2001;83(9):1352-7. <https://doi.org/10.2106/00004623-200109000-00010>
13. Perka C, Ludwig R. Reconstruction of segmental defects during revision procedures of the acetabulum with the Burch-Schneider anti-protrusio cage. *J Arthroplasty* 2001;16(5):568-74. <https://doi.org/10.1054/arth.2001.23919>
14. Paprosky WG, O'Rourke M, Sporer SM. The treatment of acetabular bone defects with an associated pelvic discontinuity. *Clin Orthop Relat Res* 2005;441:216-20. <https://doi.org/10.1097/01.blo.0000194311.20901.f9>
15. Christie MJ, Barrington SA, Brinson MF, Ruhling ME, DeBoer DK. Bridging massive acetabular defects with the triflange cup: 2- to 9-year results. *Clin Orthop Relat Res* 2001;(393):216-27. <https://doi.org/10.1097/00003086-200112000-00024>
16. Holt GE, Dennis DA. Use of custom triflanged acetabular components in revision total hip arthroplasty. *Clin Orthop Relat Res* 2005;429:209-14. <https://doi.org/10.1097/01.blo.0000150252.19780.74>
17. Joshi AB, Lee J, Christensen C. Results for a custom acetabular component for acetabular deficiency. *J Arthroplasty* 2002;17(5):643-8. <https://doi.org/10.1054/arth.2002.32106>
18. Wind MA Jr, Swank ML, Sorger JI. Short-term results of a custom triflange acetabular component for massive acetabular bone loss in revision THA. *Orthopedics* 2013;36(3):e260-5. <https://doi.org/10.3928/01477447-20130222-1>
19. Belzino MD, Ottolenghi J, Lupacchini M, Ivalde F, Espagnol R, Melo LM. Diseño digital 3D a medida para defectos óseos de cadera. *Acaro Journal* 2020;6(1):1-7. Available at: <https://acarorevista.org.ar/joomla-pages-iii/categories-list/56-la-revista/ultima-edicion/julio-2020-vol-6-num-1/213-diseno-digital-3d-a-medida-para-defectos-oseos-de-cadera#:~:text=La%20utilizaci%C3%B3n%20del%20modelo%20en,de%20manera%20precisa%20y%20personalizada>