

# Suprapectoral Biceps Tenodesis. Clinical Outcomes

Juan Martín Patiño,\* Enrique S. Cabrera\*\*

\*Hand and Upper Limb Surgery Service, Shoulder and Elbow Section, Orthopedics and Traumatology Department, "Cirujano Mayor Cosme Argerich" Central Military Hospital, Autonomous City of Buenos Aires, Argentina

\*\* Shoulder and Elbow Surgery Service, Clínica Modelo de Morón, Buenos Aires, Argentina

## ABSTRACT

**Objective:** To evaluate and compare outcomes in a case series of SLAP injuries and complete tears of the long head of the biceps treated with suprapectoral tenodesis using a mini-open approach. **Materials and Methods:** Patients aged over 18, treated between 2019 and 2020, with a minimum 1-year follow-up were included. The demographic characteristics, indication for surgery, return to activities considered usual by the patient, and complications were recorded. The American Shoulder and Elbow Surgeons (ASES) score for the shoulder was used, and the active range of motion of the affected shoulder was measured. In addition, the patients were asked if they were able to return to their daily activities. We recorded the diagnosis that led the patients to surgery and whether they had undergone a traumatic event coinciding with the onset of symptoms. **Results:** 8 patients were evaluated, the median age was 42.5, and the follow-up was 17 months (IQR 13.5 – 21.5). Six patients (75.0%) had a type II SLAP injury, and two (25.0%) had a complete LHB tear. Six patients (75.0%) associated the symptoms with a traumatic event. The final range of motion of the shoulder (median) was: flexion 180° (IQR 170°-180), internal rotation 65° (IQR 60° - 75°), and external rotation 70° (IQR 65° - 87.5°). **Conclusion:** Suprapectoral tenodesis with a prior arthroscopic tenotomy for SLAP II cases or in cases of complete tears of the long head of the biceps is a safe technique for achieving functional outcomes.

**Keywords:** Biceps; suprapectoral tenodesis; tenodesis; SLAP, proximal biceps; LHB.

**Level of Evidence:** IV case series

## Tenodesis suprapectoral del bíceps. Resultados clínicos

## RESUMEN

**Objetivo:** Evaluar los resultados de la tenodesis suprapectoral mediante un miniabordaje en una serie de pacientes con lesión SLAP y desgarros completos de la porción larga del bíceps, y compararlos con los valores prequirúrgicos. **Materiales y Métodos:** Se incluyeron pacientes adultos tratados con dicha técnica entre 2019 y 2020, y un seguimiento mínimo de un año. Se registraron las características demográficas, la indicación de cirugía, el retorno a las actividades consideradas habituales por el paciente y las complicaciones. Se utilizó el puntaje ASES para hombro, y se midió la movilidad activa del hombro afectado. Además, se le preguntó al paciente si retomó la actividad que consideraba habitual, con opciones "sí" o "no". Se consignó si los pacientes reconocían un evento traumático con el inicio de los síntomas y se registró el diagnóstico con el que se llegó a la cirugía. **Resultados:** Se evaluó a 8 pacientes (7 hombres), con una mediana de la edad de 42.5 años. El seguimiento fue de 17 meses (RIC 13.5-21.5). Seis (75%) tenían diagnóstico de lesión SLAP tipo II y dos (25%), de desgarramiento completo. Seis pacientes (75%) asociaron los síntomas con un evento traumático. Las medianas de los rangos de movilidad finales fueron: flexión 180° (RIC 170°-180°), rotación interna 65° (RIC 60°-75°) y rotación externa 70° (RIC 5°- 87,5°). **Conclusión:** La tenodesis suprapectoral tras una tenotomía artroscópica para casos de lesión SLAP II o de desgarramientos completos de la porción larga del bíceps resultó una técnica segura y con resultados funcionales.

**Palabras clave:** Bíceps; tenodesis suprapectoral; tenodesis; SLAP; tendón del bíceps proximal.

**Nivel de Evidencia:** IV serie de casos

Received on February 24<sup>th</sup>, 2022. Accepted after evaluation on May 18<sup>th</sup>, 2022 • Dr. JUAN MARTÍN PATIÑO • jmpaty2@yahoo.com.ar

 <https://orcid.org/0000-0002-9036-0442>

**How to cite this article:** Patiño JM, Cabrera ES. Suprapectoral Tenodesis of the Biceps. Clinical Outcomes. *Rev Asoc Argent Ortop Traumatol* 2022;87(4):488-497. <https://doi.org/10.15417/issn.1852-7434.2022.87.4.1526>

## INTRODUCTION

The pathology of the long head of the biceps includes a wide spectrum of clinical scenarios, such as complete tears, tenosynovitis, instability, and SLAP (superior labrum anterior posterior) injuries. With its different technical options, biceps tenodesis is usually the first option when there are complete tears and instability of the articular portion. In recent years, tenodesis has gained popularity as an alternative to repairs for SLAP injuries.<sup>1-4</sup>

Tenodesis of the long head of the suprapectoral biceps performed entirely by arthroscopy and subpectoral tenodesis through a mini-open approach have been proposed. There is evidence and comparative studies between these techniques, but there is little evidence and information on suprapectoral tenodesis using a mini-open approach after arthroscopic tenotomy.<sup>5-9</sup> We have not found published series reporting results with this technique.

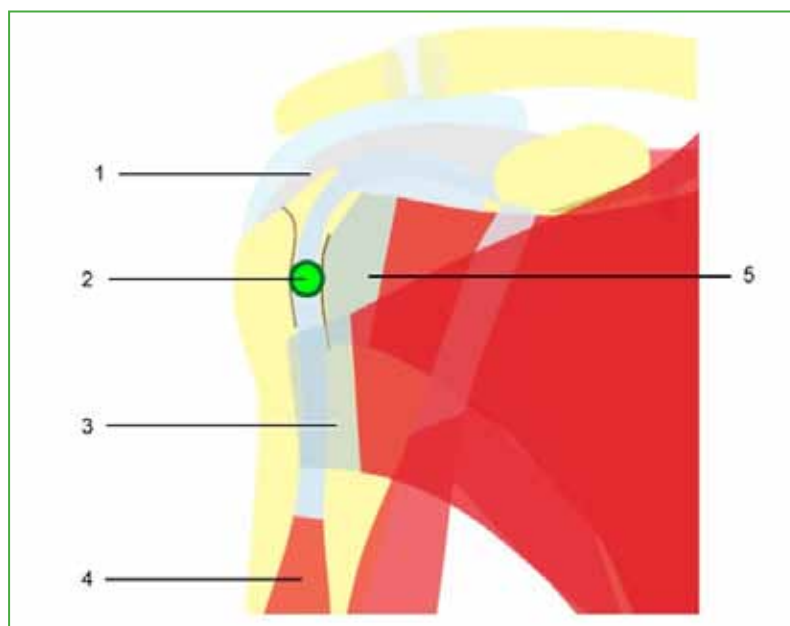
The objective of this study was to evaluate the outcomes in a series of patients undergoing suprapectoral tenodesis using a mini-open approach, and compare them with preoperative values.

## MATERIALS AND METHODS

A retrospective, descriptive and analytical research was carried out. We included adult patients who had undergone tenodesis using a mini suprapectoral approach for proximal biceps pathology between 2019 and 2020, with a minimum follow-up of one year. Patients who were lost to follow-up and those in whom the tenodesis was secondary to other procedures were excluded. In our database, 13 patients were retrospectively identified, one was excluded because he had been lost to follow-up and four because the tenodesis had been secondary to cuff repairs (in the same surgery). All were operated on by the same surgeon.

Demographic characteristics, reason for indicating surgery, return to activities considered normal, and complications were recorded. The range of motion of the affected shoulder was evaluated in anterior flexion, and external and internal rotations at 90° of abduction.

The indication for surgery in cases of SLAP lesions was due to pain that prevented the patient from performing the usual tasks, with at least three months of medical treatment and rehabilitation without remission of symptoms (pain, dislocations, positive O'Brien test). Medical treatment did not include injections. In two cases, it was indicated for the treatment of a complete tear of the long head of the biceps (Figure 1).



**Figure 1.** Scheme of the suprapectoral tenodesis site. 1. Supraspinatus. 2. Level of the suprapectoral tenodesis. 3. Pectoralis major. 4. Biceps. 5. Subscapularis.

The Snyder classification for SLAP injuries and the *American Shoulder and Elbow Surgeons* (ASES) score for the shoulder were used. The active range of motion of the affected shoulder was measured: forward flexion, external rotation with the arm in 90° abduction, internal rotation with the arm in the same position. All measurements and scores were recorded before surgery and postoperatively. In addition, the patient was asked if he was able to resume the activities he considered usual, with options “yes” or “no”. The diagnosis that led to surgery was recorded.

The biceps was evaluated by clinical inspection in the supinated and extended arm position looking for signs of detachment or re-tear (Table 1).

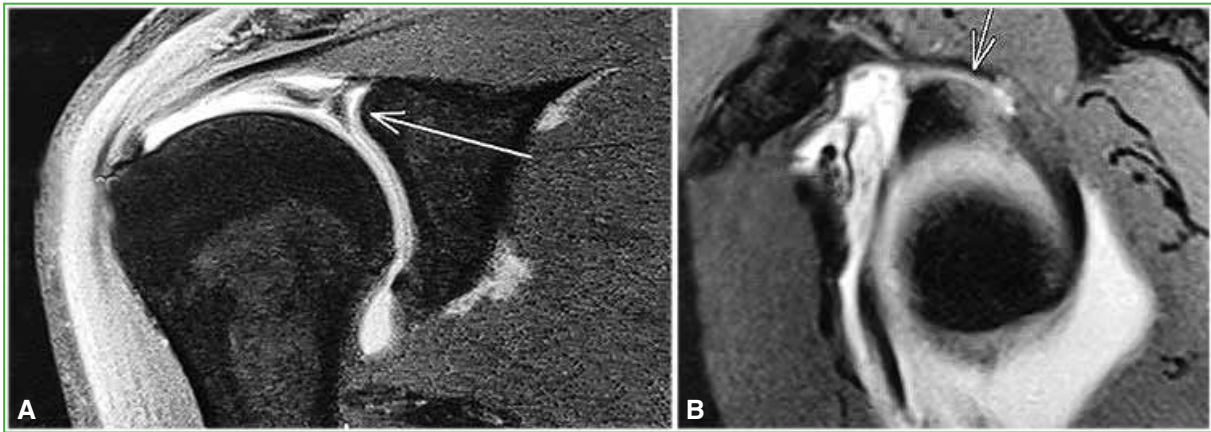
**Table 1.** Demographic, clinical and follow-up characteristics

Characteristics	Patients (n = 8)
<b>Sex, n (%)</b>	
Female	1 (12.5%)
Male	7 (87.5%)
<b>Age, median (IQR)</b>	42.5 (37.0-46.5)
<b>Diagnosis, n (%)</b>	
SLAP II	6 (75%)
Tear	2 (25%)
<b>Side, n (%)</b>	
Right	5 (62.5%)
Left	3 (37.5%)
<b>Months of follow-up, median (IQR)</b>	17 (13.5-21.5)

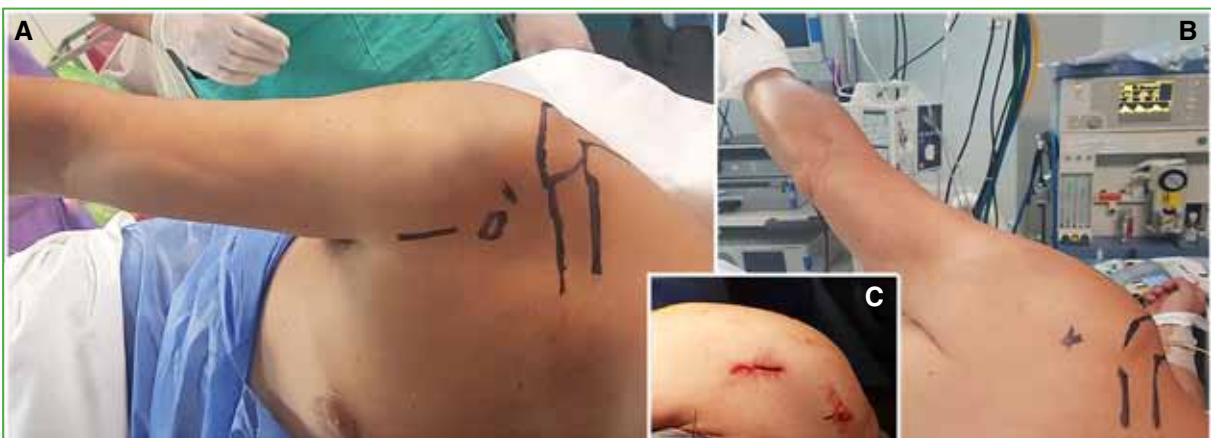IQR = interquartile range. SLAP = superior labrum anterior posterior

## Surgical technique

In all cases, general anesthesia with block was administered for postoperative pain management. Surgery is performed with the patient in the lateral decubitus position under traction in cases of SLAP injury. First, a glenohumeral arthroscopy is performed. A posterior and an anterior portal are used. Once the pathology has been evaluated and the indication defined (unstable SLAP lesion plus degenerative signs and pathology of the joint tendon such as thickening and instability), the tenotomy of the long head of the biceps with radiofrequency through the anterior portal is performed. Then, in the same position, an anterior longitudinal approach is performed in the most distal deltopectoral section, usually 5 cm distal to the anterolateral end of the acromion. The dissection is performed through the deltopectoral interval. Once that interval has been dissected, the deltoid is retracted laterally with a Hohmann lever to visualize the anterior aspect of the humerus. The bicipital groove is identified, it is incised and recovered by tractioning the end of the previously tenotomized biceps tendon. The bone surface is then roughened. After determining the reinsertion and fixation point, the end of the biceps is regularized and prepared according to the fixation method, which may consist of conventional anchors or those designed for tenodesis, bone fixation or biotenodesis screws. It is important to keep the elbow in extension to achieve adequate tension. In this case, the upper limb is under tension. If anchors are used, the fixation to the pectoralis major can be strengthened with sutures. Finally, it is sutured in planes. In cases of biceps rupture, the described mini-open approach is performed directly with the patient in a beach chair position. The patient is then immobilized in a sling for four weeks. Passive range of motion exercises are indicated at three weeks; then, physical therapy begins (Figures 2-4).

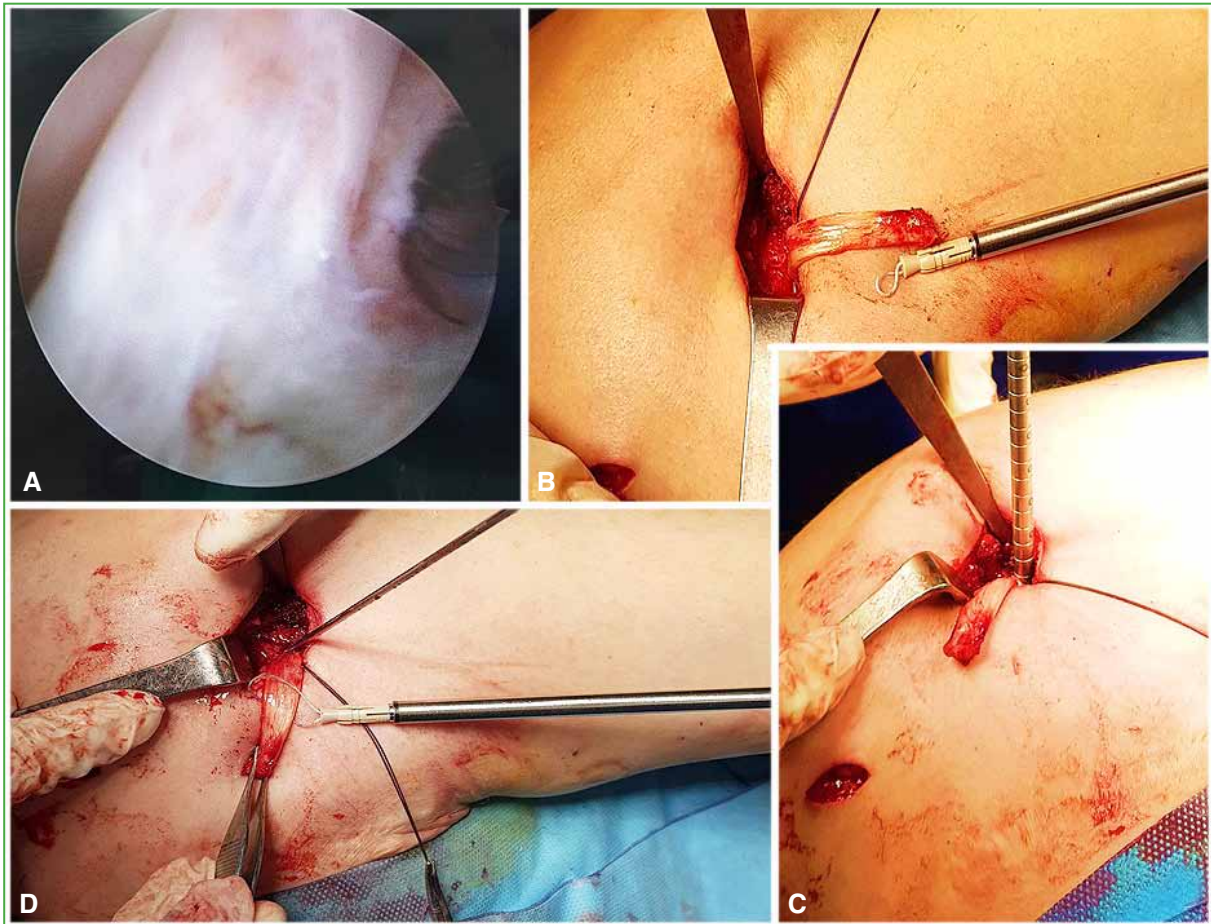


**Figure 2.** Magnetic resonance imaging of the shoulder. **A.** Anteroposterior section. The arrow shows a type II SLAP lesion. **B.** Sagittal section. The arrow shows an anteroposterior type II SLAP lesion.



**Figure 3.** Lateral decubitus position under traction used in SLAP cases. **A and B.** The anterior portal used for the tenotomy and the mini-open approach for the suprapectoral tenodesis are marked, approximately 5 cm distal to the acromion. **C.** Clinical appearance of the incisions before suturing.





**Figure 4.** **A.** Posterior arthroscopic view of a SLAP II injury and biceps with tenosynovitis. **B.** The biceps was recovered through the suprapectoral approach. The detail of the anchorage used for the tenodesis can be observed. **C.** Carving of the bone tunnel in the humerus before placement of the guide (cannulated wick). **D.** Detail of the tendon looping technique to ensure its introduction into the humerus before tenodesis.

### Statistical analysis

A descriptive analysis was made. Data are expressed as median and interquartile range (IQR) for numerical variables and as absolute values with their percentages for categorical data. To compare the results of surgery with preoperative values, the Wilcoxon signed rank test was used. A  $p$  value  $<0.05$  was considered significant. The data were analyzed with the STATA/MP version 14 package.

### RESULTS

The study group included eight patients, seven (87.5%) were men. The patients were active, practiced recreational sports and overhead activities, but had not been treated for work accidents or by a Work Risk Insurer. The median age was 42.5 years (IQR 37.0-46.5). The median follow-up was 17 months (IQR 13.5-21.5). Six of the patients (75%) had a preoperative diagnosis of type II SLAP injury and two (25%) of complete tear. In six cases (75%), surgery was performed with a diagnosis of magnetic resonance imaging compatible with a SLAP lesion. The two patients with complete tears were 42 and 56 years old. The mean age of patients with SLAP lesions was 39 years.

In four cases (50%), tenodesis was performed with a 5-mm double suture PEEK (polyetheretherketone) anchor, and in four (50%) with a TenoLok tenodesis anchor (ConMed, Largo FL, USA).

Six patients (75%) returned to their previous activity, two (25%) reported not being able to fully perform their activities.

The median pre-surgical ranges of motion were: flexion 165° (IQR 155°-175°), internal rotation 47.5° (IQR 30°-70°) and external rotation 60° (IQR 42.5°-75, 0°). The median final ranges of motion were: flexion 180° (IQR 170°-180°), internal rotation 65° (IQR 60°-75°), and external rotation 70° (IQR 65°-87.5°) (Table 2).

**Table 2.** Pre- and postoperative ranges of motion and ASES score

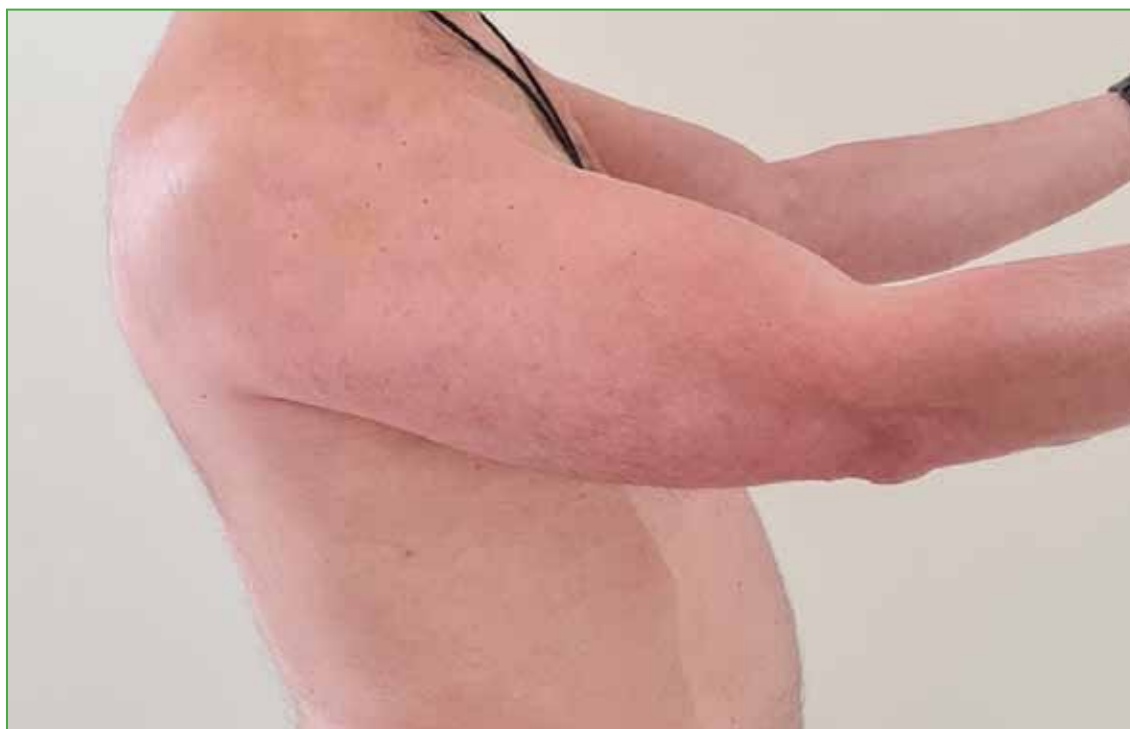	Preoperative	Postoperative	p
Flexion, median (IQR)	165 (155-175)	180 (170-180)	0.031
Internal rotation, median (IQR)	47.5 (30-70)	65 (60-75)	0.078
External rotation, median (IQR)	60 (42.5-75)	70 (65-87.5)	0.039
ASES, median (IQR)	68 (42.5-79)	90 (75-95)	0.007

IQR = interquartile range.

A statistically significant difference was observed in pre- and postoperative ranges of motion, specifically in flexion ( $p = 0.031$ ) and external rotation ( $p = 0.039$ ), but not in internal rotation ( $p = 0.078$ ).

The median pre-intervention ASES score was 68 (IQR 42.5-79) and the median final ASES score was 90 (IQR 75-95). A statistically significant difference was obtained between the ASES score before the intervention and after ( $p < 0.01$ ).

No general complications, such as infections, or related to the surgical technique were recorded. No disinsertions of the tenodesis (Popeye's sign) were observed (Figure 5).



**Figure 5.** Clinical image of the contour of the biceps after tenodesis.

## DISCUSSION

We present a series of cases treated with suprapectoral tenodesis using a mini-open approach in which ASES scores and functional range of motion were compared before and after surgery.

Different options have been proposed for proximal biceps tenodesis. The main controversy in the literature is whether to perform tenodesis entirely arthroscopically or through a mini-open approach after arthroscopic tenotomy. Another point of discussion is where to perform the tenodesis. The suprapectoral location has been reported in the bicipital groove<sup>1</sup> and the subpectoral groove.<sup>23</sup>

Although the site of suprapectoral tenodesis is the one originally proposed for reattachments after a complete tear,<sup>4</sup> in recent years, arthroscopic suprapectoral and subpectoral tenodeses using a mini-open approach have been reported in multiple studies, but we did not identify recent publications with this technique. The exceptions are an anatomical study in which the proximity to nerve structures is evaluated and another that reports the use of an Endobutton® device.<sup>5,6</sup>

In a level III epidemiological study on the trend between these two options, it was found that the general indication for tenodesis tends to increase. Of 8,547 patients treated with long head biceps tenodesis, 43.5% were performed by open technique and 56.5% by arthroscopy. In that review, open techniques were more frequent when performed as the only procedure and arthroscopic methods when there were concomitant procedures. Furthermore, the authors concluded that complications are extremely rare and that there are no differences between techniques.<sup>7</sup>

We consider that the theoretical advantages of suprapectoral tenodesis include that the technique may be less demanding than that of tenodesis performed entirely arthroscopically and, on the other hand, the location immediately above the pectoral would avoid reported complications in subpectoral tenodesis, such as neurological injuries of the musculocutaneous nerve and fractures, as it is a more robust region of the humerus.<sup>8,9</sup> In addition, good muscle coverage can be obtained, avoiding the regional pain reported as a complication in arthroscopic tenodeses in the superior groove.<sup>10</sup>

In a cadaveric anatomical study, the distances to the axillary, radial and musculocutaneous nerves were measured, with fixation techniques in which it is necessary to go through the posterior cortical bone of the humerus, and it was found that, in the suprapectoral position, the axillary nerve has greater proximity risk.<sup>5</sup> In this series, we did not transfix the posterior cortex with the techniques used for anchor fixation and biceps tenodesis.

Regarding the cases of SLAP II injury, the alternative to tenodesis is its repair with arthroscopic anchors, with which satisfactory outcomes are achieved,<sup>11</sup> but in our series, the SLAP injury was associated with degenerative characteristics of the articular portion of the biceps and injury instability. Therefore, we indicated tenotomy and tenodesis. These pathological characteristics of the tendon are related to the chronicity of the symptoms.

According to some authors, the primary indication for the treatment of SLAP lesions is repair, mainly in patients <35 years of age; however, in recent years, variable results have been published. On the other hand, worse results were obtained with repairs in series of SLAP type II lesions, which suggests better results with tenodesis. In these studies, they focus the analysis on the age of the patients and the return to normal activity.

Boileau et al.<sup>12</sup> compared a small series of tenodesis repairs and reported that 40% of repair patients were satisfied, only 20% returned to their previous activity level; in the tenodesis group, 93% were satisfied and 87% returned to their previous level of activity. In a comparative retrospective study of 15 tenodeses with 15 repairs, Ek et al.<sup>13</sup> found no differences in the ASES score, patient satisfaction and return to sports (76% vs. 60%). As in our series, tenodesis was indicated, mostly, for patients >35 years of age and due to a degenerative labrum. Instead, repairs were indicated when healthy tissue was present and in patients <35 years of age. There was one case of tenodesis failure and two cases of repair stiffness, all resolved with non-surgical treatment.

Denard et al.<sup>14</sup> compared both techniques (22 repairs and 15 tenodeses) in patients >35 years of age. The treatment decision was based on patient factors such as age, activity, and work compensation. The authors reported that in patients >35 years of age with a SLAP II injury as a single injury, greater satisfaction, more predictable function, and a higher rate of return to activity may be obtained with biceps tenodesis compared with repairs. In 2021, Hurley et al.<sup>15</sup> compared the results of 29 cases of subpectoral tenodesis and 74 arthroscopic repairs in patients <30 years of age (SLAP II and IV lesion). They found no difference in function and return to sport. They reviewed nine repairs (11.5%) and no tenodesis. They found no differences in visual analog scale, ASES score, patient satisfaction, and biceps girth.<sup>16</sup>

It should be noted that, in this series, the indication for tenodesis was defined at surgery in patients with SLAP II injury and biceps with a degenerative appearance. In all these cases, the preoperative evolution was long-standing with multiple previous non-surgical treatments, one of the patients had been operated on 20 years earlier for anterior instability using an open Bankart technique. The two cases without SLAP injury involved complete tear of the long head of the biceps, so suprapectoral tenodesis was performed directly.

The position of the biceps was clinically evaluated and no signs of detachment, re-tearing or tension alterations (Popeye's sign) were observed. According to a cadaveric anatomical study, the ideal position to achieve adequate biceps tension would be immediately proximal to the pectoralis major (suprapectoral), in addition to being safe in relation to the nearby neurovascular structures.<sup>17</sup>

We found no reports on the results of suprapectoral tenodesis using a mini-open approach, so comparison with other experiences is difficult. We obtained a final average ASES score of 90. On the other hand, numerous series comparing subpectoral tenodesis have been published. Mazzocca et al.<sup>2</sup> reported a series of 41 patients with subpectoral tenodesis and the average ASES score obtained was 89. Along the same lines, in another study of 20 active patients <45 years old with SLAP II injury undergoing subpectoral tenodesis, the authors suggested that excellent outcomes related to patient satisfaction and return to the same sporting level can be obtained.<sup>18</sup>

In a study of subpectoral tenodesis as a primary indication in cases of SLAP II injury, tenosynovitis, and other chronic pathologies of the long head of the biceps, Provencher et al. obtained high functional and return to activities rates, with a low rate of complications.<sup>19</sup> Comparisons between suprapectoral and subpectoral tenodesis have not shown substantial differences in terms of scores, satisfaction, return to sports activities, or complications.<sup>7,15,16</sup> Another option to tenodesis is tenotomy as a standalone procedure, but it is reserved for pathology of the proximal biceps in elderly patients with low functional demand, sedentary, obese, and without aesthetic problems, all situations that lead to low demand for strength. With this technique without tenodesis, a 13-50% incidence of Popeye's sign has been reported postoperatively. Likewise, a decrease in flexion and supination strength has been reported.<sup>20,21</sup> In our series, there were two cases of complete tear in which reinsertion by tenodesis was decided after exposing the options and the possible evolution to the patients.

No specific complications related to the technique used were detected. Some authors consider complications or failures when the return to full activity or low scores on the scales are not achieved.<sup>19</sup> Therefore, we believe that it constitutes a valid option for the treatment of SLAP injury—when repair is not an option—and for the reattachment of the long head of the biceps in complete tears. The weaknesses of this study are its retrospective design and the small number of patients. Likewise, it is a heterogeneous sample with different fixation methods. But, on the other hand, it is a technique with little evidence in the literature and a pre- and postoperative clinical evaluation.

## CONCLUSION

Suprapectoral tenodesis by a mini-open approach after arthroscopic tenotomy for SLAP II injuries or complete tears of the long head of the biceps was a safe technique and achieved functional outcomes.

## Acknowledgments

To Dr. Guillermo Ricciardi for his collaboration with the illustration.

---

Conflict of interest: The authors declare no conflicts of interest.

E. S. Cabrera ORCID ID: <https://orcid.org/0000-0003-3058-3465>



## REFERENCES

1. Lo IKY, Burkhart SS. Arthroscopic biceps tenodesis using a bioabsorbable interference screw. *Arthroscopy* 2004;20(1):85-95. <https://doi.org/10.1016/j.arthro.2003.11.017>
2. Mazzocca AD, Rios CG, Romeo AA, Arciero RA. Subpectoral biceps tenodesis with interference screw fixation. *Arthroscopy* 2005;21(7):896. <https://doi.org/10.1016/j.arthro.2005.04.002>
3. Gottschalk MB, Karas SG, Ghattas TN, Burdette R. Subpectoral biceps tenodesis for the treatment of type II and IV superior labral anterior and posterior lesions. *Am J Sports Med* 2014;42(9):2128-35. <https://doi.org/10.1177/0363546514540273>
4. Froimson AI, O I. Keyhole tenodesis of biceps origin at the shoulder. *Clin Orthop Relat Res* 1975;(112):245-9. PMID: 1192640
5. Sethi PM, Vadasdi K, Greene RT, Vitale MA, Duong M, Miller SR. Safety of open suprapectoral and subpectoral biceps tenodesis: an anatomic assessment of risk for neurologic injury. *J Shoulder Elbow Surg* 2015;24(1):138-42. <https://doi.org/10.1016/j.jse.2014.06.038>
6. Prabhu J, Faqi MK, Awad RK, Alkhalifa F. Modified open suprapectoral EndoButton tension slide tenodesis technique of long head of biceps with restored tendon tension-length. *Open Orthop J* 2017;11:281-90. <https://doi.org/10.2174/1874325001711010281>
7. Saltzman BM, Leroux TS, Cotter EJ, Basques B, Griffin J, Frank RM, et al. Trends in open and arthroscopic long head of biceps tenodesis. *HSS J* 2020;16(1):2-8. <https://doi.org/10.1007/s11420-018-9645-1>
8. Feng S, Song Y, Li H, Chen J, Chen J, Chen S. Outcomes for arthroscopic repair of combined Bankart/SLAP lesions in the treatment of anterior shoulder instability: A systematic review and meta-analysis. *Orthop J Sports Med* 2019;7(10):2325967119877804. <https://doi.org/10.1177/2325967119877804>
9. Gombera MM, Kahlenberg CA, Nair R, Saltzman MD, Terry MA. All-arthroscopic suprapectoral versus open subpectoral tenodesis of the long head of the biceps brachii. *Am J Sports Med* 2015;43(5):1077-83. <https://doi.org/10.1177/0363546515570024>
10. Johannsen AM, Macalena JA, Carson EW, Tompkins M. Anatomic and radiographic comparison of arthroscopic suprapectoral and open subpectoral biceps tenodesis sites. *Am J Sports Med* 2013;41(12):2919-24. <https://doi.org/10.1177/0363546513503812>
11. Patiño JM. SLAP en pacientes no deportistas. Resultados funcionales con un mínimo de dos años de seguimiento y factores de riesgo para retorno a las actividades. *Artroscopia* 2021;28(2):134-9. Available at: <https://www.revistaartroscopia.com.ar/index.php/revista/article/view/180>
12. Green JM, Getelman MH, Snyder SJ, Burns JP. All-arthroscopic suprapectoral versus open subpectoral tenodesis of the long head of the biceps brachii without the use of interference screws. *Arthroscopy* 2017;33(1):19-25. <https://doi.org/10.1016/j.arthro.2016.07.007>
13. Ek ET, Shi LL, Tompson JD, Freehill MT, Warner JJ. Surgical treatment of isolated type II superior labrum anterior-posterior (SLAP) lesions: Repair versus biceps tenodesis. *J Shoulder Elbow Surg* 2014;23(7):1059-65. <https://doi.org/10.1016/j.jse.2013.09.030>
14. Denard PJ, Lädermann A, Parsley BK, Burkhart SS. Arthroscopic biceps tenodesis compared with repair of isolated type II SLAP lesions in patients older than 35 years. *Orthopedics* 2014;37(3):e292-7. <https://doi.org/10.3928/01477447-20140225-63>
15. Hurley ET, Lorentz NA, Colasanti CA, Campbell KA, Alaia MJ, et al. Open subpectoral biceps tenodesis may be an alternative to arthroscopic repair for SLAP tears in patients under 30. *Arthroscopy* 2022;38(2):307-12. <https://doi.org/10.1016/j.arthro.2021.07.028>
16. Werner BC, Evans CL, Holzgrefe RE, Tuman JM, Hart JM, et al. Arthroscopic suprapectoral and open subpectoral biceps tenodesis: a comparison of minimum 2-year clinical outcomes. *Am J Sports Med* 2014;42(11):2583-90. <https://doi.org/10.1177/0363546514547226>
17. Jarrett CD, McClelland WB Jr, Xerogeanes JW. Minimally invasive proximal biceps tenodesis: an anatomical study for optimal placement and safe surgical technique. *J Shoulder Elbow Surg* 2011;20(3):477-80. <https://doi.org/10.1016/j.jse.2010.08.002>
18. Pogorzelski J, Horan MP, Hussain ZB, Vap A, Fritz EM, Millett PJ. Subpectoral biceps tenodesis for treatment of isolated type II SLAP lesions in a young and active population. *Arthroscopy* 2018;34(2):371-6. <https://doi.org/10.1016/j.arthro.2017.07.021>

19. Provencher MT, McCormick F, Peebles LA, Beaulieu-Jones BR, Dekker TJ, LeClere LE, et al. Outcomes of primary biceps subpectoral tenodesis in an active population: A prospective evaluation of 101 patients. *Arthroscopy* 2019;35(12):3205-10. <https://doi.org/10.1016/j.arthro.2019.06.035>
20. Hsu AR, Ghodadra NS, Provencher MT, Lewis PB, Bach BR. Biceps tenotomy versus tenodesis: a review of clinical outcomes and biomechanical results. *J Shoulder Elbow Surg* 2011;20(2):326-32. <https://doi.org/10.1016/j.jse.2010.08.019>
21. The B, Brutty M, Wang A, Campbell PT, Halliday MJC. Long-term functional results and isokinetic strength evaluation after arthroscopic tenotomy of the long head of biceps tendon. *Int J Shoulder Surg* 2014;8(3):76-80. <https://doi.org/10.4103/0973-6042.140114>