

# Case Resolution

**Rodrigo Re**

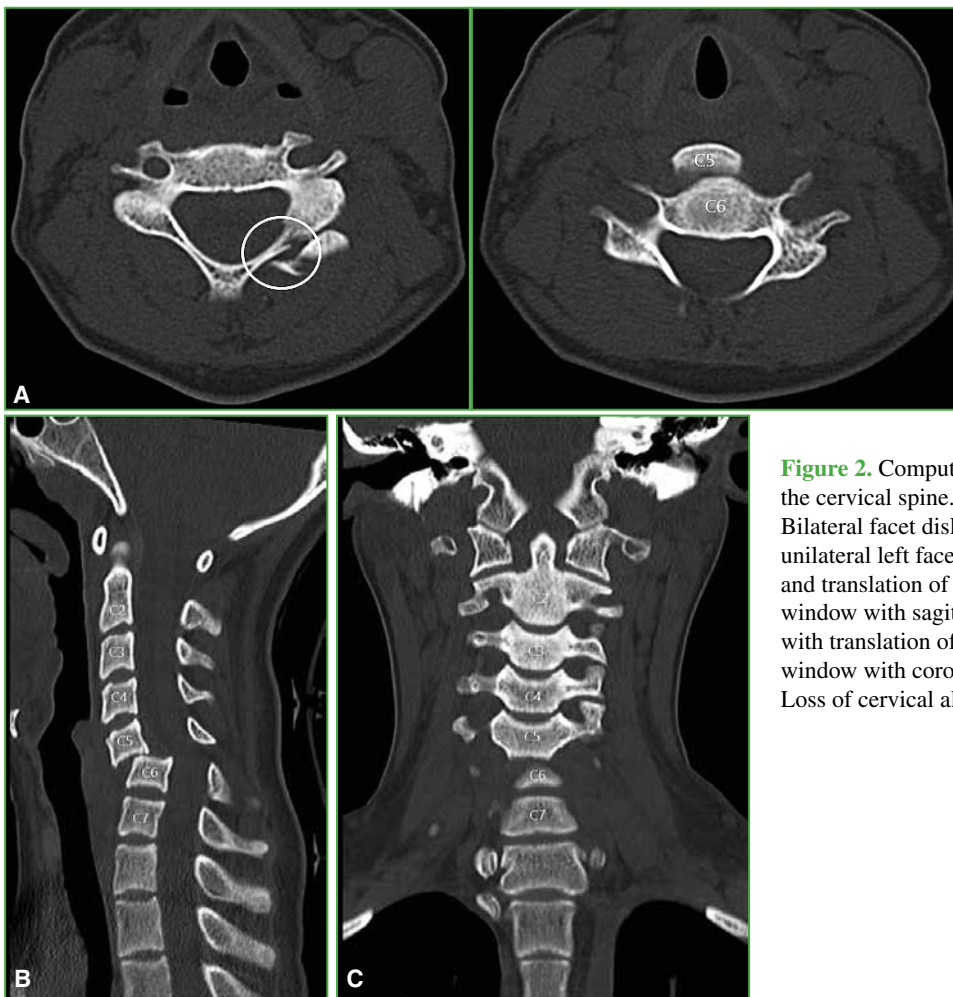
*Diagnostic Imaging Service, Osteoarticular/Musculoskeletal Area - Interventionism, Sanatorio Allende, Córdoba, Argentina*

*Case presentation on page 142.*

**DIAGNOSIS:** C5-C6 fracture-dislocation.

## DISCUSSION

In the computed tomography of the cervical spine (Figure 2) in the bone window with axial acquisition and sagittal and coronal reconstruction, an anterolisthesis of C5-C6 with bilateral facet dislocation and a left unilateral facet fracture was visualized.

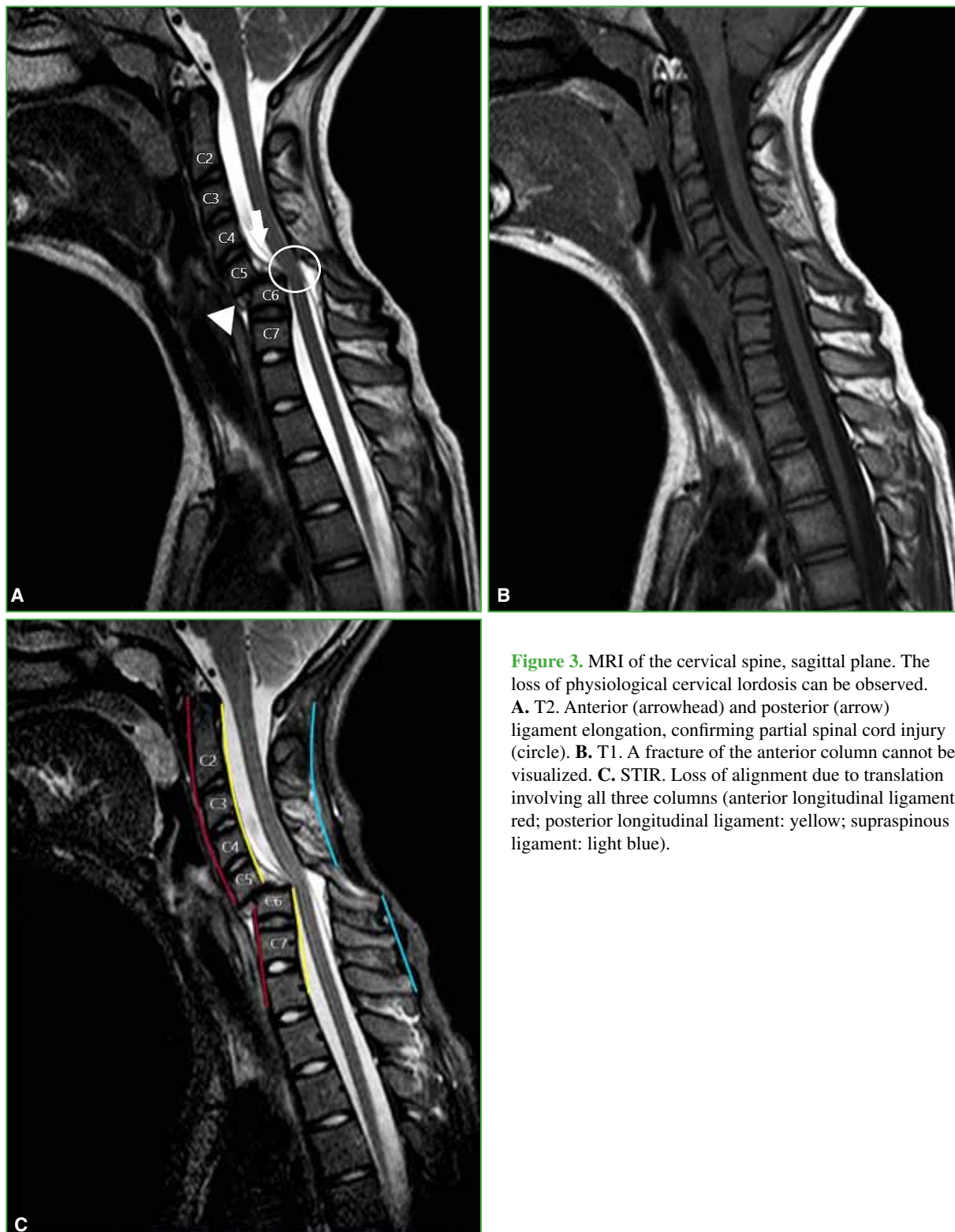


**Figure 2.** Computed tomography of the cervical spine. **A.** Axial planes. Bilateral facet dislocation with unilateral left facet fracture (circle) and translation of C5-C6. **B.** Bone window with sagittal reconstruction with translation of C5-C6. **C.** Bone window with coronal reconstruction. Loss of cervical alignment.

Dr. RODRIGO RE • rodrigo\_re@hotmail.com  <https://orcid.org/0000-0001-7382-9459>

**How to cite this article:** Re R. Postgraduate Orthopedic Instruction - Imaging. Case Resolution. *Rev Asoc Argent Ortop Traumatol* 2022;87(2):299-302. <https://doi.org/10.15417/issn.1852-7434.2022.87.2.1524>

The MRI of the cervical spine (Figure 3) included images in the sagittal plane in the T2-weighted, T1-weighted, and STIR sequences, where the loss of physiological cervical lordosis and the anterior and posterior ligament elongation continued to be seen, and partial spinal cord injury was confirmed.



**Figure 3.** MRI of the cervical spine, sagittal plane. The loss of physiological cervical lordosis can be observed. **A.** T2. Anterior (arrowhead) and posterior (arrow) ligament elongation, confirming partial spinal cord injury (circle). **B.** T1. A fracture of the anterior column cannot be visualized. **C.** STIR. Loss of alignment due to translation involving all three columns (anterior longitudinal ligament: red; posterior longitudinal ligament: yellow; supraspinous ligament: light blue).

## DIAGNOSIS

With all these findings, a C5-C6 fracture-dislocation was diagnosed.

Bilateral facet fracture-dislocation is one of the most severe and unstable spinal injuries. It is more frequent in C5-C6 due to a flexion and compression mechanism. It can present in isolation as a unilateral or bilateral dislocation, or be accompanied by fracture of the facets or the vertebral body with compromise of the anterior column. Imaging evaluation is important in order to schedule the corresponding treatment.

Traumatic cervical injuries account for 5-10% of all traumatic injuries and carry a high rate of morbidity and mortality, due to the fact that several vital structures can be damaged. It usually affects young people. The most common causes of traumatic spinal cord injury are traffic accidents and falls from heights. They can present with fractures, dislocations, and vertebral crushing, with secondary invasion of the spinal canal or spinal cord injury.

The neurological evaluation of the patient according to the algorithm proposed by the *American Spinal Injury Association* and the *International Spinal Cord Society* (ASIA/ISCoS) is very important, as well as describing the morphology, neurological status, and modifiers according to the *AOSpine Subaxial Cervical Spine Injury Classification*, which is the most widespread system today.

The algorithm proposed by the ASIA/ISCoS includes the assessment of strength and sensitivity below the level of the injury with the estimation of the degree of neurological impairment according to the impairment scale (*ASIA/ISCoS Impairment Scale*). The ASIA impairment scale includes five possible degrees: A (complete impairment of sensation and strength below the level of injury), B (incomplete impairment of sensation with total loss of strength below the level of injury), C (incomplete impairment of motor function and preservation of sensation below the level of injury. More than half of the muscle groups show severe weakness), D (incomplete motor impairment and preservation of sensation below the level of injury. Less than half of the muscle groups show severe weakness), and E (no impairment of strength or sensitivity below the level of injury).

The classification system proposed by AOSpine includes three types of fractures according to their morphology: A) Compression, fracture of the body without ligament compromise; B) Distraction: failure of the anterior or posterior tension band. There may be an associated type A vertebral body fracture and C) Displacement (subluxation/luxation) in one or more spatial planes.

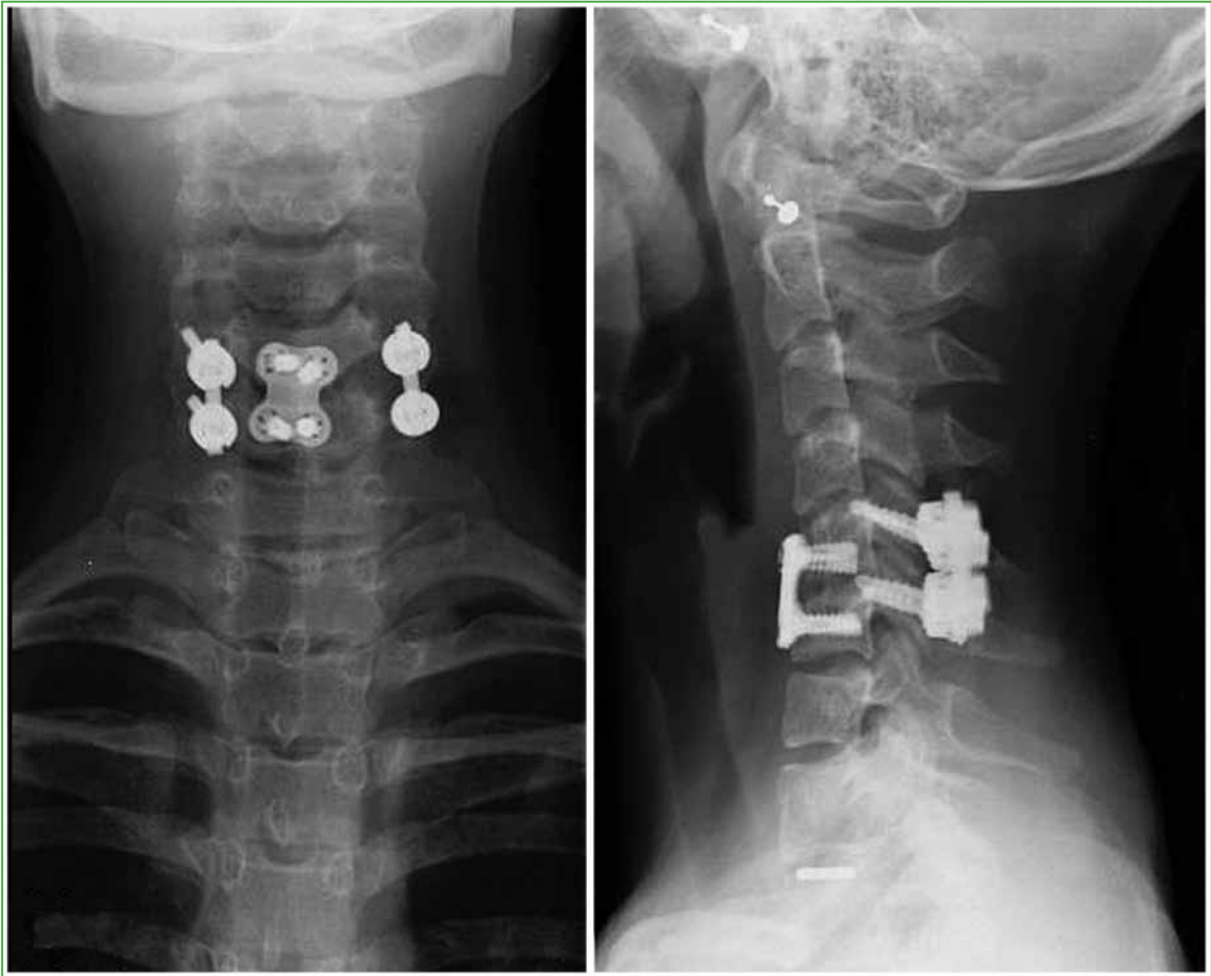This classification system also includes the assessment of the neurological status, the facet lesion, and the presence of modifiers. It classifies the neurological status into six subtypes: N0 (no neurological injury), N1 (transient neurological deficit), N2 (radiculopathy), N3 (incomplete spinal cord injury), N4 (complete spinal cord injury), and NX (unknown neurological status due to sedation, severe trauma, or intoxication).

It describes four possible subtypes of unilateral or bilateral facet injury: F1, facet fracture without displacement; F2, potentially unstable facet fracture; F3, floating lateral mass; and F4, facet subluxation/dislocation or perched (or mounted) facet.

Modifiers are clinical features that can change therapeutic decision-making; in the cervical spine, they include the following: M1, incomplete lesion of the posterior capsuloligamentous complex; M2, critical disc herniation; M3, metabolic disease/stiffness (diffuse idiopathic skeletal hyperostosis, ankylosing spondylitis, ossification of the posterior longitudinal ligament, ossification of the ligamentum flavum); and M4, vertebral artery anomaly.

The patient's initial neurological status was ASIA C. The fracture was interpreted as type C C5-C6 with dislocation of both articular facets and unilateral facet fracture. According to the nomenclature, it was described as C5-C6: C (bilateral F4; N3).

Surgery was considered due to the high instability of the lesion. Anterior and posterior arthrodesis of C5-C6 was performed (Figure 4).



**Figure 4.** Anteroposterior and lateral radiograph of the cervical spine. Immediate postoperative control of the anterior and posterior arthrodesis of C5-C6.