

Glenohumeral Bone Defects: A Review of the Diagnostic and Therapeutic Advances Over the Last 20 Years

Alejandro Mejía-Grueso, Daniela Gutiérrez-Zúñiga, Nicolle Visbal-Otero, Felipe Valbuena-Bernal

Department of Orthopedics and Traumatology, Hospital Universitario San Ignacio. Pontificia Universidad Javeriana, Bogota, Colombia

ABSTRACT

Introduction: The approach and treatment of glenohumeral bone defects have evolved intending to provide more individualized management for patients. However, to date, there are no articles that compile these historical advances. **Objective:** To describe the most relevant literature on the diagnostic analysis and therapeutic options for glenohumeral bone defects reported in the last 20 years. **Materials and Methods:** A search was conducted in the PubMed database with the terms “Glenoid defect,” “Humeral defect,” “Shoulder instability” and “Glenoid track,” filtered by year from 2000 to 2021. Studies published in English and Spanish, involving adult patients, were included. **Results:** We reviewed a total of 56 articles. A narrative chronological review of the approach to glenohumeral bone defects in anterior instability was performed. **Conclusions:** Technological advances have allowed the development of evaluation and management algorithms aimed at achieving the best outcomes according to the characteristics of each patient. To date, the current literature recommends surgical treatment of instability based on the objective measurement of glenohumeral bone defects, for which arthroscopy and 3D reconstruction tomography offer the most accurate quantification.

Keywords: Glenohumeral bone defects; shoulder instability; glenoid track; Hill-Sachs lesions.

Level of Evidence: IV. Narrative review

Defectos óseos glenohumerales: Un recorrido en los avances diagnósticos y terapéuticos durante los últimos 20 años

RESUMEN

Introducción: El abordaje y el tratamiento de los defectos óseos glenohumerales han evolucionado en miras de brindar un manejo más individualizado para los pacientes. Sin embargo, hasta la fecha, no existen artículos que recopilen dichos avances históricos. **Objetivo:** Describir la bibliografía más relevante sobre el análisis diagnóstico y las opciones terapéuticas de los defectos óseos glenohumerales en los últimos 20 años. **Materiales y Métodos:** Se realizó una búsqueda en la base de datos PubMed con los términos “Glenoid defect,” “Humeral defect,” “Shoulder instability” y “Glenoid track,” filtrada por año desde 2000 hasta 2021. Se incluyeron estudios publicados en inglés y español, de pacientes adultos.

Resultados: En la búsqueda, se revisaron 56 artículos según los criterios planteados. Se llevó a cabo una revisión narrativa cronológica sobre el abordaje de los defectos óseos glenohumerales en inestabilidad anterior. **Conclusiones:** Los avances tecnológicos han permitido desarrollar algoritmos de evaluación y manejo dirigidos a lograr los mejores desenlaces según las características de cada paciente. La bibliografía actual recomienda el tratamiento quirúrgico basado en la medición objetiva de los defectos óseos glenohumerales, para lo cual la artroscopia y la tomografía con reconstrucción 3D ofrecen la cuantificación más acertada.

Palabras clave: Defectos óseos glenohumerales; inestabilidad del hombro; pista glenoidea; lesiones de Hill-Sachs.

Nivel de Evidencia: IV Revisión narrativa

INTRODUCTION

The wide range of motion of the glenohumeral joint occurs at the expense of a demand on multiple mechanisms to preserve joint stability. Different dynamic and static components are essential to preserve joint congruence and, in this way, make movement effective in the different planes. The bony static components involve the

Received on February 14th, 2022. Accepted after evaluation on July 2nd, 2022. • Dr. ALEJANDRO MEJÍA-GRUESO • amejiag.ortopedia@gmail.com  <https://orcid.org/0000-0001-8926-9724>

How to cite this article: Mejía-Grueso A, Gutiérrez-Zúñiga D, Visbal N, Valbuena F. Glenohumeral Bone Defects: A Review of the Diagnostic and Therapeutic Advances Over the Last 20 Years. *Rev Asoc Argent Ortop Traumatol* 2022;87(4):570-578. <https://doi.org/10.15417/issn.1852-7434.2022.87.4.1518>

humeral head that articulates with a glenoid fossa that is comparatively smaller, concave, and shallow. At rest, the concavity-compression effect secondary to negative intra-articular pressure is the main stabilizing factor of the joint. Other stabilizers, known as the dynamic stabilizers, including the capsule, the glenohumeral ligaments, and the rotator cuff, are important in varying degrees of motion. From the bone point of view, the characteristics of the glenoid fossa, specifically its depth, its width and its version, as well as the position of the scapula, can alter joint stability.¹

In the 16th century, Ambroise Paré, considered the father of modern surgery, described glenohumeral dislocations and considered those associated with fractures to be complex.² Nowadays, it is known that, in episodes of acute dislocation and its recurrences, bone injuries can be generated either by fractures, by loss due to attrition, or by impaction both at the glenoid and humeral levels.³ These are known as glenohumeral bone defects, which have an impact on therapeutic decision-making when approaching a patient with shoulder instability.

The analysis of glenohumeral bone defects has been the subject of study and debate in shoulder surgery for the last 20 years, changing as arthroscopic techniques and imaging studies have evolved. This has enabled modifications in treatment and its postoperative outcomes. In this narrative review, we present the most relevant literature in sections divided by five-year periods.

2000-2005 A NEW MILLENNIUM BEGINS

In 2000, Burkhart and De Beer published one of the most relevant articles on glenohumeral instability.⁴ In an analysis of cases of traumatic glenoid defects and their relationship with therapeutic failure using Bankart surgery, they established that arthroscopic Bankart surgery obtains the same outcomes as open surgery if there are no glenoid bone defects. These findings were initially described as “inverted pear” due to their arthroscopic appearance. In addition, they described, for the first time, humeral defects as significant Hill-Sachs lesions if they generate engagement with the anterior rim of the glenoid in a functional athletic position (abduction of 90° combined with external rotation from 0 to 135°). They proposed treatment with capsular shift or humeral osteotomy and considered that glenoid defects required bone grafts to recover stability, that the procedure of transferring the coracoid to the anterior rim of the glenoid, better known as the Latarjet procedure, was preferred.⁵

Later, in 2002, the same authors suggested an arthroscopic method to establish a more precise quantification of glenoid defects.⁶ In the same year, when studying patients with Bankart lesions with a bone component, Porcellini et al. found that arthroscopic fixation with anchors in defects of less than 25% allowed return to sport in 92% of patients.⁷ In 2004, using the arthroscopic method of quantification of Burkhart defects, Lo et al. noted that the “inverted pear” shape requires a bone loss of at least 25-27% of the inferior glenoid, and for its treatment, they recommended bone grafts in order to restore the anatomy.⁸

2006-2010 THE YEARS OF GREATEST FRENCH INFLUENCE

In 2007, in France, Boileau, after carrying out a study to identify risk factors for recurrence with Bankart surgery,^{9,10} published the ISIS score (Instability Severity Index Score), which takes into account factors such as age, sports participation and the type of sport, as well as characteristics in conventional radiography of bone defects and ligament hyperlaxity.¹¹ Since then, the ISIS score has become one of the most used tools for making therapeutic decisions between Bankart-type arthroscopic surgeries or open procedures, such as Latarjet surgery, to prevent recurrence of instability.

Likewise, in 2007, Yamamoto introduced the concept of the “glenoid track”, analyzing the contact area between the humeral head and the glenoid in different abduction positions, in a cadaveric study. The glenoid track corresponds to 84% of the glenoid surface, if there are no bone defects. This author concluded that defects in the humeral head can engage with the anterior rim of the glenoid with movements of the shoulder in flexion and abduction, when the humeral defect extends medially over the medial margin of the track.¹²

After proposing the arthroscopic measurement technique in 2002, Chuang exposes, in 2007, a method for the pre-surgical quantification of glenoid defects by means of computed tomography with three-dimensional reconstruction (3D CT).¹³ One year later, using multiplanar reconstruction tomography and quantitative analysis, d’Elia et al. recommended bone grafting procedures for defects greater than 20%.¹

In 2009, in a cadaveric study to calculate the defects that cause instability, Yamamoto and Itoi found that defects located in the anterior portion of the glenoid of 6 mm, equivalent to 20%, generate significant anterior instability.¹⁴ Bollier and Arciero published an algorithm and set a 20% limit to indicate Latarjet surgery.¹⁵

During the same year, when making a synthesis of the evidence available up to that moment, Provencher proposed an algorithm calculating the defects with preoperative 3D CT or arthroscopic evaluation (Figure). Defects <15% in the glenoid are not significant, while those >30% are indicated for bone augmentation with grafting or Latarjet surgery. For the gray zone located between 15% and 30%, which would later be defined as “subcritical defects”, it is proposed to consider the clinical characteristics of the patient in terms of their functional demand and sports practice.¹⁶

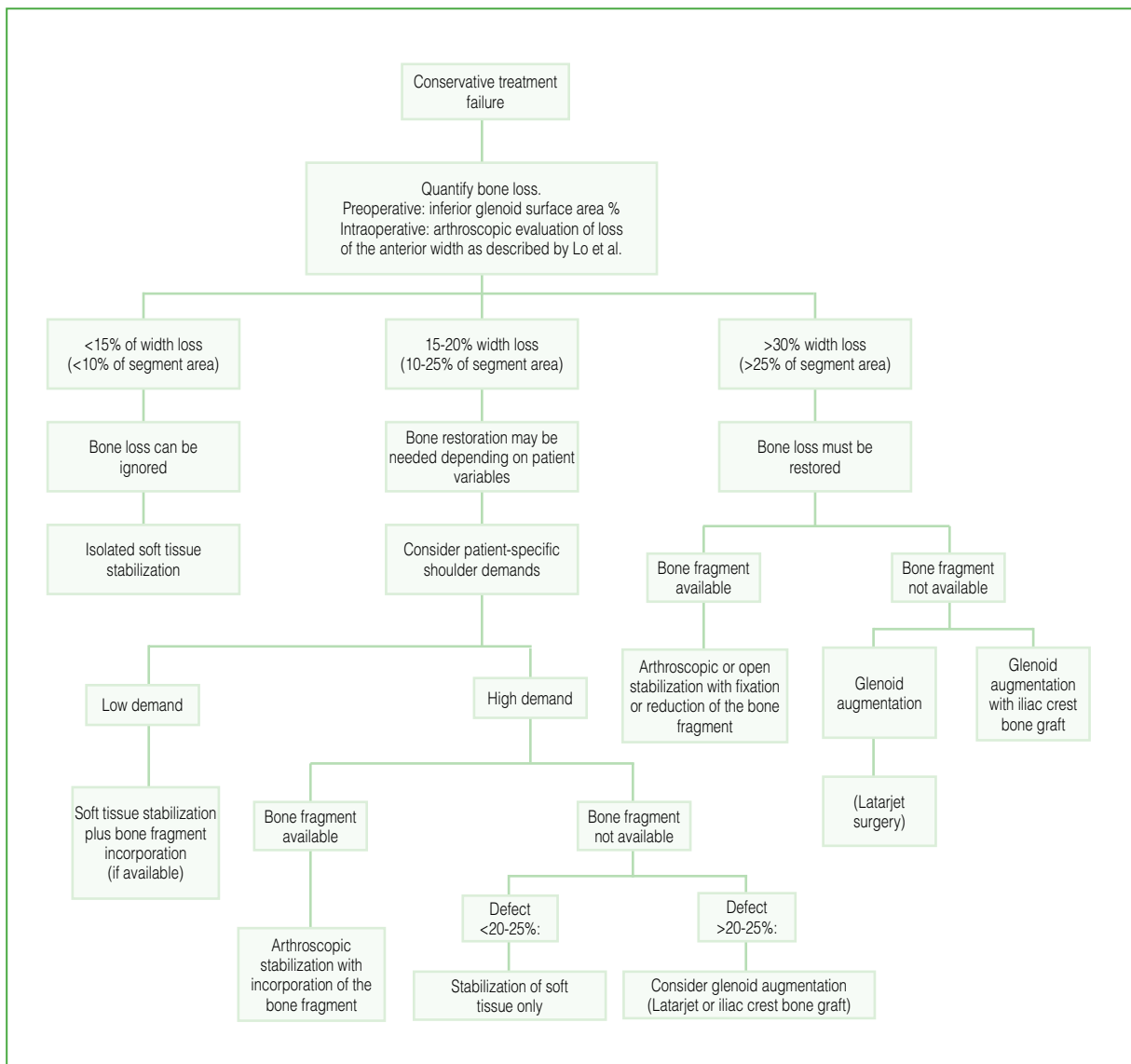


Figure. Algorithm for the surgical management of glenoid bone loss. Adapted from: Piasecki DP, Verma NN, Romeo AA, Levine WN, Bach BR Jr., Provencher MT. Glenoid bone deficiency in recurrent anterior shoulder instability: Diagnosis and management. *J Am Acad Orthop Surg* 2009;17(8):482-93.

2011- 2015 THE IMPORTANCE OF ENGAGEMENT ON OR OFF THE TRACK

In 2011, Bhatia carried out a systematic review of level I evidence studies, and proposed 25% as the limiting defect for recommending bone procedures. In this publication, he stressed the importance of quantifying the defects and taking into account the age and sports participation of the patients when choosing the type of surgery, especially with borderline defects.¹⁷ Focusing on the analysis of Hill-Sachs injuries, in a biomechanical study in 2012, Guiles compared surgical alternatives for the treatment of humeral defects such as *remplissage* (filling of the Hill-Sachs bone defect with capsule and infraspinatus tendon), resurfacing, and the use of allografts. He showed that all procedures are effective in improving stability, with the exception that *remplissage* decreases external rotation.¹⁸ In an analysis of Hill-Sachs lesions, Provencher defined them as frequent lesions that require a study of their size, orientation, and other concomitant glenoid or capsulolabral lesions. He indicated that humeral defects >30% merit surgical management with combined procedures, such as arthroplasty, allografts, *remplissage*, and resurfacing.¹⁹

A few years later, in a study of 100 patients with instability, Kurokawa established the prevalence of Hill-Sachs lesions was 94% and that 7% of them had medial extension with respect to the glenoid track.²⁰ In 2013, Metzger published a clinical study to apply the concept of the glenoid track explained in cadaveric studies by Yamamoto et al. As a result, he noted that 13% of patients with instability and Hill-Sachs injury are at risk of injury engagement with bipolar injuries off the glenoid track. 85% of these patients show functional engagement on examination under anesthesia. This engagement can be predicted before surgery with precise measurements on diagnostic images and is related to the patient's age and recurrence episodes. He stressed the importance of evaluating the lesions in a bipolar way, considering that bone defects at the glenoid and humeral levels are enhanced, increasing the risk of recurrence.²¹ In the middle of this same year, in a comparative study between the different imaging options for the study of glenohumeral bone defects, Bishop et al. stated that 3D CT is the most reliable study to quantify glenoid defects.²²

In 2014, Di Giacomo et al. synthesized previously established concepts, looking for an arthroscopic and radiological way to analyze bipolar lesions and quantify humeral defects to predict their engagement at the glenoid level. With this method, the engaged lesion is called an off-track Hill-Sachs injury, according to its size and whether its medial margin is more internal than the glenoid track, which generates a lack of bone support to the injury. Based on this quantification, they created a treatment paradigm, categorizing the findings in four types of patients, according to glenoid defects (< or >25%) and type of Hill-Sachs lesion (on-track vs. off-track) (Tables 1 and 2). Based on this categorization, the therapeutic decision is proposed, ranging from arthroscopic Bankart surgery to Latarjet surgery. The authors' recommendation is to convert Hill-Sachs injuries from off-track to on-track, with procedures such as bone grafting or *remplissage* to restore stability.²³

Later, in 2015, Shaha et al. conducted a study on a military population and found that <20% defects treated with Bankart stabilization may have poor functional outcomes. Based on a quartile analysis of bone loss, they defined defects >13.5% as "subcritical" in the active population with high functional demand.²⁴ This concept of subcritical defects calls into question the previous limit of 20% for recommending bone stabilization procedures and highlights the need to assess the patient's functional environment and sports demand. This would be reconsidered by the group of Yamamoto et al. in 2019, who, when evaluating a civilian population of young athletes or patients with high functional demand, defined a subcritical glenoid bone loss as that between 17% and 25%.²⁵

Table 1. Anterior instability categories

Group	Glenoid defect	Hill-Sachs lesion
1	<25%	On-track
2	<25%	Off-track
3	≥25%	On-track
4	≥25%	Off-track

Adapted from: Di Giacomo G, Itoi E, Burkhart SS. Evolving concept of bipolar bone loss and the Hill-Sachs lesion: From “engaging/non-Engaging” lesion to “on-track/off-track” lesion. *Arthroscopy* 2014;30(1):90-8.

Table 2. Treatment paradigm

Group	Recommended treatment
1	Arthroscopic Bankart repair
2	Arthroscopic Bankart repair plus <i>remplissage</i>
3	Latarjet surgery
4	Latarjet surgery with or without humeral procedures (humeral bone grafting or <i>remplissage</i>) depending on the engagement of the Hill-Sachs lesion after the Latarjet procedure.

Adapted from: Di Giacomo G, Itoi E, Burkhart SS. Evolving concept of bipolar bone loss and the Hill-Sachs lesion: From “engaging/non-Engaging” lesion to “on-track/off-track” lesion. *Arthroscopy* 2014;30(1):90-8.

2016-2021 THE NON-FRENCH INFLUENCE TIPS THE BALANCE

As of 2016, two studies focused on evaluating the association of bone defects measured on imaging with the natural evolution of instability and its clinical-functional impact. McNeil et al. performed an analysis of glenoid bone loss from attrition, and found that it increased along the duration of instability symptoms.²⁶ For their part, Wolke et al. found a relationship between imaging findings and bone loss quantified with functional scores for specific scales of shoulder function and quality of life (WOSI, Rowe, SSV).²⁷ Three years later, Dickens published one of the first studies evaluating the impact of the natural evolution of shoulder instability on bone defects. In it, he identified that, after the first episode of dislocation, a bone loss of 6.8% can be generated in the anterior rim of the glenoid. Considering the impact of bone defects on instability, the study suggested considering early surgical stabilization in a young, athletic population.²⁸

As of 2017, several authors questioned the reliability of tomographic or arthroscopic measurement strategies for bone defects. Moroder et al. stated that there was a lack of standardization of protocols for taking and measuring tomographic images to quantify glenoid defects.²⁹ Later, in 2019, Funakoshi explained that there was a discrepancy between calculations of bipolar defects in surgical planning with tomography and intraoperative findings by arthroscopy.³⁰ For their part, after a systematic literature review, Gowd et al. detected an inconsistency in the analysis of Hill-Sachs lesions, observing that only 3.2% of the studies quantify humeral defects.³¹ In 2019, Yamamoto introduced the new concept of on-track injuries. In his analysis, he divided the glenoid track into four zones. According to the authors, peripheral Hill-Sachs lesions, which take up more than 75% of the glenoid track, have worse functional outcomes.³²

At the end of 2020, a fundamental study on changing understanding and therapeutic decisions in shoulder instability was published. Complementing the Boileau current given by the ISIS scale with the concept of the glenoid track, Di Giacomo et al. proposed the GTIMS (*Glenoid Track Instability Management Score*) (Table 3), a new treatment algorithm that combines the concept of the glenoid track with the risk factors of the ISIS scale, using advanced tomography images. With this new instrument, a more conservative treatment indication is obtained than with the ISIS score, which recommends twice as many Latarjet surgeries, with equally satisfactory clinical outcomes.³³

Table 3. GTIMS (*Glenoid Track Instability Management Score*)

GTIMS prognostic factors	Score
Age at the time of surgery (years)	
≤20 years	2
>20 years	0
Sport type	
Contact or overhead	1
Other	0
Level of sports competition	
Competitive	2
Recreational/none	0
Shoulder hypermobility	
Confirmed anterior or inferior hypermobility	1
Normal mobility	0
Evaluation of bone loss in 3D tomography	
On-track	0
Off-track	4
Total GTIMS	10

Adapted from: Di Giacomo G, Peebles LA, Pugliese M, Dekker TJ, Golijanin P, Sanchez A, et al. Glenoid track instability management score: Radiographic modification of the Instability Severity Index Score. *Arthroscopy* 2020;36(1):56-67.

Also in 2020, Rossi et al. published an expert consensus using the Delphi technique on the management of glenohumeral instability with associated bone loss. The consensus concluded that a history of recurrent instability and failed soft tissue surgery makes it necessary to suspect bone defects. In addition, according to the experts, the image of choice for their study is 3D CT using the “en face” view as the most accurate method for measuring the glenoid. In contrast to this, they pointed out that Hill-Sachs lesions, even to this date, are poorly quantified and classified. Finally, they recommended the bone stabilization procedure for glenoid defects >20%.³⁴

Finally, Yamamoto and Itoi enunciated the concept of the central track or peripheral track, subdividing the glenoid track into four zones that include the Hill-Sachs occupation of the track. For on-track injuries at the level of its central configuration, they proposed treatment with Bankart arthroscopic surgery, given the low probability of being engaged. Unlike what happens with on-track defects within the peripheral portion, if the patient is a contact athlete, stabilization with Latarjet surgery or *remplissage* is recommended. On the other hand, if he or she performs

any non-contact sports practice, arthroscopic stabilization with Bankart surgery is recommended. This recommendation is based on the worse results on the WOSI scale without recurrent instability in patients with peripheral lesions within the glenoid track (occupation $\geq 75\%$ of the glenoid track).³²

CONCLUSIONS

Shoulder dislocations can lead to glenohumeral bone defects that are associated with significant symptoms of instability. During the last two decades, many authors have made significant contributions to these defects, which have allowed them to modify both the approach to patients, as well as the therapeutic options and their postoperative outcomes. Currently, we know that 3D CT and arthroscopy are essential tools for the evaluation of bone defects, although there is still no perfect method to quantify them. Likewise, the introduction of the categorization of Hill-Sachs lesions as on-track or off-track gives us a treatment paradigm to guide surgical therapeutic decisions. In general, all the contributions point to a common idea, in which it is concluded that the treatment must be oriented in a holistic and individual way for each patient, according to their age, functional environment, sports demand, and glenohumeral bone defect.

Finally, the evolutionary path has not been entirely easy, it presented contrasts between important currents, such as the case of the French school that defends Latarjet surgery, which has been attacked by the American influence. The current literature leans toward treatment directed by objective measurement of glenoid defects, and there is a trend toward specialized diagnosis and treatment.

Conflict of interest: The authors declare no conflicts of interest.

D. Gutiérrez-Zúñiga ORCID ID: <https://orcid.org/0000-0001-6852-0350>
N. Visbal ORCID ID: <https://orcid.org/0000-0003-1766-4500>

F. Valbuena ORCID ID: <https://orcid.org/0000-0002-1993-3797>

REFERENCES

1. d'Elia G, Di Giacomo A, D'Alessandro P, Cirillo LC. Traumatic anterior glenohumeral instability: quantification of glenoid bone loss by spiral CT. *Radiol Med* 2008;113(4):456-503. <https://doi.org/10.1007/s11547-008-0274-5>
2. Markatos K, Tzivra A, Tsoutsos S, Tsouroufflis G, Karamanou M, Androutsos G. Ambroise Paré (1510-1590) and his innovative work on the treatment of war injuries. *Surg Innov* 2018;25(2):183-6. <https://doi.org/10.1177/1553350617744901>
3. Itoi E, Yamamoto N, Kurokawa D, Sano H. Bone loss in anterior instability. *Curr Rev Musculoskelet Med* 2013;6(1):88-94. <https://doi.org/10.1007/s12178-012-9154-7>
4. Burkhart SS, De Beer JF. Traumatic glenohumeral bone defects and their relationship to failure of arthroscopic Bankart repairs: Significance of the inverted-pear glenoid and the humeral engaging Hill-Sachs lesion. *Arthroscopy* 2000;16(7):677-94. <https://doi.org/10.1053/jars.2000.17715>
5. Latarjet M. A propos du traitement des luxations récidivantes de l'épaule, *Lyon Chit* 1954;49:994-1003.
6. Burkhart SS, De Beer JF, Tehrany AM, Parten PM. Quantifying glenoid bone loss arthroscopically in shoulder instability. *Arthroscopy* 2002;18(5):488-91. <https://doi.org/10.1053/jars.2002.32212>
7. Porcellini G, Campi F, Paladini P. Arthroscopic approach to acute bony Bankart lesion. *Arthroscopy* 2002;18(7):764-9. <https://doi.org/10.1053/jars.2002.35266>
8. Lo IK, Parten PM, Burkhart SS. The inverted pear glenoid: an indicator of significant glenoid bone loss. *Arthroscopy* 2004;20(2):169-74. <https://doi.org/10.1016/j.arthro.2003.11.036>
9. Caspari RB, Savoie FH. Arthroscopic reconstruction of the shoulder: The Bankart repair. En: McGinty JB (ed). *Operative arthroscopy*. New York: Raven Press; 1991:507-15.
10. Morgan CD, Bodenstab AB. Arthroscopic Bankart suture repair: Technique and early results. *Arthroscopy* 1987;3(2):111-22. [https://doi.org/10.1016/s0749-8063\(87\)80027-0](https://doi.org/10.1016/s0749-8063(87)80027-0)

11. Balg F, Boileau P. The instability severity index score. A simple pre-operative score to select patients for arthroscopic or open shoulder stabilisation. *J Bone Joint Surg Br* 2007;89(11):1470-7. <https://doi.org/10.1302/0301-620X.89B11.18962>
12. Yamamoto N, Itoi E, Abe H, Minagawa H, Seki N, Shimada Y, et al. Contact between the glenoid and the humeral head in abduction, external rotation, and horizontal extension: A new concept of glenoid track. *J Shoulder Elbow Surg* 2007;16(5):649-56. <https://doi.org/10.1016/j.jse.2006.12.012>
13. Chuang TY, Adams CR, Burkhart SS. Use of preoperative three-dimensional computed tomography to quantify glenoid bone loss in shoulder instability. *Arthroscopy* 2008;24(4):376-82. <https://doi.org/10.1016/j.arthro.2007.10.008>
14. Yamamoto N, Itoi E, Abe H, Kikuchi K, Seki N, Minagawa H, et al. Effect of an anterior glenoid defect on anterior shoulder stability: A cadaveric study. *Am J Sports Med* 2009;37(5):949-54. <https://doi.org/10.1177/0363546508330139>
15. Bollier MJ, Arciero R. Management of glenoid and humeral bone loss. *Sports Med Arthrosc Rev* 2010;18(3):140-8. <https://doi.org/10.1097/JSA.0b013e3181e88ef9>
16. Piasecki DP, Verma NN, Romeo AA, Levine WN, Bach BR Jr., Provencher MT. Glenoid bone deficiency in recurrent anterior shoulder instability: Diagnosis and management. *J Am Acad Orthop Surg* 2009;17(8):482-93. <https://doi.org/10.5435/00124635-200908000-00002>
17. Bhatia S, Ghodadra NS, Romeo AA, Bach BR, Verma NN, Vo ST, Provencher MT. The importance of the recognition and treatment of glenoid bone loss in an athletic population. *Sports Health* 2011;3(5):435-40. <https://doi.org/10.1177/1941738111414126>
18. Giles JW, Elkinson I, Ferreira LM, Faber KJ, Boons H, Litchfield R, et al. Moderate to large engaging Hill-Sachs defects: An in vitro biomechanical comparison of the remplissage procedure, allograft humeral head reconstruction, and partial resurfacing arthroplasty. *J Shoulder Elbow Surg* 2012;21(9):1142-51. <https://doi.org/10.1016/j.jse.2011.07.017>
19. Provencher MT, Frank RM, Leclere LE, Metzger PD, Ryu JJ, Bernhardson A, et al. The Hill-Sachs lesion: diagnosis, classification, and management. *J Am Acad Orthop Surg* 2012;20(4):242-52. <https://doi.org/10.5435/JAAOS-20-04-242>
20. Kurokawa D, Yamamoto N, Nagamoto H, Omori Y, Tanaka M, Sano H, et al. The prevalence of a large Hill-Sachs lesion that needs to be treated. *J Shoulder Elbow Surg* 2013;22(9):1285-9. <https://doi.org/10.1016/j.jse.2012.12.033>
21. Metzger PD, Barlow B, Leonardelli D, Peace W, Solomon DJ, Provencher MT. Clinical application of the “glenoid track” concept for defining humeral head engagement in anterior shoulder instability: A preliminary report. *Orthop J Sports Med* 2013;1(2):1-7. <https://doi.org/10.1177/2325967113496213>
22. Bishop JY, Jones GL, Rerko MA, Donaldson C. 3-D CT is the most reliable imaging modality when quantifying glenoid bone loss. *Clin Orthop Relat Res* 2013;471(4):1251-6. <https://doi.org/10.1007/s11999-012-2607-x>
23. Di Giacomo G, Itoi E, Burkhart SS. Evolving concept of bipolar bone loss and the Hill-Sachs lesion: From “engaging/non-engaging” lesion to “on-track/off-track” lesion. *Arthroscopy* 2014;30(1):90-8. <https://doi.org/10.1016/j.arthro.2013.10.004>
24. Shaha JS, Cook JB, Song DJ, Rowles DJ, Bottoni CR, Shaha SH, et al. Redefining “critical” bone loss in shoulder instability: functional outcomes worsen with “subcritical” bone loss. *Am J Sports Med* 2015;43(7):1719-25. <https://doi.org/10.1177/0363546515578250>
25. Yamamoto N, Kawakami J, Hatta T, Itoi E. Effect of subcritical glenoid bone loss on activities of daily living in patients with anterior shoulder instability. *Orthop Traumatol Surg Res* 2019;105(8):1467-70. <https://doi.org/10.1016/j.otsr.2019.08.015>
26. McNeil JW, Beaulieu-Jones BR, Bernhardson AS, LeClere LE, Dewing CB, Lynch JR, et al. Classification and analysis of attritional glenoid bone loss in recurrent anterior shoulder instability. *Am J Sports Med* 2016;45(4):767-74. <https://doi.org/10.1177/0363546516677736>
27. Wolke J, Herrmann DA, Krannich A, Scheibel M. Influence of bony defects on preoperative shoulder function in recurrent anteroinferior shoulder instability. *Am J Sports Med* 2016;44(5):1131-6. <https://doi.org/10.1177/0363546515626541>
28. Dickens JF, Slaven SE, Cameron KL, Pickett AM, Posner M, Campbell SE, et al. Prospective evaluation of glenoid bone loss after first-time and recurrent anterior glenohumeral instability events. *Am J Sports Med* 2019;47(5):1082-9. <https://doi.org/10.1177/0363546519831286>
29. Moroder P, Plachel F, Huettner A, Ernstbrunner L, Minkus M, Boehm E, et al. The effect of scapula tilt and best-fit circle placement when measuring glenoid bone loss in shoulder instability patients. *Arthroscopy* 2017;34(2):398-404. <https://doi.org/10.1016/j.arthro.2017.08.234>

30. Funakoshi T, Hartzler RU, Stewien E, Burkhart SS. Hill-Sachs lesion classification by the glenoid track paradigm in shoulder instability: Poor agreement between 3-dimensional computed tomographic and arthroscopic methods. *Arthroscopy* 2019;35(6):1743-9. <https://doi.org/10.1016/j.arthro.2018.12.005>
31. Gowd AK, Liu JN, Cabarcas BC, Garcia GH, Cvetanovich GL, Provencher MT, et al. Management of recurrent anterior shoulder instability with bipolar bone loss: A systematic review to assess critical bone loss amounts. *Am J Sports Med* 2019;47(10):2484-93. <https://doi.org/10.1177/0363546518791555>
32. Yamamoto N, Shinagawa K, Hatta T, Itoi E. Peripheral-track and central-track Hill-Sachs lesions: A new concept of assessing an on-track lesion. *Am J Sports Med* 2019;48(1):33-8. <https://doi.org/10.1177/0363546519886319>
33. Di Giacomo G, Peebles LA, Pugliese M, Dekker TJ, Golijanin P, Sanchez A, et al. Glenoid track instability management score: Radiographic modification of the Instability Severity Index Score. *Arthroscopy* 2020;36(1):56-67. <https://doi.org/10.1016/j.arthro.2019.07.020>
43. Rossi LA, Frank RM, Wilke D, Provencher M, Millet PJ, Chahla J. Bone loss in the setting of glenohumeral instability: An Expert Consensus Statement using the Modified Delphi Technique. *Arthroscopy* 2020 ;13:S0749-8063(21)00011-6. <https://doi.org/10.1016/j.arthro.2020.12.237>