

# Facet Fluid Sign and Segmental Instability of the Spine

Pedro L. Bazán,<sup>1</sup> Marco A. Rosas Mendieta,<sup>2</sup> Emmanuel Padini,<sup>3</sup> Jorge F. Carrizo Becerra,<sup>4</sup> Álvaro E. Borri,<sup>5</sup> Martín Medina<sup>6</sup>

<sup>1</sup>Spinal Pathology Unit, Orthopedics and Traumatology Service, Hospital Interzonal General de Agudos "General San Martín", La Plata, Buenos Aires, Argentina

<sup>2</sup>Orthopedics and Traumatology Service, Caja de Salud de Caminos, Hospital Obrero 4, Oruro, Bolivia

<sup>3</sup>Orthopedics and Traumatology Service, Sanatorio Loma Linda, Saenz Peña, Chaco, Argentina

<sup>4</sup>Orthopedics and Traumatology Service, Clínica Mercedario, Hospital Descentralizado, San Juan, Argentina

## ABSTRACT

**Introduction:** Degenerative lumbar spine disease is prevalent, however, the criteria for instability are still debated. **Objectives:** To analyze the presence of the lumbar facet fluid sign as a criterion for segmental instability of the spine. **Materials and Methods:** Patients with chronic lumbar disease, who present facet hydrarthrosis on MRI and dynamic lumbar spine radiographs. The prevalence of sex, age, main symptomatology, and pain on unilateral or bilateral extension was investigated. **Results:** A total of 139 patients (62% women) were evaluated, with an average age of 50.8 years; the main reason for consultation was low back pain (76%). Sixty-five percent reported pain in extension, with 35% reporting unilateral pain and 30% reporting bilateral pain. Fourteen percent had low-grade spondyloolsthesis at L4-L5 and 7% at L5-S1. Hydrarthrosis was unilateral in 20% and bilateral in 80%; the most frequent level of hydrarthrosis was L4-L5 (58%). Six percent had only translational instability and 2% had mixed instability. 8% and 5%, respectively, had Modic I and Modic II changes. **Conclusions:** The presence of facet fluid is not a criterion for segmental instability of the spine, regardless of the level and localized segment, or the unilateral or bilateral lumbar facet presentation.

**Keywords:** Chronic lumbar disease; angular instability; translational instability; facet fluid; low back pain.

**Level of Evidence:** IV

## Signo del fluido facetario e inestabilidad vertebral segmentaria

## RESUMEN

**Introducción:** La enfermedad degenerativa de la columna lumbar es frecuente, pero aún existen dudas en relación con los criterios de inestabilidad. **Objetivos:** Analizar la relación del signo del fluido facetario lumbar como criterio de inestabilidad vertebral segmentaria. **Materiales y Métodos:** Pacientes con enfermedad lumbar crónica, que presentan hidrartrosis facetaria en la resonancia magnética y las radiografías de columna lumbar dinámicas. Se analizan la prevalencia del sexo, la edad, la sintomatología principal y el dolor a la extensión unilateral o bilateral. **Resultados:** Se evaluó a 139 pacientes (62% mujeres), con un promedio de edad de 50.8 años; el principal motivo de consulta fue lumbalgia (76%). El 65% refería dolor en extensión; el 35%, dolor unilateral y el 30%, dolor bilateral. El 14% tenía espondilolistesis de bajo grado en L4-L5 y el 7%, en L5-S1. La hidrartrosis era unilateral en el 20% y bilateral en el 80%; el nivel de hidrartrosis más frecuente era en L4-L5 (58%). El 6% tenía solo inestabilidad traslacional y el 2%, mixta. Un 8% presentaba Modic I y un 5%, Modic II. **Conclusiones:** La presencia de fluido facetario no es un criterio de inestabilidad vertebral segmentaria, al margen del nivel y el segmento localizado, o la presentación facetaria lumbar unilateral o bilateral.

**Palabras clave:** Enfermedad lumbar crónica; inestabilidad angular; inestabilidad traslacional; fluido facetario; lumbalgia.

**Nivel de Evidencia:** IV

## INTRODUCTION

Common symptoms of lumbar facet syndrome include spinal claudication, low back pain, especially in extension, or radicular pain in the lower limbs. Magnetic resonance imaging (MRI) of the lumbar spine is often ordered to evaluate these symptoms, and maximum flexion and extension lateral radiographs are generally used to evaluate

Received on January 30<sup>th</sup>, 2022. Accepted after evaluation on March 5<sup>th</sup>, 2023 • Dr. PEDRO L. BAZÁN • pedroluisbazan@gmail.com  <https://orcid.org/0000-0003-0060-6558>

**How to cite this article:** Bazán PL, Rosas Mendieta MA, Padini E, Carrizo Becerra JF, Borri AE, Medina M. Facet Fluid Sign and Segmental Instability of the Spine. *Rev Asoc Argent Ortop Traumatol* 2023;88(3):269-274. <https://doi.org/10.15417/issn.1852-7434.2023.88.3.1511>

angular ( $>12^\circ$  difference), translational ( $>3$  mm between both incidences) or mixed instability.<sup>1</sup> Facet joints in the lumbar spine are typical diarthrodial joints that normally support increasing segmental loading until the onset of disc degeneration.<sup>2</sup> MRI findings, including facet joint osteoarthritis, facet joint angle, and facet fluid sign (FFS), defined as the presence of fluid in the joint space, have been associated with instability.<sup>3,4</sup> However, it remains a controversial topic.<sup>5,6</sup>

Hasegawa et al. found that facet opening is the strongest predictor of instability.<sup>6</sup> Rihn et al. described that FFS was significantly correlated with sagittal radiographic instability in patients with degenerative low back disease.<sup>7</sup> In multiple studies, the facet sign on MRI in the supine position has been documented as an indicator of lumbar instability.<sup>7,8</sup>

Some studies<sup>7-9</sup> emphasize that the FFS requires the presence of a gap between the facet joints while the patient is in the supine position, and that the space has time to fill with fluid before the MR is obtained. Wang et al., on the other hand, were the first to describe that FFS exists in the upright weight-bearing posture as well as the supine position.<sup>1</sup>

The prevalence of chronic lumbar spine disease increases day by day, but there are still doubts regarding the criteria for instability and its clinical relationship, despite having complementary studies that are used daily in a spinal clinic.<sup>10</sup>

Therefore, we carried out a study to determine the clinical correlation of FFS with instability in patients presenting for lumbar symptoms with dynamic radiographic studies showing instability parameters and MRI images revealing hydrarthrosis.

The main objective of the study was to determine if lumbar FFS could be a criterion of segmental vertebral instability. The specific objectives were to determine whether there was angular-translational instability, the level of the affected segment, the presence of unilateral or bilateral FFS, the site of presentation, and whether spondylolisthesis was detected.

## MATERIALS AND METHODS

Images of patients who attended the Spinal Pathology Unit between September 2019 and March 2020 for symptomatic low back pain with or without radiculopathy were evaluated.

The inclusion criteria were: patients with dynamic lumbar spine radiographs (lateral in maximum flexion and extension) with parameter measurements indicating instability and MRI on axial, T1 and T2 weighted sequences showing hydrarthrosis at the facet level. In addition, the prevalence of sex, age, main symptomatology, the presence of pain on unilateral or bilateral extension were evaluated.

The exclusion criteria were: history of spinal surgery, infection, trauma or tumor in the level to be investigated.

This study was approved by the Teaching and Research Service and its Research Ethics Committee.

The following variables were evaluated: sex, age according to age groups (15-34, 35-54, 55-74 and  $>74$  years); reason for consultation; low back pain on extension (yes or no); unilateral or bilateral, radicular pain; MR Modic 0, I, II, III; dynamic radiographs; angular instability (yes/no), translational instability (yes/no), spondylolisthesis (yes/no).

## Statistical Analysis

Student's t-test for dichotomous variables and the chi-squared test were applied. A 95% confidence interval was used. The statistical analysis was performed with the SPSS program.

## RESULTS

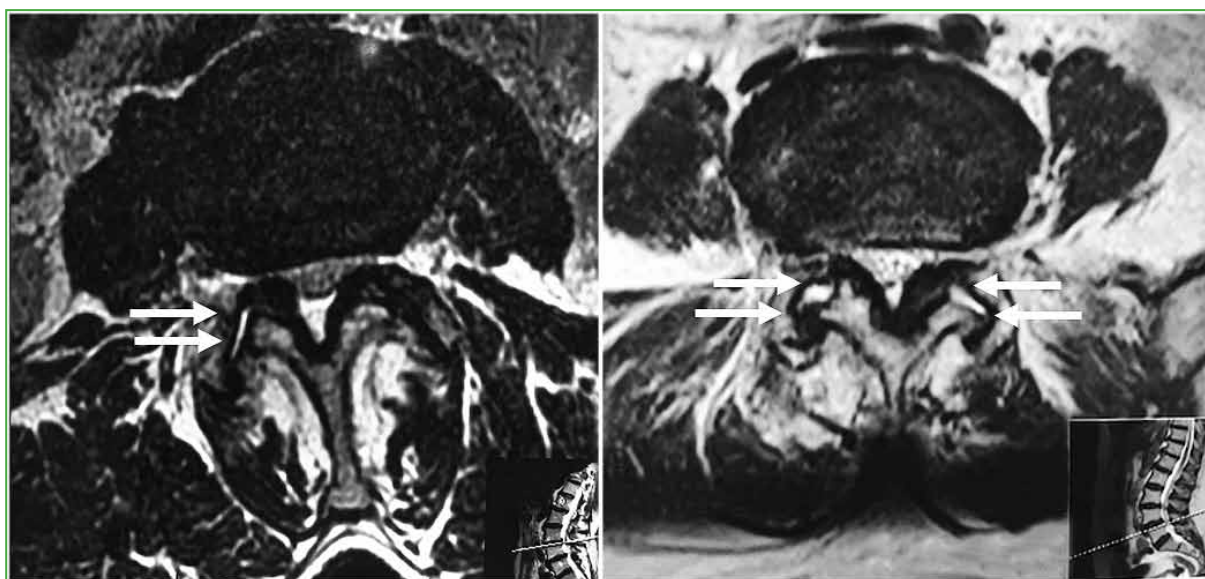
139 patients with a mean age of 50.8 years (range 20-80) were included; 86 were women and 53 men; 14 women had some type of instability ( $p$  0.07) (Table).

The incidence of translational instability was higher in patients  $>63$  years ( $p$  0.096), this relationship was statistically significant in this group.

**Table.** Epidemiological data of the patients.

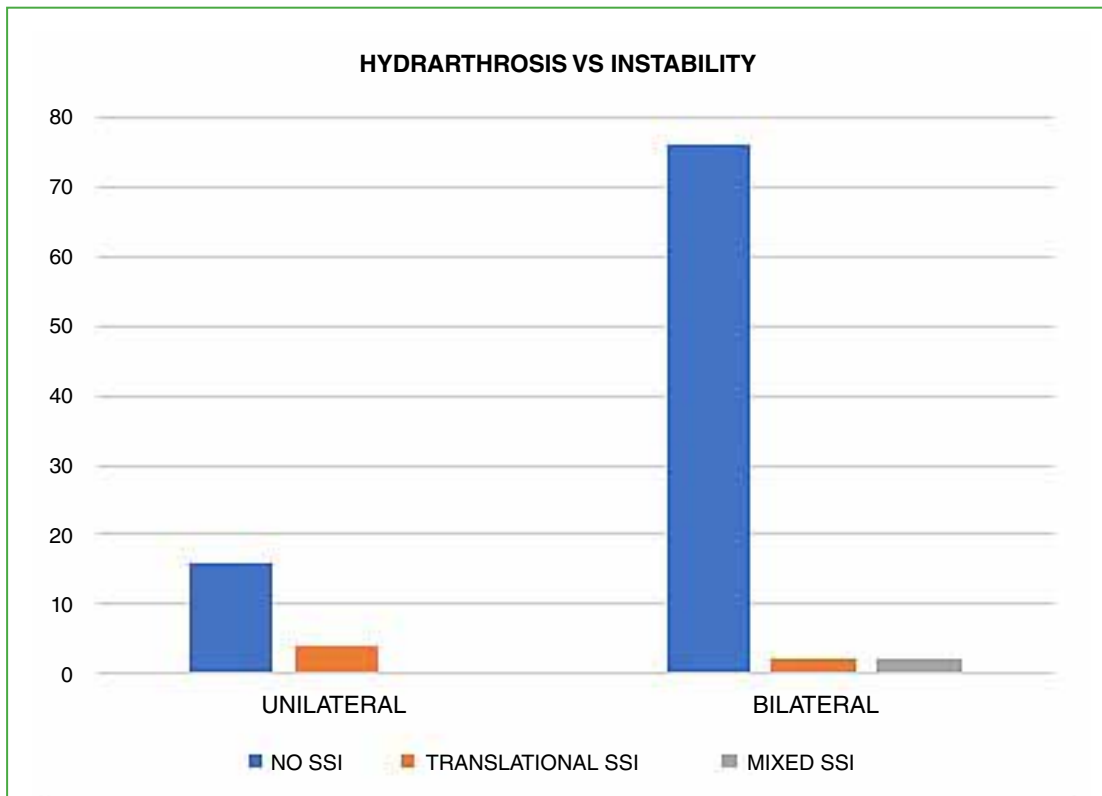
Sex	Female	Male			
	62	38			
Age (years)	Mean	CI95%			
	50.8	20-80			
Reason for consultation	Lumbalgia	Lumbosciatica	Other		
	76	19	5		
Extension pain	No	Unilateral	Bilateral		
	35	35	30		
Spondylolisthesis	No	L2-L3	L3-L4	L4-L5	L5-S1
	77	1	1	14	7
Hydrarthrosis	Unilateral	Bilateral			
	20	80			
	L1-L2	L2-L3	L3-L4	L4-L5	L5-S1
	12	24	41	58	56
Instability	No	Translational	Both		
	92	6	2		
Modic	II	II	No		
	8	5	87		

65% of patients with low back pain associated with hydrarthrosis suffered pain on extension of the trunk. Analysis of the MR images revealed that 20% were unilateral and 80% bilateral (**Figure 1**); the most frequent level of hydrarthrosis was L4-L5 (58%), followed by L5-S1 (56%) and L3-L4 (41%). 8% of patients with hydrarthrosis had a Modic I sign and 5%, Modic II; in 87%, no Modic sign was found.



**Figure 1.** Magnetic resonance imaging of the lumbar spine, axial section. Unilateral and bilateral hydrarthrosis is observed (double white arrow).

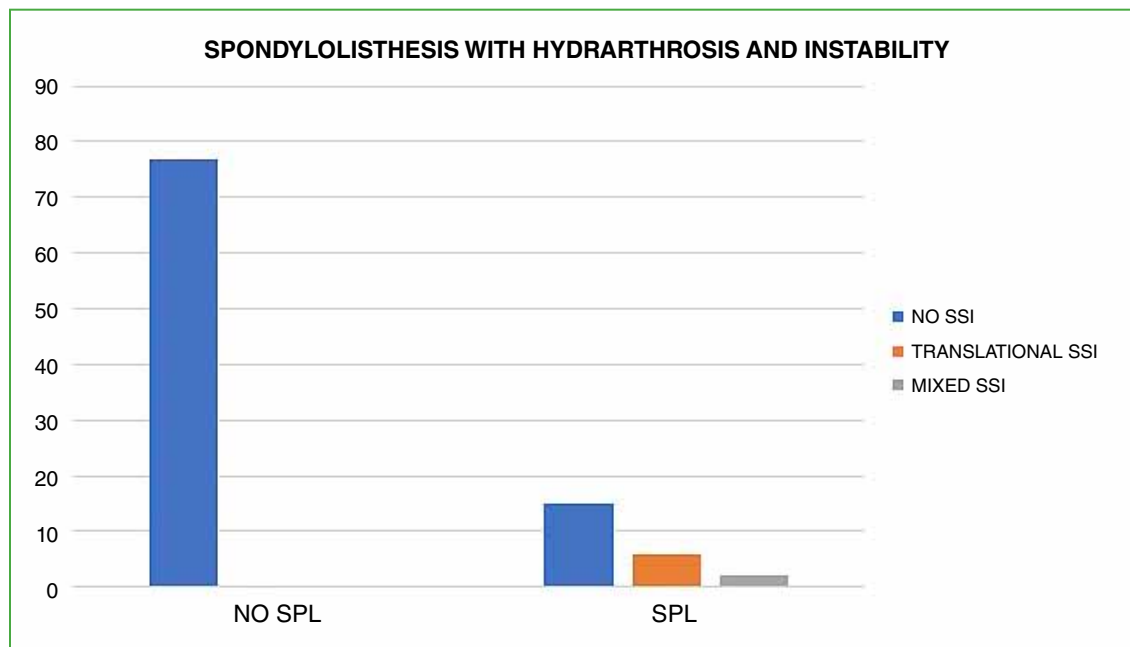
92% had no instability; 6% had translational instability and 2% both types of instability (p 0.011). This determines that there is no relationship between hydrarthrosis and the different types of instability (Figure 2).



**Figure 2.** Relationship between hydrarthrosis and the presence and type of segmental spinal instability (SSI).

Likewise, 14% had L4-L5 spondylolisthesis; 7%, from L5-S1 and 77% did not present spondylolisthesis. Those patients who had hydrarthrosis and instability also had vertebral instability, leading to the conclusion that there is a significant association between instability and spondylolisthesis (p 0.001, alpha 0.05, CI 0.95); therefore, it can be pointed out that instability is significantly associated with spondylolisthesis in this study. Breaking down this relationship by age group, the compared Tukey diagram shows the differences between the two groups. The analysis of variance shows a p value of 0.003.

Therefore, it is concluded that the diagnosis of spondylolisthesis is significantly associated with age (p < 0.003) (Figure 3).



**Figure 3.** Relationship between patients with spondylolisthesis (SPL) and instability (SSI). Mixed SSI = translational and angular instability.

## DISCUSSION

Although lumbar degenerative spondylolisthesis was described in 1932,<sup>11</sup> the definition of instability remains controversial. In multiple investigations, FFS on MRI has been documented as an indicator of lumbar instability.<sup>8</sup> In our study, no statistically significant association was found between instability and hydrarthrosis, so it can be pointed out that the presence of facet hydrarthrosis is not necessarily a fundamental variable in the case of instability.

Flexion-extension radiographs are widely used to determine segmental instability of the lumbar spine. Dupuis et al.<sup>12</sup> defined instability as a sagittal translation >8% of the width of the anterior adjacent vertebra, while Boden and Wiesel<sup>13</sup> defined instability as a significant range of motion (>3 mm of translation movement, greater than 8% of the width above the adjacent vertebra) in the sagittal plane between lateral flexion and extension radiographs.

Hasegawa et al. found that facet opening was the strongest predictor of instability.<sup>6</sup> Rihn et al. reported that the degree of facet effusion was significantly correlated with sagittal radiographic instability in patients with degenerative low back disease.<sup>7</sup>

Bazan et al. analyzed the relationship between the inflammatory Modic sign and instability, and found no correlation between this sign and the presence of translational or angular vertebral instability.<sup>14</sup>

Likewise, it was observed that the average age >63 years is significantly associated with instability and that the main difference is between patients without instability and those with translational instability.

Spondylolisthesis was found to be significantly associated with age >59 years, but this does not define unilateral or bilateral location.

In the study of FFS, differential diagnoses such as facet septic arthritis should be considered, as suggested by Ciccioli et al.<sup>15</sup>

## CONCLUSIONS

The presence of facet fluid is not a criterion for segmental vertebral instability, regardless of level and segment, or unilateral or bilateral lumbar facet presentation. It can be concluded that the instability index tends to be higher in the female sex.

Conflict of interest: The authors declare no conflicts of interest.

M. A. Rosas Mendieta ORCID ID: <https://orcid.org/0000-0001-7426-8737>

E. Padini ORCID ID: <https://orcid.org/0000-0002-8509-9438>

J. F. Carrizo Becerra ORCID ID: <https://orcid.org/0000-0001-9412-8918>

Á. E. Borri ORCID ID: <https://orcid.org/0000-0002-5568-867X>

M. Medina ORCID ID: <https://orcid.org/0000-0002-5281-5645>

## REFERENCES

1. Wang D, Yuana H. Analysis of the relationship between the facet fluid sign and lumbar spine motion of degenerative spondylolytic segment using Kinematic MRI. *Eur J Radiol* 2017;94:6-12. <https://doi.org/10.1016/j.ejrad.2017.07.010>
2. Sethi R. Relationship between disc degeneration and facet joint arthrosis a MRI study. *J Anat Soc India* 2016;65:123-7. <https://doi.org/10.1016/j.jasi.2017.02.010>
3. Fujiwara A, Tamai K, An HS, Lim TH, Yoshida H, Kurihashi A, et al. Orientation and osteoarthritis of the lumbar facet joint. *Clin Orthop Relat Res* 2001;(385):88-94. <https://doi.org/10.1097/00003086-200104000-00015>
4. Chaput C, Padon D, Rush J, Lenehan E, Rahm M. The significance of increased fluid signal on magnetic resonance imaging in lumbar facets in relationship to degenerative spondylolisthesis. *Spine (Phila Pa 1976)* 2007;32(17):1883-7. <https://doi.org/10.1097/BRS.0b013e318113271a>
5. Hasegawa K, Kitahara K, Shimoda H, Ishii K, Ono M, Homma T, et al. Lumbar degenerative spondylolisthesis is not always unstable: clinicobiomechanical evidence. *Spine (Phila Pa 1976)* 2014;39(26):2127-35. <https://doi.org/10.1097/BRS.0000000000000621>
6. Hasegawa K, Shimoda H, Kitahara K, Sasaki K, Homma T. What are the reliable radiological indicators of lumbar segmental instability? *J Bone Joint Surg Br* 2011;93(5):650-7. <https://doi.org/10.1302/0301-620X.93B5.25520>
7. Rihn JA, Lee JY, Khan M, Ulibarri JA, Tannoury C, Donaldson WF 3rd, et al. Does lumbar facet fluid detected on magnetic resonance imaging correlate with radiographic instability in patients with degenerative lumbar disease? *Spine (Phila Pa 1976)* 2007;32(14):1555-60. <https://doi.org/10.1097/BRS.0b013e318067dc55>
8. Lattig F, Fekete TF, Grob D, Kleinstück FS, Jeszenszky D, Mannion AF. Lumbar facet joint effusion in MRI: a sign of instability in degenerative spondylolisthesis? *Eur Spine J* 2012;21(2):276-81. <https://doi.org/10.1007/s00586-011-1993-1>
9. Helbig T, Lee CK. The lumbar facet syndrome. *Spine (Phila Pa 1976)* 1988;13(1):61-4. <https://doi.org/10.1097/00007632-198801000-00015>
10. Fujiwara A, Tamai K, Yamato M, An HS, Yoshida H, Saotome K, et al. The relationship between facet joint osteoarthritis and disc degeneration of the lumbar spine: an MRI study. *Eur Spine J* 1999;8(5):396-401. <https://doi.org/10.1007/s005860050193>
11. Phan KH, Daubs MD, Kupperman AI, Scott TP, Wang JC. Kinematic analysis of diseased and adjacent segments in degenerative lumbar spondylolisthesis. *Spine J* 2015;15(2):230-7. <https://doi.org/10.1016/j.spinee.2014.08.453>
12. Dupuis PR, Yong-Hing K, Cassidy JD, Kirkaldy-Willis WH. Radiologic diagnosis of degenerative lumbar spinal instability. *Spine (Phila Pa 1976)* 1985;10(3):262-76. <https://doi.org/10.1097/00007632-198504000-00015>
13. Boden SD, Wiesel SW. Lumbosacral segmental motion in normal individuals. Have we been measuring instability properly? *Spine (Phila Pa 1976)* 1990;15(6):571-6. <https://doi.org/10.1097/00007632-199006000-00026>
14. Bazán PL, Borri AE, Medina M. Correlación entre signo de Modic I e inestabilidad radiográfica dinámica. *Columna/Columna* 2021;20(4):259-62. <https://doi.org/10.1590/S1808-185120212004250503>
15. Ciccioioli NM, Medina M, Bazán PL, Borri AE. Artritis séptica facetaria en columna. *Orthotips* 2021;17(1):6-10. <https://doi.org/10.35366/99161>