

# Closed Reduction and Percutaneous Pinning Versus Dorsal-Entry Elastic Intramedullary Nailing

Andrés Ferreyra, Felicitas Allende, Juan Emiliano Sánchez Benítez, Franco Gramajo, Bruno Damiguella, Victoria Allende, J. Javier Masquijo

Department of Pediatric Orthopedics and Traumatology, Sanatorio Allende, Córdoba, Argentina

## ABSTRACT

**Objective:** To compare results and complications of closed reduction percutaneous pinning (CRPP) versus dorsal entry elastic intramedullary nails (ESIN). **Materials and Methods:** Radiographs were evaluated to determine angular deformities at the time of radiographic union. Complications were graded with a modification of the Clavien-Dindo classification. **Results:** The CRPP group consisted of 17 patients (Group A) whereas the ESIN group consisted of 19 patients (Group B). The average age of the patient cohort was  $12.5 \pm 1.6$  years. The average follow-up was  $27.6 \pm 16.6$  months. The demographic data revealed no differences between groups ( $p > 0.05$ ). Patients treated with ESIN required a shorter immobilization time ( $2.8 \pm 1.8$  versus  $5.9 \pm 1.3$  weeks,  $p = 0.00029$ ). One patient in each group presented an angulation  $> 10^\circ$  at the time of consolidation. The complication rate was higher in group A (18% versus 5.3%,  $p = 0.27$ ). According to the Clavien-Dindo classification, group A presented 2 type II (infection and granuloma), and 2 type III complications (loss of reduction). Group B presented one type I complication (implant prominence). Sixteen patients in group B underwent a second procedure for hardware removal. Two patients (11.8%) in group A required revision due to loss of reduction. **Conclusions:** Both techniques are effective in stabilizing metaphyseal-diaphyseal fractures of the distal radius in the adolescent population. ESIN has the advantage of requiring a shorter immobilization time and fewer complications but needs a second surgery for implant removal. CRPP does not require anesthesia for implant removal, although it requires a longer postoperative immobilization, and has a higher complication rate.

**Keywords:** Distal radius fractures; adolescents; treatment; elastic intramedullary nails; percutaneous pinning.

**Level of Evidence:** III

## Fracturas metafiso-diafisarias de radio distal en adolescentes: estudio comparativo entre fijación percutánea con clavijas y clavos elásticos de titanio

## RESUMEN

**Objetivo:** Comparar los resultados y las complicaciones entre la fijación percutánea con clavijas (FPC) y el enclavado endomedular elástico (EEE). **Materiales y Métodos:** Se evaluaron las radiografías para determinar deformidades angulares en la consolidación. Se usó el sistema de Clavien-Dindo adaptado para clasificar las complicaciones. **Resultados:** El grupo A (FPC) incluyó a 17 pacientes y el grupo B (EEE), a 19. La edad promedio era de  $12.5 \pm 1.6$  años y el seguimiento promedio fue de  $27.6 \pm 16.6$  meses. Los pacientes con EEE requirieron menos tiempo de inmovilización ( $2.8 \pm 1.8$  vs.  $5.9 \pm 1.3$  semanas,  $p = 0,00029$ ). Un paciente de cada grupo tuvo una angulación  $> 10^\circ$  en la consolidación. La tasa de complicaciones fue mayor en el grupo A (18% vs. 5,3%,  $p = 0,27$ ). En el grupo A, hubo 2 complicaciones tipo III (pérdida de corrección) y 2 tipo II (infección y granuloma). Un paciente del grupo B presentó una complicación tipo I (prominencia del implante). Dieciséis pacientes del grupo B se sometieron a una segunda cirugía para extraer el implante. Dos del grupo A requirieron revisión de la fijación por pérdida de alineación. **Conclusiones:** Ambas técnicas son eficaces para estabilizar fracturas metafiso-diafisarias de radio distal en adolescentes. El EEE tiene la ventaja de una inmovilización más corta y menos complicaciones, pero es más caro y requiere otra cirugía para extraer el implante. La FPC no requiere de anestesia para extraer el implante, aunque sí una inmovilización más prolongada y la tasa de complicaciones es más alta.

**Palabras clave:** Fractura de radio distal; adolescentes; tratamiento; clavos elásticos de titanio; clavijas.

**Nivel de Evidencia:** III

Received on November 4th, 2021. Accepted after evaluation on January 29th, 2022 • Dr. ANDRÉS FERREYRA • and\_ferreyra@yahoo.com.ar  <https://orcid.org/0000-0003-1163-7114>

**How to cite this article:** Ferreyra A, Allende F, Sánchez Benítez JE, Gramajo F, Damiguella B, Allende V, Masquijo JJ. Closed Reduction and Percutaneous Pinning Versus Dorsal-Entry Elastic Intramedullary Nailing. *Rev Asoc Argent Ortop Traumatol* 2022;87(3):341-348. <https://doi.org/10.15417/issn.1852-7434.2022.87.3.1458>

## INTRODUCTION

Distal radius fractures are one of the most common skeletal injuries in children. In some series, they comprise up to a fifth of all pediatric fractures and 80% of pediatric fractures of the forearm, and have an estimated annual incidence of 1 in 100.<sup>1-3</sup>

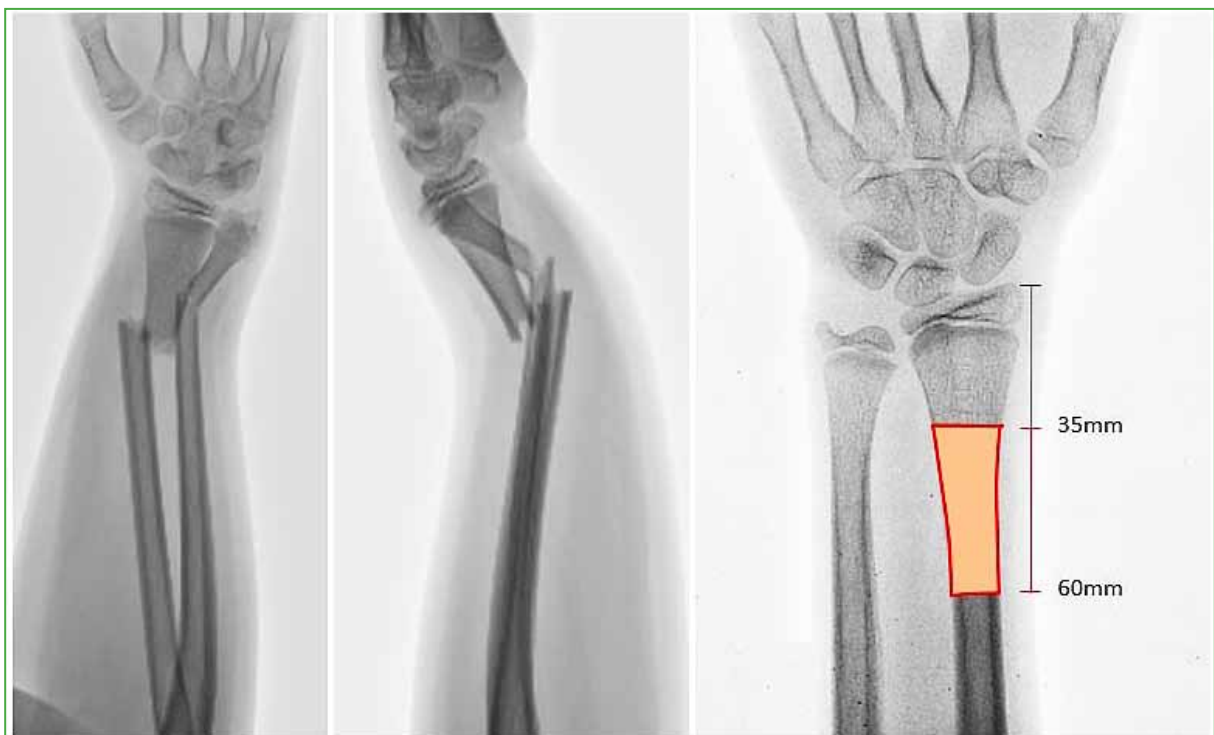Fractures located at the metaphyseal-diaphyseal junction represent a unique problem. Although most are susceptible to non-surgical treatment, they are usually more unstable than those located closer to the physis. In patients closer to skeletal maturity, some unstable or highly displaced fractures may require surgical stabilization due to failure to obtain or maintain adequate reduction. Fixation options include: open reduction and internal fixation with plates and screws,<sup>4,5</sup> percutaneous pinning (PP),<sup>6-8</sup> and dorsal-entry elastic stable intramedullary nailing (ESIN).<sup>9-11</sup> Pinning is the most popular fixation method in the pediatric-adolescent population. Although it can provide greater stability than cast immobilization, its entry is difficult, as it requires an acute angle to grasp the proximal fragment and avoid entering the fracture line. Plate fixation is less popular in this age group due to higher morbidity and risk of re-fracture.<sup>12</sup> ESIN, on the other hand, is widely accepted as an effective treatment for diaphyseal forearm fractures.<sup>13,14</sup> However, the application of this technique in fractures located in the metaphyseal-diaphyseal junction of the radius has not been widely studied.<sup>10,11</sup>

During the last years, we have alternatively used PP or ESIN in those metaphyseal-diaphyseal fractures of the radius that required stabilization.

The objective of this study was to compare the radiographic results and complications of both methods.

## MATERIALS AND METHODS

A comparative study was carried out and approved by the Ethics Committee of our institution. We included 36 patients between 10 and 16 years of age with closed metaphyseal-diaphyseal fractures of the distal radius who underwent closed reduction and PP (group A, n = 17) or ESIN (group B, n = 19) in six years (2012-2018). Metaphyseal-diaphyseal fractures were defined as those with a distance from the fracture to the joint surface of between 35 and 60 mm (Figure 1).<sup>10</sup>

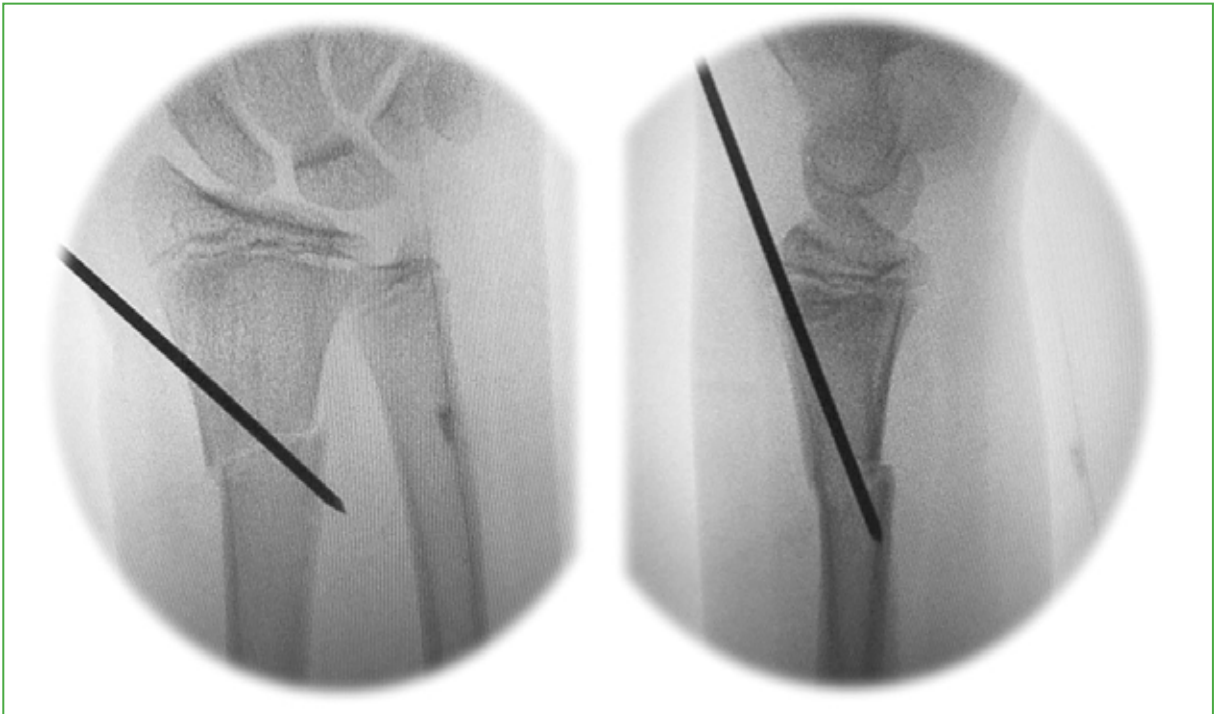

**Figure 1.** Definition of metaphyseal-diaphyseal fracture of the radius: those with a distance from the articular surface to the fracture of between 35 and 60 mm.

Patients who required another type of treatment (casting, plate and screws, etc.), with open reduction of the fracture, closed physis, a follow-up of <6 months, and missing information in the clinical records were excluded from the analysis. The patients were operated on by four traumatologists from the same institution, who had formal training in Child Orthopedics and Traumatology. Internal fixation was selectively indicated for fractures that were considered highly unstable or failed to maintain an adequate reduction in the cast. The decision to use one or another technique fell on each professional. Two preferred PP, while the other two preferred ESIN, so a similar number was achieved in each group during the evaluated period.

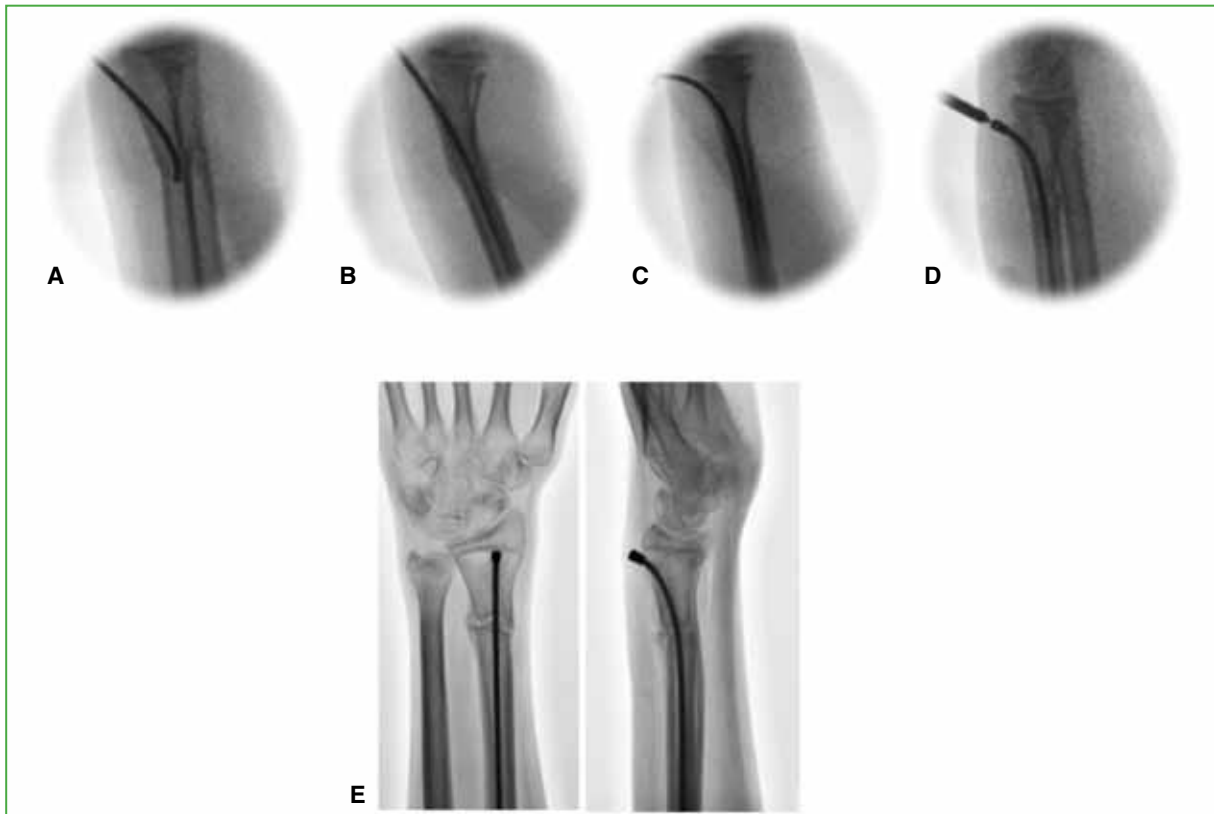
### Surgical technique

The procedure is performed under general anesthesia and intraoperative monitoring. The patient is placed in the dorsal decubitus position with the arm abducted on the hand table. Asepsis and antisepsis are performed, and the fields are placed according to the technique. The C-arm enters distally and is placed parallel to the patient, and the monitor faces the surgeon. Reduction is performed according to technique and stability is checked. If a satisfactory reduction is not achieved under fluoroscopy or it is considered very unstable, fixation is carried out. In patients undergoing PP, a 1.8mm pin is placed, entering below the radial physis from distal to proximal (Figure 2).



**Figure 2.** Percutaneous pinning technique. After reduction, a 1.8mm pin is placed and entered proximal to the distal radius physis, fixing the distal and proximal fragment. Intraoperative stability is then checked by fluoroscopy.

If a satisfactory reduction is not initially achieved, a 2.0 mm pin is used as a joystick (Kapandji technique). In group B (ESIN) patients, a 2.0 or 2.5 mm titanium elastic nail is used, depending on the size of the intramedullary canal. A small 1-1.5 cm incision is made at the level of Lister's tubercle, between the second and third dorsal compartments. An awl is inserted to pierce the distal radius below the physis. It is important to center the entry exactly in the front to avoid translation of the distal fragment. The selected nail is then inserted and passed through the fracture. It is then molded at 90° in the entry area (Figure 3).



**Figure 3.** Fixation technique with elastic intramedullary nailing. **A.** After reduction, a titanium elastic nail is inserted through an approach at the level of Lister's tubercle. **B.** Placement of the nail in the intramedullary canal that has crossed the fracture. **C.** The nail is molded at  $90^\circ$  in the entry area. Fluoroscopy confirms that the fracture is correctly aligned and stable. **D.** The nail is cut with the device and the endcap is placed. **E.** Anteroposterior and lateral radiographs of the wrist showing early signs of union at four weeks postoperatively.

After confirming by fluoroscopy that the fracture is correctly aligned and stable, the elastic nail is cut with the cutting device and the endcap is placed to prevent the distal end of the nail from injuring the extensor pollicis longus tendon. In group A, a long arm cast is placed; at four weeks, the cast and pin are removed in the office. Depending on the degree of consolidation, it is decided whether to continue immobilization for a few more weeks until clinical and radiographic consolidation is achieved. In group B, a long arm splint is placed postoperatively, which is removed at approximately two weeks and monitored with radiographs every four weeks to assess union. Removal of the elastic nail is indicated after six months.

### Patient assessment

Demographic data of the patients (age, sex, side, associated injuries and previous treatment) were recorded. Radiographs were evaluated for consolidation time, loss of correction, and angular deformities  $>10^\circ$  at the time of consolidation. Loss of correction was defined as: dorsal/volar angulation  $>10^\circ$ , radial deviation  $>5^\circ$ , a translation  $>3$  mm, or a combination of these, between the initial reduction and subsequent controls. The range of motion (flexion-extension of the wrist and prono-supination of the forearm) was evaluated with a goniometer in the affected limb and compared with the contralateral limb. Loss of forearm rotation was considered when the decrease in range of motion was  $>10^\circ$  when compared to the contralateral. Complications were classified using an adaptation of the Clavien-Dindo system.<sup>15</sup> The description of this classification system is shown in Table 1.

**Table 1.** Modification of the Clavien-Dindo classification of surgical complications of forearm fractures

Degree	Definition	Examples
1	Deviation from the routine postoperative course without the need to intervene	Asymptomatic delayed union Hardware prominence
2	Resolution after outpatient management, drug therapy, or close observation	Superficial infection Transient nerve palsy
3	Requires hospital management or re-intervention	Deep infection Migration of implants that require early removal
4	Complication that is life- or limb-threatening or results in permanent deficit	Compartment syndrome Permanent nerve palsy Radioulnar synostosis Tendon rupture
5	Patient death	Postoperative death secondary to anesthetic reaction

### Calculation of the approximate cost of each procedure

Total treatment costs were estimated for each surgical scenario. Implant charges, hospital admission, surgeon and anesthetist fees, operating room costs, diagnostic imaging, and medication were considered. Costs were obtained from the hospital billing department.

### Statistical analysis

Continuous variables were analyzed with normality tests (Shapiro-Wilk) and are expressed as mean and standard deviation ( $\pm$ SD). Comparisons between groups were made using the  $\chi^2$  test (categorical data) or Student's t-test (continuous data) with the MedCalc® version 12.7.8 program. A p-value  $<0.05$  was considered statistically significant.

## RESULTS

The average age at injury was  $12.5 \pm 1.6$  years and the average follow-up was  $27.6 \pm 16.6$  months. No statistically significant differences were found between the groups in terms of age, gender, side of injury, associated ulna fracture, prior treatment, and follow-up. The immobilization time of the patients treated with ESIN was shorter ( $2.8 \pm 1.8$  vs.  $5.9 \pm 1.3$  weeks,  $p 0.00029$ ). Two patients in each group had an angulation  $>10^\circ$  at the time of consolidation (Table 2).

**Table 2.** Demographic data and comparison between both groups.

Variable	CRPP	ESIN	p <sup>§</sup>
n	17	19	-
Age	12.2	12.7	0.437
Gender (Female/Male)	2/15	1/17	0.559
Side (Left/Right)	10/7	10/8	0.506
Previous plaster treatment*	5 (29.4%)	4 (21%)	0.576
Postoperative immobilization**	5.9 ± 1.3	3.8 ± 1.8	0.00029
Final angulation >10°	2	2	0.91
Follow-up**	25.06 ± 17.6	31.5 ± 15.04	0.33
Complications*	3 (18%)	1 (5.3%)	0.27
Revision surgery	2	0	0.13
Removal of osteosynthesis material under general anesthesia	0	15	<0.01

Values expressed as: \*whole numbers and percentage, \*\*whole numbers and standard deviation. §  $\chi^2$  test/t test for paired data.

The complication rate was higher in group A (18% vs. 5.3%; p 0.27). According to the Clavien-Dindo system, in group A, there were two type III complications (loss of correction) and two type II complications (infection and granuloma). In group B, a type I complication (implant prominence) was detected. Sixteen patients in group B underwent a second surgical procedure for implant removal. Two patients in group A required fixation revision due to loss of alignment. At the last follow-up, all had complete wrist flexion-extension and two (one in each group) had a mild pronation limitation (10-15°).

Treatment was approximately 2.5 times more expensive in group B. This value is obtained if we consider the treatment as a single event, without including reintervention in the cost (to correct the loss of correction in group A and to remove the material in group B).

## DISCUSSION

Conventional treatment of displaced distal radius fractures consists of closed reduction and cast immobilization.<sup>16</sup> Although a high percentage of patients can obtain satisfactory results with this method, some fractures are so unstable that they cannot be immobilized with a cast, and up to a third of those in which an acceptable reduction is achieved may present re-displacement.<sup>17</sup> Unstable fractures located in the metaphyseal-diaphyseal junction can be treated with various fixation methods.<sup>4-11</sup> In our study, we compared percutaneous pinning (PP) with a dorsal-entry ESIN technique that allows stabilization of fractures more distal to the diaphysis. Although both methods achieved similar clinical and radiographic outcomes, the complication rate was higher in the PP group.

In a biomechanical study comparing both techniques, fractures treated with pin fixation failed at lower levels of displacement.<sup>18</sup> Other authors<sup>18-20</sup> have reported drawbacks with the loss of reduction when using Kirschner pins in diaphyseal and metaphyseal-diaphyseal fractures, due to the smaller bone diameter. Cai et al.<sup>10</sup> evaluated a group of patients with radius fractures treated with intramedullary fixation or pins. In patients treated with ESIN, surgery was significantly shorter, intraoperative fluoroscopy exposure was shorter, and postoperative re-displacement was less than in those treated with pin fixation. At the 15-month follow-up, both techniques caused similar postoperative complications and the recovery of pronosupination was equivalent. In this same series, half of the patients treated with intramedullary fixation presented a translation in the frontal plane of 25-50%, with an uncertain long-term clinical implication. We consider this a failure of the technique, since the central entry in the distal fragment makes it possible to avoid lateral translation in the frontal plane. The technique used in our

study is different from the one proposed by Cai et al.,<sup>10</sup> as it not only pays extreme attention to this point, but also shapes the nail after it has advanced into the intramedullary canal of the proximal fragment. This allows for offset correction in the sagittal plane. Kim et al.<sup>11</sup> evaluated eight patients with fractures of the metaphyseal-diaphyseal junction treated with ESIN. The average age was 11.8 years (range 10-15). All evolved favorably towards consolidation, which occurred at 8.8 weeks. None suffered complications. The average angulation was 1.8° in the anteroposterior radiograph and 2° in the lateral projection. In our study, two patients in each group had an angulation >10° at the time of union (p 0.91).

The strength of this study is that it evaluates a group of adolescents with metaphyseal-diaphyseal fractures of the distal radius. This location has received little attention in the literature and there are very few studies that analyze the therapeutic options for this type of fracture in such a specific age population. The results of our study must be interpreted in the context of its limitations. The size of the sample and its design limit the possibility of performing a more rigorous statistical analysis. Some of the patients in the series come from the interior of our province or other provinces, so the clinical and radiographic follow-up was subject to the patients' possibility of attending follow-up visits. This may have affected the reported immobilization and consolidation times. Finally, the classification used for complications is validated in adults, but not in the pediatric population. It is also not validated in Spanish, although it has already been used in other studies.<sup>21,22</sup>

## CONCLUSIONS

Both techniques evaluated are effective in stabilizing metaphyseal-diaphyseal fractures of the distal radius in adolescents. Based on our results, we cannot recommend one or the other method. ESIN has the advantage of a shorter postoperative immobilization and fewer complications, but it is more costly and requires a second surgery for implant removal. PP does not require anesthesia to remove the implant, although it does require longer postoperative immobilization and the rate of complications is higher. The decision, ultimately, must be agreed between the treating physician and the patient's family to determine which treatment is most convenient in each situation.

Conflict of interest: The authors declare no conflicts of interest.

F. Allende ORCID ID: <https://orcid.org/0000-0001-9319-2571>

J. E. Sánchez Benítez ORCID ID: <https://orcid.org/0000-0001-7438-5909>

F. Gramajo ORCID ID: <https://orcid.org/0000-0001-6215-9787>

B. Damiguella ORCID ID: <https://orcid.org/0000-0003-2136-3364>

V. Allende ORCID ID: <https://orcid.org/0000-0003-4893-7276>

J. J. Masquijo ORCID ID: <https://orcid.org/0000-0001-9018-0612>

## REFERENCES

1. Bailey DA, Wedge JH, McCulloch RG, Martin AD, Bernhardson SC. Epidemiology of fractures of the distal end of the radius in children associated with growth. *J Bone Joint Surg Am* 1989;71(8):1225-31. PMID: 2777851
2. Cheng JC, Shen WY. Limb fracture pattern in different pediatric age groups: a study of 3350 children. *J Orthop Trauma* 1993;7(1):15-22. <https://doi.org/10.1097/00005131-199302000-00004>
3. Bae DS. Pediatric distal radius and forearm fractures. *J Hand Surg Am* 2008;33(10):1911-23. <https://doi.org/10.1016/j.jhsa.2008.10.013>
4. Nielson AB, Simonsen O. Displaced forearm fractures in children treated with AO plates. *Injury* 1984;15(6):393-6. [https://doi.org/10.1016/0020-1383\(84\)90204-3](https://doi.org/10.1016/0020-1383(84)90204-3)
5. Wyrsh B, Mencio GA, Green NE. Open reduction and internal fixation of pediatric forearm fractures. *J Pediatr Orthop* 1996;16(5):644-50. <https://doi.org/10.1097/00004694-199609000-00018>
6. Lieber J, Schmid E, Schmittbecher PP. Unstable diametaphyseal forearm fractures: transepiphyseal intramedullary Kirschner-wire fixation as a treatment option in children. *Eur J Pediatr Surg* 2010;20(6):395-8. <https://doi.org/10.1055/s-0030-1262843>

7. Miller BS, Taylor B, Widmann RF, Bae DS, Snyder BD, Waters PM. Cast immobilization versus percutaneous pin fixation of displaced distal radius fractures in children: a prospective, randomized study. *J Pediatr Orthop* 2005;25(4):490-4. <https://doi.org/10.1097/01.bpo.0000158780.52849.39>
8. Van Leemput W, De Ridder K. Distal metaphyseal radius fractures in children: reduction with or without pinning. *Acta Orthop Belg* 2009;75(3):306-9. PMID: 19681314
9. Cai H, Wang Z, Cai H. Prebending of a titanium elastic intramedullary nail in the treatment of distal radius fractures in children. *Int Surg* 2014;99(3):269-75. <https://doi.org/10.9738/INTSURG-D-13-00065.1>
10. Cai H, Wang Z, Cai H. Fixation of distal radial epiphyseal fracture: Comparison of K-wire and prebent intramedullary nail. *J Int Med Res* 2016;44(1):122-30. <https://doi.org/10.1177/0300060514566650>
11. Kim BS, Lee YS, Park SY, Nho JH, Lee SG, Kim YH. Flexible intramedullary nailing of forearm fractures at the distal metadiaphyseal junction in adolescents. *Clin Orthop Surg* 2017;9(1):101-8. <https://doi.org/10.4055/cios.2017.9.1.101>
12. Reinhardt KR, Feldman DS, Green DW, Sala DA, Widmann RF, Scher DM. Comparison of intramedullary nailing to plating for both-bone forearm fractures in older children. *J Pediatr Orthop* 2008;28(4):403-9. <https://doi.org/10.1097/BPO.0b013e31816d71f2>
13. Lascombes P, Prevot J, Ligier JN, Metaizeau JP, Poncelet T. Elastic stable intramedullary nailing in forearm shaft fractures in children: 85 cases. *J Pediatr Orthop* 1990;10(2):167-71. PMID: 231269
- Kang SN, Mangwani J, Ramachandran M, Paterson JMH, Barry M. Elastic intra-medullary nailing of paediatric fractures of the forearm: a decade of experience in a teaching hospital in the United Kingdom. *J Bone Joint Surg Br* 2011;93(2):262-5. <https://doi.org/10.1302/0301-620X.93B2.24882>
14. Clavien P, Barkun J, de Oliveira ML, Vauthey JN, Dindo D, Schulick RD, et al. The Clavien-Dindo classification of surgical complications. *Ann Surg* 2009;250(2):187-96. <https://doi.org/10.1097/SLA.0b013e3181b13ca2>
15. Pretell Mazzini J, Beck N, Brewer J, Baldwin K, Sankar W, Flynn J. Distal metaphyseal radius fractures in children following closed reduction and casting: can loss of reduction be predicted? *Int Orthop* 2012;36(7):1435-40. <https://doi.org/10.1007/s00264-012-1493-x>
16. Alemdaroglu KB, Iltar S, Cimen O, Uysal M, Alagöz E, Atlihan D. Risk factors in redisplacement of distal radial fractures in children. *J Bone Joint Surg Am* 2008;90(6):1224-30. <https://doi.org/10.2106/JBJS.G.00624>
17. Battle J, Carmichael KD, Morris RP. Biomechanical comparison of flexible intramedullary nailing versus crossed Kirschner wire fixation in a canine model of pediatric forearm fractures. *J Pediatr Orthop B* 2006;15(5):370-5. <https://doi.org/10.1097/01202412-200609000-00012>
18. Price CT, Rockwood CA, Wilkins KE, Beaty JH (eds.) *Forearm fractures in children*. 4<sup>th</sup> ed. Philadelphia: Lippincott-Raven; 1996.
19. Wilkins KE (ed.). *Operative management of upper extremity fractures in children*. Rosemont, Illinois: American Academy of Orthopaedic Surgeons; 1994.
20. Martus JE, Preston RK, Schoenecker JG, Lovejoy SA, Green NE, Mencio GA. Complications and outcomes of diaphyseal forearm fracture intramedullary nailing: a comparison of pediatric and adolescent age groups. *J Pediatr Orthop* 2013;33(6):598-607. <https://doi.org/10.1097/BPO.0b013e3182a11d3b>
21. Eamara P, Masquijo JJ. Enclavado endomedular elástico para el tratamiento de refracturas de antebrazo en niños. *Rev Asoc Argent Ortop Traumatol* 2018;83(4):242-7. <https://doi.org/doi:10.15417/issn.1852-7434.2018.83.4.813>