

Transient Synovitis of the Hip in a Pediatric Patient as an Atypical Initial Manifestation of COVID-19

Florencia Turazza, Joaquín Yunes, Diego Tourn, J. Javier Masquijo

Department of Pediatric Orthopedics and Traumatology, Sanatorio Allende, Córdoba, Argentina

ABSTRACT

We report the case of a pediatric patient with transient synovitis of the hip as an initial atypical manifestation of a COVID-19 infection. A 7-year-old boy presented with gait disturbance, limping, and pain in his right hip. After 12 days, the patient continued with functional limitations and had associated symptoms such as fatigue and fever. Because of the atypical course, he was admitted to the hospital for joint aspiration. Due to institutional protocols, the preoperative evaluation included a COVID-19 PCR test. The joint aspiration sample showed clear synovial fluid with inflammatory characteristics and negative bacterial culture. COVID-19 PCR test results came out positive during the patient's hospital stay. Clinical symptoms improved after the viral condition resolved. In the last follow-up, he was asymptomatic with a full hip range of motion. Transient synovitis of the hip could be an atypical initial symptom of a COVID-19 infection. Given the pandemic context of this disease, it is important to consider reactive arthritis as a consequence of this infection, especially in cases of atypical presentation, close family contact, fever, or other associated respiratory symptoms.

Keywords: Transient synovitis; COVID-19; children.

Level of Evidence: IV

Sinovitis transitoria de cadera en un niño como probable manifestación inicial atípica de COVID-19

RESUMEN

Comunicamos el caso de un niño con sinovitis de cadera como manifestación inicial atípica de una infección por SARS-CoV-2. Varón de 7 años que consultó por dificultad en la marcha e impotencia funcional con dolor localizado en la cadera derecha. El diagnóstico presuntivo fue sinovitis transitoria de cadera, por lo que recibió tratamiento conservador. A los 12 días, continuaba con impotencia funcional y presentó como decaimiento y fiebre. Ante la evolución atípica del cuadro, se decidió su internación para punción articular/drenaje. En la punción, se observó un líquido articular claro de aspecto inflamatorio que no presentó desarrollo en los cultivos bacterianos. Durante la internación, se confirmó el resultado positivo de la reacción en cadena de la polimerasa para SARS-CoV-2. El paciente evolucionó favorablemente una vez resuelto el cuadro viral. En el último seguimiento, no tenía síntomas y el rango de movilidad era completo. La sinovitis transitoria de cadera puede ser una manifestación clínica inicial atípica de COVID-19. En el contexto de la pandemia, es indispensable sospechar una posible artropatía reactiva como consecuencia del virus, principalmente cuando la presentación es atípica, hay contactos familiares estrechos, fiebre u otros síntomas respiratorios asociados.

Palabras clave: Sinovitis transitoria; COVID-19; SARS-CoV-2; niños.

Nivel de Evidencia: IV

INTRODUCTION

COVID-19 is an infectious disease caused by a coronavirus known as SARS-CoV-2. Most people infected with this virus have respiratory conditions of varying severity depending on their comorbidities. There have been recent reports of patients with symptoms involving other systems, such as the gastrointestinal or articular systems.^{1,2}

Received on July 29th, 2021. Accepted after evaluation on February 14th, 2022 • Dr. J. JAVIER MASQUIJO • javimasquijo@yahoo.com.ar  <https://orcid.org/0000-0001-9018-0612>

How to cite this article: Turazza F, Yunes J, Tourn D, Masquijo JJ. Transient Synovitis of the Hip in a Pediatric Patient as an Atypical Initial Manifestation of COVID-19. *Rev Asoc Argent Ortop Traumatol* 2022;87(3):387-392. <https://doi.org/10.15417/issn.1852-7434.2022.87.3.1414>

Transient synovitis of the hip is one of the most common causes of hip joint pain in children aged 3 to 10 years. Its etiology is not well defined, although it is usually associated with a viral condition in the days before the onset of pain.³ Although recent cases of reactive arthritis have been published in convalescent patients after SARS-CoV-2 infection⁴, there is little information on the presentation of arthralgia in the initial period of the disease.

The objective of this article is to report the case of a male with hip synovitis as an atypical initial manifestation of a SARS-CoV-2 infection.

CLINICAL CASE

A 7-year-old male with no pathological history consulted in the Emergency Department due to pain in the right hip joint of one week's evolution. The mother commented that the pain had been increasing since the day before the consultation, and that the child had difficulty walking, but tolerated standing. She did not report fever or feverish equivalents related to the pain, nor a history of falls or trauma to the lower limb. She also reported no recent respiratory or gastrointestinal symptoms or strenuous physical activity. The physical examination revealed pain upon movement of the right lower limb related to the hip, with defense upon passive flexion and internal rotation maneuvers.

Imaging studies were ordered, including radiographs and ultrasound of both hips. In the radiographic studies, no bone or soft tissue lesions were observed, with both joint spaces preserved. The ultrasound of the right hip showed a joint effusion with a detachment of 7 mm from the joint capsule (Figure 1). With these results and with the suspicion of transient synovitis, the patient began outpatient treatment with oral anti-inflammatory agents.

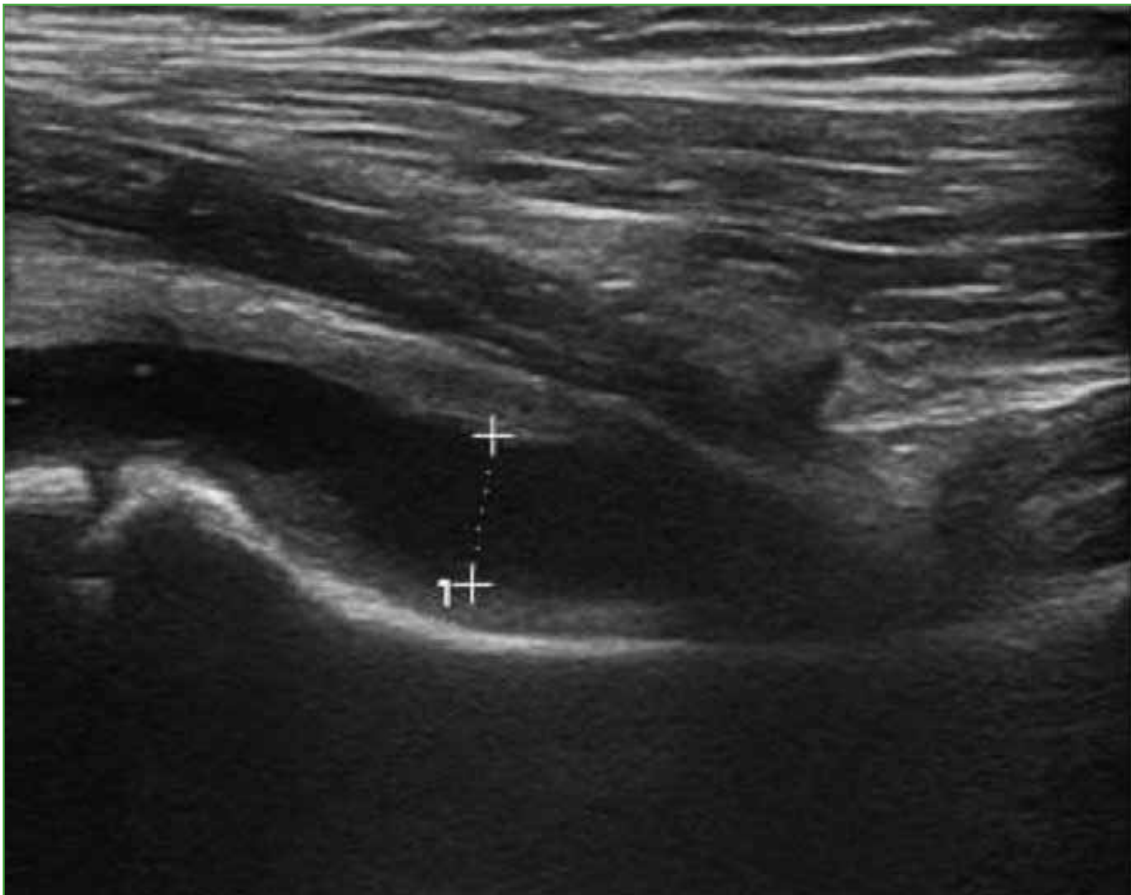

Figure 1. Hip ultrasound showing a right joint effusion with a detachment of 7 mm from the joint capsule, with intact muscle planes.

At 48 h, the patient was seen again in the outpatient clinic. The mother denied that he had a fever, but commented that the child was listless and had no appetite. The pain had not increased, but persisted, despite the indicated treatment. On physical examination, the patient continued to have pain upon movement of the right hip and limited range of motion. Biochemical tests were requested, the results of which were: white blood cell count 6.67 million/mm³ without shift in the differential (60/1/1/29/9), C-reactive protein 0.05 mg/dl; platelet count 292,000/mm³; PPA 96.8% and PTT 34.7" and a slight increase in erythrocyte sedimentation rate with a value of 40 mm. Three days later, a new control was performed in the outpatient clinic. The symptoms had improved and, the day before, he had had two temperature readings of 37.5 °C. New biochemical analyzes and an MRI of the hip were requested, which revealed the presence of hip joint effusion, without morphological changes or abnormalities in the intensity of the bone marrow signal (Figure 2).

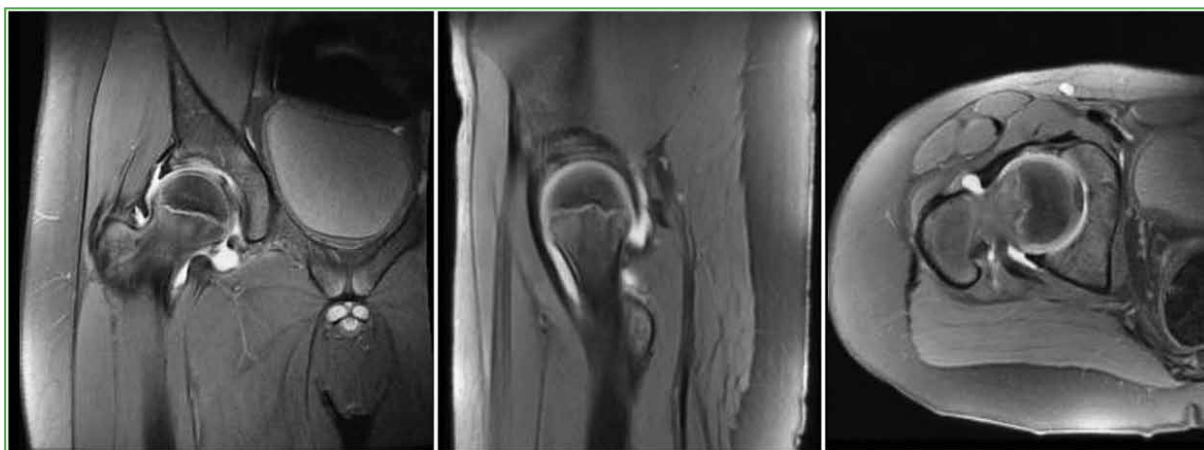


Figure 2. Magnetic resonance imaging of the hip, coronal, sagittal and axial planes, respectively, in PD FSE sequences. Hip joint effusion is observed, with preserved femoral and acetabular morphology, without signs of bone compromise.

It was decided to hospitalize the patient to perform a puncture and drainage of joint fluid and bacteriological analysis. Per the hospitalization protocol of the institution, a polymerase chain reaction study for SARS-CoV-2 was performed, which was positive. When inquiring about a possible epidemiological link, the mother reported having presented symptoms compatible with COVID-19 two months earlier, for which she had been ordered to home isolation with her family. Surgery was performed and samples of joint fluid were taken. At the time of puncture, a clear, yellowish fluid with a viscous consistency was obtained. The patient remained hospitalized for three days, had a good evolution, and was discharged, but with an indication of isolation for him and the close contacts who lived with him at home. The bacteriological analysis did not report the development of germs. The patient evolved favorably once the viral condition resolved. At the last follow-up, the child was symptom-free and had a full hip range of motion. The radiograph showed no changes in the affected joint (Figure 3).

To carry out this work, we carried out a literature search in PubMed and Embase that included those articles that dealt with reactive synovitis of the hip or other joints in the pediatric population, in the context of a SARS-CoV-2 infection or with a positive epidemiological link for the virus. Articles on reactive arthritis related to COVID-19 in the adult population were not included.

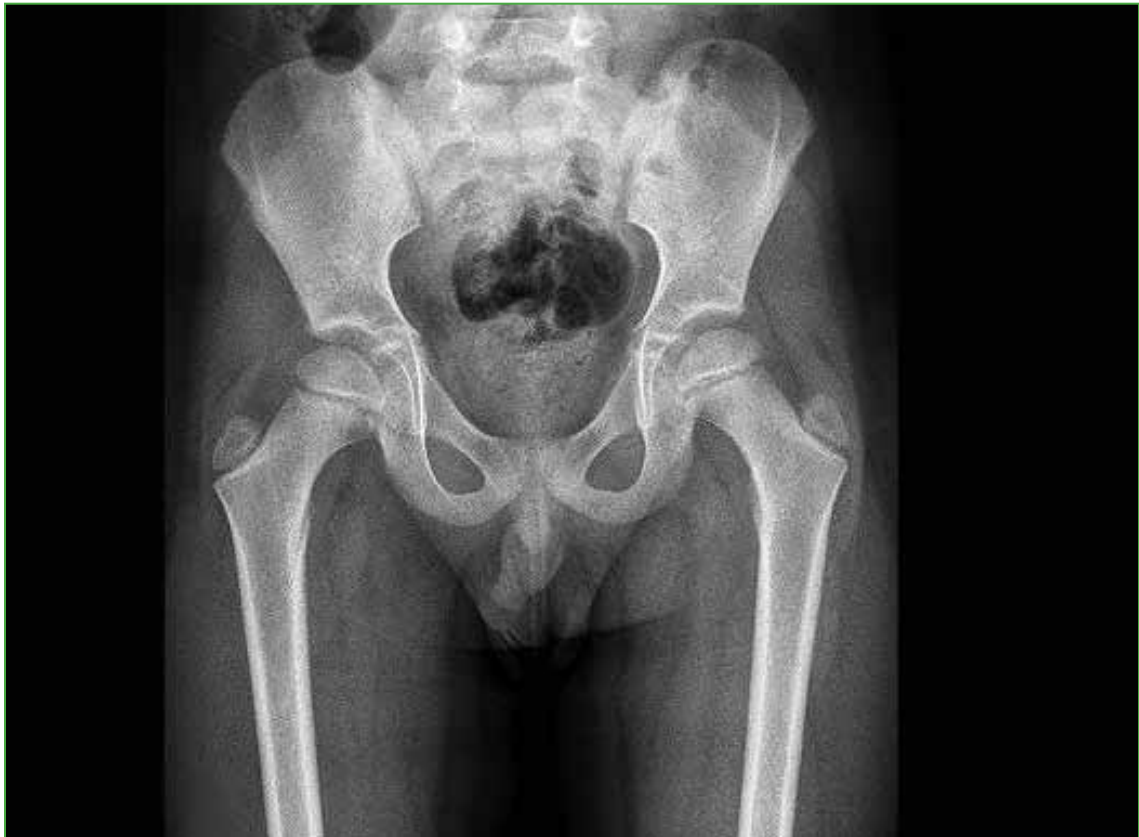

Figure 3. Anteroposterior radiograph of the hip at 6 months of evolution. There are no signs of bone compromise.

DISCUSSION

Viral infections are a well-known cause of arthritis, and are well studied for some viruses, such as parvovirus and hepatitis B virus.⁵ COVID-19 viral arthralgia has been described in the adult population as a symptom that is independent of the respiratory condition, which can manifest as the only symptom of infection or, more commonly, as reactive arthritis in convalescent patients.⁴ Although the pathogenesis is unknown, several hypotheses have been proposed. It is known that coronaviruses have proteins on their surface that interact with the receptor of the host cell for their entry and replication. In the case of SARS-CoV-2, this protein binds to the receptor for angiotensin-converting enzyme 2 found predominantly in the stomach, intestines, bladder, kidneys, and heart (extrapulmonary manifestations of SARS-CoV-2 infection).⁶ This receptor has also been detected in the synovial membrane and can cause arthritis due to direct synovial damage. Another possibility is joint damage due to immune complex deposition, as in the case of arthritis due to hepatitis B.⁷

Transient synovitis is one of the most common causes of hip joint pain in the pediatric population. It is usually associated with a previous infection of the upper respiratory tract or gastrointestinal tract, 10 to 20 days before the onset of pain. Although its pathogenesis has not been well described, some studies, such as that by Leibowitz et al.,⁸ support the theory of a viral origin, since, in their cohort, patients diagnosed with transient synovitis had high serum levels of interferon. Although SARS-CoV-2 infection in the pediatric population usually occurs asymptotically (healthy carriers) or with mild symptoms, a small percentage may suffer from a severe form that is known today as post-COVID pediatric inflammatory multisystem syndrome (PIMS), similar to Kawasaki disease or toxic shock syndrome.⁹ For this reason, the possibility of other forms of extrapulmonary presentation of this infection in the pediatric population is currently being considered, and the initial symptom could be rheumatological or muscle/joint involvement.

In 2020, Bauman¹⁰ published the case of a 10-year-old girl who met epidemiological criteria for COVID-19 (both symptomatic parents) and, 11 days after the symptoms began in the father, presented right coxalgia with joint effusion, fever, and cough. In the IgG antibody test, both parents and the girl had increased values. Sinaei et al.¹¹ reported two cases of patients aged 8 and 6 years, with a history of mild respiratory symptoms and fever who, one week later, presented left coxalgia and dysbasia with findings of joint effusion on ultrasound. In the first case, these symptoms lasted for three weeks, while the other child had concomitant arthralgias in both wrists. Test results for SARS-CoV-2 revealed increased IgG and positive polymerase chain reaction. In our case, although the patient did not report a history of respiratory symptoms or fever, he did have symptoms of synovitis of erratic evolution without clinical improvement despite conservative treatment. Likewise, he had an epidemiological history of close contact with a positive case, which made us suspect that it could be reactive arthritis associated with COVID-19. There is still little information on the muscle/joint presentation of SARS-CoV-2 infection in both adults and children. Our case complements the information from previous case reports^{10,11} that patients with COVID-19 could develop symptoms of joint irritation similar to those of other viral arthralgias, even without other associated symptoms.

CONCLUSIONS

Transient synovitis of the hip may be an atypical initial clinical manifestation of COVID-19. In a pandemic context, it is essential to suspect the possibility of reactive arthropathy as a consequence of the virus, especially if there are close family contacts, fever, or other associated respiratory symptoms. Further studies are required to elucidate the underlying mechanisms of arthralgia associated with COVID-19 and to determine its long-term implications.

Conflict of interest: The authors declare no conflicts of interest.

J. Yunes ORCID ID: <https://orcid.org/0000-0002-2487-4592>
D. Tourn ORCID ID: <https://orcid.org/0000-0002-7149-5798>

F. Turazza ORCID ID: <https://orcid.org/0000-0002-8705-0304>

REFERENCES

1. Gupta A, Madhavan MV, Sehgal K, Nair N, Mahajan S, Sehrawat TS, et al. Extrapulmonary manifestations of COVID-19. *Nat Med* 2020;26(7):1017–32. <https://doi.org/10.1038/s41591-020-0968-3>
2. Disser NP, De Micheli AJ, Schonk MM, Konnaris MA, Piacentini AN, Edon DL, et al. Musculoskeletal consequences of COVID-19. *J Bone Joint Surg Am* 2020;102(14):1197–204. <https://doi.org/10.2106/JBJS.20.00847>
3. Whitelaw CC, Varacallo M. Transient Synovitis. 2021 Jun 29. In: *StatPearls [Internet]. Treasure Island (FL): StatPearls Publishing; 2021 Jan–. PMID: 29083677*
4. Hoong CWS, Amin MNME, Tan TC, Lee JE. Viral arthralgia: a new manifestation of COVID-19 infection? A cohort study of COVID-19-associated musculoskeletal symptoms. *Int J Infect Dis* 2021;104:363-9. <https://doi.org/10.1016/j.ijid.2021.01.031>
5. Zerrak A, Bour JB, Tavernier C, Dougados M, Maillefert JF. Usefulness of routine hepatitis C virus, hepatitis B virus, and parvovirus B19 serology in the diagnosis of recent-onset inflammatory arthritides. *Arthritis Rheum* 2005;15(53(3):477-8. <https://doi.org/10.1002/art.21182>
6. Mokuda S, Tokunaga T, Masumoto J, Sugiyama E. Angiotensin-converting enzyme 2, a SARS-CoV-2 receptor, is upregulated by interleukin 6 through STAT3 signaling in synovial tissues. *J Rheumatol* 2020;47(10):1593-5. <https://doi.org/10.3899/jrheum.200547>
7. Wands JR, Mann E, Alpert E, Isselbacher KJ. The pathogenesis of arthritis associated with acute hepatitis-B surface antigen-positive hepatitis. Complement activation and characterization of circulating immune complexes. *J Clin Invest* 1975;55(5):930-6. <https://doi.org/10.1172/JCI108022>

8. Leibowitz E, Levin S, Torten J, Meyer R. Interferon system in acute transient synovitis. *Arch Dis Child* 1985;60(10):959-62. <https://doi.org/10.1136/adc.60.10.959>
9. Taffarel P, Jorro Barón F, Rodríguez AP, Widmer J, Meregallia C. Multisystem inflammatory syndrome in children related to COVID-19: An update regarding the presentation of two critically ill patients. *Arch Argent Pediatr* 2021;119(1):e26-e35. <https://doi.org/0.5546/aap.2021.eng.e26>
10. Baumann Q. Transient synovitis of the hip and SARS-CoV2. Temporality study about one case. Temporality study about one case. *Ann Pediatr* 2020;3(1):1025. <https://meddocsonline.org/annals-of-pediatrics/transient-synovitis-of-the-hip-and-SARS-CoV2-temporality-study-about-one-case.pdf>
11. Sinaei R, Pezeshki S, Sinaei R, Shiari R, Yeganeh MH, Parvaresh S, et al. Post nCoV-2 limping child: report of two cases and a rapid review. *Pediatr Rheumatol* 2020. <https://doi.org/10.21203/rs.3.rs-59943/v1>