

Case Presentation

Ricardo Trueba

*Resonance and Computed Tomography Department, Grupo Médico Rostagno,
Diagnóstico por Imágenes, Autonomous City of Buenos Aires, Argentina*

Case resolution on page 867.

A 27-year-old professional handball player consulted for pain in the posterior region of the foot. As a history, he manifested having had a complete rupture of the Achilles tendon that was surgically solved a year before. During the anamnesis and the clinical examination, pain in the calcaneus was detected, increasing with flexion-extension movements of the foot. Radiographs, magnetic resonance imaging (MRI), and ultrasound of the Achilles tendon with the “power Doppler” technique were requested as complementary studies.

FINDINGS AND INTERPRETATION OF IMAGING STUDIES

The radiograph showed a thickened Achilles tendon with insertion elements at the calcaneal level (Figure 1).

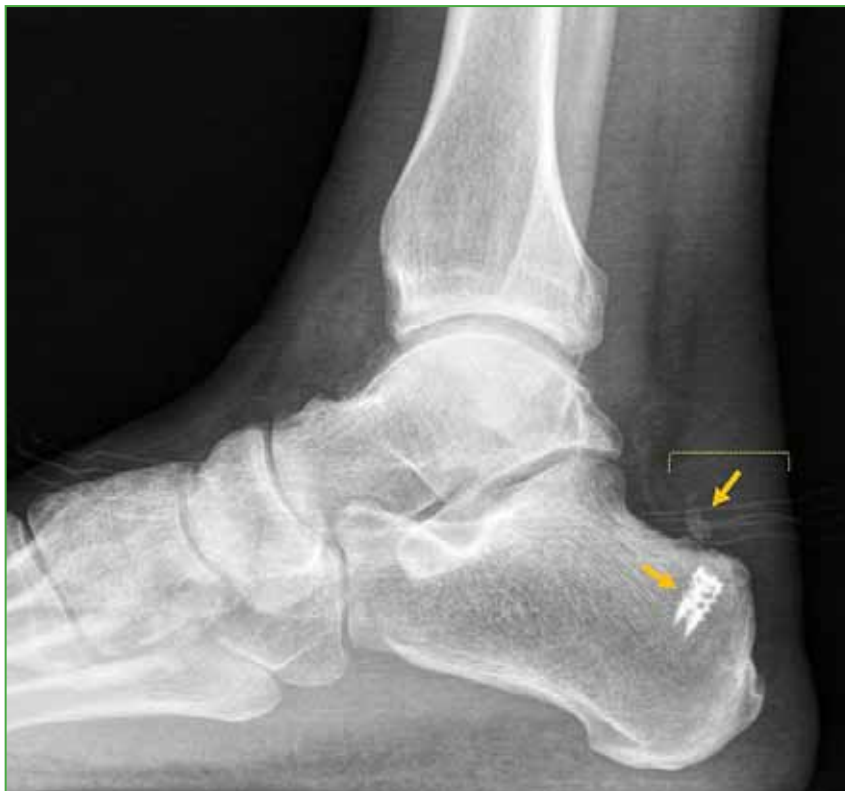

Figure 1. Lateral radiograph of the ankle showing thickening of the Achilles tendon. The screws on the dorsal calcaneus used for reattachment and small remaining calcifications of chronic tendinopathy are recognized.

Dr. RICARDO TRUEBA • ricardotrueba@gmail.com  <https://orcid.org/0000-0001-7908-817X>

How to cite this article: Trueba R. Postgraduate Orthopedic Instruction - Imaging. Case Presentation. *Rev Asoc Argent Ortop Traumatol* 2021;86(6):1852-7434. <https://doi.org/10.15417/issn.1852-7434.2021.86.6.1392>

MRI confirmed the findings of chronic tendinopathy without significant signal changes at the distal insertion (Figures 2 and 3).

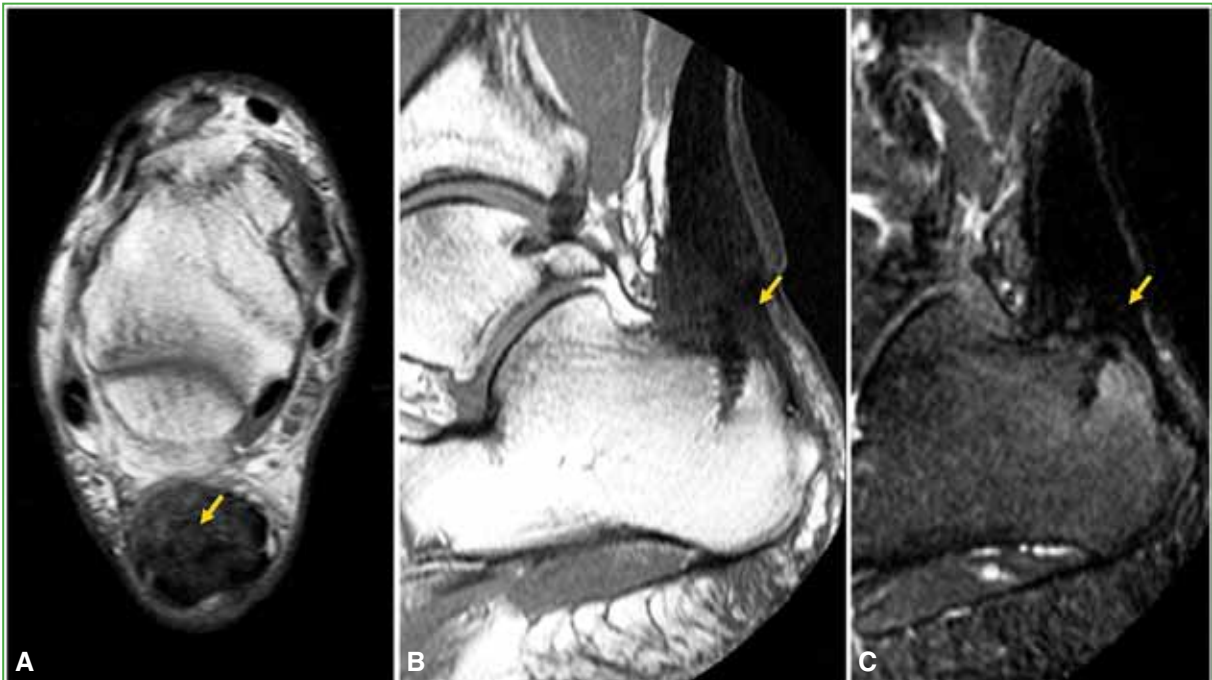


Figure 2. Ankle MRI. Axial T1 (A), sagittal T1 (B), and STIR (C) sequences. Tendon thickening is observed with intermediate signal in the T1 sequence and low in the STIR sequence at the level of reinsertion.

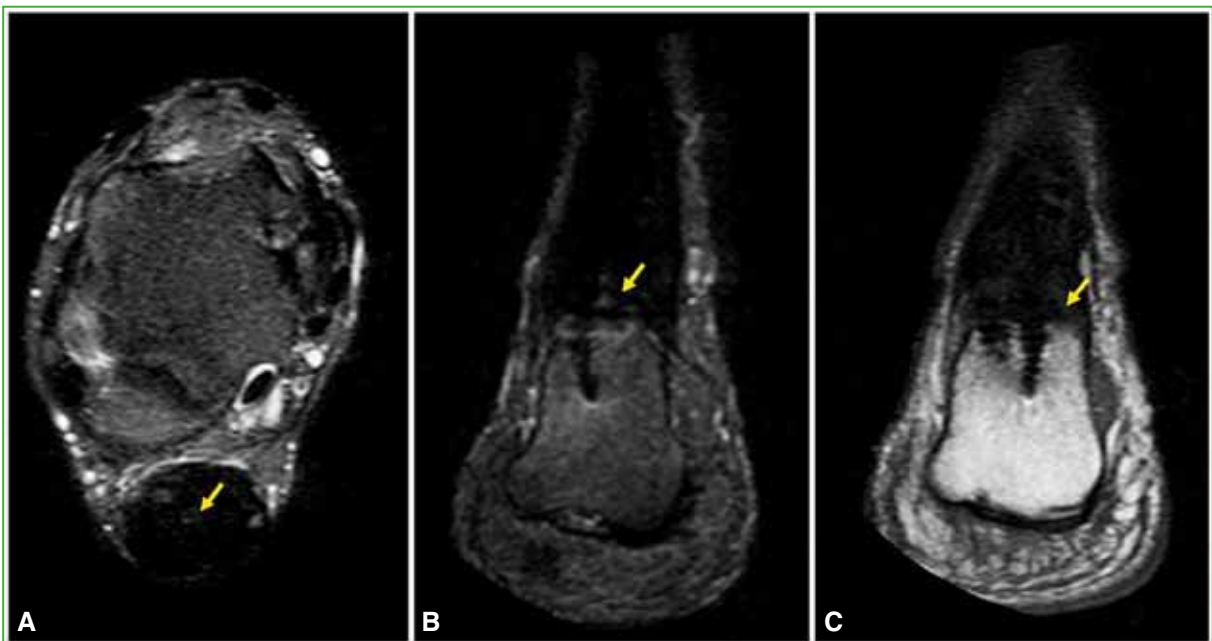


Figure 3. Ankle MRI. Axial STIR (A), coronal STIR (B), and T1 (C) sequences. Tendon thickening is observed with intermediate signal in the T1 sequence and low in the STIR sequence at the level of reinsertion.

The patient had several MRIs that showed similar findings without revealing the diagnosis of his ailment. It was decided to complete the study with a power Doppler ultrasound. The conventional ultrasound study showed the same findings as MRI; however, when adding the “power Doppler” technique, a clear increase in vascularization was observed in the reinsertion zone (Figure 4).

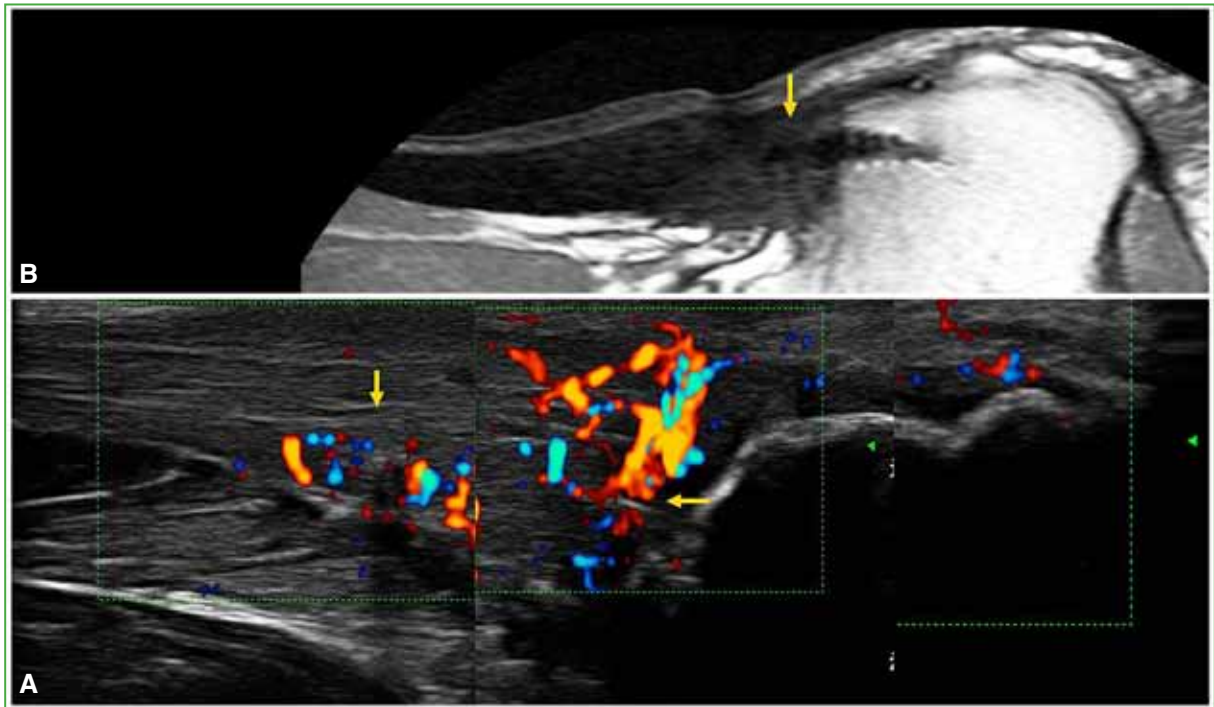


Figure 4. (A) Long-axis ultrasound in the distal third of the Achilles tendon with the “power Doppler” technique. This technique shows the large neovascularization in the reattachment area probably associated with the patient’s pain. The rest of the ultrasound study showed the same findings as the MRI. (B) Magnetic resonance imaging in the T1 sagittal plane to understand the ultrasound image.