

Total Hip Arthroplasty in a Patient with Paget's Disease. Case Report

Victoria Eugenia Restrepo-Noriega^{*}, Iván Darío Serna Maya^{*}, Diego L. Guzmán-Benedek^{*}, Manuela Corrales-González^{*}

^{*}Centro de Cuidado Clínico - Reemplazos Articulares, Clínica el Rosario - Sede Centro, Medellín, Colombia

ABSTRACT

Introduction: Paget's disease is a metabolic disorder of unknown etiology, secondary to an increase in the function of osteoclasts and the consequent response of osteoblasts to excessive bone formation. It most commonly involves the proximal femur and is often diagnosed incidentally. We present the case of a woman with a history of Paget's disease and nonunion of the left hip, with indications for a total left hip prosthesis and a single episode of dislocation, without subsequent complications and an adequate evolution. **Conclusion:** Surgical management in cases of hip fracture allows to restore walking and improves the quality of life of patients with Paget's disease. Despite being a pathology that makes patient management difficult, Paget's disease is not a contraindication for total hip arthroplasty and allows the improvement of pain and restoration of functionality.

Keywords: Paget's disease, total hip arthroplasty, bisphosphonates, hip, surgery, dislocation.

Level of Evidence: IV

Artroplastia total de cadera en paciente con enfermedad de Paget. Presentación de un caso

RESUMEN

Introducción: La enfermedad de Paget es un trastorno metabólico de etiología desconocida, secundario a un incremento en la función de los osteoclastos y la consecuente respuesta de los osteoblastos a la formación exagerada de hueso. Compromete con mayor frecuencia el fémur proximal y, a menudo, se diagnostica incidentalmente. Se presenta el caso de una mujer con antecedente de enfermedad de Paget y pseudoartrosis de cadera izquierda, con indicaciones de prótesis total de cadera izquierda y un episodio único de luxación, sin complicaciones posteriores y una adecuada evolución. **Conclusión:** El manejo quirúrgico en casos de fractura de cadera permite restablecer la marcha y mejorar la calidad de vida de los pacientes con enfermedad de Paget. A pesar de ser una patología que dificulta el manejo de los pacientes, la enfermedad de Paget no es una contraindicación para la artroplastia total de cadera y permite mejorar el dolor y recuperar la funcionalidad.

Palabras clave: enfermedad de Paget, artroplastia total de cadera, bifosfonatos, cadera, cirugía, luxación.

Nivel de Evidencia: IV

INTRODUCTION

Paget disease is a metabolic disorder secondary to an increase in the function of osteoclasts and the consequent response of osteoblasts to excessive bone formation. Of unknown etiology and multifactorial behavior, Paget disease most often involves the proximal femur and is diagnosed, in most cases, incidentally due to increased alkaline phosphatase or radiological findings. The cornerstone of management is antiresorptive therapy with bisphosphonates and, in cases of fractures, internal fixation or even total hip arthroplasty becomes an alternative to improve the patient's quality of life.

Received on June 1st, 2021. Accepted after evaluation on March 1st, 2022 • Dr. VICTORIA EUGENIA RESTREPO-NORIEGA • vickyrestrepo025@hotmail.com  <https://orcid.org/0000-0001-8703-7882>

How to cite this article: Restrepo-Noriega V.E., Serna Maya I.D., Guzmán-Benedek D.L., Corrales-González M. Total Hip Arthroplasty in a Patient with Paget's Disease. Case Report. *Rev Asoc Argent Ortop Traumatol* 2022;87(5):693-702. <https://doi.org/10.15417/issn.1852-7434.2022.87.5.1386>

The purpose of this paper is to present the short-term evolution (3 years) of a patient with Paget disease undergoing total hip arthroplasty after internal fixation failure with a long intramedullary nail for the management of a subtrochanteric fracture. We aim to provide a therapeutic alternative in cases of fractures with pseudarthrosis or nonunion.

CLINICAL CASE

A 63-year-old woman residing in the city of Medellin, Colombia. She was an independent worker with a previous diagnosis of Paget disease with polyostotic presentation, diagnosed incidentally due to radiological findings and family history. In 2015, the patient suffered a fall from her own height and a subtrochanteric fracture of the left hip was verified, which was given surgical management at another institution. We consider that the fracture occurred in a previously pathological bone compromised by Paget disease (Figures 1 and 2).

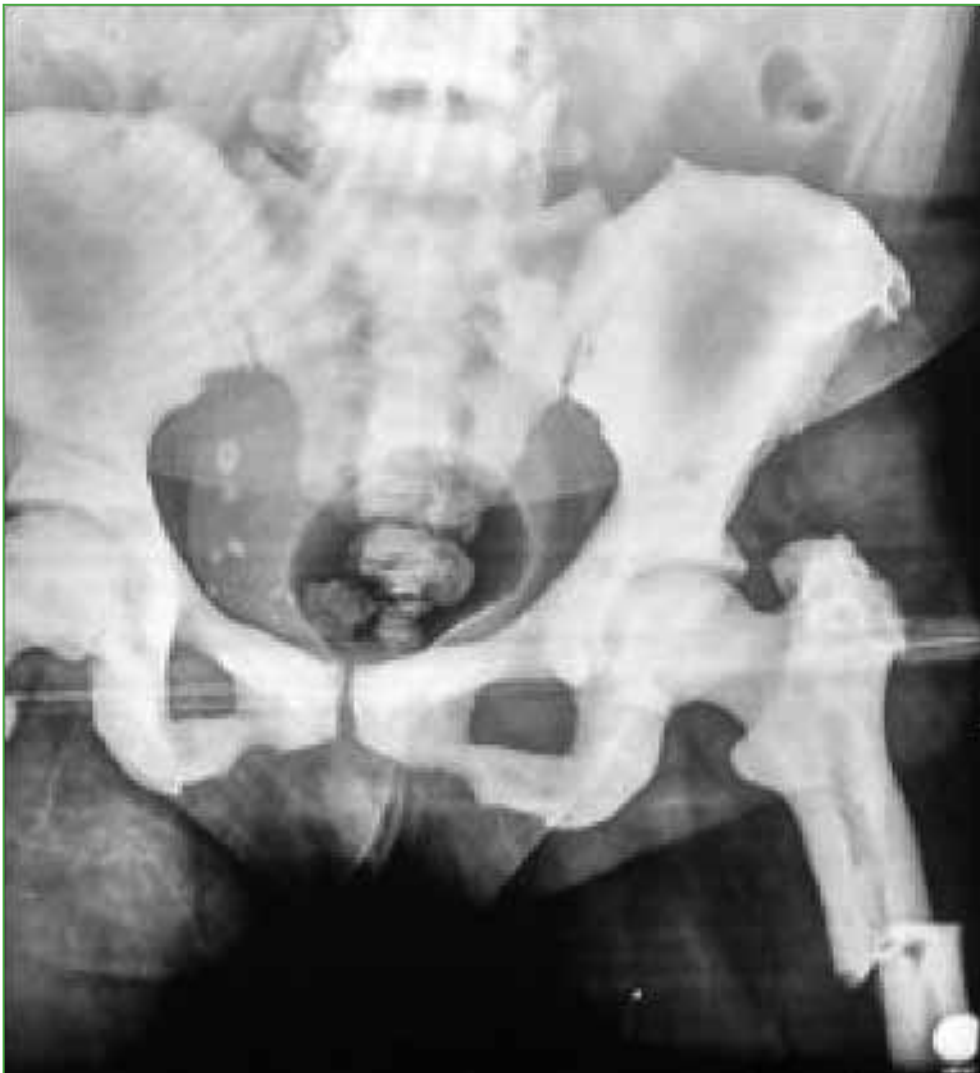

Figure 1. Subtrochanteric fracture of the left hip in pathological femur, with radiological findings suggestive of Paget disease (cotton wool appearance).

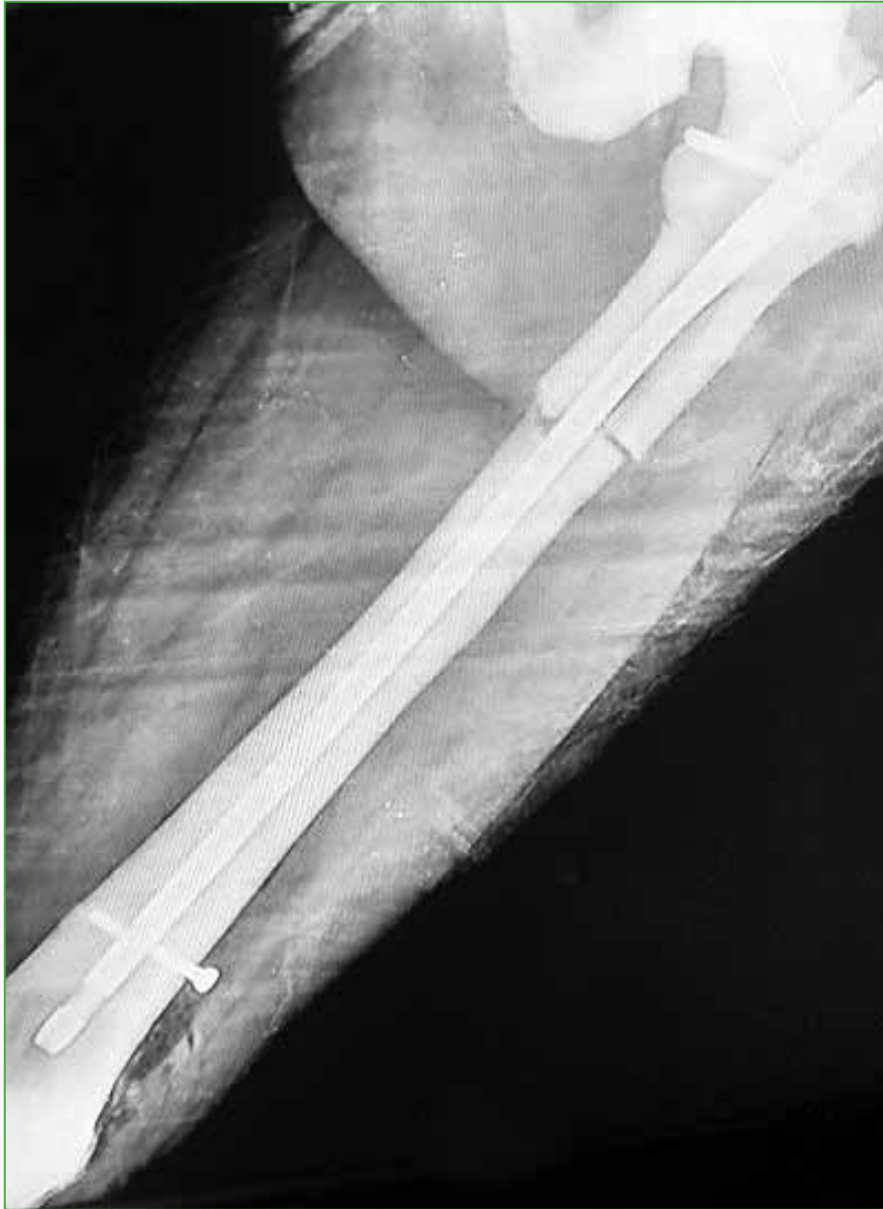

Figure 2. Postoperative control radiograph of osteosynthesis of the proximal femur with a long locking intramedullary nail.

During the postoperative evolution, due to the presence of pseudarthrosis (diagnosed 6 months after the operation and managed in another institution), the osteosynthesis material (locking intramedullary nail) was removed and the femoral head was resected, so a resection arthroplasty remained (Figures 3 and 4).

In 2016, the patient consulted at the institution due to persistent severe pain and gait limitation in the left hip, with a control radiograph showing massive bone loss in the proximal femur, a healthy surgical scar, and no signs of infection. After evaluation by multiple specialists and assessment by the *Centro de Cuidado Clínico de Reemplazos Articulares* [Joint Replacement Clinical Care Center], the patient was considered eligible for surgery and a total left hip replacement was scheduled.

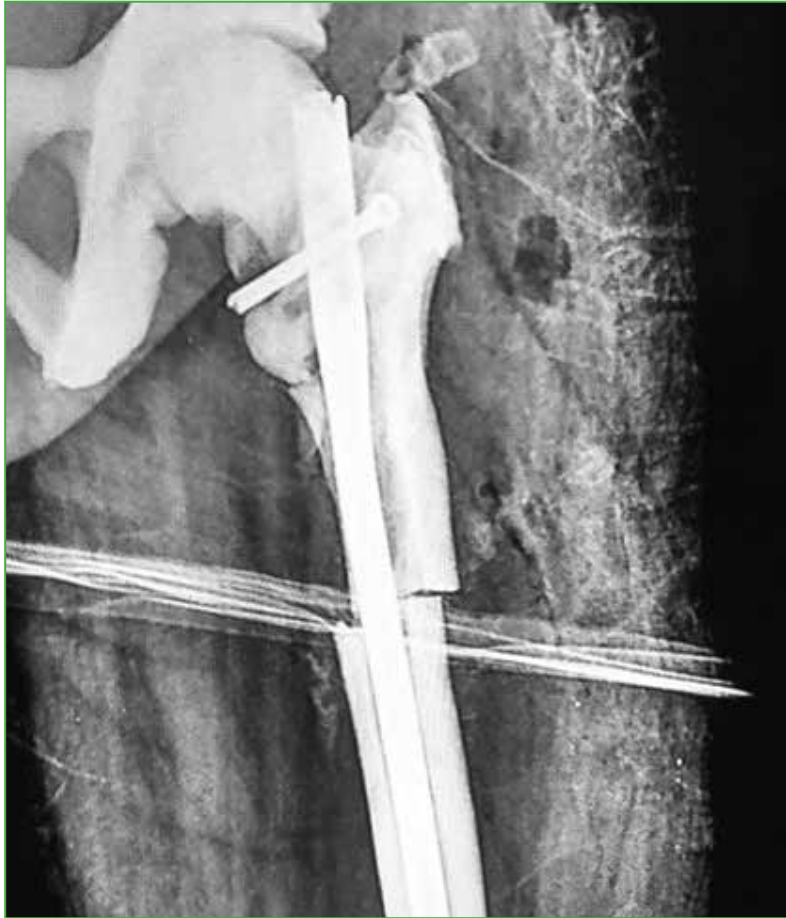


Figure 3. Fracture nonunion, osteolysis of the medial cortical bone of the proximal fragment of the femur and an image suggesting a fracture of the femoral neck.

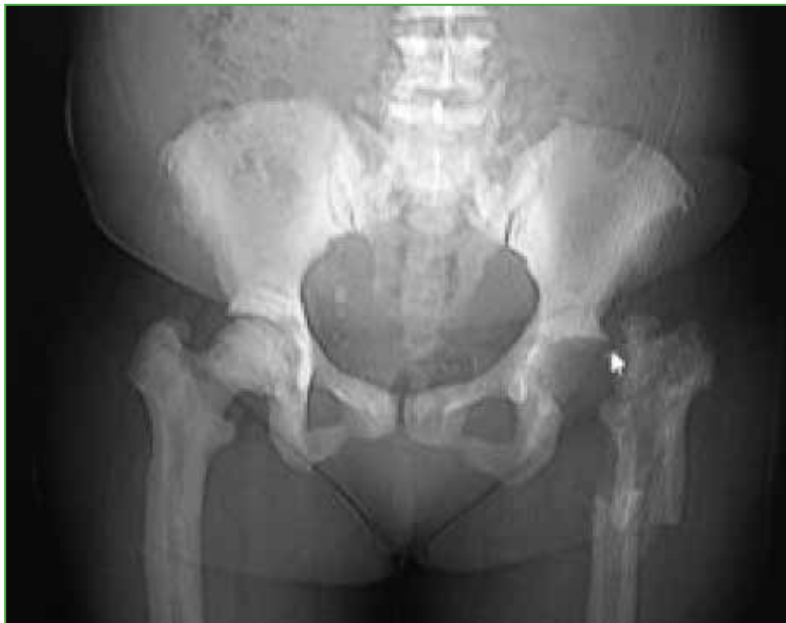

Figure 4. Postoperative control radiograph of removal of osteosynthesis material plus interposition arthroplasty with resection of the femoral head.

In February 2018, said intervention was performed together with a corrective osteotomy of the proximal femur and proximal ostectomy at the level of the trochanter through a posterolateral approach, without complications. A 44 x 28 uncemented acetabulum was implanted, together with 4 acetabular fixation screws, a 44 x 28 highly cross-linked polyethylene insert, a 140 mm x 13 mm uncemented revision stem with proximal metaphysis, with a wing for the fixation of the hip abductor mechanism and a 28M cobalt-chromium head (Figure 5).

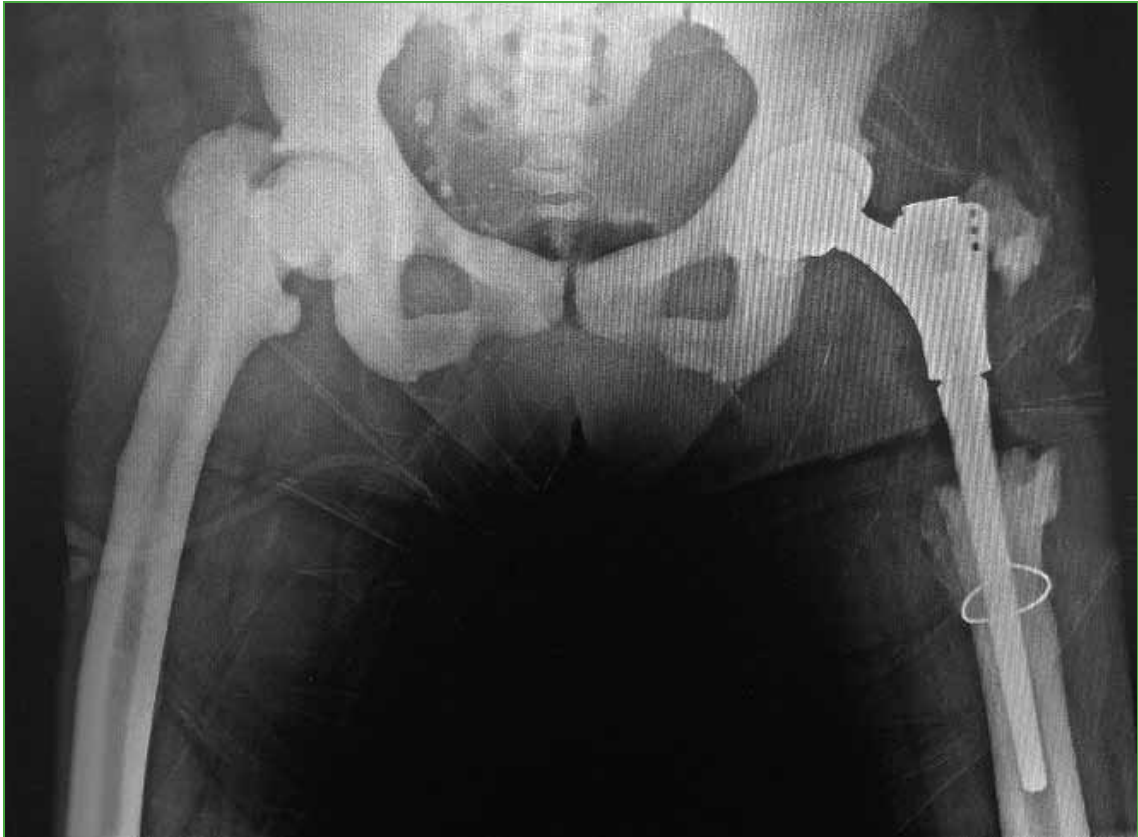

Figure 5. Postoperative control radiograph of total left hip prosthesis plus osteotomy and ostectomy of the proximal femur.

In March 2018, the patient consulted the emergency department of the institution due to intense pain in the left hip, shortening of the limb and limitations in weight-bearing and walking, with no history of a fall. The control radiograph showed a posterior dislocation of the total left hip prosthesis (Figure 6). After several attempts at closed reduction of the dislocation under general anesthesia and due to the persistence of instability, an open reduction of the prosthesis dislocation was performed, with an intraoperative finding of disinsertion of the hip abductor mechanism, with no signs of infection or loosening of the components. Therefore, the repair and new fixation to the metaphysis flap of the femoral stem were performed, without complications (Figure 7).

After open reduction, the patient presented a satisfactory clinical and radiological evolution (3-year follow-up), with occasional mild pain, range of motion from 0 to 110°, abduction of 30°, internal rotation of 20°, and external rotation of 20°. She walks with a cane and has returned to work activities. To date, she has not had any other episodes of dislocation and control radiographs at 1 year and 3 years show no signs of loosening or osteolysis (Figure 8).

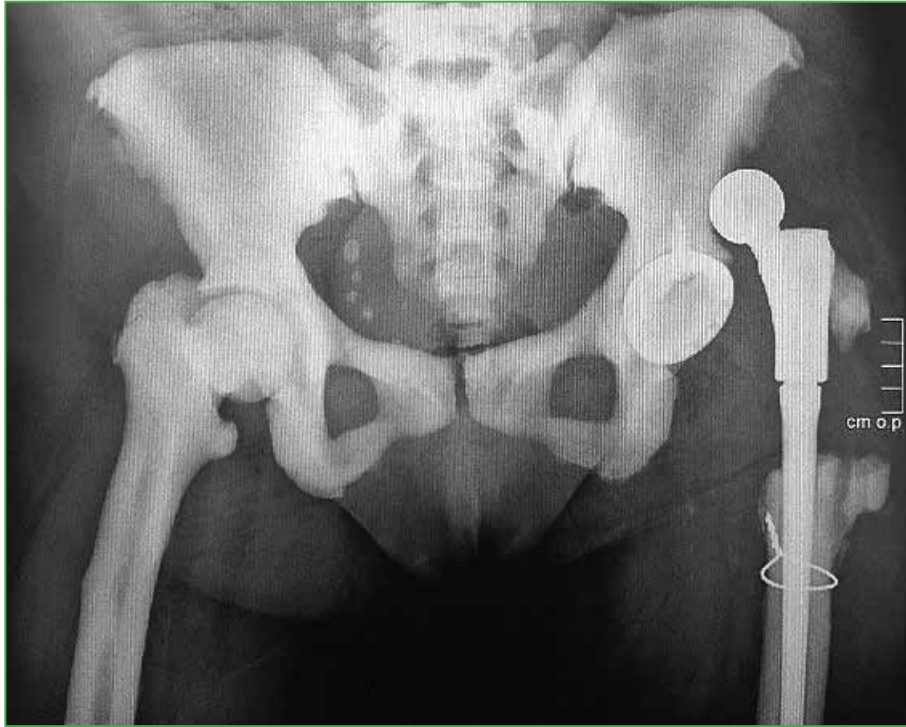

Figure 6. Posterior dislocation of total left hip prosthesis, with no history of falls.

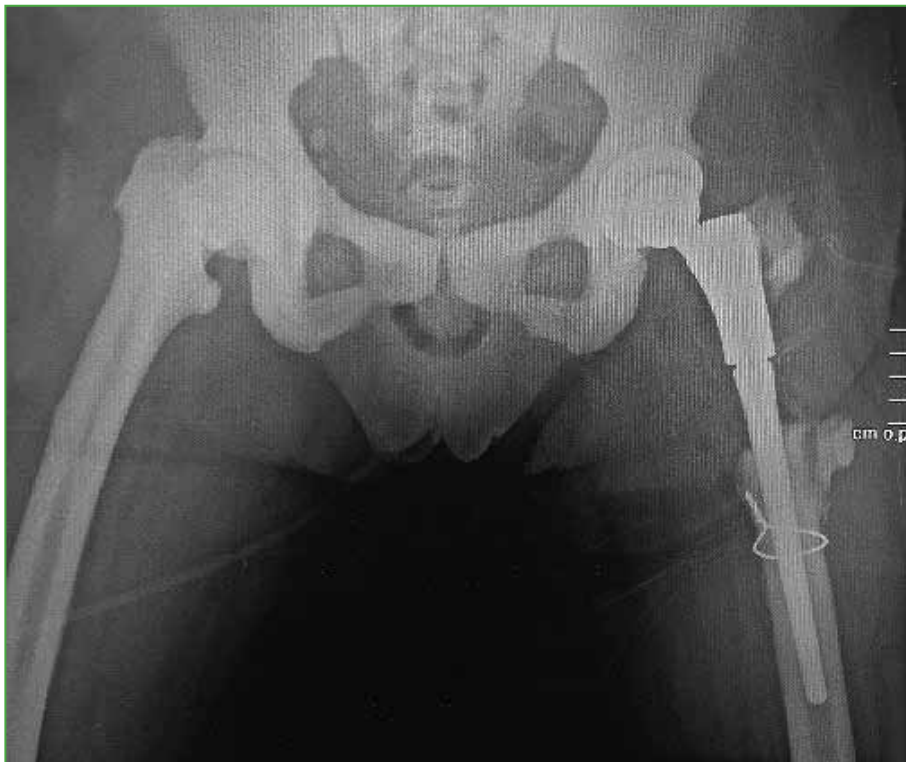

Figure 7. Postoperative control radiograph of open reduction of dislocation and reattachment of the hip abductor mechanism.

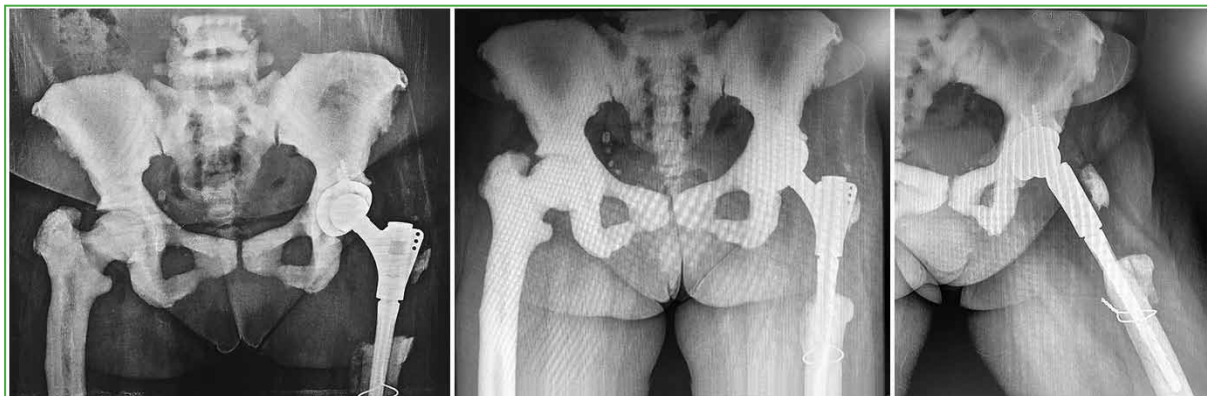


Figure 8. From left to right: Postoperative control radiograph a year later, without dislocations, loosening or osteolysis. Postoperative control radiograph at 3 years, without loosening or osteolysis of the prosthesis.

DISCUSSION

Paget disease or osteitis deformans, first described by Sir James Paget in 1877 at St. Bartholomew's, in London,^{1,2} is a metabolic disorder secondary to an increase in the function of osteoclasts and the consequent exaggerated response of osteoblasts to bone formation, which leads to a complete loss of bone homeostasis.¹ The prevalence is higher in patients older than 55 years and in countries such as Great Britain (3-5%), the United States, Canada, Australia and New Zealand.¹

The etiology is still unknown, but the most accepted hypothesis is that latent infection by viruses of the *Paramyxoviridae* family (measles virus, respiratory syncytial virus, canine distemper virus) in genetically predisposed individuals can trigger the disease.³ Approximately 15% of patients have a family history of the disease, which is due to autosomal dominant inheritance with incomplete penetrance, where almost half of the patients have a family history and 5-10% of those with disease *de novo* have a mutation in the SQSTM1 gene, encoded in p62 and responsible for a protein production that is fundamental in the regulation of osteoclast function.⁴

However, it is known that some external factors can influence the development of the disease, which assumes a multifactorial behavior, where the patient's nutrition, exposure to infections and sedentary lifestyle can play an important role.⁴

Under physiological conditions, the human skeleton undergoes complete remodeling every 2 to 4 years, with the appearance of 3-5 active osteoclast nuclei in each anatomical region, but in patients with Paget disease, osteoclasts increase their activity by almost 9 times, as well as increasing in number (10 to 100 times more than normal), which leads to the formation of approximately 100 nuclei of osteoclastic activity, which by positive feedback allow increased recruitment of osteoblasts and the consequent formation of bone matrix.^{1,5,6}

Although both osteoclastic and osteoblastic activities occur in the disease, three well-differentiated phases explain its pathophysiology and can occur simultaneously in different anatomical sites. In the first phase or osteolytic phase, there is an increase in bone resorption and hypervascularization. In phase two or mixed phase (osteoblastic/osteoclastic), in addition to constant bone resorption by osteoclasts, there is an increase in the formation of new bone matrix by osteoblasts. However, the mineralization of this matrix is not adequate, which leads to the replacement of lamellar bone by random bone tissue, with less deforming capacity and resistance. In phase three or the sclerotic phase, osteoclastic activity decreases, leading to the formation of disordered, dense, and sclerotic bone tissue.^{1,7}

In most patients, the diagnosis of Paget disease is incidental, either due to the finding of increased alkaline phosphatase levels or the characteristic radiological findings, with 20-25% of cases being asymptomatic. However, many patients may present bone pain, skeletal deformities, fractures, deafness, symptoms of nerve compression or headache due to skull deformity, symptoms that are related to the involvement of a single bone (monoostotic form) or several bones (polyostotic form).

Regarding bone pain, it must be taken into account that it increases with rest, it is predominantly nocturnal, improves with activity and is very difficult to manage with analgesics, which is why, in many cases, it leads to the initial suspicion of an oncological condition. It should be noted that the most common tumor in patients with Paget's disease is osteosarcoma, with an incidence of 0.2-1%.¹

The characteristic bone deformities are tibia antecurvatum (saber tibia) and femoral antecurvatum and laterocurvatum (shepherd crook), which explains the frequency in the location of fractures in these patients, which may be traumatic or pathological. These occur more frequently distal to the lesser trochanter in the femur (20-80%)⁸ and in the proximal third of the tibia. Pelvic involvement is usually asymptomatic, except when the hip joint is involved and there is acetabular protrusion.^{9,10}

Other clinical manifestations include cardiovascular complications associated with decreased peripheral vascular resistance and increased cardiac output, nephrolithiasis, hypercalcemia and hyperuricemia, among others.

As already mentioned, patients with Paget's disease have increased levels of alkaline phosphatase, which are closely related to the extent and severity of the disease. However, some patients may present normal or slightly elevated values. In order to rule out false positives, bone-specific alkaline phosphatase should be measured and liver function tests performed.¹¹ Serum calcium and 25-hydroxy vitamin D levels are usually normal.

Radiological findings include, in the first phase, well-defined areas of osteolysis; in the second phase, areas with cotton wool appearance, which indicate mixed bone activity; and, in the third phase, bone with sclerotic characteristics become more predominant than lytic images. Although radiographs represent a great diagnostic aid, the best diagnostic aid to identify polyostotic presentation is bone scintigraphy.¹²

Regarding treatment, the cornerstone is antiresorptive therapy with bisphosphonates (zoledronic acid, pamidronate, alendronate, risedronate), which is indicated in specific circumstances: 1. symptomatic patients with active bone lesions; 2. as prophylaxis in patients with evidence of active lesions in high-risk areas (weight-bearing bones or sites of potential nerve compression); 3. alkaline phosphatase levels 2 to 4 times the upper limit; 4. before surgery, when the procedure involves bone tissue affected by the disease; and 5. hypercalcemia secondary to immobilization.¹

In cases of adverse reactions to bisphosphonates due to gastrointestinal symptoms, atypical fractures, atrial fibrillation, osteonecrosis of the jaw, hypocalcaemia or musculoskeletal pain, or when their use is contraindicated (stage IV and V renal failure, pregnancy), therapy with calcitonin SC can be chosen, which has already been approved by the FDA.¹

It should be noted that all patients with fractures must be managed comprehensively, in order to improve their quality of life and achieve rapid return of the patient to their daily activities, which reduces subsequent complications. It must be taken into account that, due to the pathophysiology of the disease and bone biomechanical differences, many of the fractures, whether treated orthopedically or with internal fixation, may present delayed consolidation (average of 26-42 weeks to consolidate),^{13,14} nonunion or even failure, which represents a challenge for the treating physician,¹³ as described in this report.

Taking into account the case of our patient, total hip arthroplasty, both cemented and uncemented, has resulted in very good functional outcomes. However, bone hypervascularity, sclerotic tissue, and profuse bleeding during surgery have been shown to limit cement penetration and interdigitation, leading to increased risk of long-term loosening of cemented prostheses,^{15,16} which causes almost 15% of revisions in these patients.^{8,15,17} This situation has led to an increase in the use of uncemented implants and the pre- and postoperative use of antiresorptive therapy, which allows a decrease in disease activity and bleeding, reduces pain and lowers the rate of long-term complications.^{18,19} For this reason, and due to the condition of the femoral bone tissue in the case presented, we decided to perform an uncemented total hip arthroplasty with revision stem, secondary to the removal of the previously implanted osteosynthesis material. This also allowed us to avoid both intraoperative and postoperative complications, which are more prevalent in these patients (as was the case of dislocation or detachment of the hip abductor mechanism). The careful selection and use of implants allow proper management of these complications and their minimization in the future.

CONCLUSIONS

Paget disease is not a contraindication for total arthroplasties, despite being a pathology that makes it difficult to manage patients with a history of fracture. Even though this condition increases the complexity of the procedure due to bone quality, bone physiological characteristics and the high risk of complications, total arthroplasties are indicated in order to improve the patient's quality of life and, as far as possible, achieve the disappearance of pain and functional limitations.

The purpose of this article was to present a surgical alternative for patients with this type of comorbidities and its adequate evolution, which allows us to increase the range of possibilities in patients who would otherwise be treated with femoral head resection (Girdlestone arthroplasty) and protected support.

However, the high risk of intra- and postoperative complications cannot be underestimated, so the management of these patients must be in expert hands in order to minimize these risks, ensure the success of the procedure, and appropriately manage possible eventualities in the future such as pain, loosening or even infection.

Ethical considerations

The patient gave her informed consent and the study was authorized and approved by the research ethics committee of Clínica el Rosario - Sede Centro, Medellín, Colombia.

Conflict of interest: The authors declare no conflicts of interest.

I.D. Serna Maya ORCID ID: <https://orcid.org/0000-0002-6650-280X>

D.L. Guzmán-Benedek ORCID ID: <https://orcid.org/0000-0002-1324-814X>

M. Corrales-González ORCID ID: <https://orcid.org/0000-001-7612-5529>

REFERENCES

1. Kravets I. Paget's disease of bone: diagnosis and treatment. *Am J Med.* 2018;131(11):1298-303. <https://doi.org/10.1016/j.amjmed.2018.04.028>
2. Crego-Vita D, Aedo-Martin D, Sánchez-Pérez C. Case report of early aseptic loosening of total hip arthroplasty in monostotic paget disease, a diagnostic challenge. *Int J Surg Case Rep.* 2016;24:215-8. <https://doi.org/10.1016/j.ijscr.2016.05.050>
3. Siris E, Ottman R, Flaster E, Kelsey JL. Familial aggregation of Paget's disease of bone. *J Bone Miner Res.* 1991;6(5):495-500. <https://doi.org/10.1016/j.ijscr.2016.05.050>
4. Ralston SH, Layfield R. Pathogenesis of Paget's disease of bone. *Calcif Tissue Int.* 2012;91(2):97-113. <https://doi.org/10.1007/s00223-012-9599-0>
5. Reddy SV. Etiology of Paget's disease and osteoclast abnormalities. *J Cell Biochem.* 2004;93(4):688-96. <https://doi.org/10.1002/jcb.20256>
6. Vallet M, Ralston SH. Biology and treatment of Paget's disease of bone. *J Cell Biochem.* 2016;117(2):289-99. <https://doi.org/10.1002/jcb.25291>
7. Schneider D, Hofmann MT, Peterson JA. Diagnosis and treatment of Paget's disease of bone. *Am Fam Physician.* 2002;65(10):2069-72. PMID: 12046775
8. Wegrzyn J, Pibarot V, Chapurlat R, Carret JP, Béjui-Hugues J, Guyen O. Cementless total hip arthroplasty in Paget's disease of bone: a retrospective review. *Int Orthop.* 2010;34(8):1103-9. <https://doi.org/10.1007/s00264-009-0853-7>
9. Siris E, Roodman GD. Paget's disease of bone. In: Rosen CJ, Compston JE, Lian JB (eds). *ASBMR Primer on the metabolic bone diseases and disorders of mineral metabolism.* 7th ed. American Society for Bone and Mineral Research, New Jersey: Wiley; 2008: 335-43.

10. Kang H, Park YC, Yang KH. Paget's disease: skeletal manifestations and effect of bisphosphonates. *J Bone Metab.* 2017;24(2):97-103. <https://doi.org/10.11005/jbm.2017.24.2.97>
11. Shankar S, Hosking DJ. Biochemical assessment of Paget's disease of bone. *J Bone Miner Res.* 2006;21(Suppl 2):22-27. <https://doi.org/10.1359/jbmr.06s20>
12. Theodorou DJ, Theodorou SJ, Kakitsubata Y. Imaging of Paget disease of bone and its complications: review. *AJR Am J Roentgenol.* 2011;196(6Suppl):S64-S75. <https://doi.org/10.2214/AJR.10.7222>
13. Khurjekar KS, Vidyadhara S, Dheenadhayalan J, Rajasekaran S. Spontaneous rapid osteolysis in Paget's disease after internal fixation of subtrochanteric femoral fracture. *Singapore Med J.* 2006;47(10):897-900. PMID: 16990967
14. Shardow DL, Giannoudis PV, Matthews SJ, Smith RM. Stabilisation of acute femoral fractures in Paget's disease. *Int Orthop.* 1999;23(5):283-5. <https://doi.org/10.1007/s002640050372>
15. McDonald DJ, Sim FH. Total hip arthroplasty in Paget's disease a follow-up note. *J Bone Joint Surg Am.* 1987;69(5):766-72. PMID: 3597478
16. Imbuldeniya A, Tai S, Aboelmagd T, Walter WL, Wlaler WK, Zicat BA. Cementless hip arthroplasty in Paget's Disease at long-term follow-up (average of 12,3 years). *J Arthroplasty.* 2014;29(5):1063-6. <https://doi.org/10.1016/j.arth.2013.10.015>
17. Amundsen S, Koenig K, Goodwin D, Memoli V. Failure of primary total hip arthroplasty secondary to new onset of Paget disease. A case report. *JBJS Case Connect.* 2015;5(1):e19-e5. <https://doi.org/10.2106/JBJS.CC.M.00096>
18. Werner de Castro GR, Fernandes de Castro SA, Pereira IA, Zimmermann AF, Toscano MA, Souza Neves F, et al. Determinants of quality of life in Paget's Disease of bone. *Rev Bras Reumatol. (Engl Ed)* 2017;57(6):566-73. <https://doi.org/10.1016/j.rbre.2017.06.002>
19. Lozano-Calderon SA, Colman MW, Raskin KA, Hornicek FJ, Gebhardt M. Use of bisphosphonates in orthopedic surgery. Pearls and pitfalls. *Orthop Clin North Am.* 2014;45(3):403-16. <https://doi.org/10.1016/j.ocl.2014.03.006>