

# Total Knee Replacement in Patients with Ankylosis. Report of Three Cases and Literature Review

Juan Ignacio Pérez Abdala, Ignacio García-Mansilla, Tomás Nicolino, Carlos Yacuzzi, Lisandro Carbó, Julián Costantini, Matías Costa Paz

Knee Sector, Institute of Orthopedics and Traumatology "Prof. Dr. Carlos E. Ottolenghi", Hospital Italiano de Buenos Aires, Buenos Aires, Argentina

## ABSTRACT

**Introduction:** Performing a Total Knee Replacement (TKR) in patients with ankylosed knees is technically demanding and associated with considerable complications. The purpose of this study is to report three cases of patients with ankylosed knees treated with TKR and present an updated literature review. **Materials and Methods:** We evaluated etiologies, preoperative range of motion, surgical technique, and type of implant utilized in each case. Complications and postoperative range of motion were also analyzed. Radiographs were used to evaluate loosening or osteolysis. Lastly, we performed an updated literature review. **Results:** The etiologies were juvenile rheumatoid arthritis in two cases and chronic osteomyelitis in one. The patients did not have a range of motion at all and the ability to perform daily life activities was severely affected. A medial parapatellar approach was used in all cases followed by an extensive soft tissue release. A primary posterior-stabilized design was used in two cases and a rotating-hinge design in one case. The mean postoperative range of motion was 90° and all three patients reported a high satisfaction rate. No complications were reported. **Conclusions:** TKR in patients with ankylosed knees has substantially improved the clinical outcome and the arc of motion. Due to its complexity, it must be approached as revision surgery, with careful preoperative planning.

**Keywords:** Ankylosis; knee; arthroplasty.

**Level of Evidence:** IV

## Reemplazo total de rodilla en pacientes con anquilosis. Reporte de tres casos y revisión bibliográfica

## RESUMEN

**Introducción:** El reemplazo total de rodilla en pacientes con anquilosis representa un desafío para el cirujano, tanto por la alta demanda técnica de la cirugía como por la elevada tasa de complicaciones comunicada. El objetivo de este artículo es presentar tres pacientes con anquilosis tratados con un reemplazo total de rodilla y una revisión bibliográfica actualizada. **Materiales y Métodos:** Se evaluaron las distintas etiologías, la movilidad preoperatoria, la técnica quirúrgica y el tipo de implante utilizado en cada caso. En el seguimiento, se evaluaron la tasa de complicaciones, el rango de movilidad y la supervivencia del implante. Por último, se realizó una revisión actualizada de la bibliografía. **Resultados:** Dos pacientes tenían artritis reumatoide juvenil y uno, una secuela de osteomielitis crónica de rodilla. Los pacientes no tenían movilidad articular y sufrían un severo compromiso para realizar las actividades de la vida cotidiana. En los tres pacientes, se efectuó un abordaje parapatelario medial seguido de una amplia liberación de partes blandas. En dos casos, se utilizaron prótesis primarias con vástagos y, en el restante, una prótesis de bisagra rotacional. El rango de movilidad alcanzado fue de 90° en promedio y los pacientes refirieron una tasa alta de satisfacción. No se registraron complicaciones. **Conclusiones:** El reemplazo total de rodilla en pacientes con anquilosis es una opción terapéutica por considerar, y tiene un impacto beneficioso en la calidad de vida. Por la complejidad que representa debe afrontarse como una cirugía de revisión, con una detenida planificación preoperatoria.

**Palabras clave:** Anquilosis; rodilla; artroplastia.

**Nivel de Evidencia:** IV

Received on May 30<sup>th</sup>, 2021. Accepted after evaluation on June 24<sup>th</sup>, 2021 • Dr. JUAN IGNACIO PÉREZ ABDALA • ignacio.perez@hospitalitaliano.org.ar  <https://orcid.org/0000-0002-5398-6876>

**How to cite this article:** Pérez Abdala JI, García-Mansilla I, Nicolino T, Yacuzzi C, Carbó L, Costantini J, Costa Paz M. Total Knee Replacement in Patients with Ankylosis. Report of Three Cases and Literature Review. *Rev Asoc Argent Ortop Traumatol* 2021; 86 (4) :519-528. <https://doi.org/10.15417/issn.1852-7434.2021.86.4.1383>

## INTRODUCTION

Total knee arthroplasty (TKA) aims to improve pain and range of motion, provide stability and enable an adequate quality of life, taking into account the expectations of each patient.<sup>1-3</sup> Success is based, in part, on the functional outcomes obtained, and the preoperative range of motion is a determining variable in the expected postoperative range.<sup>3-5</sup> Between 1% and 13% of primary replacements are performed in patients with knee stiffness.<sup>3,6-8</sup> The most common etiologies are primary osteoarthritis, rheumatoid arthritis, post-traumatic osteoarthritis and sequelae of an infectious disease.<sup>3,6,9</sup> At least two scenarios are distinguished in these patients: those with a range of motion  $<50^\circ$  and those without knee range of motion, these conditions are called stiffness and ankylosis, respectively.<sup>3,6,10,11</sup> The latter causes a severe compromise of quality of life due to the functional limitations it generates; therefore, surgical management plays an inexorable role.<sup>12,13</sup>

This situation poses a great challenge for the surgeon, both due to the highly demanding surgical technique and the high complication rate published.<sup>11,12</sup> Surgery should be treated as a revision, with detailed preoperative planning. The approach is a key point in these cases. It is often necessary to expand it by adding surgical steps, such as the release of the lateral retinaculum, osteotomy of the anterior tibial tuberosity, *rectus snip* or V-Y quadricepsplasty.<sup>3,6,11-15</sup> Due to soft tissue retraction, ligament structures are difficult to identify, which can lead to complications such as rupture of the patellar tendon or ligament avulsions. For this reason, it is often necessary to use prosthetic designs with greater constriction.

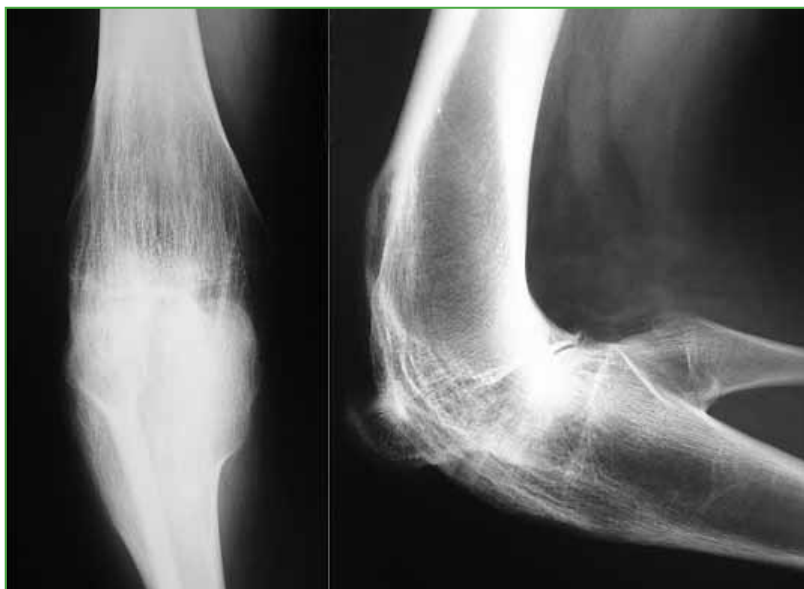Postoperative complications are considerable, the published rate reaches 53% and most of them are wound infections and necrosis.<sup>6,8,13,16-18</sup> However, the quality of life of patients improves considerably and a high satisfaction rate is reported.<sup>6,9,19</sup>

Due to the low incidence of this condition, the literature is scarce and, to a large extent, these are series with a small number of patients. This article aims to present three patients with ankylosis treated with TKA and to carry out a literature review of the topic.

## CLINICAL CASES

### Case 1

An 18-year-old woman with juvenile rheumatoid arthritis and a surgical intervention during childhood. She presented ankylosis of the right knee in  $100^\circ$  flexion, without significant deformity in the coronal plane. The left knee had a range of motion of  $90^\circ$ , with a flexion contracture of  $30^\circ$ . She had difficulty walking, going up and down stairs, and sitting down. The *Knee Society Score* (KSS) of the right knee measured before surgery was 26/50. On radiographs, both tibiofemoral and patellofemoral bone ankylosis of the right knee could be observed (Figure 1).

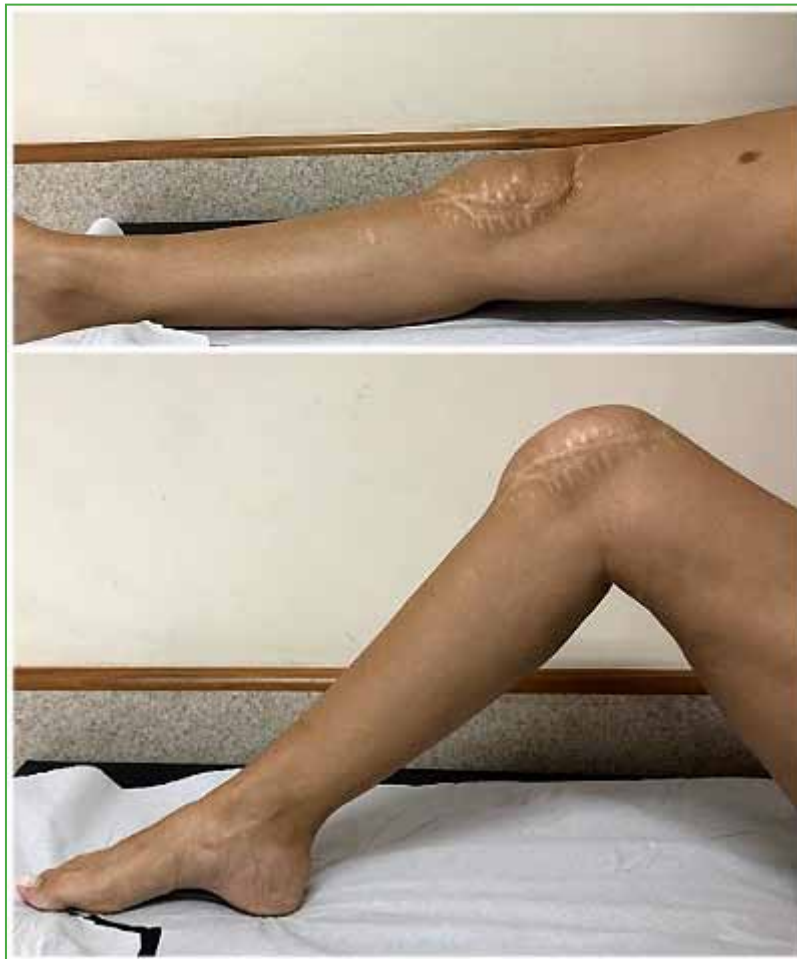

**Figure 1.** Preoperative anteroposterior and lateral radiograph of the right knee.

### *Surgical technique*

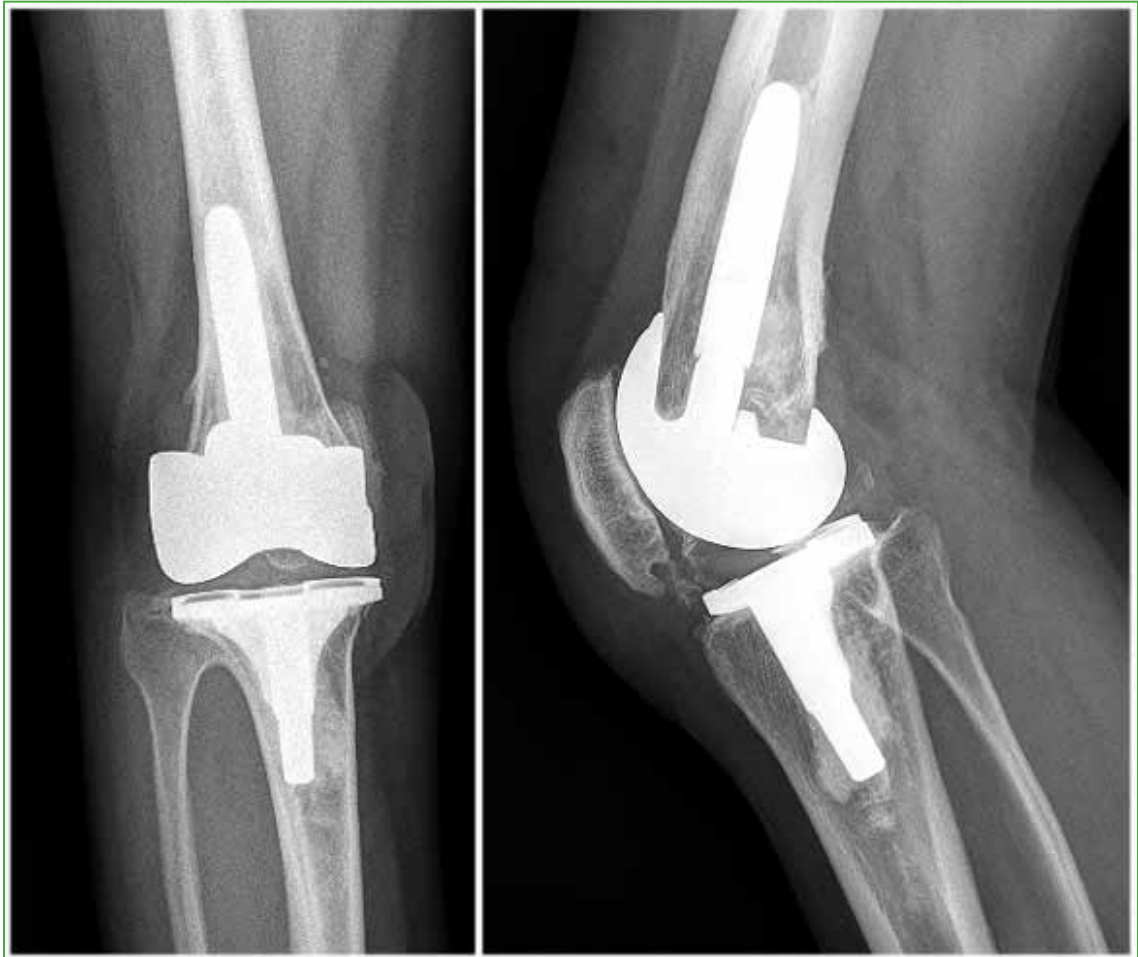The anterior approach was used and a medial parapatellar arthrotomy was performed, followed by the release of adhesions and subperiosteal dissection on-demand until the patellofemoral ankylosis was exposed. An osteotomy was performed, the Hoffa's fat pad was resected as needed and the patella was dislocated to the side. The gutters were restored and a tibiofemoral osteotomy was performed. First, the tibial cut was performed with an extramedullary guide, achieving a good posterior vision to release soft tissue, allowing a full extension. Femoral cuts were made with an intramedullary guide, and the gaps were evaluated. The components were tested and patellar tracking was evaluated; in some situations, the lateral release was necessary. In this case, a correct joint balance and good stability were achieved; therefore, a posterior stabilized primary prosthesis with tibial and femoral stem was used.

At 13 years of follow-up, the patient has a range of motion of 90°, with a full extension (Figure 2).



**Figure 2.** Clinical images of the postoperative range of motion.

Radiographs show no signs of loosening (Figure 3). The KSS on the right knee improved to 86/90. The patient manifests to be satisfied with the results obtained.

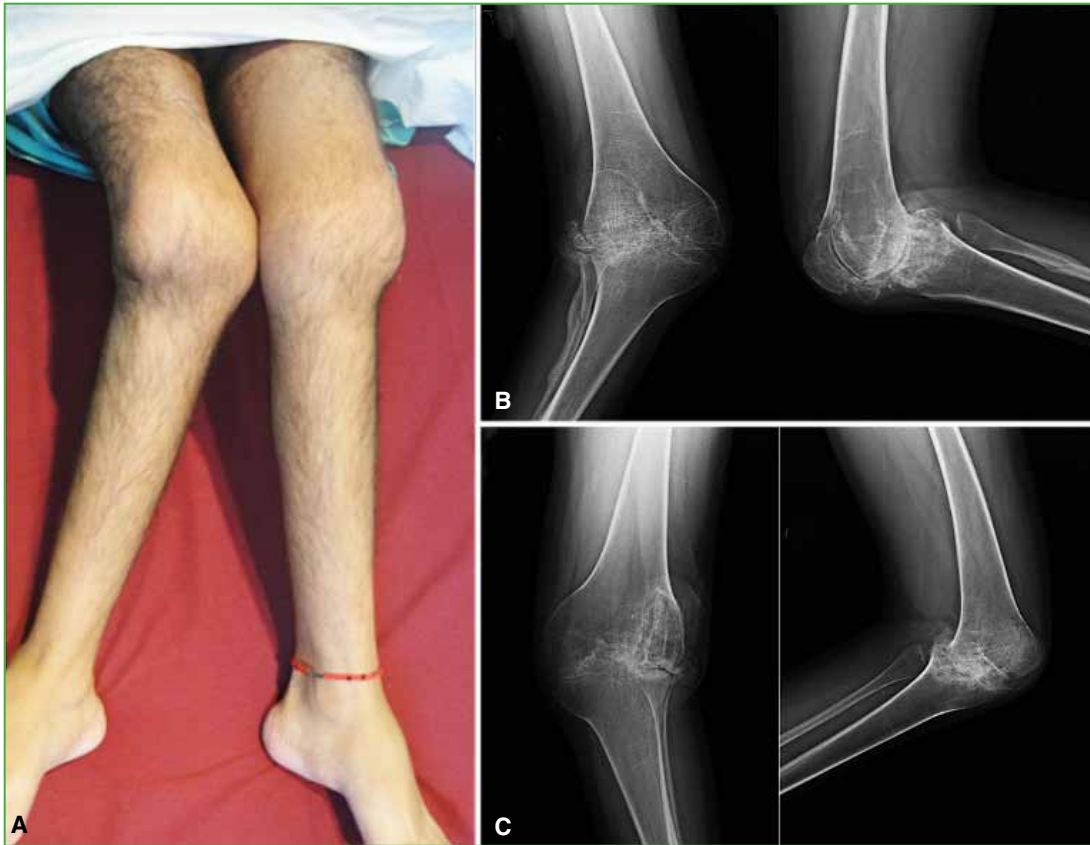

**Figure 3.** Postoperative anteroposterior and lateral radiograph of the right knee.

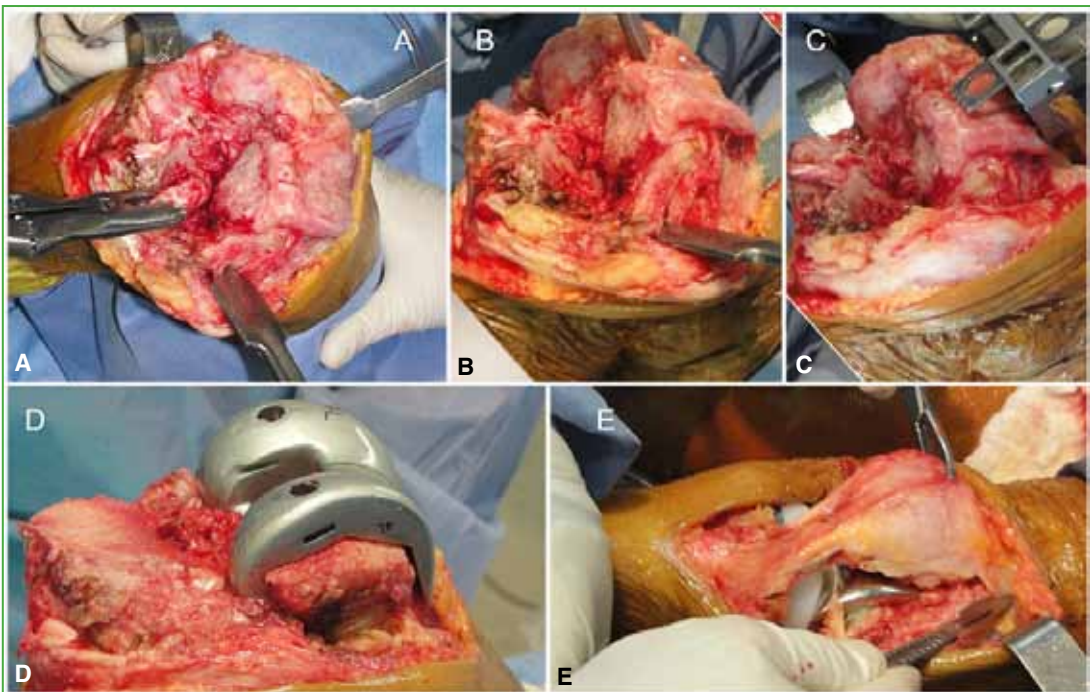
## Case 2

A 28-year-old male with a history of juvenile rheumatoid arthritis. He had ankylosis and severe valgus of both knees (Figure 4). The left knee had a flexion of 70°, and the right, 60°. The KSS was 11/45 for the right knee and 15/45 for the left knee. The patient had severe limitations in daily life activities.

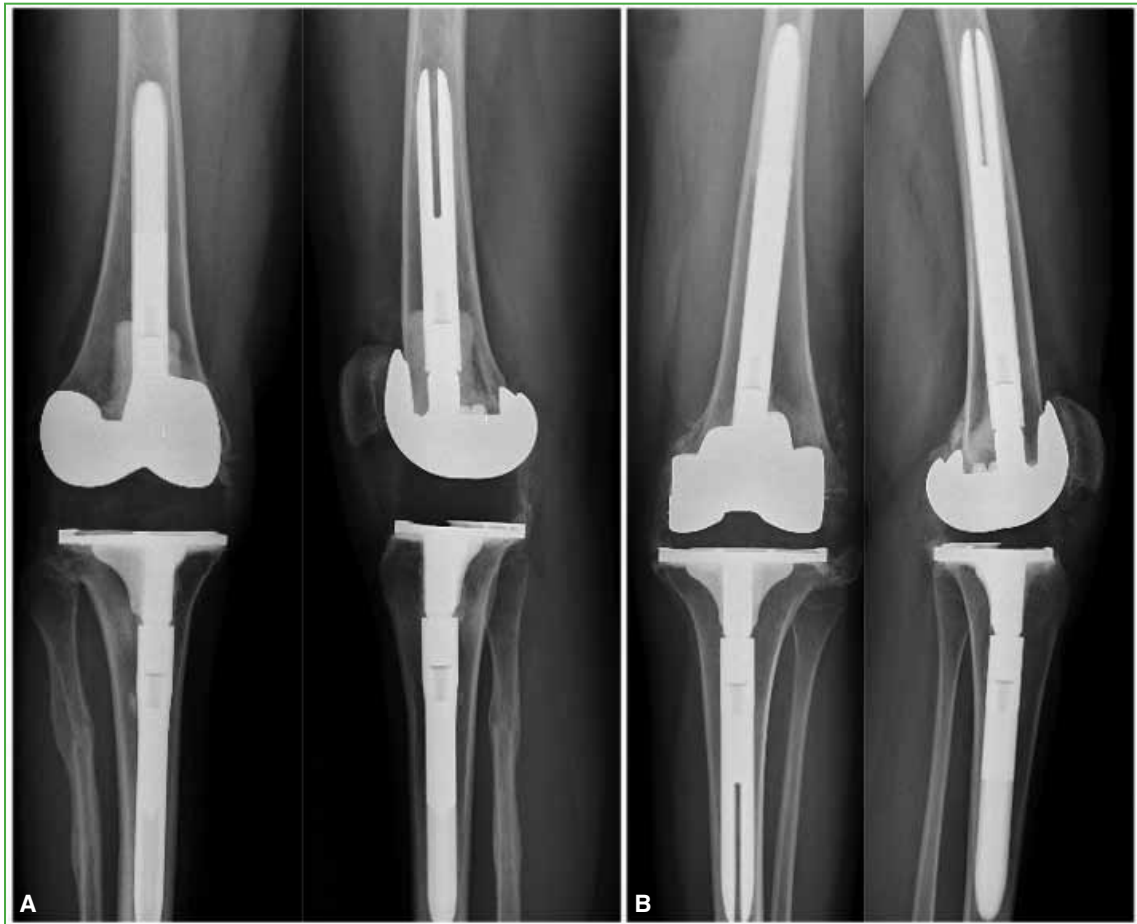A bilateral TKA was performed in a single surgical stage (Figure 5). A posterior stabilized prosthesis with tibial and femoral stems was used for both knees. He had no complications in the immediate or late postoperative period. Four years after surgery, the range of motion is 100° and the extension of both knees is complete. The KSS significantly improved to 87/90 on the right knee and 80/90 on the left. No signs of loosening of the prosthesis are observed on radiographs (Figure 6). The patient expresses satisfaction with the procedure.



**Figure 4.** A. Clinical image of both knees showing coronal deformity and ankylosis. B and C. Preoperative anteroposterior and lateral radiographs of the right and left knee.



**Figure 5.** Intraoperative images. A. Exhibition of the surgical field. B. Intramedullary femoral guide. C. Femoral cuts. D. Test femoral component. E. Side release of the patella.



**Figure 6.** Postoperative anteroposterior and lateral radiographs of the right (A) and left (B) knee.

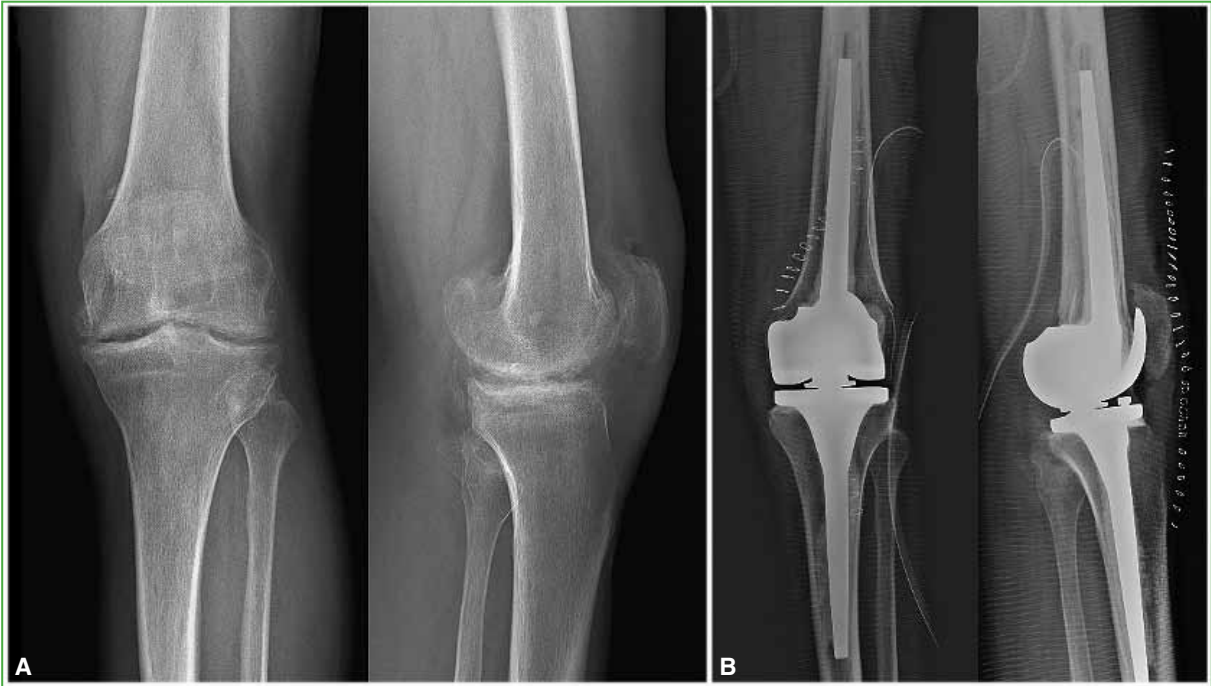### Case 3

A 58-year-old male with chronic osteomyelitis sequela on the left knee. He presented knee in extension, no mobility, and pain. On the radiograph, patellofemoral ankylosis was observed, without femorotibial bone junction, interpreted as fibrous ankylosis (Figure 7A). The preoperative KSS was 43/55. An infection could not be ruled out, so a two-stage TKA was chosen. A rotating hinge prosthesis was used for reimplantation due to the incompetence of the medial ligament complex. In the last follow-up at 18 months after surgery, he had no complications, and had a 100° flexion and full extension, with a KSS of 87/90 (Figure 7B).

### DISCUSSION

TKA in the context of ankylosis or knee stiffness represents a challenge for the surgeon, not only because of its high technical demand but also because of the high rate of postoperative complications. We presented a series of three patients, in which the causes leading to ankylosis were juvenile rheumatoid arthritis (2 cases) and an infectious sequela (1 case). These patients were treated satisfactorily and there were no complications.

It is important to make a distinction between the concepts of stiffness and ankylosis, often confused as a single entity, but with clear differences in surgical difficulty, complications, and functional outcomes.<sup>6,9</sup> In cases of stiffness, fewer contractures and soft tissue adhesions are found, and the range of motion they present allows better access, especially to the posterior region. Therefore, access to an appropriate surgical field and the achievement of gaps in flexion and extension are facilitated in comparison with cases of ankylosis.



**Figure 7.** Preoperative (A) and postoperative (B) anteroposterior and lateral radiographs of the left knee.

The [Table](#) summarizes the publications on the subject over the past 30 years. One of the most extensive series was that of Kim et al., published in 2008.<sup>20</sup> They evaluated a cohort of 99 knees with ankylosis for a minimum of six years, and obtained an average functional increase of the *Hospital for Special Surgery score* from 60 to 81, of the *Western Ontario and McMaster Universities Osteoarthritis Index* from 79 to 37 and of the KSS from 53 to 85. The postoperative range of motion increased between 55° and 105°, reaching an average of 79°. In the cases of Fosco et al. and Polascik et al., who compared outcomes in flexible and stiff knees, a greater postoperative range of motion was reported in patients with flexible knees, but the range of motion acquired in those with stiff knees increased to 70°. <sup>11,13</sup> This difference is maintained between patients with stiff and ankylosed knees. Bae et al. reported functional improvement in both groups without significant differences, while the improvement in the range of motion was more noticeable in the group with stiffness (98.7° in the stiffness group and 75.3° in patients with ankylosis ).<sup>6,9</sup> These findings support the previously stated idea that preoperative range of motion conditions postoperative range of motion. <sup>3,4,12</sup> Another aspect worth mentioning is that, in cases of ankylosis or stiffness in flexion, better outcomes in the postoperative range of motion are achieved than in cases in extension. <sup>6,12</sup> The increase in range of motion from 90° to 100° in our series coincides with that reported, which is 50-90°. <sup>2,3,7,9,12,14,20,21</sup>

Despite the good published outcomes, the surgical decision must be made together with the patient. It is vital to know the patient's expectations regarding the procedure to be performed and to be clear about the risks and benefits. <sup>1</sup> Even so, patients, for the most part, choose to have surgery. <sup>13</sup> To achieve successful surgery, correct pre-surgical planning must be performed, focusing on the condition of the soft tissues. The chosen approach should be the one that causes the least aggression to the soft tissues but provides comfortable exposure. If this is not achieved, mainly in the case of extension rigidity, it is necessary to expand the field to avoid intraoperative complications. <sup>3,12</sup> Kovalak et al. prefer osteotomy of the anterior tibial tuberosity, but we should not forget the risks of loss of fixation in osteoporotic patients, the difficulty in the use of tibial stem, and the risk of tendon rupture. <sup>14</sup> Aglietti et al. and Kim et al. performed V-Y quadricepsplasty in all cases to allow better flexion and obtain a greater surgical field, with good outcomes a year after aggressive rehabilitation. <sup>8,10</sup>

**Table.** Chronological review of the literature

Author (Year)	Number of knees	Follow-up (range)	Clinical score	Preoperative/Postoperative range of motion	Complications
Bradley et al. <sup>2</sup> (1987)	9 knees	3.6 years (2-6)		0°/64° (15°-90°)	33.3% (3 cases)
Aglietti et al. <sup>10</sup> (1989)	20 stiffness 6 ankylosis	4.5 years (2.5-7.5)	HSS preop. : 34 (20-46) HSS postop. : 74 (0-94) Not specified by group.	Stiffness 32°/82° Ankylosis 0°/68°	7.5% loosening and deep infection
Naranja et al. <sup>16</sup> (1996)	6 merger 31 ankylosis	7.5 years (0.2-12)		0°/7°-62°	53%
Kim et al. <sup>8</sup> (2000)	14 fusion 16 ankylosis	5.3 years (5-6)	Fusion KSS preop. : 60, KSS postop. : 73 Ankylosis KSS preop. : 60, KSS postop. : 73	Ankylosis 0°/75.7° (70°-95°) Fusion 0°/75.9° (70°-95°)	53.3% wound necrosis
McAuley et al. <sup>21</sup> (2002)	27 knees	6 years (2.3-11.8)		30° (0°-50°)/74° (15°-110°)	41%
Rajgopal et al. <sup>19</sup> (2005)	84 knees	9 years (4-15)	KSS preop. : 14.6/26.8 KSS postop. : 75/84	<20°/75° (55°-100°)	7.36%
Bae et al. <sup>9</sup> (2005)	12 stiffness 20 ankylosis	10 years (5-13)	Stiffness HSS preop. : 52.1 (29-66) HSS postop. : 86.7 (69-97) Ankylosis HSS preop. : 59.7 (26-87) HSS postop. : 84.9 (64-94)	Stiffness 49.5° (15°-80°)/98.7° (60-130°) Ankylosis 0°/75.3° (30°-115°)	12.5%
Bhan et al. <sup>6</sup> (2006)	64 stiffness 26 ankylosis	6.5 years (2-10)	Stiffness KSS preop. : 34.5 KSS postop. : 89.2 Ankylosed KSS preop. : 47 KSS postop. : 75	Stiffness 35°-69°/1°-94° Ankylosis 0°/3°-74°	33% general 50% wound necrosis in ankylosis group vs. 7% in the stiffness group
Kim and Kim <sup>20</sup> (2008)	99 knees	8.9 years (6.6-14)	HSS preop. : 60 HSS postop. : 81 WOMAC preop. : 79 WOMAC postop. : 37 KSS preop. : 53 KSS postop. : 85	0°/79° (55°-115°)	27% 17% wound necrosis
Camanho <sup>15</sup> (2009)	9 knees	5 years	HSS preop. : 55.9 HSS postop. : 81.8	<5°/65° (0°-90°)	2 cases
Kim and Kim <sup>7</sup> (2009)	86 knees	9.1 years (5-12)	KSS preop. : 11 KSS postop. : 90 WOMAC preop. : 79 (78-96) WOMAC postop. : 34.4 (5-68) HSS preop. : 42 HSS postop. : 84	40° (10°-50°)/102° (65°-145°)	14% 6% wound necrosis
Fosco et al. <sup>11</sup> (2011)	32 knees cases 28 knees controls	2 years	Cases KSS preop. : 31.3/34 KSS postop. : 85.2/70.8 Controls KSS preop. : 29.3/37.8 KSS postop. : 92.6/84	Cases 29°/87° 86°/106° controls	Cases 21.8% Controls 6.2%
Hsu et al. <sup>3</sup> (2012)	39 knees	4.8 years (2-10.25)	KSS preop. : 33/11 KSS postop. : 80/41 WOMAC preop. : 71 WOMAC postop. : 35	35° (0°-50°)/94° (0°-135°)	43.6% wound necrosis 7.7%
Kovalak et al. <sup>14</sup> (2015)	6 knees	7.1 years (1.8-10.5)	HSS preop. : 19.5 HSS postop. : 57.5 WOMAC preop. : 39.75 WOMAC postop. : 62.4	0-20°/85° (75°- 95°)	2 cases
Kim <sup>17</sup> (2017)	10 knees	10.2 years (1-19.5)	KSS preop. : 42.6/39 KSS postop. : 68.6/66	9.5° (0°-30°)/8.5° (15°-115°)	3 cases 1 wound necrosis
Rajgopal et al. <sup>12</sup> (2017)	51 knees extension 64 knees flexion	9.7 years (2-17.5)	Preop extension KSS: 23.2/14.4 Postop extension KSS: 74.1/66.4 Preop. flexion KSS: 14/8.3 Postop flexion KSS: 71.2/64.3	Extension 10.9° (0°-20°)/86.5° (30°-120°) Flexion 8.7° (<20°)/92.2° (45°-110°)	Extension 23.5% Flexion 18.75%
Polascik et al. <sup>13</sup> (2018)	28 stiff knees 56 flexible knees	4.3 years (2.5-6.3)	Preop cases KSS: 28/42 — OKQS: 39 Postop cases. KSS: 78/64 — OKQS: 22 Preop controls KSS: 35/49 — OKQS: 39 Postop controls KSS: 83/75 — OKQS: 19	Cases 8° (±7°)/80° (±33°) Controls 116° (±17°)/118° (±12°)	Cases 10% revisions Controls 0% revisions
Bittelmann et al. <sup>18</sup> (2019)	39 knees	4-16 years	HSS preop. : 30 HSS postop. : 77	<30°/80°	20.5%

Preop. = Preoperative, Postop. = Postoperative, HSS = Hospital for Special Surgery score, WOMAC = Western Ontario and McMaster Universities Osteoarthritis Index, OKQS = Oxford Knee Questionnaire Score.



Subsequently, in 2009, Kim et al. reserved quadricepsplasty for less than 50% of cases, and Bae et al. used it in 30% of their patients and obtained inferior outcomes than with osteotomy of the anterior tibial tuberosity.<sup>7,9</sup> Adding this surgical step can lead to an extension deficit of up to 20°, so we believe it should be used with caution.<sup>12</sup> Fosco et al. and Polascik et al. preferred to perform lateral release in all cases, adding osteotomy of the anterior tibial tuberosity or *rectus snip*, as appropriate.<sup>11,13</sup>

The rule governing the choice of prosthesis design is the slightest constriction that generates sufficient stability. In this way, we avoid unnecessary constriction that increases stress in the bone-cement interface, accelerating the loosening of the prosthesis.<sup>8</sup> We decided to use a rotating hinge design in the patient with infectious sequela, since successive debridement compromised ligament structures. In the other two cases, a posterior stabilization design with stem was chosen. This choice relies heavily on the preferences of the surgeon. Bae et al. used posterior cruciate ligament retention or posterior stabilization designs in all patients and had no cases requiring revision due to loosening after 10 years.<sup>9</sup> Kim et al. reported that they tested the posterior stabilization design during surgery: if it achieved coronal stability, they selected it; otherwise, they tested the condylar constriction design which, in the rest of the cases, was satisfactory. They did not report cases of revision due to loosening for a minimum period of five years.<sup>7</sup> Bhan et al. and Rajgopal et al. achieved a 100% prosthesis survival in all cases, over a period of 6 to 15 years, treated with posterior stabilization and condylar constriction designs.<sup>6,19</sup> In other cases, the failures were more evident. Polascik et al. reported the use of posterior stabilization designs on 28 stiff knees, with a revision rate of 10% at 5 years.<sup>13</sup>

Surgical and patient characteristics make this surgery very risky from the perspective of complications. In our cases, we have not had early nor late complications. But, as we have already mentioned, the way to prevent complications is with proper planning. Wound necrosis is the most common complication; it has a high incidence, up to 50%.<sup>6,8,20</sup> This is due to multiple causes; on the one hand, previous surgeries which may have altered skin irrigation and caused adhesions that limit skin elasticity. On the other hand, the combination of the increase in content, due to the size of the prosthesis, and the increase in range of motion, generate continuous stress through the patella leading to skin stress. Stretching the skin with a balloon expander before surgery is a way to prevent it through tissue compliance.<sup>22</sup> In addition, it can be avoided by patelloplasty or by restricting the postoperative range of motion, facing the risk of decreasing it permanently.<sup>6,8,20</sup> Another non-negligible complication is loosening, explained by the need for constrained implants in young patients with good functionality and the technical difficulty generated by the anatomical distortion they present, leading to incorrect placement of components that accelerate loosening.<sup>13</sup> In contrast, some studies report low revision rates, similar to those published on flexible knees, ranging from 0% to 4% in follow-up >9 years.<sup>3,12,20</sup> The revision rate for infection or fracture around the prosthesis is < 10% according to the publications.<sup>3,11,12</sup>

Despite being a report of three cases, we believe that TKA in patients with ankylosis is a valuable therapeutic option. This is mainly because they are mostly young adults and this procedure has a high impact on quality of life. To optimize surgical success, a trained team must be in charge and meticulous pre-surgical planning is necessary. Still and all, the patient should be aware of the greater risk of complications from this intervention, but we still obtained a high satisfaction rate.

---

Conflict of interests: The authors declare they do not have any conflict of interests.

I. García-Mansilla ORCID ID: <https://orcid.org/0000-0002-7247-3734>

T. Nicolino ORCID ID: <https://orcid.org/0000-0002-9550-3713>

C. Yacuzzi ORCID ID: <https://orcid.org/0000-0002-7732-7883>

L. Carbó ORCID ID: <https://orcid.org/0000-0002-8053-0890>

J. Costantini ORCID ID: <https://orcid.org/0000-0001-8900-6254>

M. Costa Paz ORCID ID: <https://orcid.org/0000-0002-8217-1086>

## REFERENCES

1. Lange T, Schmitt J, Kopkow C, Rataj E, Günther K-P, Lützner J. What do patients expect from total knee arthroplasty? A Delphi Consensus Study on Patient Treatment Goals. *J Arthroplasty* 2017; 32:2093-9.e1. <https://doi.org/10.1016/j.arth.2017.01.053>
2. Bradley GW, Freeman MA, Albrektsson BE. Total prosthetic replacement of ankylosed knees. *J Arthroplasty* 1987;2(3):179-83. [https://doi.org/10.1016/s0883-5403\(87\)80035-9](https://doi.org/10.1016/s0883-5403(87)80035-9)
3. Hsu CH, Lin PC, Chen WS, Wang JW. Total knee arthroplasty in patients with stiff knees. *J Arthroplasty* 2012;27(2):286-92. <https://doi.org/10.1016/j.arth.2011.05.001>
4. Gatha NM, Clarke HD, Fuchs R, Scuderi GR, Insall JN. Factors affecting postoperative range of motion after total knee arthroplasty. *J Knee Surg* 2004;17(4):196-202. <https://doi.org/10.1055/s-0030-1248221>
5. Harvey IA, Barry K, Kirby SP, Johnson R, Elloy MA. Factors affecting the range of movement of total knee arthroplasty. *J Bone Joint Surg Br* 1993;75(6):950-5. <https://doi.org/10.1302/0301-620x.75b6.8245090>
6. Bhan S, Malhotra R, Kiran EK. Comparison of total knee arthroplasty in stiff and ankylosed knees. *Clin Orthop Relat Res* 2006;451:87-95. <https://doi.org/10.1097/01.blo.0000229313.20760.13>
7. Kim Y-H, Kim J-S. Does TKA improve functional outcome and range of motion in patients with stiff knees? *Clin Orthop Relat Res* 2009;467(5):1348-54. <https://doi.org/10.1007/s11999-008-0445-7>
8. Kim YH, Kim JS, Cho SH. Total knee arthroplasty after spontaneous osseous ankylosis and takedown of formal knee fusion. *J Arthroplasty* 2000;15(4):453-60. <https://doi.org/10.1054/arth.2000.4640>
9. Bae DK, Yoon KH, Kim HS, Song SJ. Total knee arthroplasty in stiff knees after previous infection. *J Bone Joint Surg Br* 2005;87(3):333-6. <https://doi.org/10.1302/0301-620x.87b3.15457>
10. Aglietti P, Windsor RE, Buzzi R, Insall JN. Arthroplasty for the stiff or ankylosed knee. *J Arthroplasty* 1989;4(1):1-5. [https://doi.org/10.1016/s0883-5403\(89\)80046-4](https://doi.org/10.1016/s0883-5403(89)80046-4)
11. Fosco M, Filanti M, Amendola L, Savarino LM, Tigani D. Total knee arthroplasty in stiff knee compared with flexible knees. *Musculoskelet Surg* 2011;95(1):7-12. <https://doi.org/10.1007/s12306-011-0099-6>
12. Rajgopal A, Panda I, Dahiya V. A Comparative study on the long-term outcome of total knee arthroplasty performed for knees stiff in extension and those stiff in flexion. *J Arthroplasty* 2017;32(11):3396-403. <https://doi.org/10.1016/j.arth.2017.06.027>
13. Polascik BW, Bin Abd Razak HR, Chong H-C, Lo N-N, Yeo S-J. Acceptable functional outcomes and patient satisfaction following total knee arthroplasty in asians with severe knee stiffness: A matched analysis. *Clin Orthop Surg* 2018;10(3):337-43. <https://doi.org/10.4055/cios.2018.10.3.337>
14. Kovalak E, Can A, Stegemann N, Erdoğan AO, Erdoğan F. Total knee arthroplasty after osseous ankylosis of the knee joint. *Acta Orthop Traumatol Turc* 2015;49(5):503-7. <https://doi.org/10.3944/AOTT.2015.14.0304>
15. Camanho GL. Total arthroplasty in ankylosed knees: a case series. *Clinics* 2009;64(3):183-7. <https://doi.org/10.1590/s1807-59322009000300006>
16. Naranja RJ Jr, Lotke PA, Pagnano MW, Hanssen AD. Total knee arthroplasty in a previously ankylosed or arthrodesed knee. *Clin Orthop Relat Res* 1996;(331):234-7. <https://doi.org/10.1097/00003086-199610000-00033>
17. Kim H-J, Mun J-U, Kim K-H, Kyung H-S. Total knee arthroplasty conversion for patients with ankylosed knees. *J Orthop Surg* 2017;25(1):2309499016684095. <https://doi.org/10.1177/2309499016684095>
18. Bittelman S, Nemtala F, Salvo N, Araya R, Devia B, Voss C, et al. Prótesis de rodilla en pacientes con anquilosis. *Revista Acaro* 2019;5(2):31-4. Disponible en: [http://acaro.org.ar/acarorevista/images/revistas/05\\_02/AC\\_05\\_02\\_v6.pdf](http://acaro.org.ar/acarorevista/images/revistas/05_02/AC_05_02_v6.pdf)
19. Rajgopal A, Ahuja N, Dolai B. Total knee arthroplasty in stiff and ankylosed knees. *J Arthroplasty* 2005;20(5):585-90. <https://doi.org/10.1016/j.arth.2005.04.002>
20. Kim Y-H, Kim J-S. Total knee replacement for patients with ankylosed knees. *J Bone Joint Surg Br* 2008;90(10):1311-6. <https://doi.org/10.1302/0301-620X.90B10.20857>
21. McAuley JP, Harrer MF, Ammeen D, Engh GA. Outcome of knee arthroplasty in patients with poor preoperative range of motion. *Clin Orthop Relat Res* 2002;404:203-7. <https://doi.org/10.1097/00003086-200211000-00033>
22. Cho SH, Jeong ST, Park HB, Hwang SC, Kim DH. Two-stage conversion of fused knee to total knee arthroplasty. *J Arthroplasty* 2008;23(3):476-9. <https://doi.org/10.1016/j.arth.2007.06.013>