

# Results of the Knotless Arthroscopic Foveal Anchorage of the Triangular Fibrocartilage Complex in Atzei 2/3 Lesions

Matías Sala,\* Sergio Daroda\*\*

\*Hand and Upper Limb Surgery Division, Hospital Regional de Comodoro Rivadavia, Comodoro Rivadavia, Chubut, Argentina

\*\*Clínica de la Mano Gamma, La Plata, Buenos Aires, Argentina

## ABSTRACT

**Objective:** To retrospectively evaluate the functional and objective outcomes in patients with foveal lesions of the triangular fibrocartilage complex treated with arthroscopic knotless bone anchors. **Materials and Methods:** We retrospectively evaluated 12 patients with Atzei 2/3 foveal lesions of the triangular fibrocartilage complex with an average follow-up of 18 months. All the lesions were repaired arthroscopically using a fibrocartilage guide and knotless bone anchors. The ranges of motion and grip strength were assessed with the Mayo Clinic wrist scale and the DASH questionnaire. **Results:** Improvements were obtained in the pain and strength test; the average range of motion was 70° in extension, 85° in flexion, 20° in radial deviation, and 30° in ulnar deviation. The outcomes according to the Mayo Clinic wrist scale were excellent in 83% of the cases and good in 17%; there were no poor outcomes. The average DASH score was 56 preoperatively and 8 postoperatively. The average contralateral comparative strength was 70%. **Conclusion:** The arthroscopic repair of Atzei 2/3 lesions with knotless bone anchors achieves good outcomes, improves ranges of motion, and restores stability and total or partial strength in all cases.

**Keywords:** Wrist arthroscopy; Atzei 2; Atzei 3; triangular fibrocartilage complex; knotless bone anchorage.

**Level of Evidence:** IV

## Resultados del anclaje foveal artroscópico sin nudo del complejo del fibrocartílago triangular en lesiones Atzei 2/3

## RESUMEN

**Objetivo:** Evaluar, en forma retrospectiva, la función y los resultados objetivos de los pacientes con lesión foveal del complejo del fibrocartílago triangular mediante anclaje óseo sin nudo artroscópico. **Materiales y Métodos:** Se evaluó, en forma retrospectiva, a 12 pacientes con lesión foveal del complejo del fibrocartílago triangular Atzei 2/3 y un seguimiento promedio de 18 meses. Todas las lesiones se repararon con artroscopia mediante la guía de fibrocartílago y anclaje óseo sin nudo. Se evaluaron los rangos de movilidad y la fuerza de agarre con la escala de muñeca de la Clínica Mayo y el cuestionario de DASH. **Resultados:** Se obtuvieron mejoras en la prueba del dolor y la fuerza; el rango de movilidad promedio fue de 70° de extensión, 85° de flexión, 20° de desviación radial y 30° de desviación cubital. Los resultados según la escala de muñeca de la Clínica Mayo fueron excelentes en el 83% y buenos en el 17%, no hubo resultados malos. El puntaje promedio del cuestionario DASH fue 56 en el preoperatorio y 8 en el posoperatorio. El promedio de la fuerza comparativa contralateral fue del 70%. **Conclusiones:** La reparación artroscópica de las lesiones Atzei 2/3 mediante anclaje óseo sin nudo logra buenos resultados, mejora los rangos de movilidad, recupera la estabilidad en todos los casos y la fuerza total o parcial.

**Palabras clave:** Artroscopia de muñeca; Atzei 2; Atzei 3; complejo de fibrocartílago triangular; anclaje óseo sin nudo.

**Nivel de Evidencia:** IV

Received on May 13<sup>th</sup>, 2021. Accepted after evaluation on July 11<sup>th</sup>, 2021 • Dr. MATÍAS SALA • salajuanmatias@icloud.com

 <https://orcid.org/0000-0001-5542-5004>

**How to cite this article:** Sala M, Daroda S. Results of the Knotless Arthroscopic Foveal Anchorage of the Triangular Fibrocartilage Complex in Atzei 2/3 Lesions. *Rev Asoc Argent Ortop Traumatol* 2021;86(5):581-594. <https://doi.org/10.15417/issn.1852-7434.2021.86.5.1374>

## INTRODUCTION

The triangular fibrocartilage complex (TFCC) is the main stabilizer of the distal radioulnar joint (DRUJ) and consists of the articular disc, the proximal and distal dorsal and palmar ligaments, the ulnocarpal ligaments, and the *subcreatum ligamentus*. The stability of the DRUJ depends on the TFCC, the joint capsule, the posterior ulna, the pronator quadratus, and the distal oblique bundle. The TFCC is a fibrocartilaginous disc with a rich vascularization in its ulnar zone, precarious on the radial side and null in the center of the disc.<sup>1,2</sup> This complex is surrounded by fibrous structures that make up a key of rotation, loading, and translation of forces from the wrist to the forearm.<sup>1</sup>

TFCC injury is one of the most common causes of ulnar wrist pain, which limits activities of daily living. It is common in athletes with a high level of competition, due to trauma or repetitive use of the joint.<sup>1,3</sup> That is why, in recent years, there has been great interest in its repair with resistant fixation techniques using bone tunnels and capsular anchors with hook and knotless techniques.<sup>3</sup>

Knotless anchors are a valid option for fixing ligament structures in bones, with similar outcomes to knotted anchors. An advantage of knotless anchors is the faster fixation technique which is just as strong as knotted anchors.<sup>4,5</sup>

Palmer distinguished two types of TFCC injuries, traumatic (acute) and degenerative (chronic) (Table 1).<sup>6</sup> Acute injuries occur from trauma to the wrist with hyperextension and ulnar deviation, direct trauma, or activities that require weight bearing.<sup>1,3</sup> Degenerative injuries are caused by repetitive activities with axial load and ulnar deviation of the wrist, as well as by poor consolidation of distal radius fractures.<sup>7-9</sup>

**Table 1.** Palmer's classification for triangular fibrocartilage complex injuries

<b>Type 1</b>	A. Central perforation B. Ulnar-sided injury C. Ulnocarpal ligament injury D. Radial-sided injury
<b>Type 2</b>	A. Central TFCC wear B. Central TFCC wear plus SL or ulnar head chondromalacia, or both. C. Perforation of the TFCC and SL or ulnar head chondromalacia, or both. D. 2C plus lunotriquetral ligament injury E. 2D plus ulnocarpal osteoarthritis

TFCC = triangular fibrocartilage complex, SL = semilunate.

On the other hand, with their arthroscopic classification, Atzei et al. modified the concept of “hammock” of the TFCC by that of “iceberg”, where the visible part comprises the superficial fibers that tolerate and absorb the impact, and the non-visible part are the deep fibers, responsible for the stability of this complex (Table 2).<sup>1,3</sup>

Wrist arthroscopy is the method of choice for the diagnosis and treatment of TFCC injuries. The two most commonly used arthroscopic tests are the hook test for foveal injuries and the trampoline test for superficial injuries. The phantom test is another useful tool that is performed from the dorsal distal radioulnar portal.<sup>2,8</sup>

The technique of choice to treat lesions with TFCC instability consists of the reinsertion of the foveal fibers of this complex.<sup>1,2,7,8</sup>

Although open surgery achieves good long-term outcomes, arthroscopic techniques have the following advantages: the injury can be fully evaluated and the associated injuries can be treated, and there is less postoperative stiffness and capsular damage.<sup>1,3</sup>

The objective of this study is to communicate the functional outcomes of patients with Atzei type 2/3 TFCC injuries operated through arthroscopic knotless anchoring, considering that it is a reliable, resistant, fast, and simple technique.

**Table 2.** Atzei classification of ulnar injuries of the triangular fibrocartilage complex based on its stability, ligament structures, repair potential, and suggested treatment

Type	DRU Instability	Appearance of the distal TFCC	Appearance of the proximal TFCC	TFCC repair potential	Appearance of the DRU cartilage	Suggested treatment
1	Mild /No	Broken	Intact	Good	Good	Capsule repair
2	Moderate /Severe	Broken	Broken	Good	Good	Foveal repair
3	Moderate/Severe	Intact	Broken	Good	Good	Foveal repair
4	Severe	Broken	Broken	Poor	Good	Graft reconstruction
5	Moderate/Severe	Variable	Variable	Variable	Poor	Arthroplasty or salvage

DRU = distal radioulnar, TFCC = triangular fibrocartilage complex.

## MATERIALS AND METHODS

We conducted a retrospective study to analyze surgical outcomes in 12 consecutive adult patients with deep Atzei type 2/3 TFCC injuries, operated between January 1, 2018, and December 31, 2019.

The inclusion criteria were: patients >18 years of age; athletes; no history of TFCC surgery or wrist arthroscopy; ulnar-sided wrist pain compatible with TFCC injury that limited work, sport or daily activities; positive Berger, Ruby, and Nakamura tests; Atzei 2/3 injuries confirmed by magnetic resonance imaging and arthroscopy; and a minimum postoperative follow-up of 12 months. The exclusion criteria were: previous TFCC surgery, previous arthroscopy of the wrist, degenerative lesions, and DRUJ osteoarthritis. We studied 12 patients (9 men and 3 women, 10 right-handed and 2 left-handed) with unstable foveal lesions of TFCC.

Associated carpus ligament injuries were evaluated with the Geissler classification (Table 3).<sup>10</sup>

**Table 3.** Geissler classification

Types	
1	Attenuation or hemorrhage as seen from radiocarpal space. No incongruity of carpal alignment. Allows the passage of the 1 mm probe through the midcarpal.
2	Breakage with slight incongruity. Allows the passage of the probe through the midcarpal without rotation
3	Breakage with incongruity. Allows the passage of the probe through the midcarpal with rotation.
4	Breakage with incongruity. Allows the passage of the probe between bones from the midcarpal to the radiocarpal.

In all patients, the ranges of motion of the wrist in flexion, extension, and in ulnar and radial deviations were objectively evaluated with a standard PVS hand goniometer, whereas grip strength was evaluated with a standard hydraulic dynamometer (Baseline-Orthowell®).

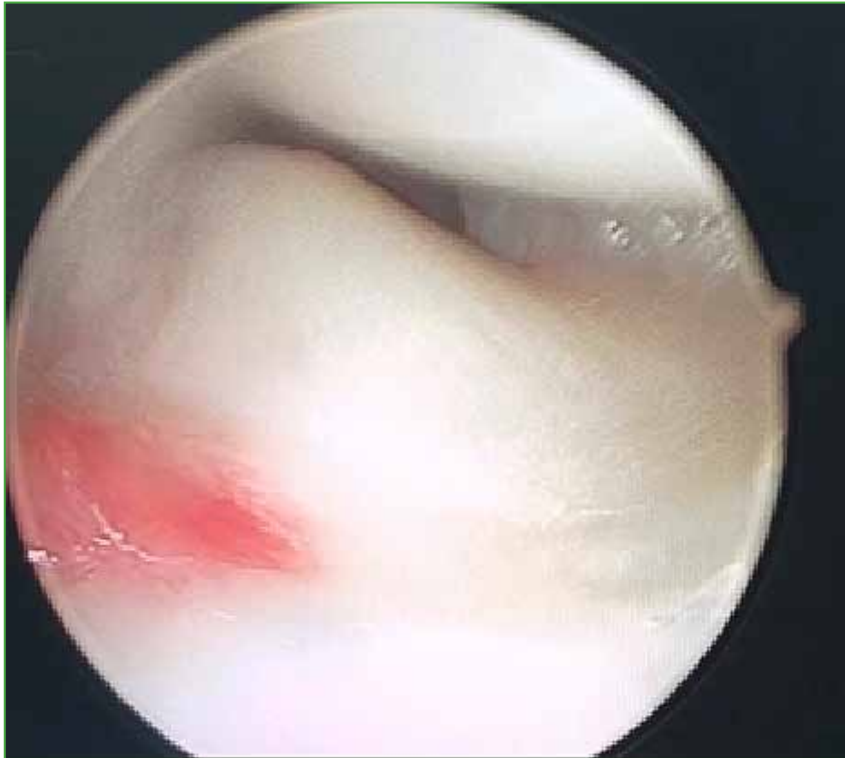Subjective assessment was performed using the visual analog scale for pain, the Mayo Clinic wrist scale, and the DASH questionnaire.<sup>11,12</sup>

The treatment protocol was as follows: upon the first consultation for ulnar pain of the wrist, the anamnesis on the mechanism of trauma was obtained and then the clinical examination was performed. We used the Waiter, Ruby, Berger, Nakamura, and axial compression tests in three positions.<sup>13</sup> We then requested anteroposterior weight-bearing radiographs and an MRI without contrast to confirm the diagnosis and immobilized the patient with a sugar-tong splint for three weeks. After removing the immobilization, the patient began with physiotherapy and we repeated the tests, if they were positive, we indicated diagnostic and therapeutic wrist arthroscopy. These times are based on the study of Atzei, who indicates the repair before three months after the injury to obtain good outcomes.

## Surgical technique

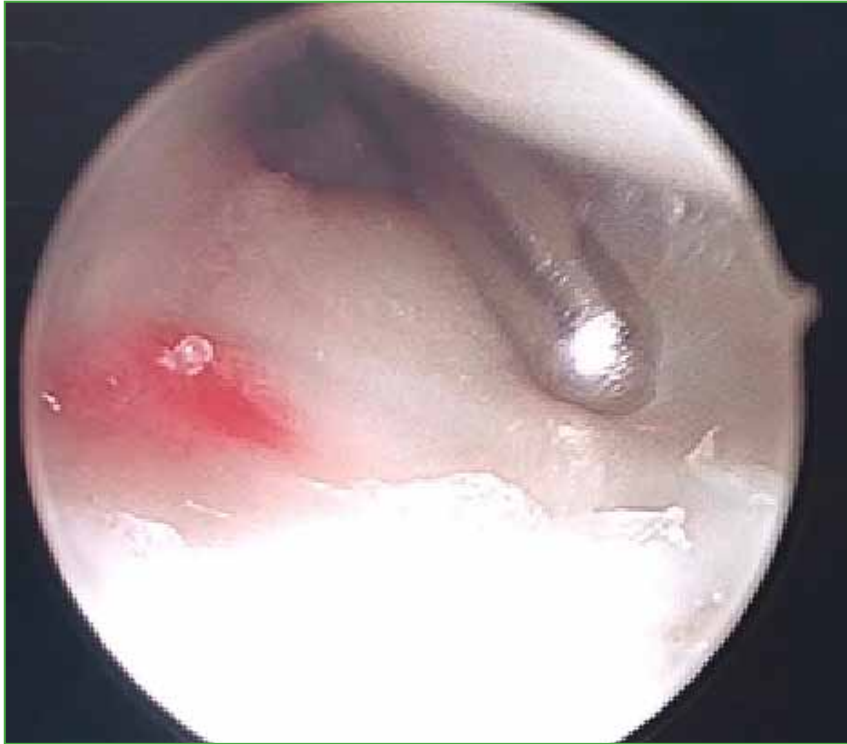Brachial plexus block anesthesia is administered and a cuff is placed at 250 mmHg to prevent ischemia. 3/4, 6R, 6U, MCU and MCR portals are used.

The radiocarpal and midcarpal joints are scanned for associated injuries. Then the hook, ghost, and trampoline tests are performed on the TFCC and the injury is classified ([Figure 1](#)).

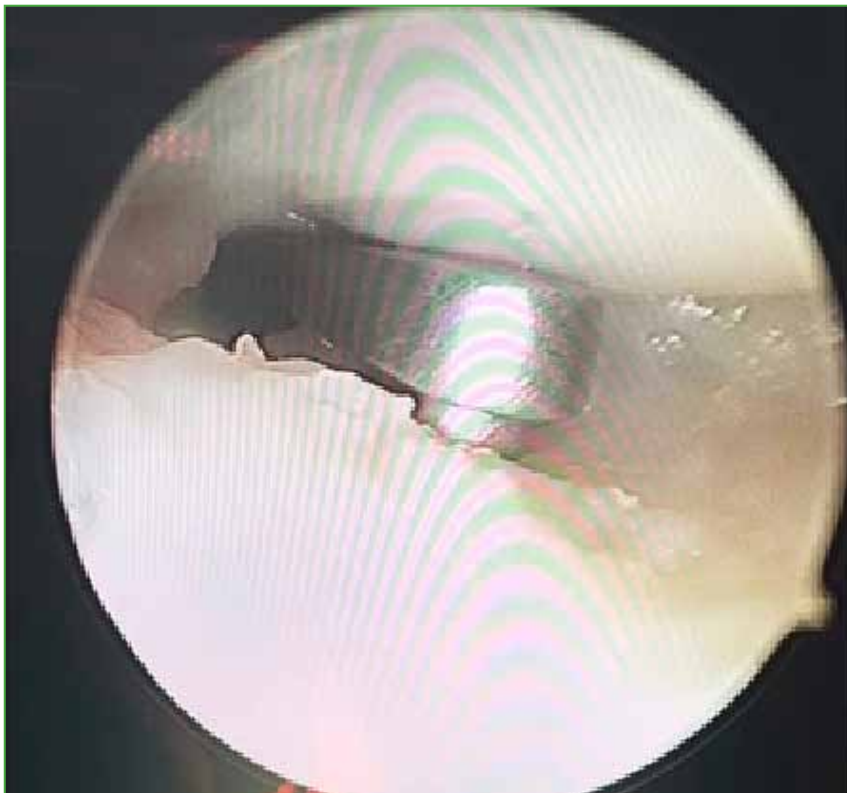


**Figure 1.** Positive phantom test, compatible with foveal injury.

Synovectomy and debridement are performed on the injury. ([Figure 2](#)). Next, the TFCC guide is placed through the 6R portal and, under  $\frac{3}{4}$  vision, the guide is placed in the  $\frac{2}{2}$  zone described by Matsumoto ([Figure 3](#)). A 2 cm ulnar approach is used to place the guide at the same time that it is positioned through the 6R portal; a pin is passed through the guide until it exits through the joint, ensuring that it is in zone  $\frac{2}{2}$ . It is reamed with a 3.0 guide from the ulna to the joint. Then, the guide is removed and a fiberwire 2.0 suture passer is passed through the ulnar orifice, penetrating the disc; this thread is removed through the 6R portal without losing it in the ulnar tunnel ([Figures 4-6](#)). Next, a suture passer with a suture retriever is placed through the ulnar tunnel, penetrating the disc 2 mm to the volar or dorsal side. Then, the suture retriever is removed through the 6R portal ([Figures 7-9](#)). The thread is passed through the suture retriever and pulled from it through the ulnar approach, always from the  $\frac{3}{4}$  portal. It is observed how the suture passes into the ulnar orifice, tensing the fibrocartilage ([Figures 10-12](#)). With a 2.8 mm knotless anchoring device, the two ends of the threads are placed inside the fixation system and it is impacted 5 mm distal to the previously made tunnel ([Figures 13 and 14](#)). The trampoline and hook tests are verified to be negative, traction is removed and stability is tested. The portals are closed. A Munster splint (sugar-tong) is placed for four weeks allowing the mobility of fingers and shoulder; then, the rehabilitation program begins. During the first two weeks, it is performed with a permanent-use short wrist splint. The splint is only removed in rehabilitation and inside the house for controlled mobility of the wrist. After six weeks, a rigid wrist splint is worn only at night and the energetic mobility of the wrist without weight-bearing is indicated. At eight weeks, the progressive strengthening begins and the wrist splint is permanently removed.

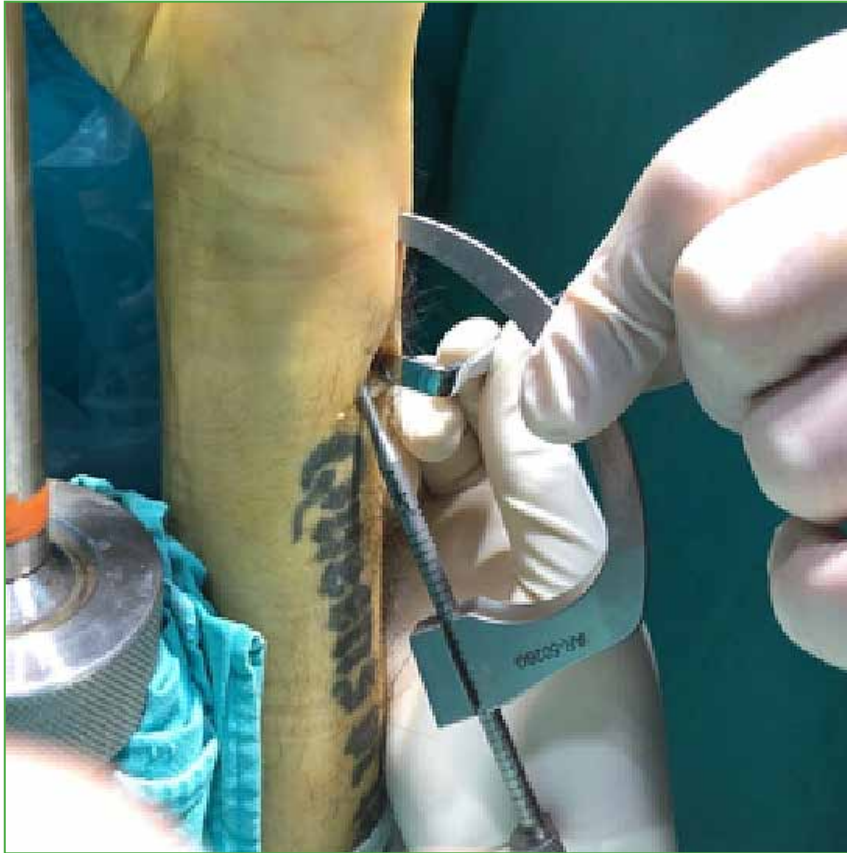

**Figure 2.** Debridement of the triangular fibrocartilage complex.

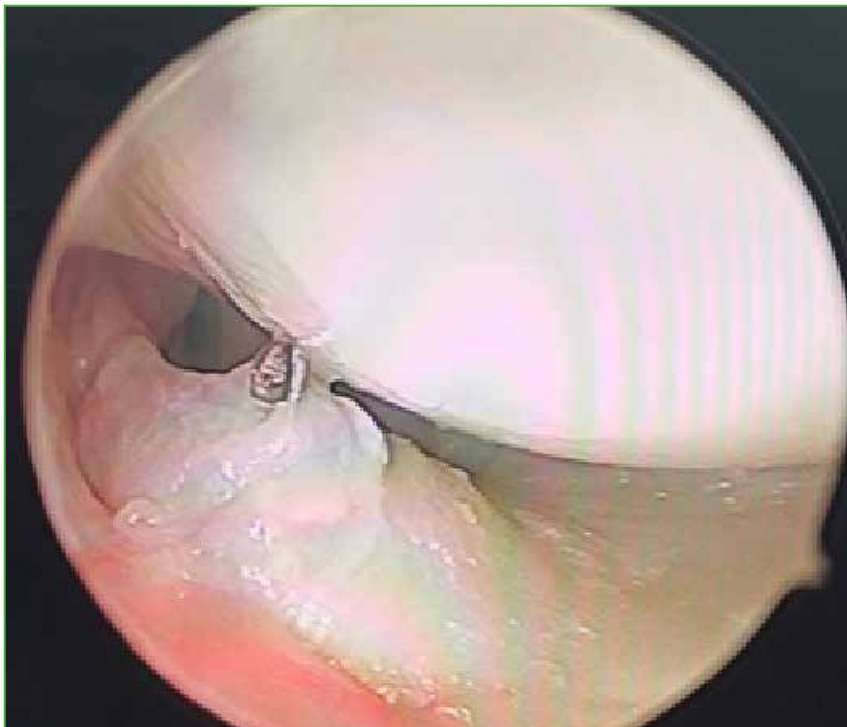


**Figure 3.** Guide of the triangular fibrocartilage complex in the 2/2 position.

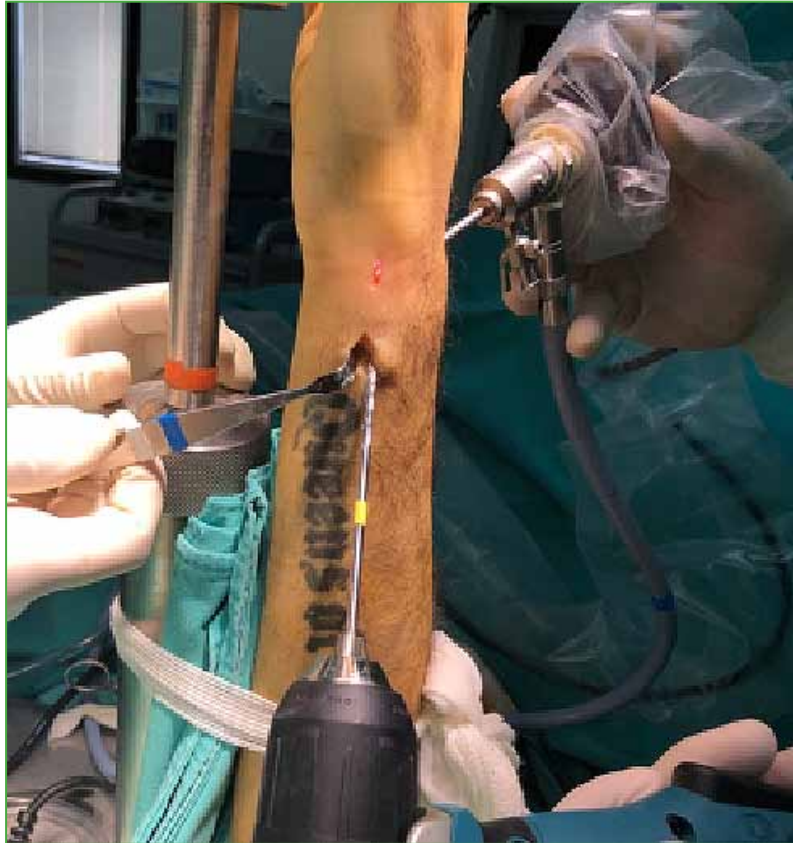



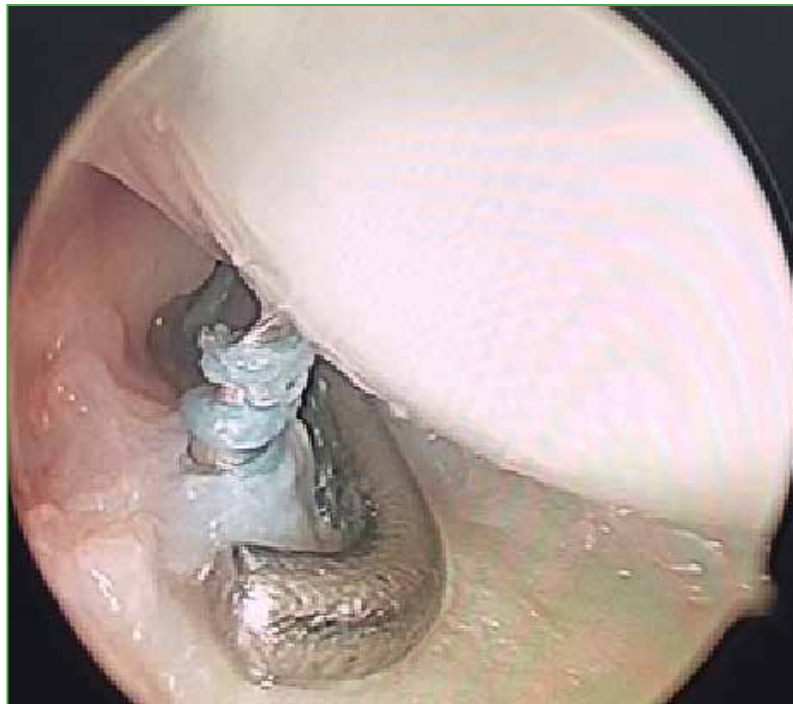**Figure 4.** Placement of the guide through the 6R portal and ulnar incision.



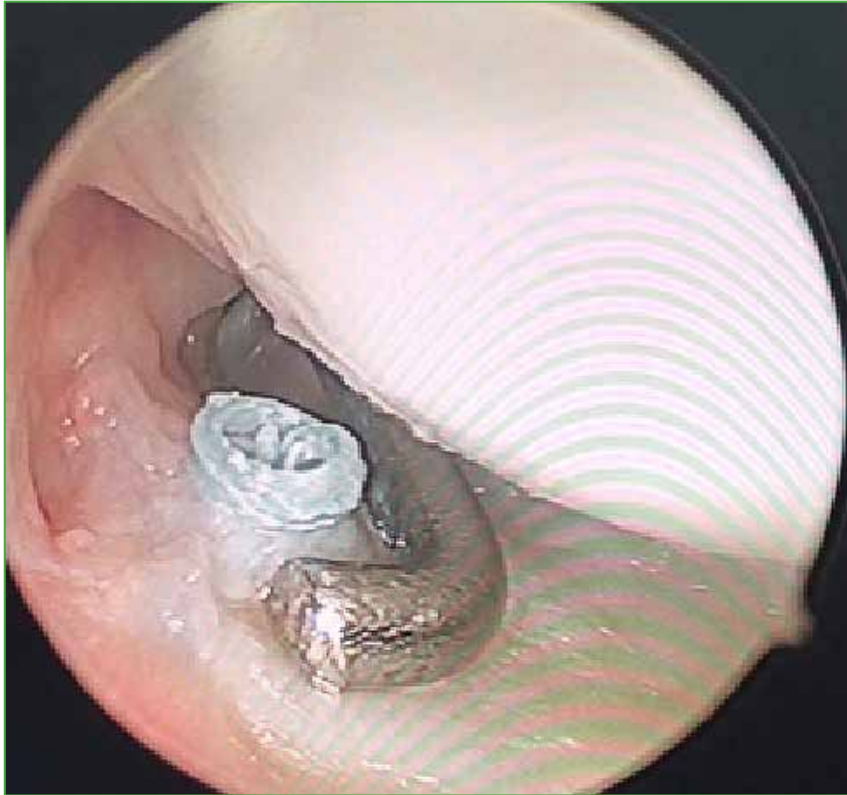
**Figure 5.** Pin exiting through the triangular fibrocartilage complex from the ulnar tunnel.



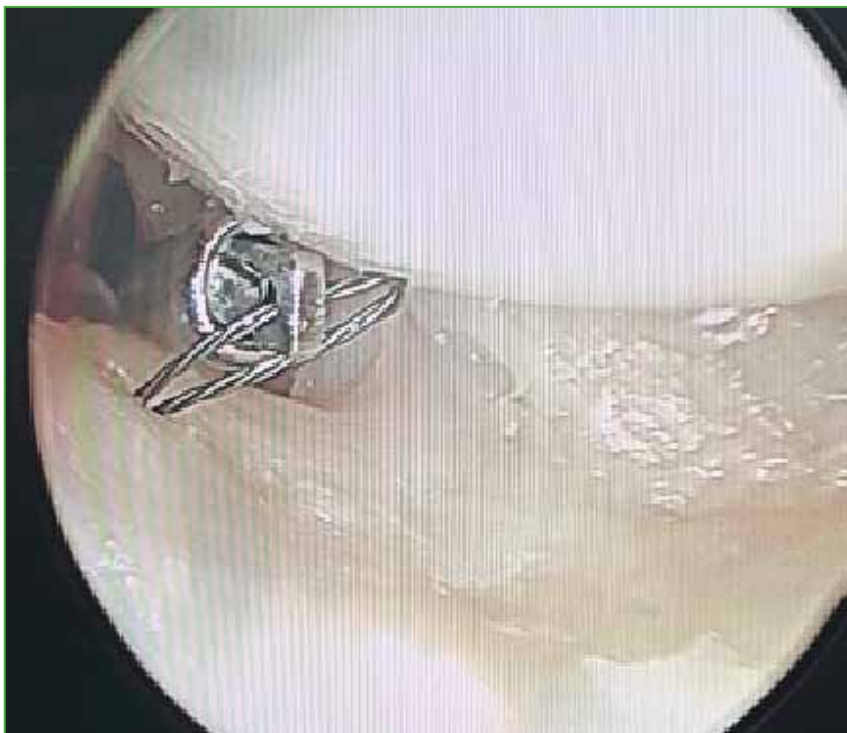
**Figure 6.** Reaming of the ulna to create the ulnar tunnel.



**Figure 7.** Passage of the suture passer with the suture penetrating the triangular fibrocartilage complex.

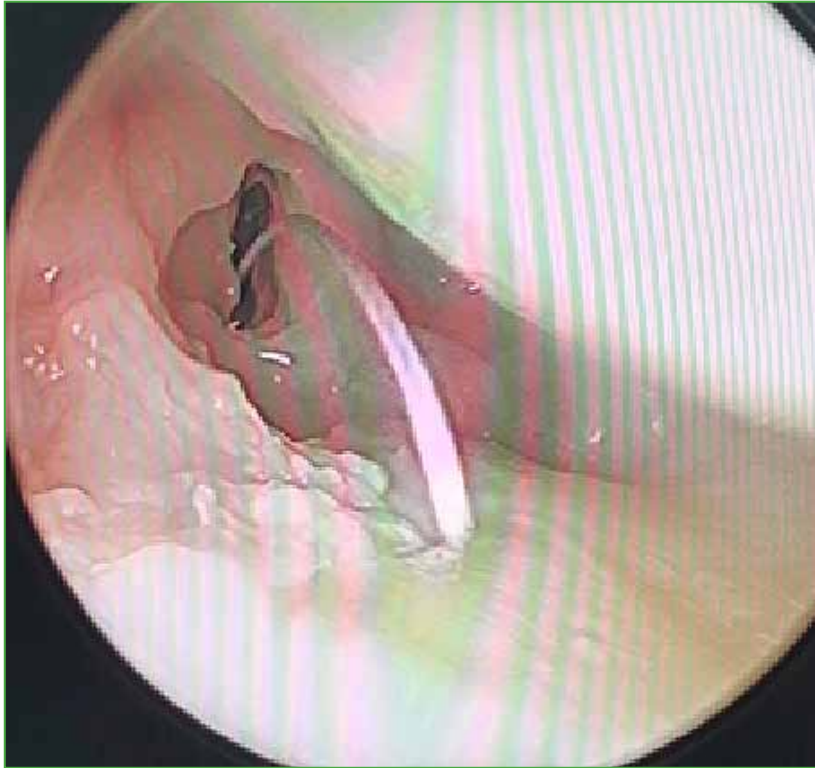

**Figure 8.** Loop of the thread passing through the triangular fibrocartilage complex.

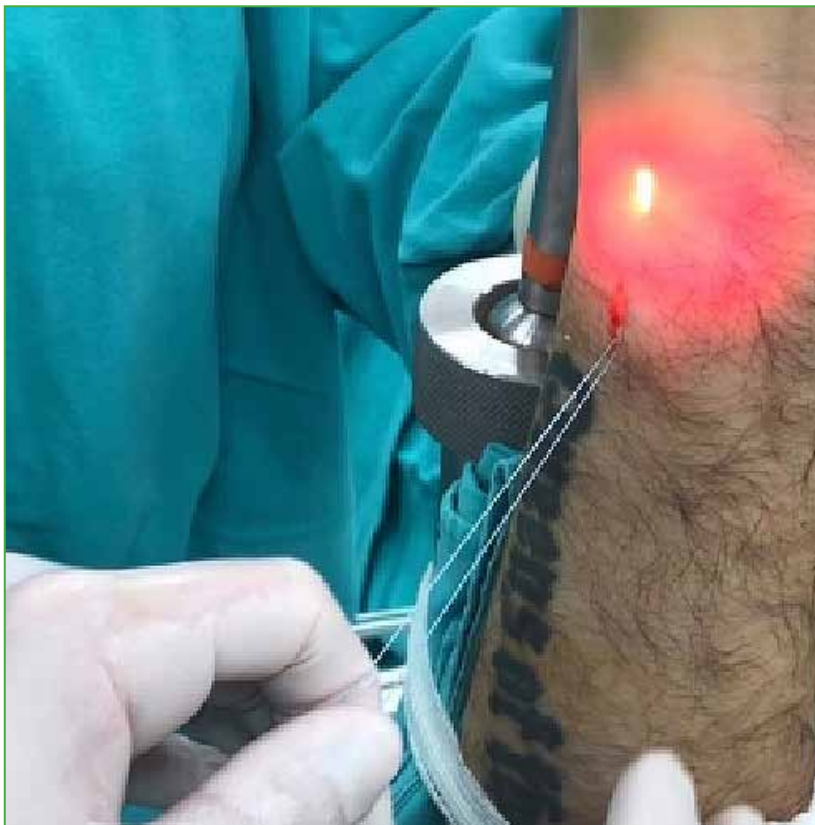

**Figure 9.** Suture passer penetrating the triangular fibrocartilage complex with the suture retriever.

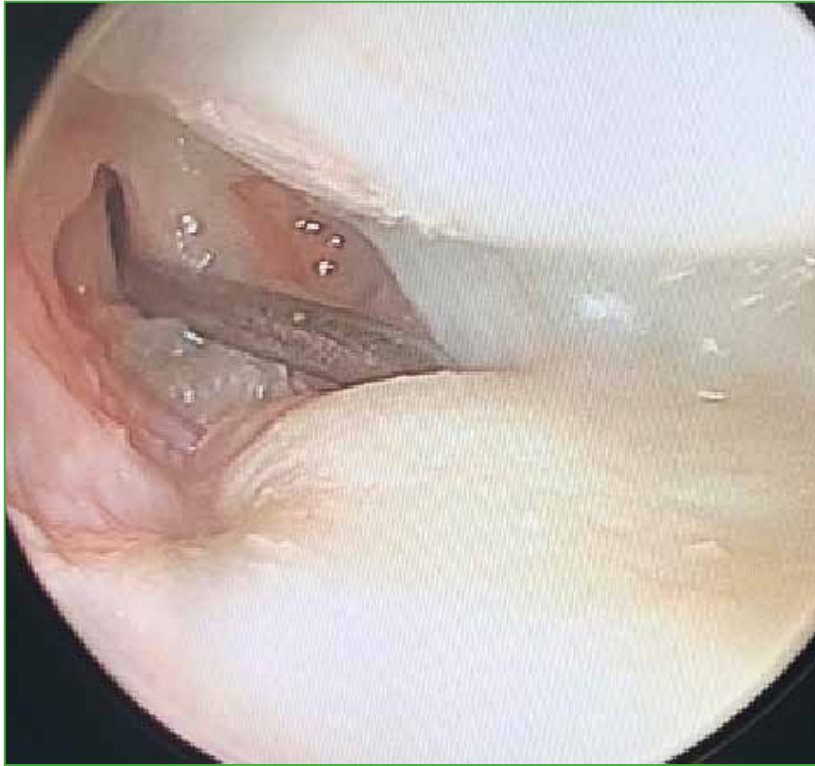



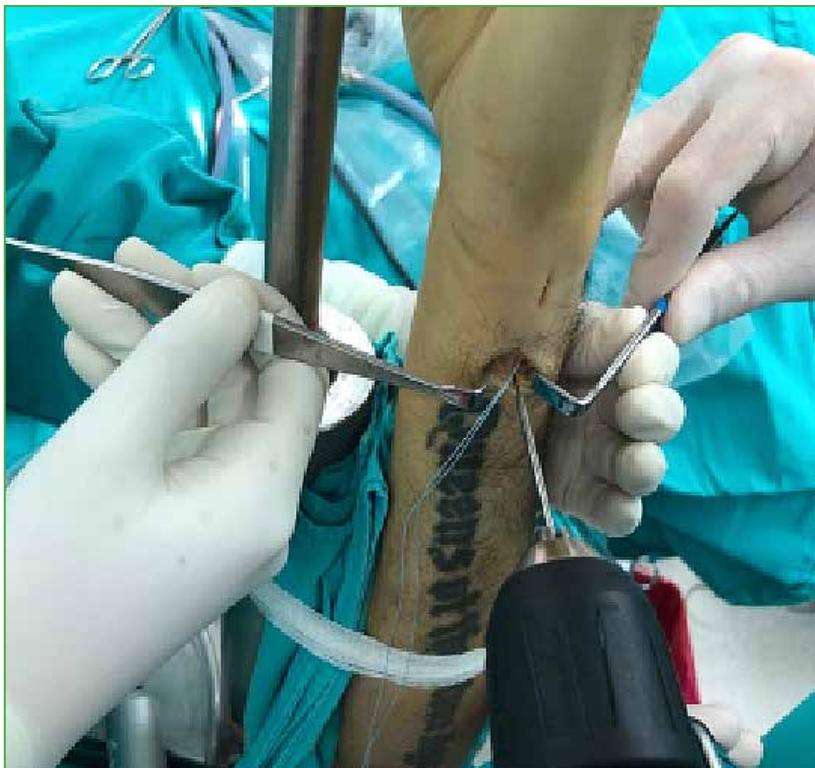**Figure 10.** End of the passage of the suture from the 6R portal to the ulnar tunnel.



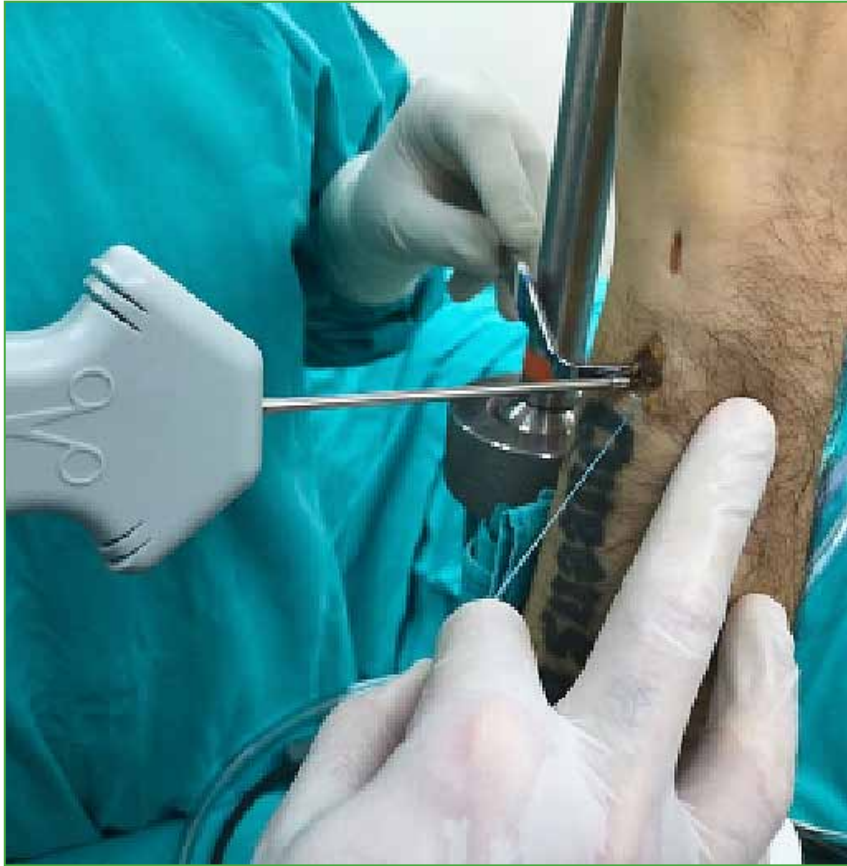**Figure 11.** The two sutures were retrieved through the ulnar tunnel.



**Figure 12.** Foveal tests become negative by tightening the threads.



**Figure 13.** Distal reaming of the ulnar tunnel for the placement of the knotless anchor.



**Figure 14.** Placement of the knotless anchor, maintaining suture tension.

## RESULTS

The follow-up period for the retrospectively evaluated patients ranged from 12 to 26 months, with an average of 18 months. The time between injury and surgery was less than three months (acute stage) in 58.3% and more than three months (chronic stage) in 41.7%. The arcs of motion of the wrist were measured with a standard PVS handheld goniometer. The values obtained were: 85° of flexion, 70° of extension, 20° of radial deviation, and 30° of ulnar deviation. Grip strength was evaluated with a standard hydraulic dynamometer and a 70% strength was obtained compared to the contralateral hand.

The average DASH questionnaire score was 56 (range 41-90) preoperatively and 8 (range 2-16) postoperatively. The Mayo Clinic wrist scale values were excellent at 83% and good at 17%, there were no poor outcomes. The visual analog scale yielded 8 points (range 6-10) before surgery and 2 points (range 1-3) at the end of follow-up. All patients regained joint stability in comparison to the healthy wrist as assessed by the Nakamura test.

All operated athlete patients resumed their sports activity without difficulties in the sixth month after surgery.

As for associated arthroscopic injuries, 30% were scapholunate injuries (6 Geissler 1, 2 Geissler 2, and 2 Geissler 4) and 20% were lunotriquetral injuries (3 Geissler 2 and 2 Geissler 1). All associated injuries were repaired in the same surgical stage.

There were no infections in the population studied. 16% of the patients had paresthesia in the dorsal sensory territory of the ulnar nerve, which disappeared spontaneously. No patient needed to be reoperated.

## DISCUSSION

We conducted a retrospective study to analyze surgical outcomes in 12 consecutive adult patients with deep Atzei 2/3 injuries of the TFCC treated with arthroscopic knotless anchors. 83% had excellent outcomes and 17% had good outcomes, according to the Mayo Clinic wrist scale score. The final average DASH score was 8. All returned to sport activities without discomfort in the sixth month after surgery.

Various alternatives have been published to solve this problematic condition.

Nakamura et al. introduced the outside-in technique using two separate tunnels for foveal lesions. In their study of 24 wrists and a 3.5-year follow-up, the outcomes obtained were 54% excellent, 12% good, 16% fair, and 16% poor, according to the Mayo Clinic wrist scale.<sup>1</sup> Shinohara et al. presented their study on foveal repair using two tunnels and needles in 11 patients with a follow-up of 30 months. They obtained a grip strength of 84% and excellent results in 63% of the cases, good in 27%, and poor in 10%, according to the Mayo Clinic wrist scale. 27% had neuropraxia in the territory of the ulnar nerve sensory branch.<sup>7</sup>

Ma et al. compared the biomechanical outcomes in open and arthroscopic repair in cadaveric models and observed that better strength results and lower ulnar translation were achieved with arthroscopic repairs.<sup>3</sup> Atzei et al. performed arthroscopy on 48 patients using a foveal harpoon, with outcomes ranging from excellent to good on the Mayo Clinic wrist scale in 83% of cases; 85% of patients resumed sport activities at the pre-injury level, although 8% continued having a positive Nakamura test. The range of motion obtained was 95% for flexion-extension and 98% for pronosupination, while grip strength was 92%, with 10% of ulnar sensory neuropathies.<sup>1</sup>

Jung et al. published a study of arthroscopic foveal repair with knotless anchors in 42 patients with a follow-up of 26 months. The outcomes on the Mayo Clinic wrist scale were excellent (30%), good (40%), fair (26%), and poor (4%), and the grip strength obtained was 69%.<sup>8</sup> Park reported a study on the foveal arthroscopic repair of the TFCC through a tunnel in 17 patients with a follow-up of 30 months. The grip strength achieved was 57% and the outcomes were excellent and good in 83% of the patients evaluated with the Mayo Clinic wrist scale, the DASH questionnaire score was 35.5 before surgery and 9 after the intervention.<sup>9</sup>

The comparative data of our series and the main published series are summarized in [Table 4](#).

**Table 4.** Comparison of the outcomes with the reference series.

Outcomes	Technique	Patients (n)	Follow-up (months)	Grip (%)	DASH Score	Mayo Scale (good or excellent) (%)	Sensory neuropathy	Residual instability (n)
Jung et al.	Knotless anchor, 1 tunnel	42	26	70	-	71	-	2
Shinohara et al.	Anchor, 2 tunnels, with needle	11	30	-	-	93	27	-
Atzei and Luchetti	Harpoon anchor	48	30	92	42 preoperatively 20 postoperatively	83	-	2
Nakamura et al.	2 tunnels with needle	24	42	-	-	66	-	-
Park et al.	Knotless anchor, 1 tunnel	17	30	57%	35 preoperatively 7 postoperatively	83	-	-
Sala et al.	Knotless bone anchor, 1 tunnel	12	15	70	56 preoperatively 8 postoperatively	100	16	0



All these authors have obtained good or excellent outcomes similar to ours, although the follow-up in our study is shorter. In turn, we obtained a grip strength superior to that of most of the authors and a return to sport activities in all our patients. Thanks to the advances in technology and biomechanical studies of the TFCC, we know that both its stability and that of the DRUJ depend on its foveal fibers. Arthroscopic repairs can be performed by harpoons or sutures with two tunnels, one tunnel, or without a tunnel. The aim is to achieve a stable, painless, and functional DRUJ.<sup>1-3,14</sup>

Based on the aforementioned studies and our case series, we consider that the arthroscopic technique for foveal repair is a reliable one and that knotless bone anchors are the best biomechanical option for its repair.

From the biomechanical point of view, we believe that tunnel anchorage is superior to foveal harpoon anchorage, since the use of the guide allows the tunnel to be made in Matsumoto's zone 2/2 or 2/4, enabling a ligament anchorage with a minimal translation of the suture until its healing and avoiding elongated ligament scarring.

Placing a harpoon in zone 2/2 or 2/4 requires the use of accessory portals and knots that technically complicate the surgery and prolong the surgical time.<sup>15</sup>

The strengths of our study are the assessment of patients with a homogeneous condition, the appropriate minimum follow-up, and the fact that the treatment was carried out by the same surgeon, with the same method. We consider that the weaknesses are the retrospective nature of the series and the limited sample of cases, as well as the lack of long-term follow-up. We did not have a control group to demonstrate the advantage over other techniques and we believe that the associated injuries added heterogeneity to the sample and may have affected the results.

## CONCLUSION

The arthroscopic repair of Atzei 2/3 injuries using knotless bone anchors achieved acceptable and technically reproducible functional outcomes, improving ranges of motion and recovering DRUJ stability and grip strength in all cases.

---

Conflict of interest: The authors declare they do not have any conflict of interest.

S. Daroda ORCID ID: <https://orcid.org/0000-0001-7347-7705>

## REFERENCES

1. Atzei A, Luchetti R, Braidotti F. Arthroscopic foveal repair of the triangular fibrocartilage complex. *J Wrist Surg* 2015;4:22-30. <https://doi.org/10.1055/s-0035-1544226>
2. Trehan SK, Wall LB, Calfee RP, Shen TS, Dy CJ, Yannascoli SM, et al. Arthroscopic diagnosis of the triangular fibrocartilage complex foveal tear: a cadaver assessment. *J Hand Surg Am* 2018;43(7):680.e1-680.e5. <https://doi.org/10.1016/j.jhsa.2017.12.017>
3. Ma CH, Lin TS, Wu CH, Li DY, Yang SC, Tu YK. Biomechanical comparison of open and arthroscopic transosseous repair of triangular fibrocartilage complex foveal tears: a cadaveric study. *Arthroscopy* 2017;33(2):297-304. <https://doi.org/10.1016/j.arthro.2016.10.027>
4. Hong Li, Yujie Zhao, Yinghui Hua, Qianru Li, Hongyun Li, Shiyi Chen. Knotless anchor repair produced similar favourable outcomes as knot anchor repair for anterior talofibular ligament repair. *Knee Surg Sports Traumatol Arthrosc* 2020;28(12):3987-93. <https://doi.org/10.1007/s00167-020-05998-3>
5. Lacheta L, Dekker TJ, Anderson N, Goldenberg B, Millett PJ. Arthroscopic knotless, tensionable all-suture anchor Bankart repair. *Arthrosc Technic* 2019;8(6):e647-e653. <https://doi.org/10.1016/j.eats.2019.02.010>
6. Palmer AK. Triangular fibrocartilage complex lesions: a classification. *Hand Surg Am* 1989;14(4):594-606. [https://doi.org/10.1016/0363-5023\(89\)90174-3](https://doi.org/10.1016/0363-5023(89)90174-3)



7. Shinohara T, Tatebe M, Okui N, Yamamoto M, Kurimoto S, Hirata H. Arthroscopically assisted repair of triangular fibrocartilage complex foveal tears. *J Hand Surg Am* 2013;38(2):271-7. <https://doi.org/10.1016/j.hsa.2012.11.008>
8. Jung HS, Song KS, Jung HS, Yoon BI, Lee JS, Park MJ. Clinical outcomes and factors influencing these outcome measures resulting in success after arthroscopic transosseous triangular fibrocartilage complex foveal repair. *Arthroscopy* 2019;35(8):2322-30. <https://doi.org/10.1016/j.arthro.2019.03.060>
9. Park JH, Kim D, Park JW. Arthroscopic one-tunnel transosseous foveal repair for triangular fibrocartilage complex (TFCC) peripheral tear. *Arch Orthop Trauma Surg* 2018;138(1):131-8. <https://doi.org/10.1007/s00402-017-2835-3>
10. Geissler WB. Management of scapholunate instability. En: Geissler WB (ed). *Wrist arthroscopy*. New York: Springer; 2005:86-93.
11. De Smet L. The DASH questionnaire and score in the evaluation of hand and wrist disorders. *Acta Orthop Belg* 2008;74(5):575-81. PMID: 19058688
12. Cáceres-Palou E, López-Prats F, Mesa-Ramos M, et al. Valoración de resultados en Cirugía Ortopédica y Traumatología. *Rev Esp Cir Ortop Traumatol* 2005;49(S1):119-42. Disponible en: <https://www.elsevier.es/en-revista-revista-espanola-cirugia-ortopedica-traumatologia-129-articulo-valoracion-resultados-cirugia-ortopedica-traumatologia-X1888441505011090>
13. DaSilva MF, Goodman AD, Gil JA, Akelman EJ. Evaluation of ulnar-sided wrist pain. *Am Acad Orthop Surg* 2017;25(8):e150-e156. <https://doi.org/10.5435/JAAOS-D-16-00407>
14. Matsumoto T, Tang P, Fujio K, Strauch RJ, Rosenwasser MP. The optimal suture placement and bone tunnels for TFCC repair: a cadaveric study. *J Wrist Surg* 2018;7(5):375-81. <https://doi.org/10.1055/s-0038-1661361>
15. Chen WJ. Arthroscopically assisted transosseous foveal repair of triangular fibrocartilage complex. *Arthrosc Tech* 2017;6(1):e57-e64. <https://doi.org/10.1016/j.eats.2016.09.004>