

Ulnar Artery Pseudoaneurysm in a Child. Case Report and Literature Review

Laura Togneri, Lucas Fernández Korosek

Upper Limb Reconstruction and Hand Surgery Sector, Orthopedics and Traumatology Service, Hospital de Pediatría SAMIC "Prof. Dr. Juan P. Garrahan", Autonomous City of Buenos Aires, Argentina

ABSTRACT

Pseudoaneurysms of the arteries of the hand are infrequent; few reports of cases in adult patients, secondary to closed or open trauma, have been found in the literature.

The diagnosis is confirmed by Doppler ultrasound and other complementary studies. If it is left untreated, the complications include thrombosis, distal digital artery embolism, nerve injury, or necrosis. Surgery is the recommended treatment and consists of resection of the pseudoaneurysm and simple ligation, arteriorraphy, or vascular reconstruction with graft. The objective of this report is to describe a case of hypothenar pseudoaneurysm due to penetrating injury in a pediatric patient, and, due to the rarity of this condition, to conduct a non-systematic review of the current literature.

Keywords: Pseudoaneurysm; artery; ulnar; hand; pulsatile tumor.

Level of Evidence: IV

Seudoaneurisma cubital en un niño. Reporte de un caso y revisión bibliográfica

RESUMEN

Los seudoaneurismas de las arterias de la mano son infrecuentes, se han publicado escasos reportes de casos de adultos, secundarios a un trauma cerrado o abierto. El diagnóstico se confirma mediante ecografía Doppler y otros estudios complementarios. Si no se trata, se puede complicar con trombosis, embolia distal de arterias digitales, lesión nerviosa o necrosis. La cirugía es el tratamiento recomendado y consiste en resección del segmento dañado y ligadura simple, arteriorrafia o reconstrucción vascular con injerto. Los objetivos de este reporte son describir un caso de seudoaneurisma hipotenar secundario a una herida penetrante en un niño y, dada la rareza de este cuadro, revisar, de manera no sistemática, la bibliografía actual.

Palabras clave: Seudoaneurisma; arteria; cubital; mano; tumoración pulsátil.


Nivel de Evidencia: IV

INTRODUCTION

Pseudoaneurysm or false aneurysm is defined as a defect or dilation of the arterial wall that does not compromise all of its layers, leading to the formation of a hematoma by extravasation, with communication of the intravascular and extravascular space. It differs from true aneurysm in that it involves all three layers of the arterial wall.^{1,2,3}

The origin of the ulnar artery pseudoaneurysm, whether at the level of the wrist or distal to it, is varied. Closed trauma is often described as part of hypothenar hammer syndrome, caused by repetitive percussion at this level and dilation of the arterial wall. Penetrating injury, iatrogenic catheterization, and intraoperative trauma represent the main invasive causes that originate it.^{1,4,5,6} They are rare lesions, whose differential diagnosis includes lipomas, cysts and synovial tumors, abscesses, neurofibromas, and soft tissue sarcomas, among others.⁴ Early diagnosis is vital, because if left untreated, it increases the risk of thrombosis with limb ischemia, compression and subsequent nerve injury, and necrosis.⁵⁻⁶

Received on April 19th, 2021. Accepted after evaluation on May 1st, 2021 • Dra. LAURA TOGNERI • lauratogneri@hotmail.com

 <https://orcid.org/0000-0002-7165-2677>

How to cite this article: Togneri L, Fernández Korosek L. Ulnar Artery Pseudoaneurysm in a Child. Case Report and Literature Review. *Rev Asoc Argent Ortop Traumatol* 2021;86(5):639-644. <https://doi.org/10.15417/issn.1852-7434.2021.86.5.1352>

Several complementary studies are available to evaluate these vascular lesions. Doppler ultrasound is presented as the main alternative because of the low cost, its easy availability, and because it does not require radiation and general anesthesia in pediatric patients, although its disadvantage is to be dependent on the operator. Other options include arteriography, magnetic resonance imaging, magnetic resonance angiography, and CT angiography. These studies allow us to describe the lesion and its location in more detail, as well as to rule out thrombosis and vascular malformations.^{4,7,8}

The objectives of this article are to describe a case of hypothenar pseudoaneurysm secondary to a penetrating wound in a child and—given the rarity of this condition—to review the current literature in a non-systematic way.

CLINICAL CASE

A 12-year-old male with a history of penetrating glass wound in the hypothenar region of the left hand. Upon the first consultation to a tertiary care center, the skin was cleaned and sutured. During follow-up, he developed a reluctant tumor, which was interpreted as having an infectious origin, so he was prescribed oral antibiotics. After two weeks of evolution, the size and pain had increased, so he was referred to our Service. During the consultation, he reported pain of 07/10 (visual analog scale) in the hypothenar region of the left hand. Upon physical examination, an ovoid pulsatile tumor was observed (Figure 1). The Allen test was positive, and distal mobility and sensitivity in the ulnar territory were preserved. In the Doppler ultrasound, a hypoechoic image of defined walls, filled with liquid and displaying the characteristic yin-yang sign was detected, juxtaposed to the ulnar artery (Figure 2). Finally, the CT angiography showed a pseudoaneurysm of the ulnar artery at the level of the hook of the hamulus, of 2.17 x 2.45 cm in diameter (Figure 3).

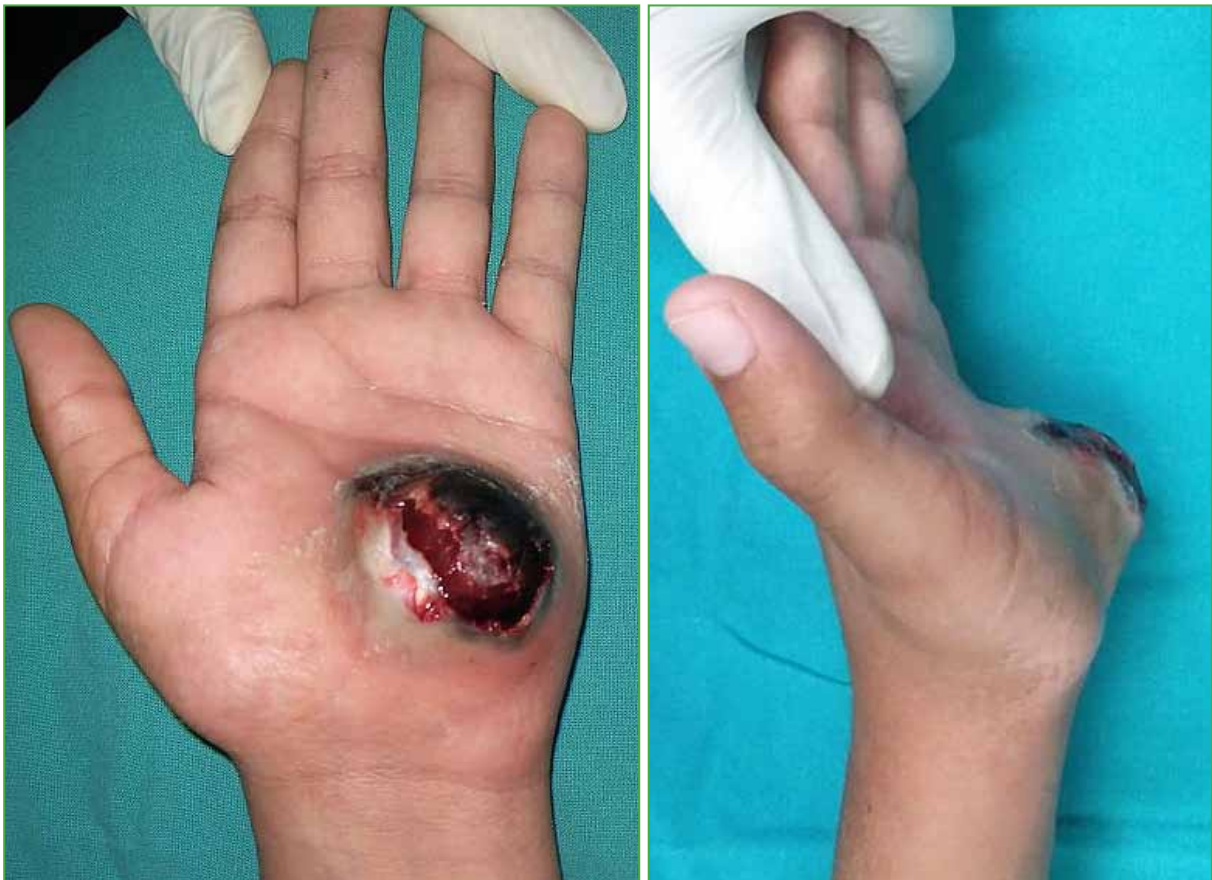

Figure 1. Preoperative anteroposterior and lateral image of the hypothenar pseudoaneurysm.

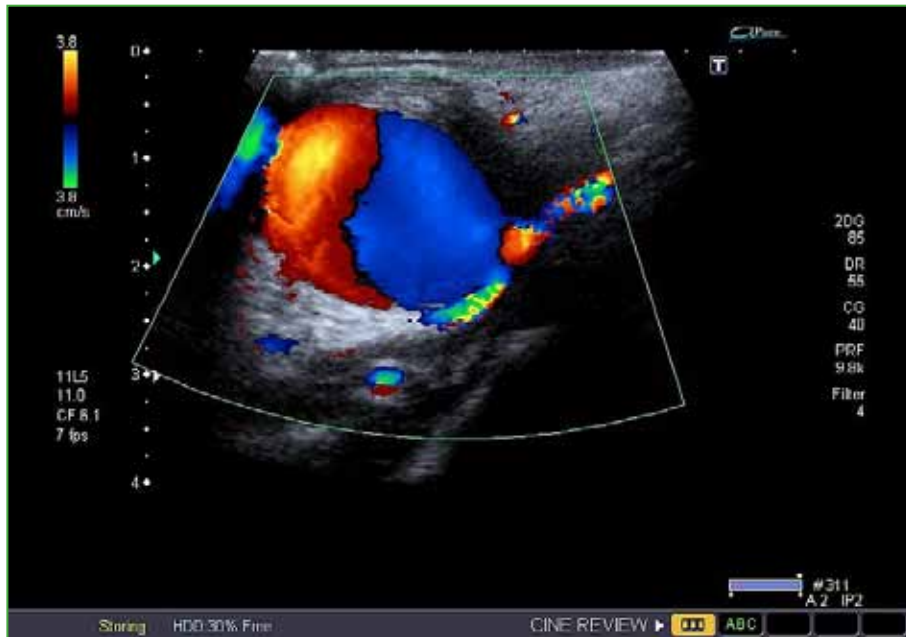


Figure 2. Preoperative Doppler ultrasound. The sign of yin-yang, pathognomonic of pseudoaneurysm, is observed.

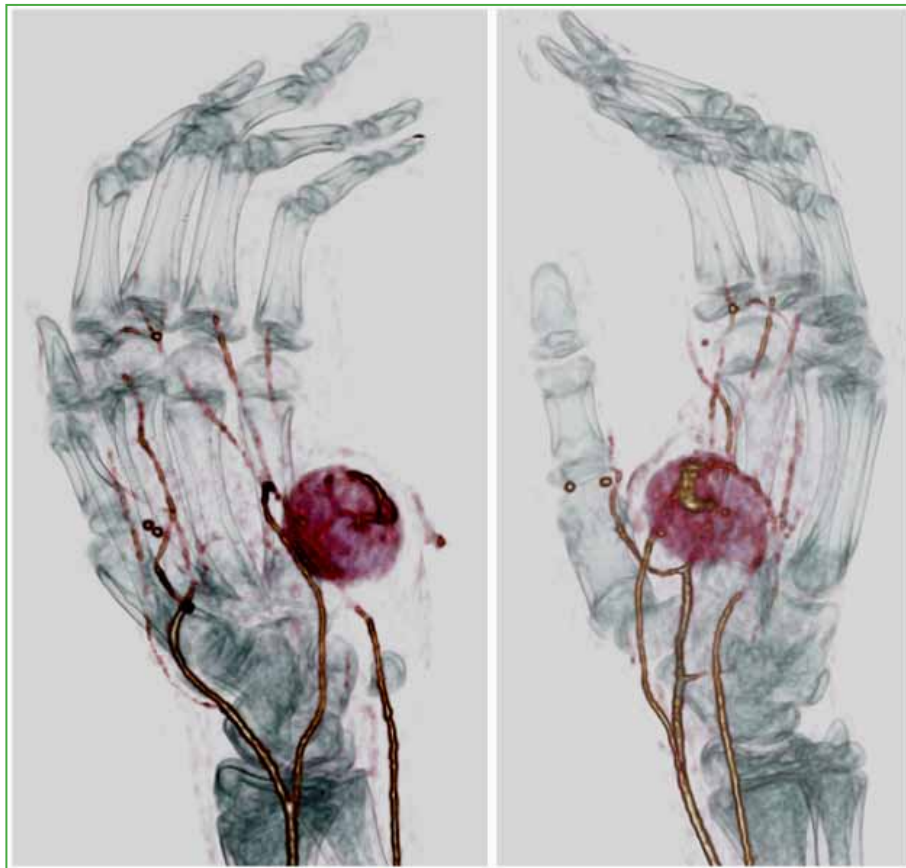


Figure 3. Preoperative CT angiography with three-dimensional visualization of hypothenar pseudoaneurysm.

After confirming the diagnosis, the tumor was resected under general anesthesia and 3.5x magnification, the approach of the previous wound was extended proximally (Guyon's canal) and distally, and the patient underwent ulnar arteriorrhaphy and ulnar microsurgical neurolysis of the sensory and motor branch (Figure 4). The sample was sent for an anatomopathological study. A bandage and a forearm splint were placed. Weekly controls were carried out until the stitches were removed. At the end of follow-up, six months after surgery, the wound was healed (Figure 5), the patient felt no pain (0/10), was able to discriminate two 2 mm acral points in the ulnar territory, and had a grip strength of 6 kg. There were no complications or sequelae.

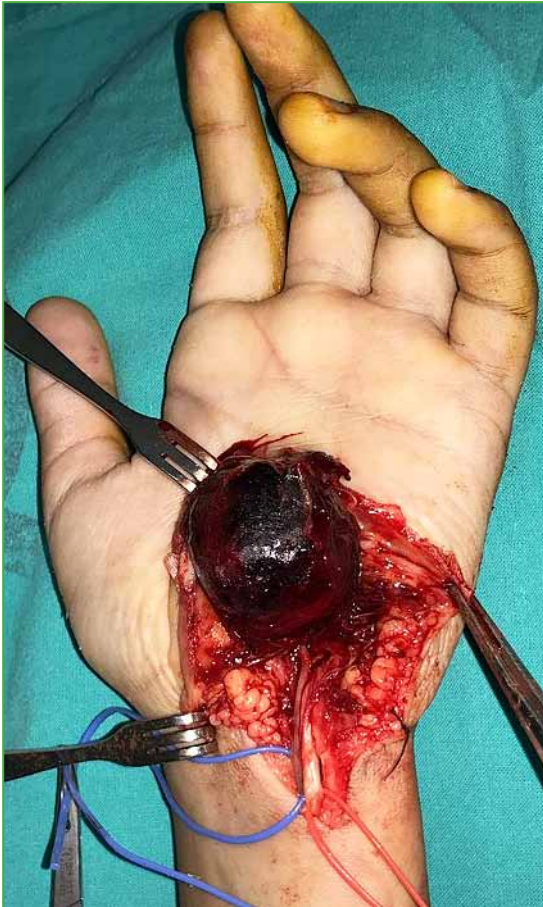

Figure 4. Intraoperative image of hypothenar pseudoaneurysm, with the extended proximal and distal approach.

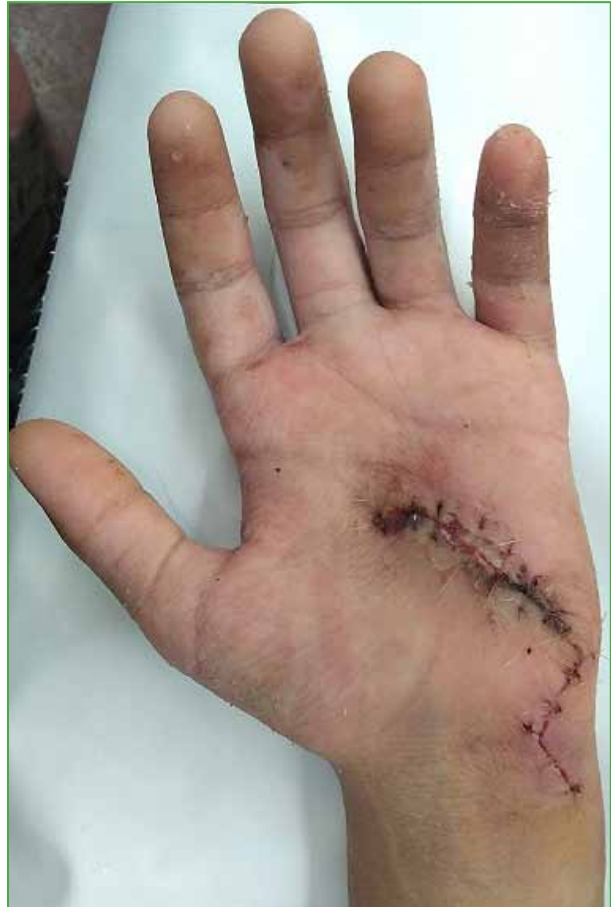

Figure 5. Appearance three weeks after resection of hypothenar pseudoaneurysm.

DISCUSSION

Due to the low incidence of pseudoaneurysms in the hand, there is no consensus regarding treatment protocols. Therapeutic options vary between resection of the lesion and ligation of the artery, and reconstruction by termino-terminal anastomosis or through a venous bypass. By verifying vascular sufficiency only on the radial artery through the Allen test and complementary studies, it is feasible to resect the pseudoaneurysm and ligate the ends of the artery without the need to restore circulation by bypass. However, this choice is questioned in pediatric patients because of the risk of future injuries in a limb whose vascularization depends on a single vessel.⁸

Kalisman et al. published the case of a man with a hypothenar pseudoaneurysm after a closed trauma. The patient had altered sensation in the ulnar territory, although there were no alterations of the intrinsic muscles. Initially, the resection of the pseudoaneurysm and a termino-terminal anastomosis were performed. After two weeks of follow-up, the appearance of a pulsatile mass was again confirmed, the recurrence of the pseudoaneurysm was confirmed, and the revision with resection and ligation of the ulnar artery was decided, with which the definitive relief of the signs of symptomatology was achieved.⁹

Dobson et al. and Hurst et al. reported cases of ulnar pseudoaneurysm in Guyon's canal and hypothenar eminence, respectively, secondary to penetrating trauma of the hand. In addition, they detected secondary hypoesthesia in the ulnar territory and paresis of the intrinsic muscles of the hand (3/5 strength MRC). They carried out the resection of the pseudoaneurysm and a termino-terminal anastomosis, with full recovery.^{10,11}

Thio described a case of hypothenar ulnar pseudoaneurysm secondary to the use of a tourniquet in a hypothenar neuroma resection surgery. A satisfactory outcome was achieved through resection and termino-terminal anastomosis.¹²

Wang et al. published the formation of an ulnar pseudoaneurysm in an elderly woman, secondary to a distal radius and ulna fracture. The fracture was treated conservatively (due to the low functional demand) and, after confirming the distal collateral circulation in the radial artery, the ulnar artery was ligated.¹³

Vancabeke et al. described the formation of an ulnar pseudoaneurysm in the site of a radial external fixator nail, used as a definitive treatment for an exposed wrist fracture. The patient was treated by manual compression and elastic bandage. Within a month of treatment, the clinical signs had disappeared and the Doppler ultrasound confirmed the resolution of the condition. There were no recurrences.¹⁴

Saour et al. and González Martínez et al. presented a case of pseudoaneurysm that appeared after conventional decompression of carpal tunnel syndrome. A hypothenar pulsatile mass, paresthesia in the ulnar territory, and pain with allodynia were detected immediately after surgery, highlighting the ulnar location of the approach as a problem. The aneurysmal sac was resected and the pain relief was immediate.^{15,16}

Unlü et al. reported on the formation of a pseudoaneurysm in the palmar segment of the ulnar artery, in a patient with chronic kidney disease. He had undergone a venous thrombectomy for a fistula, with insertion of a Fogarty catheter into the ulnar artery, distal through the arteriovenous fistula. The patient reported pain and a hypothenar pulsatile mass. Finally, the symptoms were relieved after resection of the pseudoaneurysm and termino-terminal anastomosis.¹⁷

Shaerf et al. and Komorowska-Timek et al. reported on the resolution of a post-traumatic ulnar pseudoaneurysm in the Guyon canal, treated with an ultrasound-guided thrombin injection associated with serial controls for the verification of thrombus size until complete occlusion of the pseudoaneurysm. In this case, the resolution was obtained after two procedures, confirmed by ultrasound and with normal function of the hand.^{18,19}

CONCLUSION

Based on the literature reviewed, in cases of closed or open trauma, of varied clinical presentations and with limited therapeutic options, the diagnostic suspicion of ulnar pseudoaneurysm is important to avoid complications or sequelae due to lack of treatment.

Conflict of interest: The authors declare they do not have any conflict of interest.

L. Fernández Korosek ORCID ID: <https://orcid.org/0000-0002-7472-4234>

REFERENCES

1. Erdoes LS, Brown WC. Ruptured ulnar artery pseudoaneurysm. *Ann Vasc Surg* 1995;9(4):394-6. <https://doi.org/10.1007/BF02139413>
2. Torres-Blanco Á, Gómez-Palónés F, Ortiz-Monzón E. Rapidly expanding ulnar false aneurysm related to a tablet computer. *Ann Vasc Surg* 2015;29(5):1015.e5-8. <https://doi.org/10.1016/j.avsg.2014.11.010>
3. Gimenez DC, Gilabert OV, Ruiz JG, Muns CY, Alter JB, Cubells MD. Ultrasound and magnetic resonance angiography features of post-traumatic ulnar artery pseudoaneurysm: a case report and review of the literature. *Skeletal Radiol* 2009;38(9):929-32. <https://doi.org/10.1007/s00256-009-0715-9>
4. Woodley-Cook J, Konieczny M, Simons M. The ulnar artery pseudoaneurysm. *BMJ Case Rep* 2015;2015:bcr2015212791. <https://doi.org/10.1136/bcr-2015-212791>
5. Glichenstein J, Ohama J, Lecelrecq C. *Tumors of the hand*. Berlin: Springer; 1988: 147-50.
6. Iyer RS, Hanel DP, Enriquez BK, Weinberger E. Ulnar artery aneurysm causing palmar mass in 5-month-old girl. *Pediatr Radiol* 2012;42(11):1401-4. <https://doi.org/10.1007/s00247-012-2438-7>
7. Spittel JA. Aneurysms of the hand and wrist. *Med Clin North Am* 1958; 42:1007-10. [https://doi.org/10.1016/S0025-7125\(16\)34252-3](https://doi.org/10.1016/S0025-7125(16)34252-3)
8. Sarkar R, Coran AG, Cilley RE. Arterial aneurysms in children: clinicopathologic classification. *J Vasc Surg* 1991; 13:47-56. PMID: 1987396
9. Kalisman M, Laborde K, Wolff T. Ulnar nerve compression secondary to ulnar artery false aneurysm at the Guyon's canal. *J Hand Surg Am* 1982;7:137-9. [https://doi.org/10.1016/s0363-5023\(82\)80077-4](https://doi.org/10.1016/s0363-5023(82)80077-4)
10. Dobson P, Purushothaman B, Michla Y, England S, Krishnan MK, Tourret L. Delayed ulnar nerve palsy secondary to ulnar artery pseudoaneurysm distal to Guyon's canal following penetrating trauma to the hand. *Ann R Coll Surg Engl* 2013;95:e75-e76. <https://doi.org/10.1308/003588413X13511609955850>
11. Hurst SA, Raveendran S, Eckersley JR. Ulnar artery pseudoaneurysm following single non-penetrating trauma to the hypotenar region. *J Hand Surg Eur* 2014;39(7):786-8. <https://doi.org/10.1177/1753193412462309>
12. Thio RT. False aneurysm of the ulnar artery after surgery employing a tourniquet. *Am J Surg* 1972;123(5):604-5. [https://doi.org/10.1016/0002-9610\(72\)90231-0](https://doi.org/10.1016/0002-9610(72)90231-0)
13. Wang AA, Strauch RJ, Moore JA. Pseudoaneurysm of the ulnar artery occurring after fracture of the distal radius and ulna: a case report. *J Hand Surg Am* 1998;23(5):933-7. [https://doi.org/10.1016/S0363-5023\(98\)80176-7](https://doi.org/10.1016/S0363-5023(98)80176-7)
14. Vancabeke M, Heiderich B, Bellens B, Putz P. Pseudoaneurysm of the ulnar artery following use of an external fixator-a case report. *Acta Orthop Scand* 1999;70(5):522-3. <https://doi.org/10.3109/17453679909000994>
15. Saour S, Khan U, Feldberg L. Ulnar artery pseudoaneurysm post-carpal tunnel decompression. *J Hand Surg Eur* 2008;33(3):391-2. <https://doi.org/10.1177/1753193408090116>
16. González Martínez P, Salazar Agorria A, Bravo Ruiz E, Suárez Tornin MJ, Vega Manrique R. Pseudoaneurisma de arteria cubital después de cirugía de túnel del carpo. *Angiología* 2012;64(5):220-1. <https://doi.org/10.1016/j.angio.2012.03.004>
17. Unlü Y, Ceviz M, Polat P. False aneurysm in the palmar segment of the ulnar artery: report of a case. *Surg Today* 2003;33(2):148-50. <https://doi.org/10.1007/s005950300034>
18. Shaerf DA, Robertson B, Horwitz M. Traumatic pseudoaneurysm of the ulnar artery treated with ultrasound guided thrombin injection. *J Hand Surg Eur* 2019;44(6):652-4. <https://doi.org/10.1177/1753193419841510>
19. Komorowska-Timek E, Teruya T, Abou-Zamzam A, Papa D, Ballard JL. Treatment of the radial and ulnar artery pseudoaneurysms using percutaneous thrombin injection. *J Hand Surg Am* 2004;29(5):936-42. <https://doi.org/10.1016/j.hsa.2004.05.009>