

# Hip Labral Reconstruction Using the Ligamentum Teres Capitis: Case Report and Surgical Technique

Fernando Díaz Dilernia, Franco L. De Cicco, Fernando Comba, Martín Buttaró, Gerardo Zanotti

Hip Center "Sir John Charnley", Orthopedics and Traumatology Institute "Prof. Dr. Carlos E. Ottolenghi", Hospital Italiano de Buenos Aires, Autonomous City of Buenos Aires, Argentina

## ABSTRACT

Labral tears with insufficient substance can be treated with augmentation, reconstruction, or grafting techniques. If the remnant labrum is very scarce, reconstructive options would be the most appropriate. We present the case of a 40-year-old female patient who had undergone two failed hip arthroscopies due to labral tears. Following the original technique described by Ganz, a surgical hip dislocation was performed and the Ligamentum Teres Capitis was resected to cover the labral defect. To our knowledge, this is the first report of labral reconstruction using the Ligamentum Teres Capitis in our literature. Despite poorly reported outcomes in patients with previous procedures, surgical repair using the Ligamentum Teres Capitis has proven to be a viable option.

**Keywords:** Hip; acetabulum; autografts; labral tear; surgical hip dislocation.

**Level of Evidence:** IV

## Reconstrucción del labrum de la cadera con injerto de ligamento redondo de la cabeza femoral. Presentación de un caso y descripción de la técnica quirúrgica

## RESUMEN

Las lesiones del labrum de la cadera con sustancia insuficiente se pueden tratar con técnicas de aumento, de reconstrucción o con trasplante de tejidos. Si el remanente labral es muy escaso, las opciones reconstructivas serían las más adecuadas. Se presenta el caso de una paciente de 40 años con dos cirugías artroscópicas previas fallidas por lesión labral, que fue sometida a una luxación controlada de cadera, siguiendo la técnica original descrita por Ganz, y a la resección del ligamento redondo de la cabeza femoral para cubrir el defecto del labrum. Según nuestro conocimiento, se trata del primer reporte de reconstrucción labral utilizando el ligamento redondo de la cabeza femoral en nuestro medio. Pese a los resultados poco alentadores en pacientes con cirugías previas, la reconstrucción labral utilizando el ligamento redondo ha mostrado ser una alternativa viable.

**Palabras clave:** Cadera; acetábulo; autoinjertos; lesión labral; luxación controlada.

**Nivel de Evidencia:** IV

## INTRODUCTION

5-15% of injuries suffered by athletes cause hip pain, and more than half of these patients report mechanical symptoms attributable to a labral injury.<sup>1,2</sup> The labrum increases the contact surface of the acetabulum,<sup>3</sup> improves joint stability,<sup>4</sup> reducing the load forces that are transmitted to the cartilage, and intervenes in proprioception.<sup>5,6</sup> For the correct sealing effect of the labrum on the hip, intact tissue is needed to generate the pressurization of the joint fluid. This would protect and reduce the load on the cartilage, thus reducing femoroacetabular friction.<sup>5,7</sup> Labral injuries decrease pressurization within the hip; intra-articular pressure is restored after repair.<sup>8</sup>

Received on October 30<sup>th</sup>, 2020. Accepted after evaluation on December 28<sup>th</sup>, 2020 • Dr. FERNANDO DÍAZ DILERNIA • fernandodiazdilernia@gmail.com  <https://orcid.org/0000-0002-7830-2207>

**How to cite this article:** Díaz Dilernia F, De Cicco FL, Comba F, Buttaró M, Zanotti G. Hip Labral Reconstruction Using the Ligamentum Teres Capitis: Case Report and Surgical Technique. *Rev Asoc Argent Ortop Traumatol* 2021;86(4):553-559. <https://doi.org/10.15417/issn.1852-7434.2021.86.4.1281>

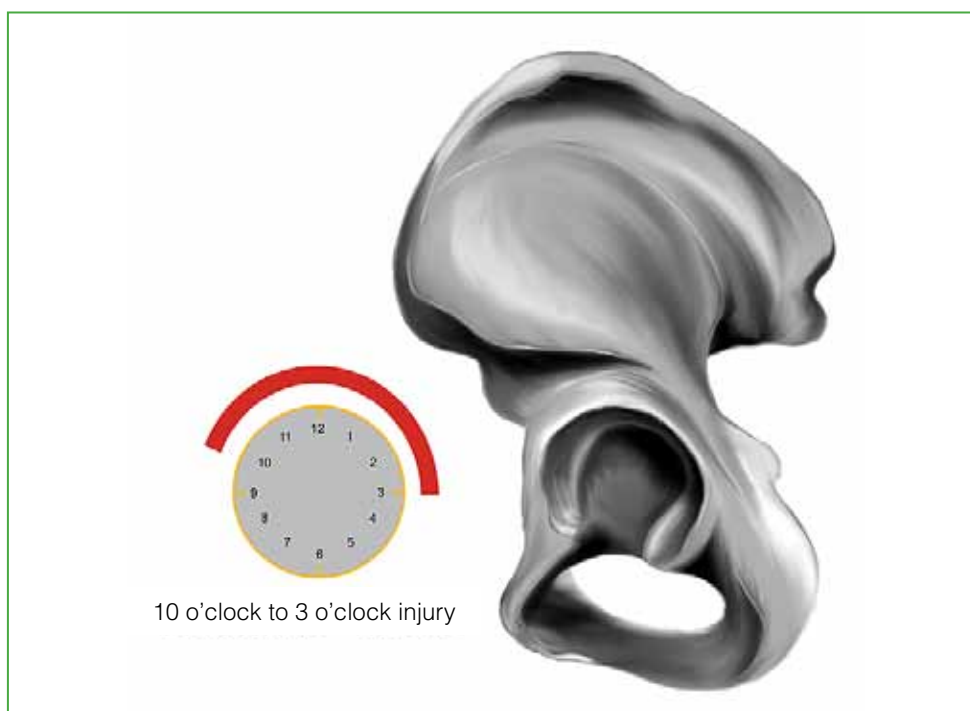
In hip preservation surgery, suture anchors are used to repair the injured labrum.<sup>9</sup> If the remnant is too thin or extensively damaged, treatment options include resection or reconstruction of the tissue. Although good results have been reported with labral debridement,<sup>10</sup> there is sufficient evidence to recommend its repair or reconstruction in order to preserve its stabilizing function.<sup>9</sup> In 2001, Ganz et al. described the controlled dislocation technique for the treatment of femoroacetabular impingement with which they obtained encouraging initial outcomes.<sup>11-13</sup> One of the disadvantages is the longer rehabilitation due to trochanteric osteotomy, deterioration of proprioception, and loss of stability attributed to capsulotomy and ligamentum teres capitis resection. As an alternative, Hartmann et al.<sup>14</sup> described a minimally invasive procedure assisted by arthroscopy.

The purpose of this article is to describe the surgical technique of labral reconstruction using the ligamentum teres capitis as a graft and to report the postoperative outcomes in a patient treated with this technique. To our knowledge, this would be the first case reported in our field.

## CLINICAL CASE

A 40-year-old professional dancer, female, with a history of two failed arthroscopies performed in another Center, consulted for left hip pain, difficulty walking, and a decreased range of motion due to pain. She presented 0°-80° flexion, 90°-0° extension, 0°-35° abduction, 35°-0° adduction, and 0°-25° external and internal rotation.

Anteroposterior pelvic and lateral hip radiographs, computed tomography, and magnetic resonance imaging studies were performed, which revealed an extensive labrum lesion from 10 o'clock to 3 o'clock (Figure 1), with areas only 2 mm thick. The degenerative changes corresponded to a grade 1 of the Tönnis classification. Wiberg's acetabular index and lateral center-edge angle, measured in the preoperative radiographs, were 3 ° and 33 °, respectively. The preoperative alpha angle, measured in the axial planes of the magnetic resonance, was 40°. The preoperative clinical-functional Merle d'Aubigné and Postel score was 8. With the diagnosis of an extensive labral injury and after unsuccessful conservative treatment, the patient underwent a controlled hip dislocation, following the technique described by Ganz, and labral reconstruction using the ligamentum teres capitis as a graft.



**Figure 1.** Anatomical drawing of the entire surface of the acetabulum. On the left, a schematic representation of a clock is seen to exemplify the extensive labral injury suffered by the patient.

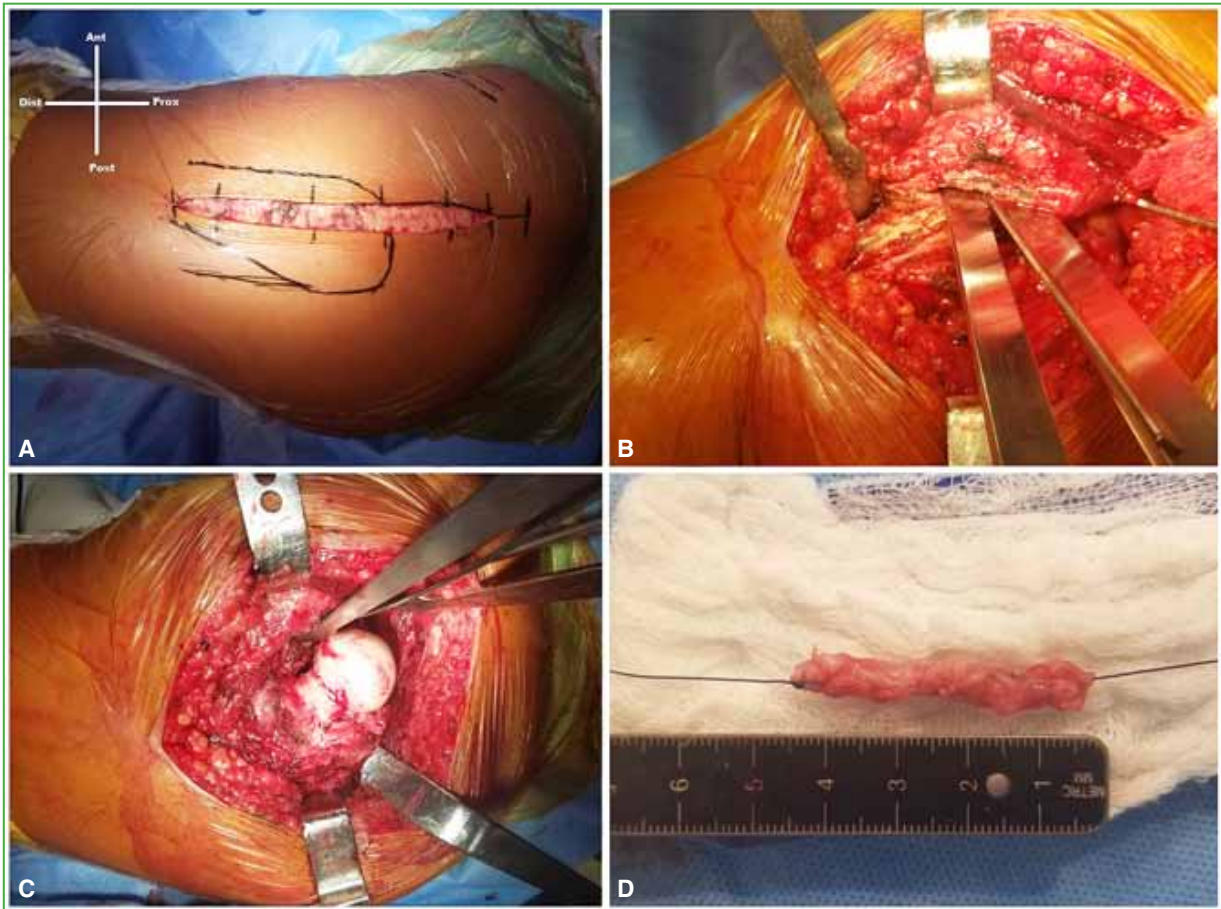
## Surgical technique

Vascularization of the femoral head is provided mainly by the deep branch of the medial femoral circumflex artery (MFCA)<sup>15</sup>, which is protected by the obturator externus muscle during the controlled surgical dislocation of the hip. Using a posterolateral approach together with a trochanteric osteotomy, the hip can be dislocated anteriorly, respecting the integrity of the external rotator muscles and achieving a 360 ° exposure. To accomplish this, the patient was placed in the lateral decubitus position and a posterior hip approach was performed (Figure 2A), incising the fascia lata and the gluteus maximus, seeking its posterior retraction to access the posterolateral region, still covered by the rotator muscles. The first assistant rotated the leg internally to achieve the correct identification of the posterior border of the gluteus medius, thus allowing a further incision from the posterosuperior border of the greater trochanter to the posterior border of the vastus lateralis.

With an oscillating saw and chisels, the osteotomy of the greater trochanter was performed, which had to respect the most posterior insertion of the gluteus medius at the proximal level in order to preserve the deep branch of the MFCA that becomes intracapsular at the proximal level of the superior gemellus muscle (Figure 2B). After releasing the gluteus maximus and the most posterior fibers of the gluteus medius, the fragment of the greater trochanter was displaced anteriorly, maintaining the insertion of the vastus lateralis. After careful retraction of the posterior border of the gluteus medius, the piriformis tendon became visible. The inferior border of the gluteus minimus was then separated from the piriformis and the underlying capsule, preserving the anastomosis formed between the inferior gluteal artery and the MFCA. Special care must be taken with the sciatic nerve, which can be identified below the piriformis muscle.

The joint capsule was then exposed, retracting the muscular plane in an anterosuperior direction, including the gluteus minimus. In this step, the assistant must flex and outwardly rotate the hip so as to be able to correctly visualize the capsule and allow the surgeon to incise it anterolaterally and anteroinferiorly, in a z-shape, protecting the deep branch of the MFCA. The first incision was extended to the acetabular rim, parallel to the labrum and reaching the piriformis tendon posteriorly.

Next, a controlled hip dislocation was performed by external flexion and rotation, placing the leg in a sterile bag. The ligamentum teres capitis was then divided, allowing complete anterior dislocation and obtaining a 360 ° view of both the acetabulum and the femoral head (Figure 2C). In our case, the sectioned ligamentum teres capitis was preserved and debrided, and an incomplete longitudinal incision was made, achieving a width of approximately 5 mm, to later be tubulized with resorbable sutures (Figure 2D).

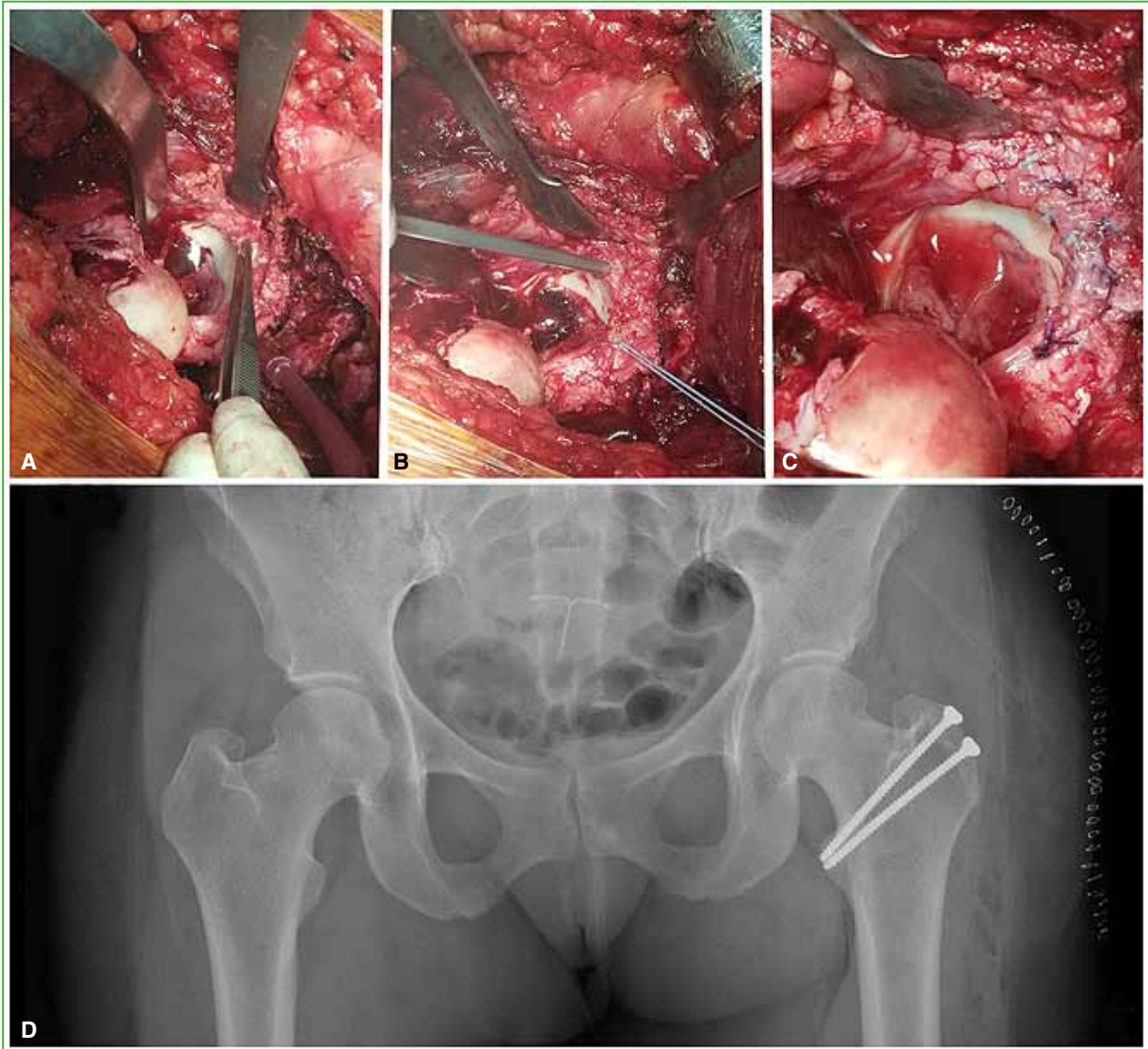


**Figure 2.** A. Posterolateral hip approach with the patient in the right lateral decubitus position. B. Osteotomy of the greater trochanter respecting the most posterior insertion of the gluteus medius at the proximal level. C. Flexion, external rotation, and section maneuvers of the ligamentum teres capitis to achieve controlled anterior dislocation of the hip with a 360° view. D. Tubulization of the ligamentum teres capitis graft.

For a correct and complete visualization of the acetabulum, the assistant must elevate the knee and exert an axial force on it, thus moving the femoral head posteriorly. Due to the surgical history of our patient, the remaining labrum was practically null from 10 o'clock to 3 o'clock, with abundant scar tissue (Figure 3A). The corresponding debridement and the necessary acetabular osteoplasty were carried out to achieve a suitable receptor bed for the graft. Since the patient did not have a CAM lesion in the femoral neck, it was not necessary to perform a femoral osteoplasty. Then, the anchors used in the previous surgeries were extracted and the area of the defect was marked on the acetabular bone ridge.

The tubulized graft was positioned, achieving its fixation with biodegradable suture anchors (Figure 3B). Once the graft was fixed, resorbable reinforcing stitches were placed with the surrounding joint capsule (Figure 3C). The exposed articular cartilage was constantly irrigated with lactated Ringer's solution to prevent its degeneration. During surgery, Beck's classification<sup>16</sup> was used to categorize the chondral damage, which was grade 1. Hip reduction was easily accomplished by manual traction on the flexed knee and internal hip rotation. The sealing effect of the labrum was recovered and corroborated under direct vision when the characteristic sound was heard when trying to dislocate the hip again. The joint capsule must be repaired without too much stress to avoid damage to the retinacular vessels. Finally, the greater trochanter was reduced and fixed with two 3.5 mm cortical screws (Figure 3D).





**Figure 3.** A. Deficient labrum with abundant scar tissue. B. Debridement of the acetabular bone ridge and placement of biodegradable anchor sutures. C. Resorbable reinforcement sutures with the surrounding joint capsule. D. Postoperative anteroposterior pelvic radiograph showing reduction and fixation of the greater trochanter with two 3.5 mm cortical screws.

Antithrombotic prophylaxis with low molecular weight heparin (40 mg/day) was administered subcutaneously for four weeks. Postoperative rehabilitation included assisted active and passive mobility and partial weight bearing on the operated side for four weeks, with a progressive increase according to tolerance over the next two weeks. Hip flexion was limited to  $90^\circ$ , and an internal and external rotation of  $20^\circ$  was indicated for four weeks, with a gradual increase in the following weeks.

### Postoperative results

Clinical-functional controls were carried out 15, 45, and 90 days after surgery, and then annually. At each consultation, the corresponding clinical and radiographic controls were carried out using the Merle d'Aubigné and Postel scale.

After 45 days, full weight-bearing and unaided walking were authorized, and the patient resumed her work activities three months after surgery. The evolution was satisfactory for the first 12 months. After that period, she began to experience pain again from active and passive mobility, and a range of motion limited by pain. At 18 months of follow-up, the patient continues with the same symptoms, undergoes kinesiological rehabilitation, and uses a cane to walk long distances. The postoperative clinical-functional Merle d'Aubigné and Postel score was 11, with 0°-90° flexion, 100°-0° extension, 0°-40° abduction, 40°-0° adduction, and 0°-30° external and internal rotation.

## DISCUSSION

Labrum injury is more frequent in hips with combined or pincer morphologies, but not in pure CAM injuries,<sup>17</sup> and different studies have reaffirmed the theory of the sealing effect of labral tissue. In addition to being a primary stabilizer of the hip, a healthy labrum confers additional stability through this effect. For its part, the intra-articular fluid exerts a negative pressure, providing greater stability, as long as the labrum is undamaged.<sup>18</sup> As published, labral reconstruction using the ligamentum teres capitis graft successfully restores this sealing function.

Different open and arthroscopic techniques have been described for labral repair. While labral reconstruction replaces damaged tissue, graft augmentation preserves the original healthy tissue.<sup>19</sup> In this way, it seeks to maintain hoop tension while preserving the healthy labral remnant in order to improve the sealing effect. This is achieved by placing the graft between the acetabular bone ridge and the remaining healthy labrum. The ligamentum teres capitis is an ideal graft, as it can be easily resected during controlled hip dislocation without generating additional morbidity. Another alternative is the fascia lata or iliotibial band graft as reported by Philippon et al.<sup>20</sup> An advantage of open surgery is that it allows confirmation of restoration of the sealing effect when the characteristic sound is heard when attempting to dislocate the hip. It also makes it possible to readjust the graft and ensure its correct suture more easily.

The evidence in the literature regarding the surgical history in these patients is compelling. Weidner et al. have observed inferior outcomes using the ligamentum teres capitis as a graft for labral reconstruction in patients who had already undergone surgery.<sup>21</sup> Intra-articular adhesions, recurrences, poor tissue quality, and the presence of osteophytes have been described. On the other hand, patients with previous surgeries have a longer history of pain and, therefore, we could postulate that their chronification is a possible cause of the poor outcomes.

Philippon et al.<sup>20</sup> also demonstrated lower postoperative satisfaction associated with joint space narrowing (<2 mm), increasing patient age (≥30 years), and waiting time >1 year for surgery from the time of injury. On the contrary, the good outcomes of this technique are mainly based on a meticulous knowledge of the anatomy, adequate exposure of the acetabulum, correct preparation and fixation of the graft, the adequate restoration of the sealing effect corroborated by low direct vision in open surgery, and finally a careful postoperative rehabilitation.

## CONCLUSIONS

Open labral reconstruction using ligamentum teres capitis as a graft is a viable alternative without a significant increase in morbidity. It is important to note that this technique is a salvage procedure and requires a trained surgeon and certain patient characteristics to achieve a satisfactory outcome. Less encouraging outcomes can be expected in patients with previous surgeries, >30 years, with a joint narrowing <2 mm, and a waiting time >1 year from injury to surgical reconstruction.

---

Conflict of interests: The authors declare they do not have any conflict of interests.

## REFERENCES

1. Philippon MJ, Schroder e Souza BG, Briggs KK. Labrum: resection, repair and reconstruction sports medicine and arthroscopy review. *Sports Med Arthrosc* 2010;18(2):76-82. <https://doi.org/10.1097/JSA.0b013e3181de376e>
2. Singh PJ, O'Donnell JM. The outcome of hip arthroscopy in Australian football league players: a review of 27 hips. *Arthroscopy* 2010;26(6):743-9. <https://doi.org/10.1016/j.arthro.2009.10.010>
3. Haviv B, O'Donnell J. Arthroscopic treatment for acetabular labral tears of the hip without bony dysmorphism. *Am J Sports Med* 2011;(39 Suppl):79S-84S. <https://doi.org/10.1177/0363546511412915>
4. Ejnisman L, Philippon MJ, Lertwanich P. Acetabular labral tears: diagnosis, repair, and a method for labral reconstruction. *Clin Sports Med* 2011;30(2):317-29. <https://doi.org/10.1016/j.csm.2010.12.006>
5. Ferguson SJ, Bryant JT, Ganz R, Ito K. An in vitro investigation of the acetabular labral seal in hip joint mechanics. *J Biomech* 2003;36(2):171-8. [https://doi.org/10.1016/s0021-9290\(02\)00365-2](https://doi.org/10.1016/s0021-9290(02)00365-2)
6. Ferguson SJ, Bryant JT, Ganz R, Ito K. The influence of the acetabular labrum on hip joint cartilage consolidation: a poroelastic finite element model. *J Biomech* 2000;33(8):953-60. [https://doi.org/10.1016/s0021-9290\(00\)00042-7](https://doi.org/10.1016/s0021-9290(00)00042-7)
7. Cadet ER, Chan AK, Vorys GC, Gardner T, Yin B. Investigation of the preservation of the fluid seal effect in the repaired, partially resected, and reconstructed acetabular labrum in a cadaveric hip model. *Am J Sports Med* 2012;40(10):2218-23. <https://doi.org/10.1177/0363546512457645>
8. Nepple JJ, Philippon MJ, Campbell KJ, Dornan GJ, Jansson KS, LaPrade RF, et al. The hip fluid seal--Part II: The effect of an acetabular labral tear, repair, resection, and reconstruction on hip stability to distraction. *Knee Surg Sports Traumatol Arthrosc* 2014;22(4):730-6. <https://doi.org/10.1007/s00167-014-2875-y>
9. Espinosa N, Beck M, Rothenfluh DA, Ganz R, Leunig M. Treatment of femoro-acetabular impingement: preliminary results of labral refixation. Surgical technique. *J Bone Joint Surg Am* 2007;(89 Suppl 2) Pt.1:36-53. <https://doi.org/10.2106/JBJS.F.01123>
10. Byrd JWT, Jones KS. Prospective analysis of hip arthroscopy with 10-year follow up. *Clin Orthop Relat Res* 2010;468(3):741-6. <https://doi.org/10.1007/s11999-009-0841-11>
11. Ganz R, Gill TJ, Gautier E, Ganz K, Krügel N, Berlemann U. Surgical dislocation of the adult hip a technique with full access to the femoral head and acetabulum without the risk of avascular necrosis. *J Bone Joint Surg Br* 2001;83(8):1119-24. <https://doi.org/10.1302/0301-620x.83b8.11964>
12. Peters CL, Erickson JA. Treatment of femoro-acetabular impingement with surgical dislocation and debridement in young adults. *J Bone Joint Surg Am* 2006;88(8):1735-41. <https://doi.org/10.2106/JBJS.E.00514>
13. Ganz R, Parvizi J, Beck M, Leunig M, Nötzli H, Siebenrock KA. Femoroacetabular impingement: a cause for osteoarthritis of the hip. *Clin Orthop Relat Res* 2003;(417):112-20. <https://doi.org/10.1097/01.blo.0000096804.78689.c2>
14. Hartmann A, Günther K-P. Arthroscopically assisted anterior decompression for femoroacetabular impingement: technique and early clinical results. *Arch Orthop Trauma Surg* 2009;129(8):1001-9. <https://doi.org/10.1007/s00402-008-0806-4>
15. Sevitt S, Thompson RG. The distribution and anastomoses of arteries supplying the head and neck of the femur. *J Bone Joint Surg Br* 1965;47:560-73. <https://doi.org/10.1302/0301-620X.47B3.560>
16. Amenabar T, Piriz J, Mella C, Hetaimish BM, O'Donnell J. Reliability of 3 different arthroscopic classifications for chondral damage of the acetabulum. *Arthroscopy* 2015;31(8):1492-6. <https://doi.org/10.1016/j.arthro.2015.02.029>
17. Beck M, Leunig M, Parvizi J, Boutier V, Wyss D, Ganz R. Anterior femoroacetabular impingement: part II. Midterm results of surgical treatment. *Clin Orthop Relat Res* 2004;(418):67-73. PMID: 15043095
18. Philippon MJ, Nepple JJ, Campbell KJ, Dornan GJ, Jansson KS, LaPrade RF, et al. The hip fluid seal--Part I: the effect of an acetabular labral tear, repair, resection, and reconstruction on hip fluid pressurization. *Knee Surg Sports Traumatol Arthrosc* 2014;22(4):722-9. <https://doi.org/10.1007/s00167-014-2874-z>
19. Ito K, Leunig M, Ganz R. Histopathologic features of the acetabular labrum in femoroacetabular impingement. *Clin Orthop Relat Res* 2004;(429):262-71. <https://doi.org/10.1097/01.blo.0000144861.11193.17>
20. Philippon MJ, Briggs KK, Hay CJ, Koppersmith DA, Dewing CB, Huang MJ. Arthroscopic labral reconstruction in the hip using iliotibial band autograft: technique and early outcomes. *Arthroscopy* 2010;26(6):750-6. <https://doi.org/10.1016/j.arthro.2009.10.016>
21. Weidner J, Wyatt M, Beck M. Labral augmentation with ligamentum capitis femoris: presentation of a new technique and preliminary results. *J Hip Preserv Surg* 2018;5(1):47-53. <https://doi.org/10.1093/jhps/hnx049>