

Isolated Elbow Dislocation in Children Under 10 Years of Age: Report of Two Cases

Julio A. Pérez De-León, Alma F. Reyes Arceo, Manuel A. Fuentes González

Orthopedics and Traumatology Department, Instituto Guatemalteco de Seguridad Social, City of Guatemala, Guatemala

ABSTRACT

Isolated elbow dislocation is extremely rare in immature skeletons. Due to the low casuistry, the management and treatment are not standardized. Isolated dislocations in children under 10 years of age constitute a pathology described as shared evidence in studies of older children. The objective of this report is to share the experience of two cases of isolated elbow dislocation in children under 10 years of age. The children consulted the emergency unit about pain and elbow deformity a few hours after the trauma. For each case, a clinical and radiological evaluation was developed in search of associated lesions before and after closed reduction. Joint instability was ruled out under anesthesia and the patient was immobilized for two weeks. Excellent functional outcomes were obtained in both cases three months after the injury.

Keywords: Elbow dislocations; pediatrics; joint instability.

Level of Evidence: IV

Luxación aislada de codo en niños menores de 10 años: reporte de dos casos

RESUMEN

La luxación de codo aislada es muy infrecuente en esqueletos inmaduros. El manejo y el tratamiento no están estandarizados debido a la baja casuística. Las luxaciones aisladas en niños <10 años constituyen un cuadro descrito como evidencia compartida en estudios de niños más grandes. El objetivo de este artículo es comunicar dos casos de luxación aislada de codo en niños <10 años. Los niños consultan a la unidad de urgencias por dolor y deformidad en el codo a las pocas horas del trauma. En ambos casos, se realizaron evaluaciones clínicas y radiográficas en busca de lesiones asociadas antes de la reducción cerrada y después. Se descartó inestabilidad articular bajo anestesia y se inmovilizó por dos semanas. Los resultados funcionales fueron excelentes en ambos casos, a los tres meses de la lesión.

Palabras clave: Luxación de codo; pediatría; inestabilidad articular.

Nivel de Evidencia: IV

INTRODUCTION

Elbow dislocations are very rare in children under 10 years of age and especially if they are not associated with fractures or other ligament injuries.¹ There is an estimated incidence of 3-6% of dislocations within all elbow injuries; the exact rate of isolated dislocations is not known.² The average age is 12-14 years; according to Lieber et al., cases in children <10 years are rare.³ In younger children, these lesions may be confused with transphyseal fractures due to the immaturity of the physis, which plays a protective factor against true dislocations in children.²⁻⁴

The exact mechanism of the injury is unknown, the most common cause is a fall with the elbow and hand extended plus a slight valgus angulation that cushions the axial load on the posterior hinge. Elbow dislocation is classified according to the direction taken by the proximal radioulnar joint displacement in relation to the distal humerus. The most frequent presentations, in ascending order, are anterior, posterior, posteromedial, or posterolateral.^{1,2}

Received on October 4th, 2020. Accepted after evaluation on June 22nd, 2021 • Dr. JULIO A. PÉREZ-DE LEÓN • juliopereztyo@yahoo.com  <https://orcid.org/0000-0003-4756-0470>

How to cite this article: Pérez-De León JA, Reyes Arceo AF, Fuentes González MA. Isolated Elbow Dislocation in Children Under 10 Years of Age: Report of Two Cases. *Rev Asoc Argent Ortop Traumatol* 2021;86(5):659-665. <https://doi.org/10.15417/issn.1852-7434.2021.86.5.1207>

Basic radiographic evaluation includes anteroposterior and lateral images of the elbow before and after reduction, with attention directed to associated fractures, especially to the medial epicondyle, which is the most frequent (up to 50% of cases).^{5,6} Previous studies indicate that dislocation should be treated immediately or within the first four hours, with the patient sedated and radiographic confirmation.^{1,5,6}

CLINICAL CASES

Case 1

A 6-year-old boy, without a clinical history, had fallen from a tree with his elbow in hyperextension. Eight hours after the fall, he consulted with the Emergency Department about pain and deformity in his right elbow. In the initial evaluation, a closed injury was observed, associated with lateral and posterior edema and deformity with loss of range of motion. The radial pulse was palpable, the hand had a capillary refill time <2 seconds and there was no sensory deficit. An isolated posterior right elbow dislocation was observed in both the physical examination and the radiographs of the injured elbow (Figure 1).

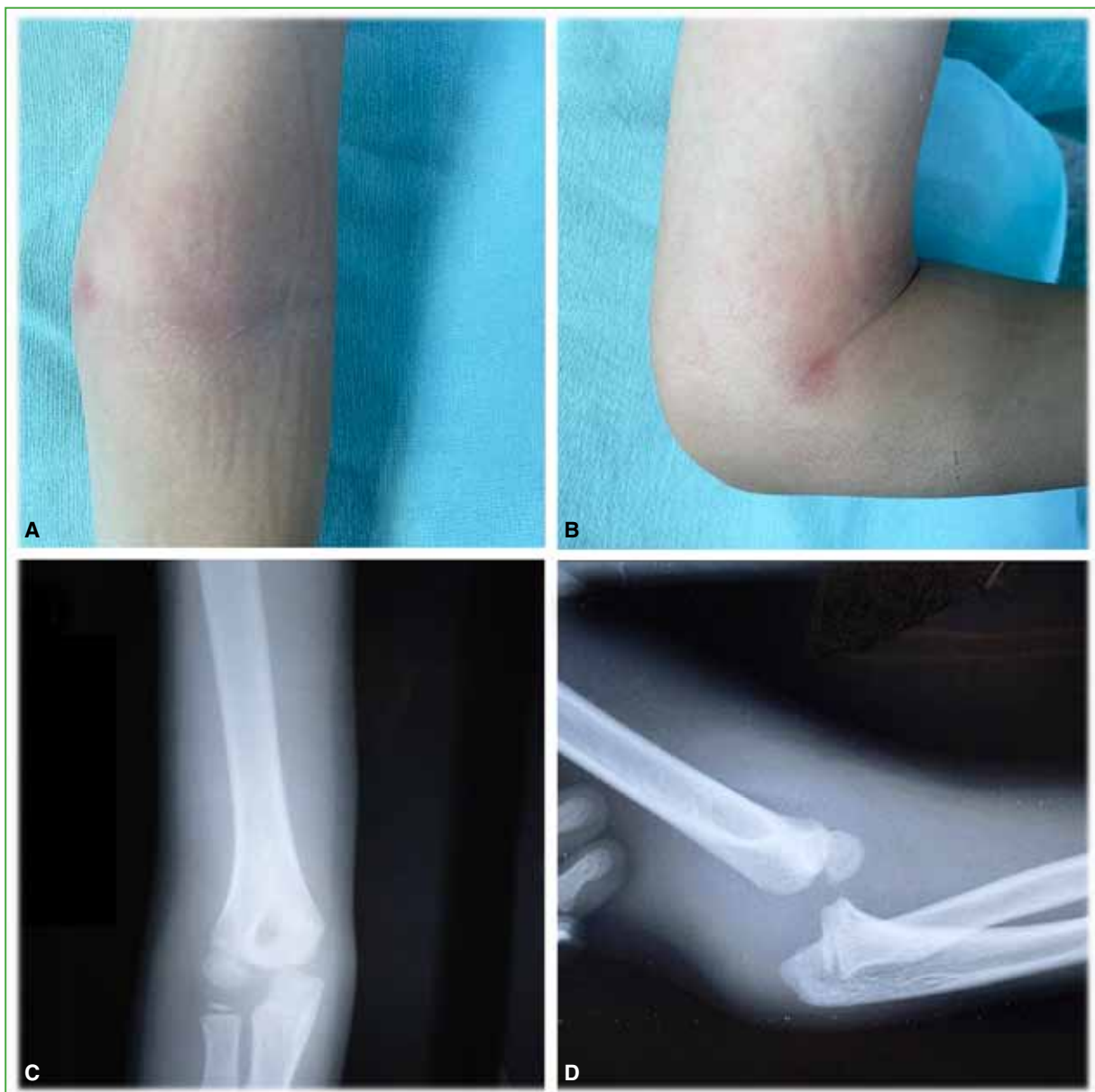

Figure 1. A. Anterior clinical image. B. Lateral clinical image. Elbow radiographs. C. Anteroposterior. D. Lateral.

The plan was to reduce the dislocation using the hyperextension and traction technique to disengage the coronoid from the olecranon fossa, followed by gentle elbow flexion and posterior translation of the distal humerus for a congruent joint reduction.^{7,8} In this way, it was possible to restore length and correct the carrying angle. An image intensifier was used for the intraoperative radiographic evaluation: a true lateral radiograph was taken to visualize congruence, then an anteroposterior orthogonal projection was used to evaluate both condyles and rule out associated fractures. Stability was evaluated under anesthesia, in flexion and extension movements, and then also in pronation and supination. In this stability analysis, spontaneous dislocation in flexion at less than 30° was determined as a surgical indication; this indication was ruled out. A long arm fiberglass splint was placed in supination for two weeks. The patient left the operating room in a stable condition with inpatient follow-up. In the immediate postoperative period, joint congruence of the right elbow was measured (Figure 2). The splint was removed after two weeks and the treating traumatologist initiated passive mobilization immediately afterward. The elbow was kept unrestrained, except for the use of the sling for up to six hours a day if the patient felt pain during the third week after the reduction. In the clinical follow-up three weeks after reduction, elbow flexion was 100° and the extension deficit was 20°, with mild pain and discomfort. At three months, the elbow flexion was 125° and the extension was total, with full and definitive ranges.

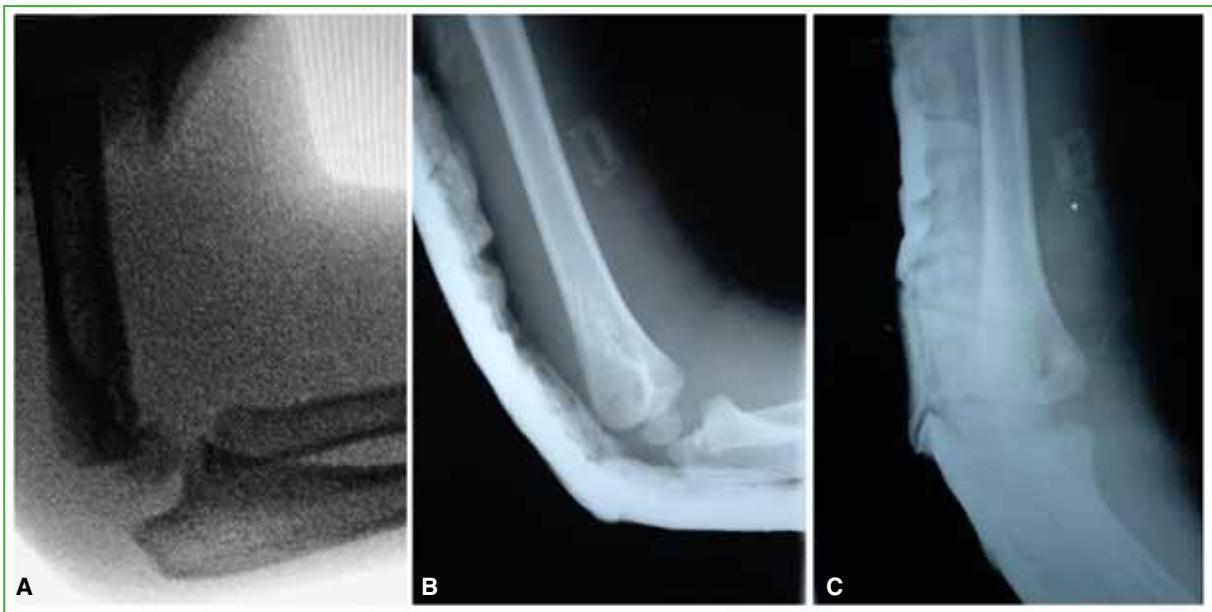


Figure 2. A. Image of the intraoperative intensifier. B and C. Immediate postoperative lateral and oblique elbow radiographs.

Case 2

A 5-year-old boy, without a clinical history, had fallen off a swing with his left elbow extended and with a valgus angulation. He attended the emergency department two hours after the injury, with pain and deformity. In the initial evaluation, we observed a closed injury associated with edema and erythema on the medial side, unassessable ranges of motion, skin hypersensitivity to superficial palpation, and palpable brachial and radial pulses. Anteroposterior and lateral radiographs of the injured elbow were taken and a posterolateral dislocation of the left elbow was detected. The treatment, which consisted of a closed reduction in the operating room under general anesthesia, was explained to the child's mother. A closed maneuver was performed with flexion, posterior traction of the ulnar fossa, and insertion of the olecranon. On the radiograph, it was found that there were no incarcerated fragments of the medial epicondyle, and the humeroulnar and humeroradial joints were congruent (Figure 3).

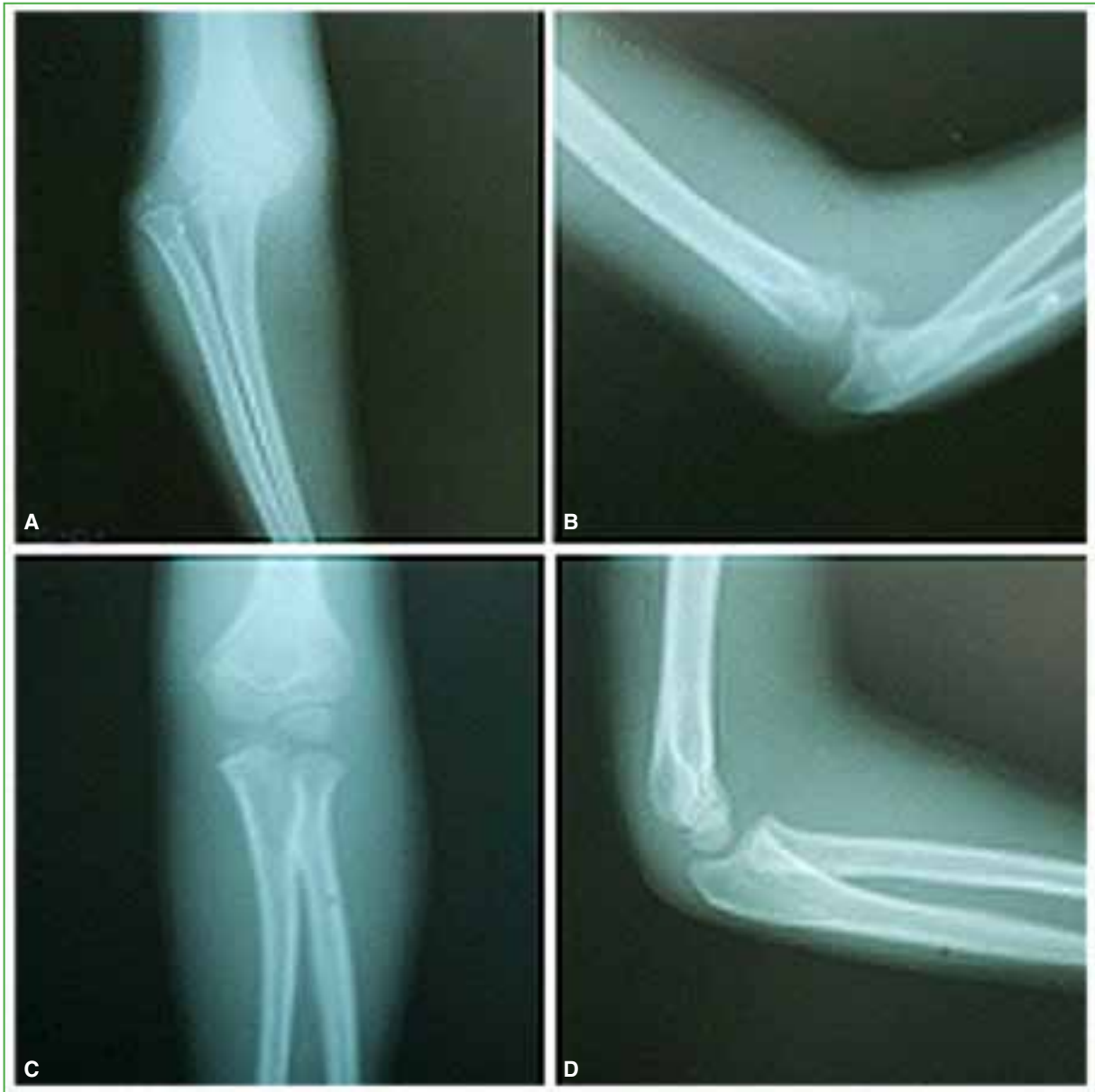

Figure 3. **A and B.** Anteroposterior and lateral elbow radiographs in the Emergency Department. **C and D.** Anteroposterior and lateral elbow radiographs after surgery.

An immobilizing long arm fiberglass splint was placed in supination for two weeks. The patient left the operating room in a stable condition. Routine radiographs were taken in congruent orthogonal projections. The boy was discharged two days later. In the follow-up visit two weeks after reduction, the splint was removed and the treating traumatologist initiated passive mobilization immediately afterward. The elbow was left unrestrained; the use of a sling was suggested, depending on the pain, but it was not necessary. At three weeks, elbow flexion was 110° and the extension had a 15° deficit associated with mild pain. The final outcomes at three months were full flexion of 130° and full extension.

In both patients, the radiographic follow-up showed no signs of heterotopic ossification or associated fractures (Figures 4 and 5).

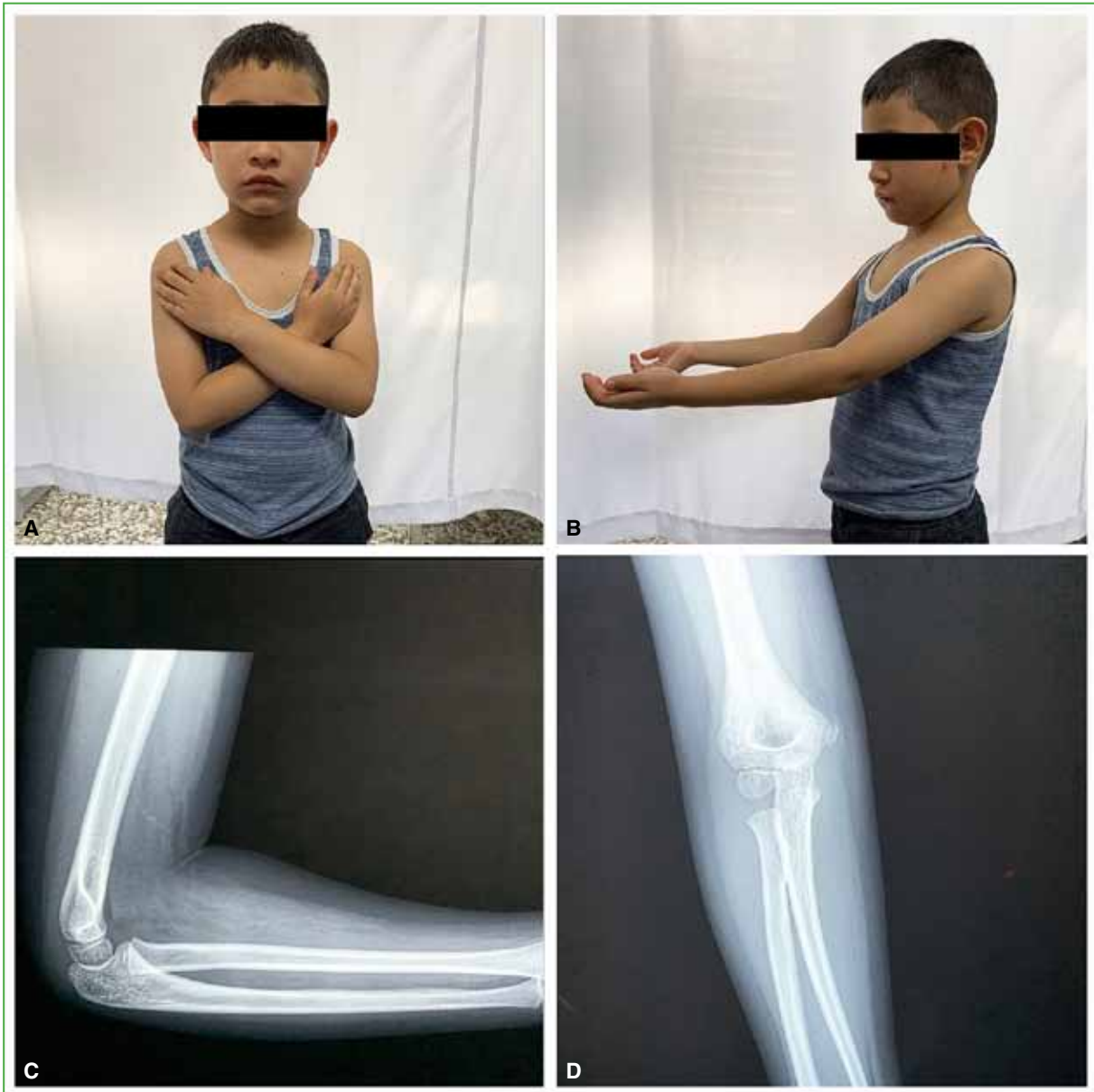

Figure 4. A and B. Functional outcomes of the first case. C and D. Radiographic outcomes of the first case.

DISCUSSION

Injuries to the joint surfaces of the elbow in immature skeletons with open physes are rare. The report of these two similar cases coincides with the published incidence of 6% and a rate of 6.4 per 100,000 children.^{2,3,6} According to the studies consulted, the dislocation occurs most frequently in males and its direction is often posterior; in our cases, dominance is not defined, because the children are preschoolers.^{9,10}

The ligaments and capsule are stronger than bone tissue; associated avulsion fractures of the epicondyles, olecranon, and head of the radius are more frequent than isolated dislocations. The mechanism of injury also involves soft tissue lesions, for example, to the brachial artery, median nerve or ulnar nerve, which are close to bone surfaces.² All these diagnostic possibilities were ruled out through thorough clinical and radiographic evaluations with the patient sedated, before and after the reduction.

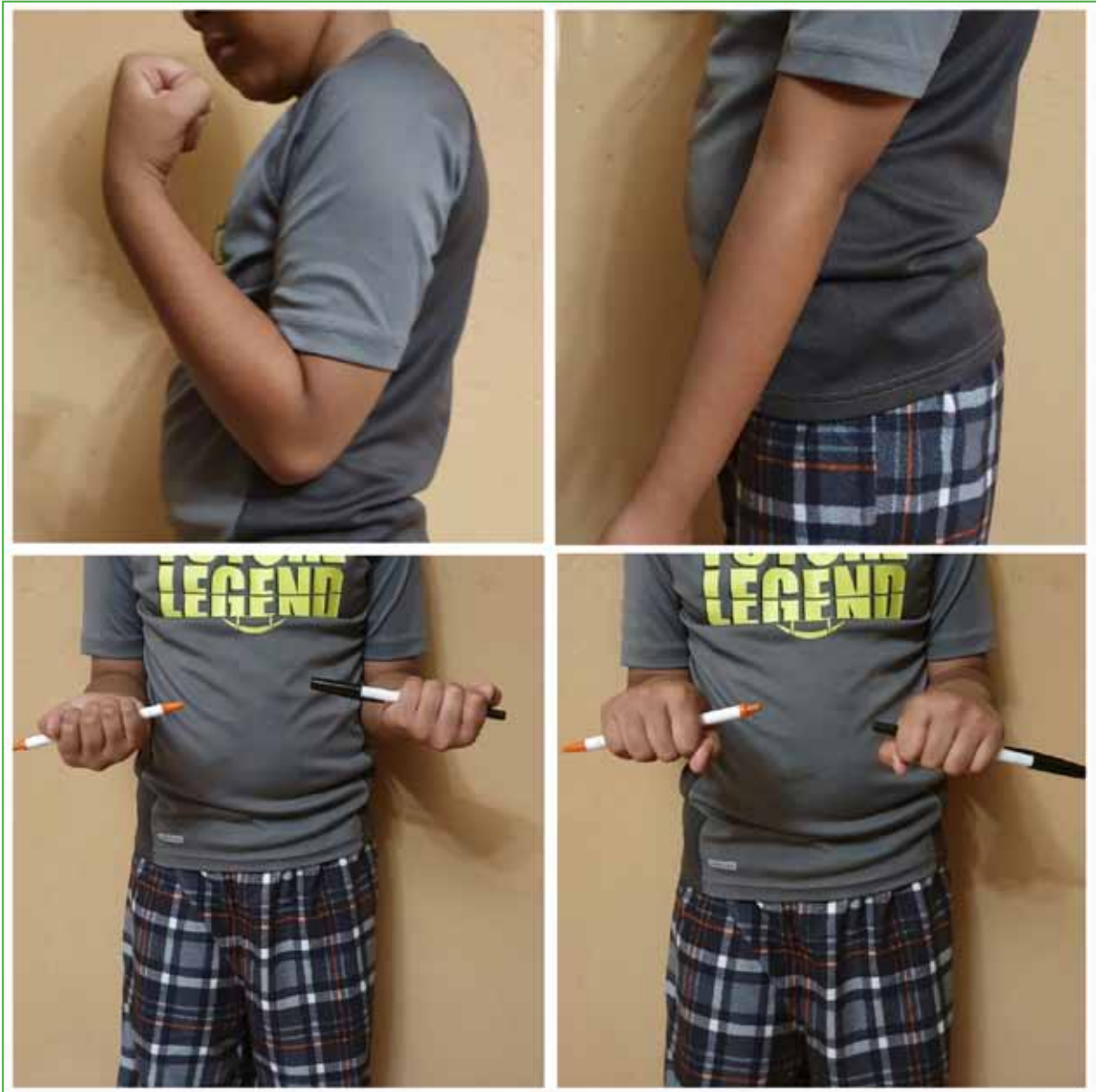

Figure 5. Functional outcomes of Case 2.

Previous studies support that satisfactory outcomes in both cases were determined by the short prolonged immobilization, closed reduction, and absence of associated injuries.^{6,11} The immediate indication of open reduction is for open dislocation, a situation that was not present in these patients.¹¹ The Roberts scale is used to classify clinical and functional outcomes. It presents four outcomes based on symptoms and total motion restriction, the latter is calculated by the missing degrees to the average elbow flexion and extension ranges (Table). In both cases, the outcomes were excellent.^{1,5,6}

The main complications of elbow dislocations in children are movement restriction, heterotopic ossifications, and untreated fractures. To reduce these complications, the elbow is immobilized during the first two weeks, then functional therapy is initiated to ensure early mobilization. Physical therapy is essential to initiate passive mobilization after removing the splint from the second week after the closed reduction.^{1,10}

Table 1. Roberts Criteria

Outcome	Symptoms	Flexion-extension deficit (°)
Excellent	None	None
Fair	Mild	Deficit under 10°
Adequate	Moderate	Range between 10° and 30°
Poor	Severe	Deficit greater than 30°

In: Murphy RF, et al. Early Outcomes of Pediatric Elbow Dislocation Risk Factors Associated With Morbidity. *J Pediatr Orthop*. 2017; 37 (7).

CONCLUSION

In cases of elbow dislocation in children, it is suggested to rule out associated lesions before and after reduction. A stability test is performed under anesthesia and then the joint is immobilized for a maximum of two or three weeks. Excellent functional outcomes are achieved with closed reduction and short immobilization in these cases.

Conflict of interest: The authors declare they do not have any conflict of interest.

A. F. Reyes Arceo ORCID ID: <https://orcid.org/0000-0001-8569-1899>

M. A. Fuentes González ORCID ID: <https://orcid.org/0000-0003-4156-6927>

REFERENCES

- Little KJ. Elbow fractures and dislocations. *Orthop Clin North Am* 2014;45(3):327-40. <https://doi.org/10.1016/j.ocl.2014.03.004>
- Guzmán R, Rincón DCJ. Reporte de caso y revisión de la literatura: luxofractura de codo en niños. *Acta Ortop Mex* 2015;29(2):118-22. PMID: 27012086
- Lieber J, Zundel SM, Luithle T, Fuchs J, Kirschner HJ. Acute traumatic posterior elbow dislocation in children. *J Pediatr Orthop Part B* 2012;21(5):474-81. <https://doi.org/10.1097/BPB.0b013e328354b08c>
- Rodríguez Martín J, Pretell Mazzini J. Posterolateral elbow dislocation with entrapment of the medial epicondyle in children: a case report. *Cases J* 2009;2(1):6. <https://doi.org/10.1186/1757-1626-0002-0000006603>
- Schubert I, Strohm PC, Zwingmann J. Einfache Ellenbogenluxationen beim Kind. *Unfallchirurg* 2019;122(5):364-8. <https://doi.org/10.1007/s00113-018-0576-6>
- Murphy RF, Vuillermin C, Naqvi M, Miller PE, Bae DS, Shore BJ. Early outcomes of pediatric elbow dislocation—Risk factors associated with morbidity. *J Pediatr Orthop* 2017;37(7):440-6. <https://doi.org/10.1097/BPO.0000000000000676>
- Wilkins KE. Fractures and dislocations of the elbow region. In: Rockwood CA, Wilkins KE, King RE (eds). *Fractures in children*. 4th ed. Philadelphia: Lippincott-Raven; 1996:653-887.
- Sofu H, Gursu S, Camurcu Y, Yildirim T, Sahin V. Pure elbow dislocation in the paediatric age group. *Int Orthop* 2016;40(3):541-5. <https://doi.org/10.1007/s00264-015-3074-2>
- Rasool MN. Dislocations of the elbow in children. *J Bone Joint Surg Br* 2004;86(7):1050-8. <https://doi.org/10.1302/0301-620x.86b7.14505>
- Hyvönen H, Korhonen L, Hannonen J, Serlo W, Sinikumpu J-J. Recent trends in children's elbow dislocation with or without a concomitant fracture. *BMC Musculoskelet Disord* 2019;20(1):294. <https://doi.org/10.1186/s12891-019-2651-8>
- Polat G, Karademir G, Akgül T, Hüseyin Ceylan H. Pediatric open elbow dislocation without fracture: A case report. *Int J Surg Case Rep* 2014;5:1064-7. <https://doi.org/10.1016/j.ijscr.2014.10.086>