

# Capsulodesis. “Liberata” Surgery Origin story. A grandfather and grandson’s account on a quiet afternoon

**Eduardo A. Zancolli, Eduardo P. Zancolli\***

\*Upper Limb Sector, Fundación Favaloro (Buenos Aires, Argentina)

In 1956, a plastic surgeon from Porto Alegre (Brazil) came to Buenos Aires. His medical history included a median and ulnar nerve injury, which progressed into a claw deformity (flexible) of the four fingers. The doctor was on his way to Europe, where he was to seek consult in England. During his stopover in Buenos Aires, the Brazilian doctor visited the former Sanatorio Finochietto, because Dr. Héctor Marino had advised him to attend a surgery performed by Dr. Eduardo A. Zancolli.

After that surgery, the Brazilian doctor decided to cancel his European travel plans and to undergo surgery in Buenos Aires with Dr. Zancolli.

At the time, Dr. Zancolli used the Stiles-Bunnell procedure for treating the ulnar claw deformity.<sup>1</sup> This procedure, which was used in that surgery, consists of retrieving the middle finger superficialis tendon into the palm after distal resection and splitting it into four slips. Each slip is then passed through the lumbrical canal into the intermetacarpal ligament, where it is inserted on the lateral digital band.

Dr. Zancolli recounts getting back home that afternoon and sitting down on a couch to review the surgical procedure. He was not content with having spent hours passing tendons to reconstruct the claw. The procedure was indeed complex. Based on the personal principle that when faced with “different surgical procedures that produce the same outcome, the simplest is the best,” Dr. Zancolli pondered in search of an easier way to correct the claw. He tells that while searching he remembered something he had read in a book from Emmanuel Kaplan.<sup>2</sup> “The congenital presentation of contracture in metacarpophalangeal flexion in the setting of ulnar paralysis prevents claw deformity development and enables the extensor tendon to extend the interphalangeal joints.”

Based on this memory, Dr. Zancolli considers the possibility to reproduce surgically that which occurs congenitally for the claw not to develop, in other words, a *metacarpophalangeal volar capsuloplasty*, and so preventing joint hyperextension and enabling the extrinsic extensor mechanism to extend the fingers.

While studying Medicine in Buenos Aires, Dr. Zancolli lived in a student hostel where *Liberata*, the hostel cook, had an ulnar paralysis with clawing of the digits. The day after the Brazilian surgery, Dr. Zancolli went to his former student hostel and found *Liberata* doing the dishes of the students’ lunch. The doctor examined her and verified that *Liberata* was eligible for volar capsulodesis, which would improve the biomechanics of her fingers. He convinced her, not without difficulty, to undergo surgery. That same afternoon, in Buenos Aires Hospital del Quemado, where Dr. Zancolli performed surgery daily, that cook underwent the first volar capsulodesis for ulnar claw deformity. Hence, Dr. Zancolli naming this procedure as “Liberata” Surgery.

In October 1957, Dr. Zancolli published in the Journal of Bone and Joint Surgery his description of volar capsulodesis.<sup>3</sup>

Injuries of the ulnar nerve or of both median and ulnar nerves result in the claw deformity of the fingers. This condition commonly presents with metacarpophalangeal hyperextension and interphalangeal joint flexion due to loss of intrinsic muscle function, which would regularly flex the metacarpophalangeal joint and extend the interphalangeal joints.

Received on July 30<sup>th</sup>, 2020. Accepted after evaluation on July 31<sup>st</sup>, 2020 • EDUARDO A. ZANCOLLI, Prof • pablozancolli@yahoo.com.ar

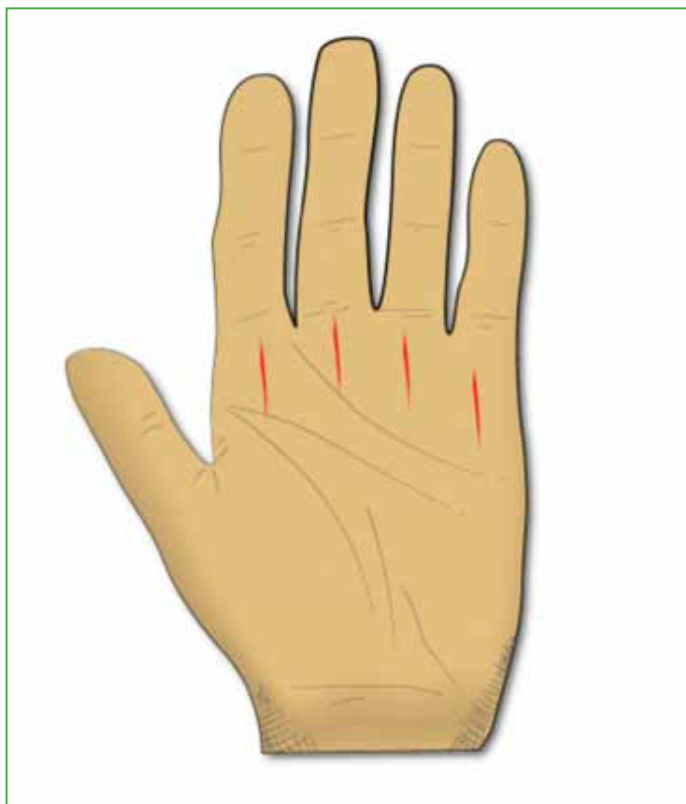 <https://orcid.org/0000-0002-2523-3594>

**How to cite this paper:** Zancolli EA, Zancolli EP. Capsulodesis. “Liberata” Surgery Origin story. A grandfather and grandson’s account on a quiet afternoon. *Rev Asoc Argent Ortop Traumatol* 2020;85(Supl.):45-47. <https://doi.org/10.15417/issn.1852-7434.2020.85.4S.1177>

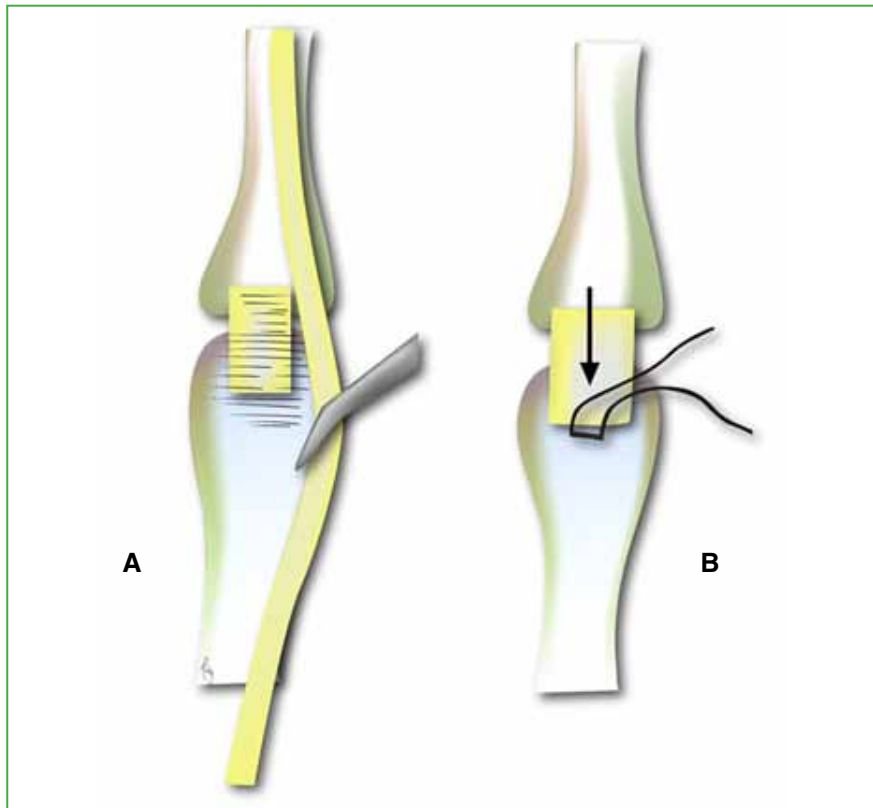
The correction of the claw-hand warrants reducing the hyperextension of the affected metacarpophalangeal joints to restore the extrinsic extensor biomechanics. The available literature provides different procedural descriptions for correcting the ulnar claw deformity, which could be classified into static or dynamic procedures.<sup>4-6</sup> If Bouvier's test is positive, static procedures, such as volar capsulodesis, are indicated.<sup>7</sup>

Dr. Zancolli's capsulodesis is performed through a longitudinal palmar incision at the metacarpophalangeal level (Figure 1). Neurovascular bundles are identified and protected. The A1 pulley is then incised, and the flexor tendons split to expose the volar capsule of the metacarpophalangeal joints (Figure 2A)- A capsuloplasty is then performed which involves designing a distally based capsular flap (Figure 2B). The flap is advanced proximally and attached to the bone to achieve a capsular shortening that will limit the joint extension, resulting in a 20° metacarpophalangeal flexion position. Postoperative management includes finger immobilization in metacarpophalangeal flexion for 30 days, leaving the interphalangeal joints free to move. Active and passive motion of the interphalangeal joints is instituted at postoperative week 2 to prevent flexor tendon adhesions. Following plaster cast removal, patients begin the rehabilitation program.

Through this short story, we share the origin of a surgical technique: the *Liberata Surgery*. A technique that stems from a deep understanding of hand anatomy and biomechanics as well as a constant search for effective and simple solutions.



**Figure 1.** Longitudinal palmar incision at the metacarpophalangeal level.



**Figure 2.** **A.** Volar capsule of the metacarpophalangeal joint identification. **B.** Creating the distally based capsular flap.

Conflict of interests: The authors claim they do not have any conflict of interests.

E. P. Zancolli ORCID: <https://orcid.org/0000-0002-0376-8002>

## REFERENCES

1. Bunnell S. Surgery of the intrinsic muscles of the hand other than those producing opposition of the thumb. *J Bone Joint Surg* 1942;24:1-31.
2. Kaplan EB. *Functional and surgical anatomy of the hand*. Philadelphia: J.B. Lippincott Co.; 1953.
3. Zancolli EA. Claw-hand caused by paralysis of the intrinsic muscles: a simple surgical procedure for its correction. *J Bone Joint Surg Am* 1957;39(5):1076-80. PMID: 13475406
4. Mikhail IK. Bone block operation for claw-hand. *Surg Gynecol Obstet* 1964;118:1077-9. PMID: 14143460
5. Bunnell S. *Surgery of the hand*. Philadelphia: J.B. Lippincott Company; 1944.
6. Riordan DC. Tendon transplantations in median-nerve and ulnar-nerve paralysis. *J Bone Joint Surg Am* 1953;35(2):312-20. PMID: 13052603
7. Bouvier M. Note sur une paralysie partielle des muscles de la main. *Bull Acad Nat Med (Paris)* 1851-1852;18:125-39.