

# Treatment of phalangeal and metacarpal fractures with intramedullary compression screws

Macarena Layús, Pablo Pasetto

Hand and Upper Limb Department, Sanatorio Británico (Santa Fe, Argentina)

## ABSTRACT

**Objective:** To study the clinical and radiological outcomes of patients with extra-articular phalangeal and metacarpal fractures who were treated with minimally invasive internal fixation using retrograde intramedullary compression screws. **Materials and Methods:** Prospective study in patients over 18 years of age treated for simple, transverse or short oblique, extra-articular phalangeal and metacarpal fractures between November 2016 and June 2019. The series included 47 patients and 76 fractures: 28 metacarpal bones (MC), 27 proximal phalanges (PP), 21 middle phalanges (MP). Clinical and functional outcomes were assessed with goniometry, documenting the total active range of motion (TAM). Radiological outcomes were assessed using the criteria proposed by Pun *et al.* All patients completed the Quick DASH questionnaire at last follow-up. **Results:** The average follow-up period was 24.5 months. All study fractures average TAM was 238°, metacarpal TAM was 252°, and phalangeal TAM was 230°. Radiograph evaluation showed fracture consolidation in all cases. Average time taken to return to normal daily activities was 79 days. Average final Quick DASH score was 4.5. There were no complications nor secondary surgeries. **Conclusions:** Minimally invasive internal fixation with retrograde intramedullary compression screw proved to be a highly effective option in the treatment of extra-articular phalangeal and metacarpal fractures.

**Key words:** Fracture, metacarpal, phalanx, screws, intramedullary, compression.

**Level of Evidence:** II

## Tratamiento de fracturas de falanges y metacarpianos con tornillos endomedulares compresivos

## RESUMEN

**Objetivos:** Evaluar los resultados clínicos y radiográficos de pacientes con fracturas extrarticulares de falanges y metacarpianos de la mano, tratados mediante osteosíntesis mínimamente invasiva con tornillos endomedulares compresivos retrógrados. **Materiales y Métodos:** Estudio prospectivo que incluyó a pacientes >18 años con fracturas cerradas transversales u oblicuas cortas, extrarticulares, de falanges y metacarpianos tratadas entre noviembre de 2016 y junio de 2019. La serie estaba integrada por 47 pacientes, con 76 fracturas (28 de metacarpianos, 27 de falange proximal y 21 de falange media). Se evaluaron los resultados clínicos y funcionales con goniometría, registrando el rango de movilidad activa total. La evaluación radiográfica se realizó sobre la base de los criterios establecidos por Pun y cols. Todos los pacientes completaron el cuestionario QuickDASH en el examen final. **Resultados:** El tiempo promedio de seguimiento fue de 24.5 meses. El rango de movilidad activa total promedio fue de 238° para todas las fracturas, 252° para las de metacarpianos y 230° para las de falanges. Se observó la consolidación radiográfica de todas las fracturas. El tiempo promedio de retorno a la actividad habitual fue de 79 días. El resultado final del cuestionario QuickDASH fue 4,5. No hubo complicaciones ni cirugías secundarias. **Conclusiones:** La osteosíntesis mínimamente invasiva con tornillos endomedulares compresivos retrógrados resultó una alternativa eficaz para el tratamiento de fracturas extrarticulares de falanges y metacarpianos.

**Palabras clave:** Fractura; metacarpianos; falanges; tornillos endomedulares, compresivos.

**Nivel de Evidencia:** II

Received on July 30<sup>th</sup>, 2020. Accepted after evaluation on August 2<sup>nd</sup>, 2020 • MACARENA LAYÚS, MD • layusmac@gmail.com  <https://orcid.org/0000-0003-3852-5155>

**How to cite this paper:** Layús M, Pasetto P. Treatment of phalangeal and metacarpal fractures with intramedullary compression screws. *Rev Asoc Argent Ortop Traumatol* 2020;85(3):2-11. <https://doi.org/10.15417/issn.1852-7434.2020.85.4S.1172>

## INTRODUCTION

Phalangeal and metacarpal fractures of the hand are common, and their treatment complexity varies. The goal of both conservative and surgical treatment is to achieve adequate functional recovery of the affected hand, with an acceptable alignment, a stable bone union, and full TAM.<sup>1</sup> Multiple procedures have been described to this end. Stable fractures can be successfully managed with orthoses or early protected mobilization. Unstable fractures treatment mainly depends on the type and location of the fracture line. The most common treatments for extra-articular fractures are percutaneous fixation with Kirschner pins and plate-screw fixation.<sup>2</sup> There is no current consensus on the best treatment modality.

Early mobilization takes on special importance because soft tissue recovery may be more problematic than bone healing.<sup>3</sup>

The use of retrograde intramedullary compression screws in minimally invasive approaches has been described over the past years and represents a reliable option that allows for early mobilization.<sup>2</sup> The articular surface damage in the screw entry site has been studied in and supported by cadaver studies and 3-dimensional computed tomography (3DCT) analyses.<sup>4,5</sup>

The purpose of our study is to report the clinical and radiological outcomes of patients with extra-articular phalangeal and metacarpal fractures who were treated with minimally invasive internal fixation using retrograde intramedullary compression screws.

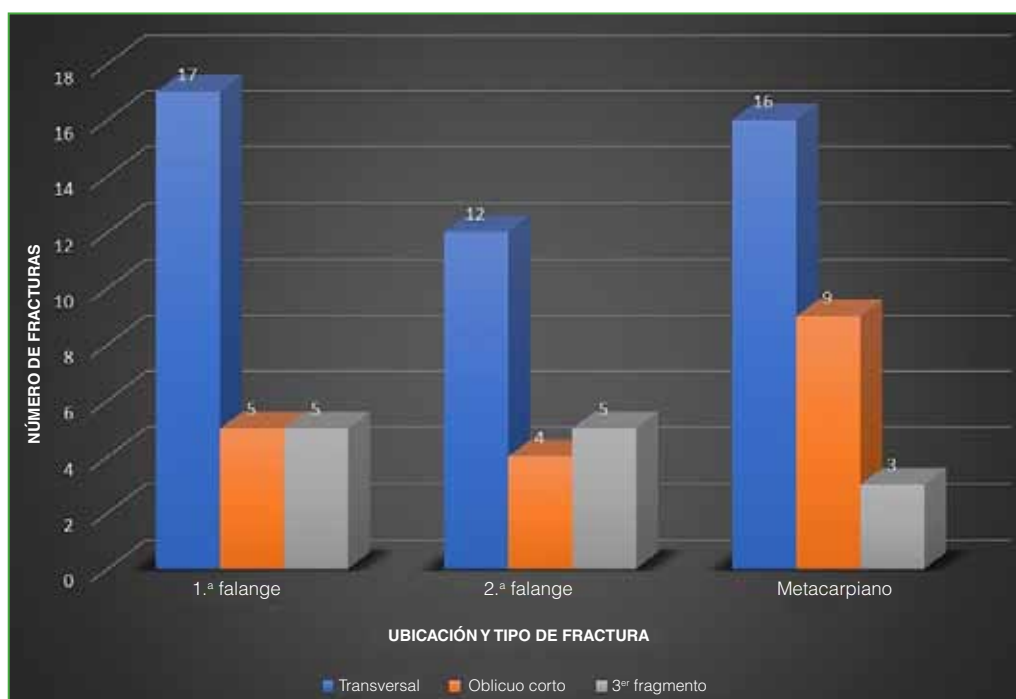
## MATERIALS AND METHODS

We conducted a cohort prospective study between November 2016 and June 2019. All study subjects provided written informed consent.

The inclusion criteria were: 1) patients over 18 years of age; 2) simple, transverse or short oblique fractures involving the MC, PP or MP; 3) no joint involvement; and 4) a follow-up of no less than 12 months.

The exclusion criteria were: 1) articular, spiral or long oblique fractures; 2) previous fractures in the ipsilateral hand; 3) associated injuries (tendon, nerve, vessels, soft tissue).

The series included 47 patients (45 males and 2 females) and 76 fractures: 28 metacarpal bones (MC), 27 proximal phalanges (PP), 21 middle phalanges (MP). There were 45 transverse, 16 short oblique and 15 three-fragment fractures (Figure 1, Table 1).



**Figure 1.** These series patients phalangeal and metacarpal fractures distribution in terms of location and type.

**Table 1.** Series of patients undergoing surgery with intramedullary compression screws

Patients	Age (years)	Number of fractures	Location	Screw (mm)
1	38	1	MP F3	2.3
2	40	2	MP F3-4	2.3
3	20	4	PP F-2-3; MP F3	2.0
4	30	2	PP F2-3	2.0
5	21	2	MC 3-4	3.0
6	39	1	MC 5	3.0
7	49	1	MC 5	3.0 FT
8	20	1	MC 5	3.0 FT
9	31	1	MC 5	3.2
10	29	1	MC 5	3.0
11	24	1	PP; F2	2.0
12	31	2	MC 4-5	2.7
13	28	4	PP F 1-2; MP F 2-3	2.3
14	24	1	PP F 1	2.3
15	18	1	MC 5	3.0
16	32	1	MC 5	3.0 FT
17	34	2	MP F 2-3	2.0
18	35	3	MC 3-4-5	3.0
19	53	1	MC 5	3.0
20	32	3	PP F 3-4-5	2.0
21	22	2	MP F 3-4	2.0
22	64	1	PP F5	2.0
23	34	1	MP F3	2.0
24	26	2	MP F 2-3	2.0
25	25	3	PP F 1-2; MP F 2-3	2.4
26	34	1	MC 5	3.0
27	31	3	PP F 1; MP F 2-3	2.4
28	32	2	PP F 2-3	2.4
29	31	1	MC 5	3
30	34	1	PP F 1	2.4
31	24	1	MP F 2	2
32	48	1	MC 5	3
33	31	3	MC 2; PP F 3-4	3
34	38	2	MC 4-5	3
35	21	1	MC 2	3
36	24	1	MC 5	3
37	20	1	MC 4	3
38	29	2	MC 4-5	3
39	26	3	PP F 2-3-4	2.4
40	22	2	MP F 3-4	2
41	23	1	PP F 1	2.4
42	21	1	MP F 3	2
43	51	1	PP F 5	2.4
44	25	1	MC 5	3
45	25	1	PP F 5	2.4
46	30	1	MC 5	3
47	34	1	PP F 5	2.4

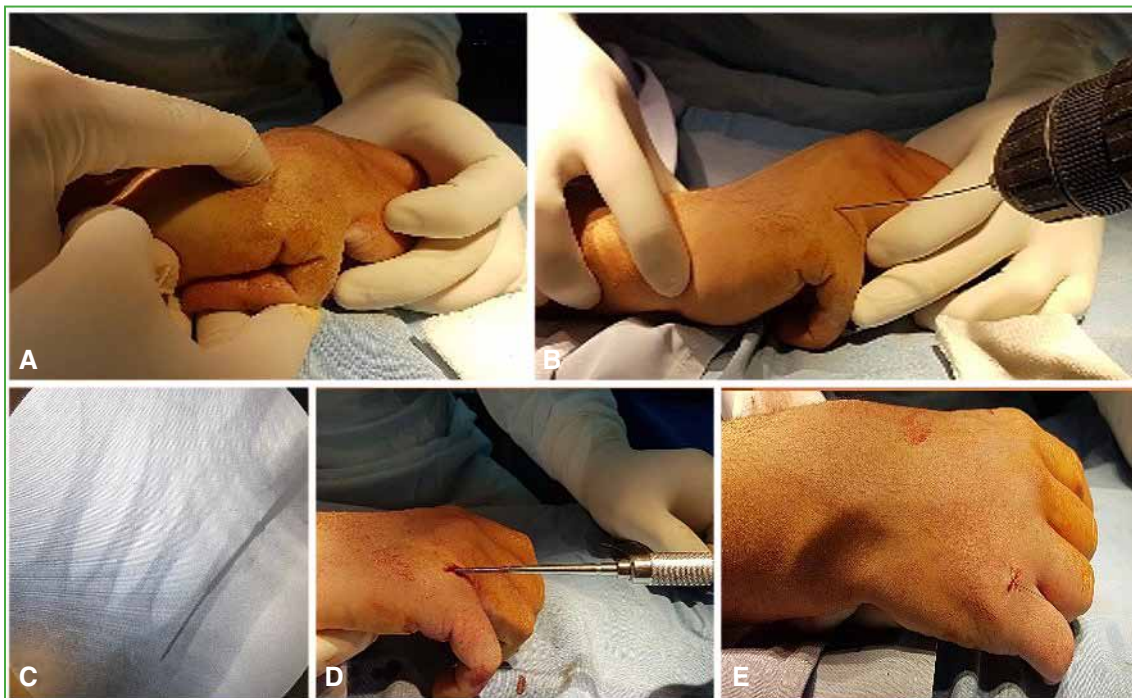
F = finger; MC = metacarpal bone; PP = proximal phalanx; MP = middle phalanx; DP = distal interphalangeal; FT = fully threaded.

Twenty-two patients had multiple fractures in the ipsilateral hand. Patients' average age was 31 years (range, 18-64). Most patients (33) had suffered from occupational accidents. The average time to surgery was 6.7 days after injury (range, 3-20 days). All surgeries were overseen only by 2 surgeons. All patients underwent postoperative immobilization with Zimmer or plaster splints until suture removal (10-12 days) and began with early mobilization supervised by an occupational therapist 5-7 days after surgery. Time to return to daily activities (work/sports) was recorded. Objective assessment protocols consisting of goniometric and radiographic evaluations were established. Goniometric evaluations to assess clinical and functional outcomes considered the TAM: active flexion of the metacarpophalangeal (MCP), proximal interphalangeal (PIP) and distal interphalangeal (DIP) joints minus the extension deficits in these joints.<sup>6</sup> Results were graded into four categories: 150°, excellent; 125° to 149°, good; 90° to 124°, fair; <90°, poor.

Radiographic evaluations consisted of anteroposterior and lateral views taken before surgery, in the immediate postoperative period, and at last follow-up. Results were graded as satisfactory if they met the criteria proposed by Pun *et al.*<sup>7</sup> Phalanx-fracture outcomes with less than 10° angulation in sagittal and coronal planes with no rotation deformity were considered acceptable. Metacarpal-fracture outcomes with up to a 6mm-shortening, with no rotation deformity or head angulation were considered acceptable. For the assessment of the subjective outcome, all patients completed the Quick DASH questionnaire at last follow-up.<sup>8</sup>

### Surgical technique

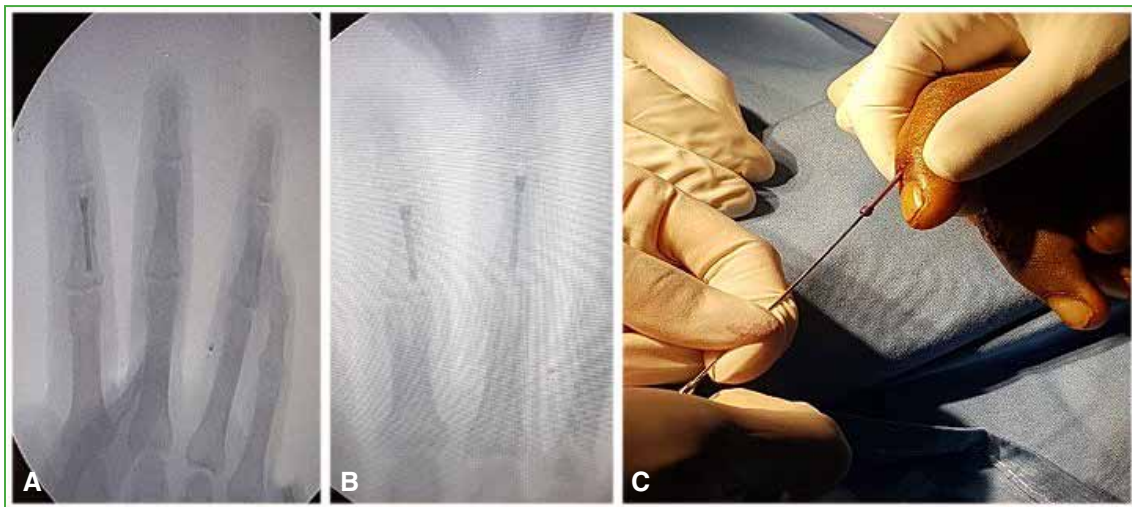
The patient was placed in the supine position, with the upper limb on the operating table. Plexus anesthesia or neurolept-anesthesia associated with nerve block anesthesia was administered. Manual reduction was performed under fluoroscopic monitoring. For MC fractures, the PP was maximally flexed to expose the head of the MC. A 1cm transverse incision was made in that area and the extensor tendon was longitudinally opened at the midline. Under fluoroscopic guidance, a 1.0 mm retrograde Kirschner pin was advanced along the intramedullary canal followed by countersinking and insertion of the 3.0 mm-diameter, double-threaded, cannulated, compression screw using the standard technique, making sure that the screw head was completely beneath the cartilage (Figure 2). The maximum available length for this screw is 40 mm.



**Figure 2.** Minimally invasive technique with retrograde intramedullary compression screw for metacarpal fractures. **A.** Closed reduction maneuver. **B.** Placing of a 1.0 mm intramedullary retrograde pin and reaming of the entry point on the metacarpal head, through a transverse incision and small longitudinal incision on the extensor tendon. **C and D.** Insertion of the cannulated compression screws. **E.** Wound closure.

The procedure for the PP fractures is similar. PIP joint was maximally flexed, a 1 cm transverse incision was made, and the extensor tendon slightly opened to expose the head of the PP. For this procedure, 2.2 mm screws were used. The maximum available length for this screw is 34 mm.

For MP fractures, the incision was made over the DIP joint, with the DIP joint maximally flexed to expose the head of the MP (Figure 3). This procedure also involved 2.2 mm screws.



**Figure 3.** Minimally invasive technique for middle phalanx fractures. **A and B.** Radiographic showing screws in the middle phalanx. **C.** Insertion of the retrograde cannulated screws.

During the compression screw placement, it is important to control adequate rotation by applying lateral compression and to verify lack of scissoring by simulating the patient making a fist.

## RESULTS

The average follow-up period was 24.5 months (range, 12 to 43 months). All study fractures average TAM was 238° (range, 110°-280°), metacarpal TAM was 253° (range, 205°-280°), and phalangeal TAM was 229° (range, 110°-280°). The average time taken to return to normal daily activities was 79 days (range, 21 to 120 days). At final evaluation, all fractures presented satisfactory radiographic evolution. Average final Quick DASH score was 4.5 (range, 0 to 5). We complications were recorded. No patient required a secondary surgery (Tables 2 and 3). To illustrate these procedures, we present case images of a phalanx fracture case (Figure 4) and a metacarpal fracture case (Figure 5).

## DISCUSSION

Herbert and Fisher popularized the use of cannulated headless compression screws, mainly for the stabilization of scaphoid fractures.<sup>9</sup>

Over the past years, several papers have reported their use for the treatment of extra-articular phalangeal and metacarpal fractures.<sup>2,10,11</sup>

Del Piñal *et al.* described the use of these screws for the fixation of extra-articular fractures of the phalanges and metacarpals using a retrograde minimally invasive approach. They highlighted as its main advantage its potential to achieve a stable fixation that allows for early mobilization, thus preventing the MCP and interphalangeal joint stiffness that commonly occur following other treatments.<sup>2</sup>

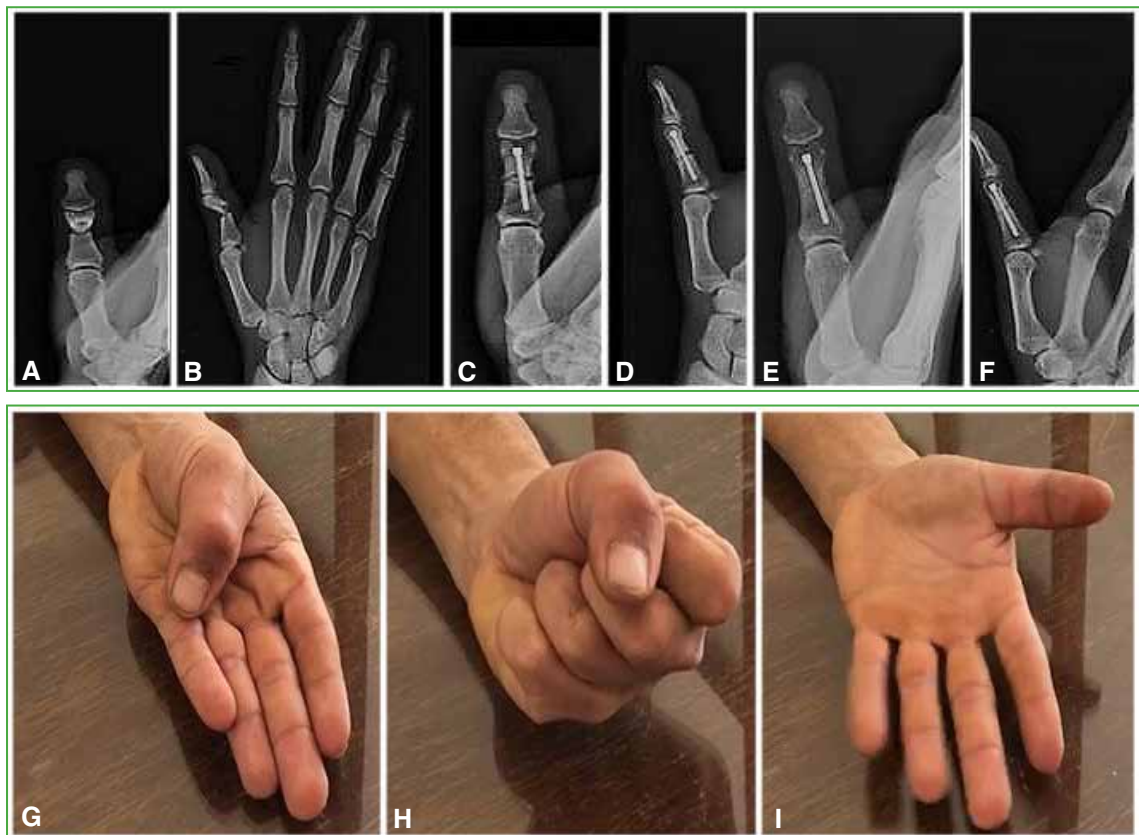
**Table 2.** Series results

Patient	Return to daily activities (days)	Quick DASH questionnaire	Follow-up (months)
1	92	5	43
2	95	4	41
3	115	5	33
4	90	4	33
5	95	5	33
6	86	5	32
7	21	0	32
8	35	5	30
9	90	4	30
10	95	5	30
11	85	4	29
12	60	5	29
13	94	4	28
14	67	5	28
15	55	4	27
16	68	5	27
17	95	5	27
18	70	5	26
19	67	5	26
20	95	4	26
21	95	5	26
22	90	5	26
23	55	5	25
24	105	4	25
25	85	5	25
26	55	4	25
27	95	5	25
28	90	5	25
29	67	4	23
30	70	5	22
31	77	4	21
32	65	4	20
33	90	5	18
34	72	5	18
35	69	5	16
36	65	5	16
37	70	5	15
38	75	4	15
39	98	4	15
40	78	5	14
41	90	5	14
42	80	5	14
43	75	5	13
44	68	5	13
45	75	4	13
46	70	5	12
47	82	4	12



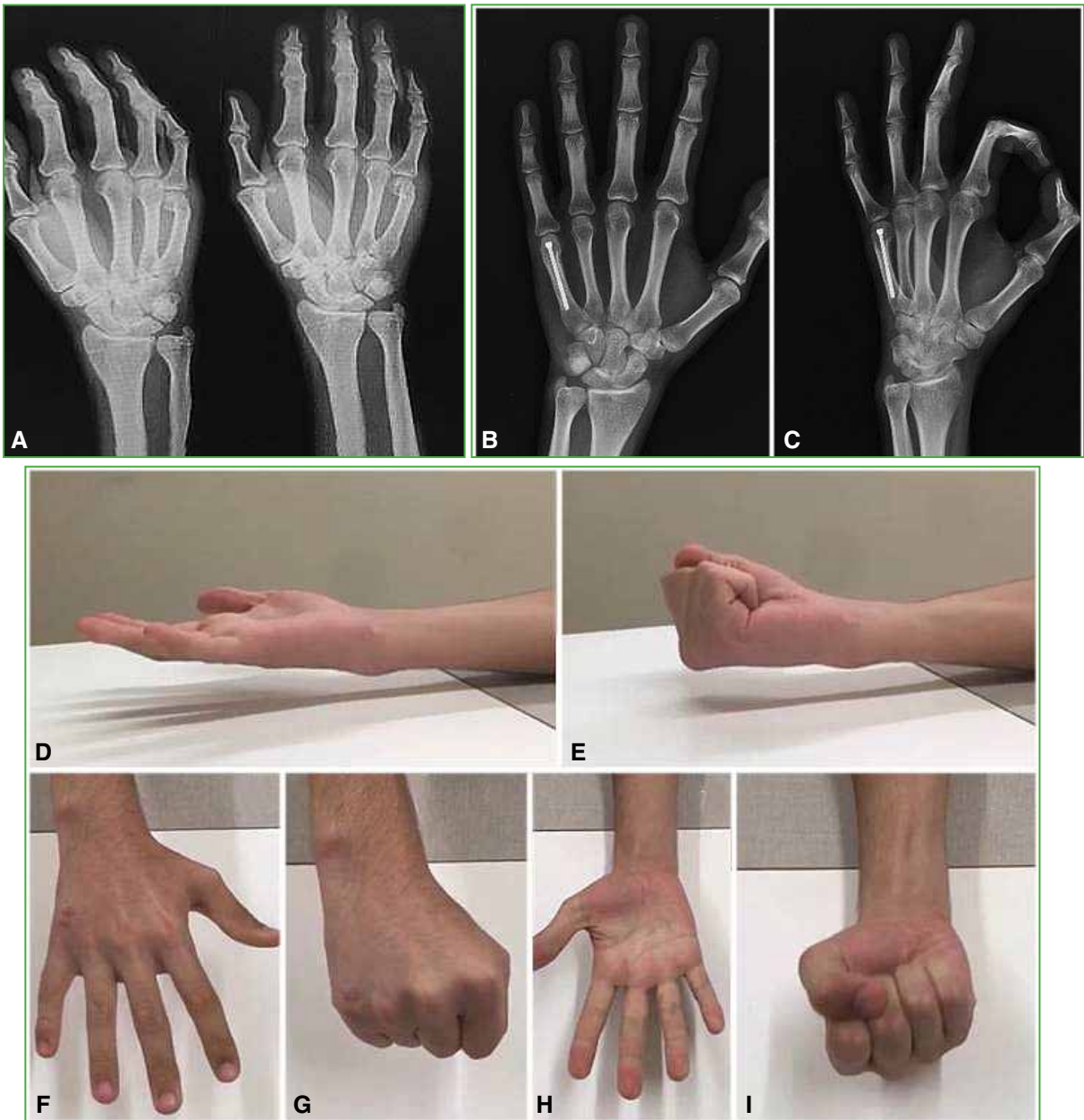
**Table 3.** Total active range of motion results

Location	Total active range of motion (average)	Range
All fractures	238°	110°-280°
Metacarpal bones	253°	205°-280°
Phalanges	229°	110°-280°



**Figure 4.** Patient with a thumb proximal phalanx fracture. **A and B.** Preoperative lateral and anteroposterior radiographs. **C and D.** One-month follow-up radiographic study. **E and F.** Three-month follow-up control. **G-I.** Range of motion 3 months after surgery.

Plate-screw fixation provides excellent stability but requires greater soft tissue dissection, periosteal stripping, which commonly results in tendon and scar adhesions.<sup>12,13</sup> In a 129-patient series that included 157 metacarpal fractures treated with open reduction and plate-screw fixation, Fusetti *et al.* reported complications in more than a third of the patients, including delayed union, tendon and soft tissue adhesions, complex regional pain syndrome, and deep infection.<sup>14</sup>



**Figure 5.** Patient with 5th metacarpal bone fracture. **A.** Preoperative anteroposterior and oblique radiographs. **B and C.** 45-day follow-up radiographic study. **D-I.** Functional outcome at 60-day postoperative follow-up.

Although percutaneous fixation approaches with Kirschner wire prevent fracture site exposure and soft tissue dissection, they require 3 to 4 weeks of postoperative immobilization to minimize the risk of superficial and deep pin infections that may result in early Kirschner pin removal and additional procedures.<sup>11</sup> In their series of 189 patients with hand and wrist fractures who underwent percutaneous pinning, Hsu *et al.* reported a 14% minor complication rate (superficial infection, edema, pin migration) and a 3% major complication rate (nonunion, deep infection).<sup>15</sup>



Berg *et al.* published a quantitative 3DCT analysis to study the articular entry point, surface area, and subchondral volumes used during fixation of metacarpal neck fractures using retrograde intramedullary compression screws. They suggest that direct visualization of the entry point may eliminate the need for multiple attempts to achieve said approach, which is common in percutaneous pinning procedures. They further describe that the dorsal entry point is aligned with the medullary canal and prevents the engagement of the center of the articular base through most of the sagittal plane arc. When these criteria are met, metacarpal head surface areas and subchondral volumes occupied by compression screws are minimum.<sup>5</sup>

In their cadaver study, Borbas *et al.* reported that the damage to the articular surface caused at the screw entry point in the MTF and IFP joints is less than the previously reported values: 8.5% (3.0 mm screw) and 4.6% (2.2 mm screw).<sup>4</sup>

To the best of our knowledge, there are no papers on the long-term impact of the screw entry point on the articular surface.

These study strengths were its prospective design, technique reproducibility, the series number of patients, and the study disease homogeneity. The limitations of this study include a lack of sample randomization and a limited follow-up period for the study of potential joint osteoarthritic changes related to the screw entry point. A new study on these same series patients using CT imaging of the articular surfaces may provide insights into the understanding of this articular condition.

## CONCLUSIONS

Minimally invasive internal fixation with retrograde intramedullary compression screw proved to be a highly effective option in the treatment of extra-articular phalangeal and metacarpal fractures.

---

Conflict of interests: Authors claim they do not have any conflict of interest.

P. Pasetto ORCID: <https://orcid.org/0000-0001-5193-0898>

## REFERENCES

1. Kozin SH, Thoder JJ, Lieberman G. Operative treatment of metacarpal and phalangeal shaft fractures. *J Am Acad Orthop Surg* 2000;8(2):111-21. <https://doi.org/10.5435/00124635-200003000-00005>
2. Del Piñal F, Moraleta E, Ruas JS, de Piero GH, Cerezal L. Minimally invasive fixation of fractures of the phalanges and metacarpals with intramedullary cannulated headless compression screws. *J Hand Surg Am* 2015;40:692-700. <https://doi.org/10.1016/j.jhssa.2014.11.023>
3. Meals C, Meals R. Hand fractures: A review of current treatment strategies. *J Hand Surg Am* 2013;38(5):1021-31. <https://doi.org/10.1016/j.jhssa.2013.02.017>
4. Borbas P, Dreu M, Poggetti A, Calcagni M, Giesen T. Treatment of proximal phalangeal fractures with an antegrade intramedullary screw: a cadaver study. *J Hand Surg Eur* 2016;41(7):683-7. <https://doi.org/10.1177/1753193416641319>
5. Berg P, Mudgal C, Leibman M, Belsky M, Ruchelsman D. Quantitative 3-dimensional CT analyses of intramedullary headless screw fixation for metacarpal neck fractures. *J Hand Surg Am* 2013;38(2):322-30. <https://doi.org/10.1016/j.jhssa.2012.09.029>
6. American Society for Surgery of the Hand. *The hand, examination and diagnosis*. 3<sup>rd</sup> ed. New York: Churchill Livingstone; 1990.
7. Pun W, Chow S, So Y, Luk K, Ip F, Chan K, et al. A prospective study on 284 digital fractures of the hand. *J Hand Surg Am* 1989;14(3):474-81. [https://doi.org/10.1016/s0363-5023\(89\)80006-1](https://doi.org/10.1016/s0363-5023(89)80006-1)

8. Beaton DE, Wright JG, Katz JN, Upper Extremity Collaborative Group. Development of the QuickDASH: comparison of three item-reduction approaches. *J Bone Joint Surg Am* 2005;87(5):1038-46. <https://doi.org/10.2106/JBJS.D.02060>
9. Herbert TJ, Fisher WE. Management of the fractured scaphoid using a new bone screw. *J Bone Joint Surg Br* 1984;66(1):114-23. PMID: 6693468
10. Boulton CL, Salzler M, Mudgal CS. Intramedullary cannulated headless screw fixation of a comminuted subcapital metacarpal fracture: case report. *J Hand Surg Am* 2010;35(8):1260-3. <https://doi.org/10.1016/j.jhsa.2010.04.032>
11. Ruchelsman DE, Puri S, Feinberg-Zadek N, Leibman MI, Belsky MR. Clinical outcomes of limited-open retrograde intramedullary headless screw fixation of metacarpal fractures. *J Hand Surg Am* 2014;39(12):2390-5. <https://doi.org/10.1016/j.jhsa.2014.08.016>
12. Ozer K, Gillani S, Williams A, Peterson S, Morgan S. Comparison of intramedullary nailing versus plate-screw fixation of extra-articular metacarpal fractures. *J Hand Surg Am* 2008;33(10):1724-31. <https://doi.org/10.1016/j.jhsa.2008.07.011>
13. Ouellette EA, Freeland AE. Use of the minicondylar plate in metacarpal and phalangeal fractures. *Clin Orthop Relat Res* 1996;327:38-46. <https://doi.org/10.1097/00003086-199606000-00007>
14. Fusetti C, Meyer H, Borisch N, Stern R, Della Santa D, Papaloizos M. Complications of plate fixation in metacarpal fractures. *J Trauma* 2002;52(3):535-9. <https://doi.org/10.1097/00005373-200203000-00019>
15. Hsu L, Schwartz E, Kalainov D, Chen F, Makowiec R. Complications of K-wire fixation in procedures involving the hand and wrist. *J Hand Surg Am* 2011;36(4):610-6. <https://doi.org/10.1016/j.jhsa.2011.01.023>