

# Versatility of the Tibia Long Retrograde Intramedullary Nail for Tibiototalcalcaneal Arthrodesis in Patients with Associated Lesions in the Same Segment

Marisol Alberti, Guido Carabelli, Jonathan Verbner, Danilo Taype Zamboni, Jorge D. Barla, Carlos F. Sancineto

Trauma Sector, Institute of Orthopedics and Traumatology "Prof. Dr. Carlos E. Ottolenghi", Hospital Italiano de Buenos Aires (Buenos Aires, Argentina).

## ABSTRACT

**Background:** The joint condition that leads to the need for a tibiocalcaneal arthrodesis may be accompanied by a second injury in the same bone segment, and design nails for arthrodesis are not of adequate length to cover both injuries. We have not found therapeutic options for this type of injury in the literature. **Objective:** To present a series of cases where a single tibia nail (antegrade placement) was used retrogradely, with the dual objective of performing a tibiotalcalcaneal arthrodesis added to the treatment of an associated injury in the same surgical stage. **Materials and methods:** We retrospectively evaluated a group of 12 patients who required a tibiotalcalcaneal arthrodesis as well as to simultaneously resolve a local secondary defect from September 2009 to June 2019. The average age was 43.7 (27-61) years, and the global follow-up was 43.9 months. **Results:** All patients achieved a tibiocalcaneal arthrodesis confirmed in antero-posterior and lateral radiographs, and 83.3% of the patients recovered their bone stock completely. **Conclusion:** Faced with the lack of osteosynthesis in the market to resolve associated pathologies in the same patient, we propose the use of a long tibial intramedullary nail placed in a retrograde manner as a treatment option since it has proven to be efficient in achieving tibiocalcaneal arthrodesis. In addition, it could be used as a rail for bone lengthening and transport, and as stabilization to treat simultaneous injuries.

**Keywords:** Tibiotalcalcaneal arthrodesis; bone lengthening; bone transport; retrograde nail; tibial fracture.

**Level of Evidence:** IV

## Versatilidad del clavo endomedular retrógrado largo de tibia para artrodesis tibio-talo-calcánea en pacientes con lesiones asociadas en el mismo segmento

## RESUMEN

**Introducción:** La afección articular que lleva a la necesidad de una artrodesis tibio-calcánea puede estar acompañada de una segunda lesión en el mismo segmento óseo, y los clavos de diseño para artrodesis no tienen la longitud adecuada para cubrir ambas lesiones. No hallamos opciones terapéuticas para este tipo de lesiones en la bibliografía. **Objetivo:** Presentar una serie de casos en los que se utilizó un único clavo de tibia (de colocación anterógrada) de forma retrógrada, con el doble objetivo de efectuar una artrodesis tibio-talo-calcánea, sumada al tratamiento de una lesión asociada en un mismo tiempo quirúrgico. **Materiales y Métodos:** Se evaluó, en forma retrospectiva, desde septiembre de 2009 hasta junio de 2019, a un grupo de 12 pacientes que requirió una artrodesis tibio-talo-calcánea sumada a la necesidad de resolver simultáneamente un defecto secundario local. La edad promedio fue de 43.7 años, y el seguimiento global fue de 43.9 meses. **Resultados:** Todos los pacientes lograron una artrodesis tibio-calcánea constatada en radiografías de frente y de perfil, y el 83,3% recuperó el capital óseo de manera completa. **Conclusión:** Ante la ausencia en el mercado de osteosíntesis para resolver las patologías asociadas en un mismo paciente, proponemos el uso del clavo endomedular largo de tibia colocado de manera retrógrada como una opción de tratamiento, porque se ha demostrado que es eficaz para lograr la artrodesis tibio-calcánea. Además, se lo pudo utilizar como riel en el alargamiento y el transporte óseo, y como estabilización para tratar lesiones simultáneas.

**Palabras clave:** Artrodesis tibio-talo-calcánea; alargamiento óseo; transporte óseo; clavo endomedular retrógrado; fractura de tibia.

**Nivel de Evidencia:** IV

Received on July 13<sup>th</sup>, 2020. Accepted after evaluation on January 8<sup>th</sup>, 2021 • MARISOL ALBERTI, MD • sol\_alb@hotmail.com  <https://orcid.org/0000-0002-2266-8138>

**How to cite this article:** Alberti M, Carabelli G, Verbner J, Taype Zamboni D, Barla JD, Sancineto CF. Versatility of the Tibia Long Retrograde Intramedullary Nail for Tibiotalcalcaneal Arthrodesis in Patients with Associated Lesions in the Same Segment *Rev Asoc Argent Ortop Traumatol* 2021;86(3):XXXX. <https://doi.org/10.15417/issn.1852-7434.2021.86.3.1159>

## INTRODUCTION

Tibiototalcaneal arthrodesis is a procedure indicated for patients with post-traumatic osteoarthritis, rheumatoid arthritis, sequelae of infections, neuromuscular symptoms and ankle arthroplasty failure.<sup>1</sup> Its goal is to achieve a solid and painless fusion in a biomechanically stable position that allows the person to ambulate unaided.<sup>2</sup> For this, retrograde intramedullary fixation is the implant of choice.<sup>3</sup>

The procedure described refers to the tibiototalcaneal fixation in the context of a lesion at this level, an element that motivates the use of nails of adequate lengths for this purpose; however, the joint involvement may be accompanied by an extension or a second bone lesion at the diaphyseal level of the same bone segment, and design nails for arthrodesis are not of adequate length to cover both lesions; therefore, it is necessary to add an implant or apply a tactic that allows a single osteosynthesis to be adapted for the management of added injuries.

We have not found therapeutic options for this type of injury in the literature, so we have implemented a strategy that is tailored to the needs of the possible combination of injuries that the patient may present. For this reason, we present a series of cases in which a traditional antegrade tibial nail was used, placed in a retrograde manner, with the main objective of performing a tibiototalcaneal arthrodesis adding the function of treating associated injuries with a single osteosynthesis as a secondary objective.

At the same time, we tried to outline a way to classify the possible indications.

## MATERIALS AND METHODS

Our case series was evaluated retrospectively from September 2009 to June 2019. We included patients >18 years of age with an indication for tibiototalcaneal arthrodesis, who presented a concomitant condition in said bone segment where the use of a conventional-length arthrodesis nail was not possible. They also had to have complete medical records. Those who did not meet any of these three conditions were excluded.

Using the data provided by the electronic medical record of our institution, demographic variables, the type of initial trauma and the number of previous surgeries upon admission to our institution were evaluated.

Likewise, the length of the bone defect, if it existed, and the correction achieved at the end of the treatment were evaluated, as well as the presence or absence of concomitant infection and the type of germ, if applicable. After collecting the information, a group of 12 patients was formed, who were classified according to bone defects and therapeutic needs, namely:

1. Limb with conservation of segment length
  - A. With segmental defect
  - B. Without segmental defect
2. Limb that does not preserve segment length

As an example, the treatment of each of the possible sequelae was described, showing the versatility of the technique according to the problem in each case.

### Problem 1.A. Limb with length conservation plus segmental defect

This group was made up of five patients with a bone stock deficit in the tibia, whose main reconstructive strategy, in most cases, was bone transport.

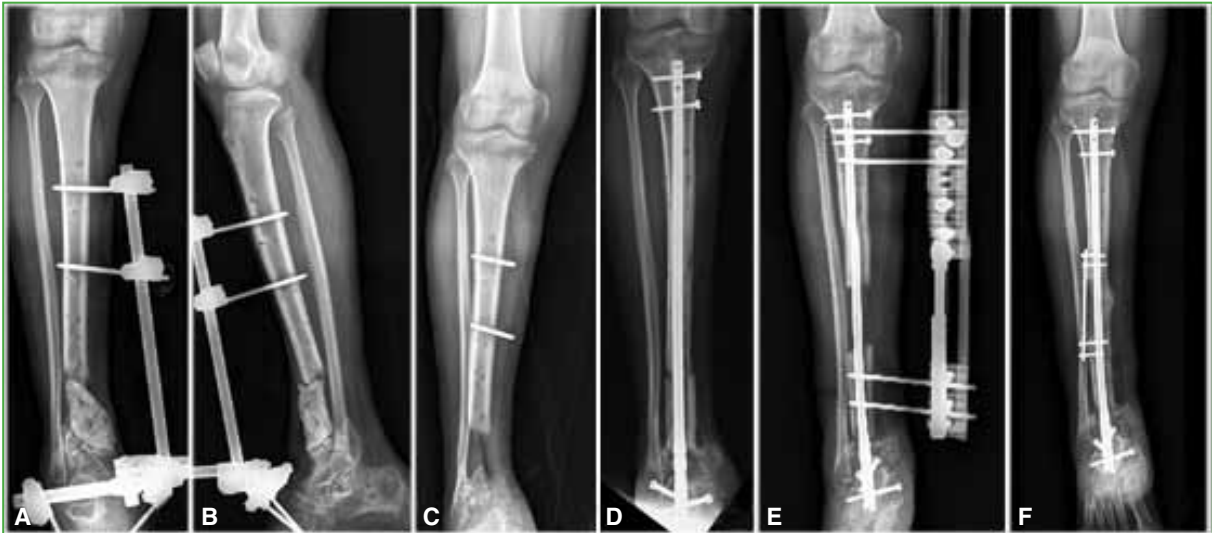In these situations, the same intramedullary nail was used for the tibiototalcaneal arthrodesis and as a mechanical axis to guide the transported bone segment for bone reconstruction.

A 35-year-old man with a history of exposed distal tibia fracture with joint involvement and bone loss. He was treated at another center and progressed to an infected nonunion (Figure 1A-B).

Upon entering our institution, he underwent debridement (Figure 1C), then a cement spacer with antibiotics was placed and stabilized with a retrograde tibia nail at the tibio-talo-calcaneus level (Figure 1D).

Faced with a favorable evolution and after control of the local septic process, the defect was reconstructed with bone transport on a nail (Figure 1E).

After transporting, it was decided to protect the area with plating and screws (Figure 1F).

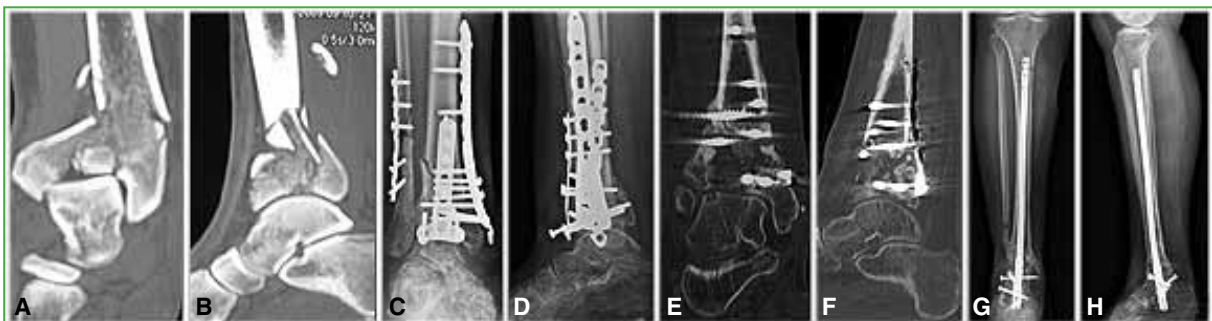


**Figure 1.** **A and B.** Anteroposterior and lateral leg radiographs. The focus of nonunion is observed in the distal tibia. **C.** Anteroposterior leg radiograph after initial debridement. The bone stock deficit is observed. **D.** Anteroposterior leg radiograph after the placement of an antibiotic-loaded cement spacer and the stabilization with a retrograde tibia nail at the tibioalcanal level. **E.** Anteroposterior leg radiograph. The reconstruction of the defect with bone transport on a nail is observed. **F.** After transporting, it was decided to protect the area with a plate and screws.

### Problem 1.B. Limb with length conservation and without segmental defect

This group included two patients with two or more injuries to the tibia, who preserved limb length and did not have a segmental bone defect.

A 46-year-old woman with a right pilon fracture associated with a fibula fracture (**Figure 2A-B**). Reduction and osteosynthesis were carried out. The postoperative outcome is shown in **Figure 2C-D**. Four months after surgery, she suffered from a surgical site infection, requiring multiple cleanings over four months. In a tomographic control (**Figure 2E-F**), a joint with important degenerative changes was observed; therefore, it was decided to remove the osteosynthesis. At the time of reimplantation, due to post-traumatic osteoarthritis and an infectious history, it was decided to perform retrograde tibiototalcaneal arthrodesis with a nail coated with antibiotic-loaded cement. The postoperative outcome is shown in **Figure 2G-H**.



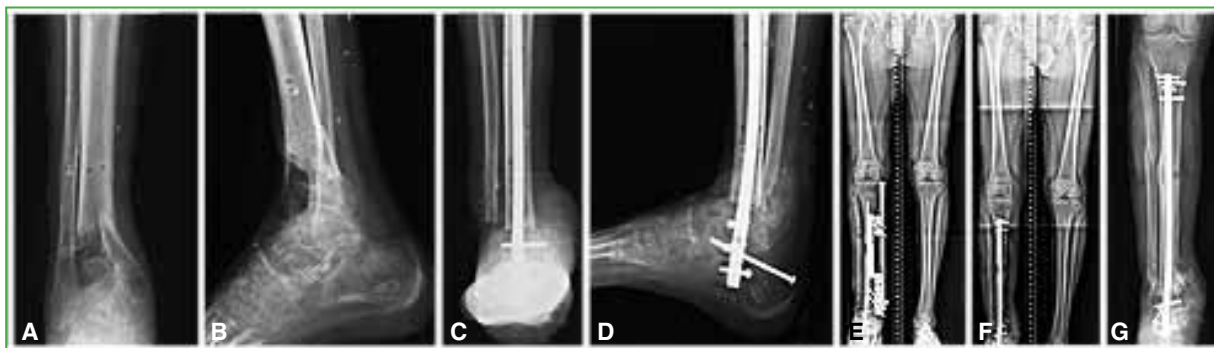**Figure 2.** Ankle computed tomography, coronal (**A**) and sagittal (**B**) planes. A 46-year-old woman with a right pilon fracture associated with a fibula fracture. **C and D.** Anteroposterior ankle radiographs after reduction and osteosynthesis. **E and F.** Ankle computed tomography, coronal and sagittal planes. Follow-up after the treatment of the focus of infection. Important degenerative joint changes are detected. **G and H.** Anteroposterior and lateral leg radiographs, after a retrograde tibioalcanal arthrodesis using a nail coated with antibiotic-loaded cement.

### Problem 2.B. Limb that does not preserve the length of the segment plus segmental bone defect

This group comprised five patients who had a length discrepancy due to a bone defect in the affected lower limb. In patients with defects that could not be compensated for with enhancement, callotasis lengthening was performed on the same retrograde intramedullary nail that was used for ankle arthrodesis.

A 59-year-old man with a history of peripheral vascular disease, who suffers an open pilon fracture. He was initially treated in another center, required multiple bone and soft tissue surgical procedures, and progressed with loss of bone stock at the joint level (Figure 3A-B) and the failure of two covering flaps. At that time, an infrapatellar amputation was indicated, which was rejected by the patient.

He was referred to our institution with a soft tissue defect on the lateral aspect of the right ankle, in addition to long-standing bone and joint exposure. Reconstruction was performed through a bone resection of the tibia and distal fibula with acute shortening of the limb and tibiototalcalcaneal arthrodesis with a long nail. (Figure 3C-D). Given the improvement of the soft tissues, we proceeded with callotasis lengthening according to the technique (Figure 3E). The final outcome can be observed in Figure 3F-G.



**Figure 3.** **A and B.** Anteroposterior and lateral ankle radiographs. The sequela of an open fracture of the tibial pilon is observed which, after multiple surgeries, evolved with loss of joint bone stock. **C and D.** Anteroposterior and lateral ankle radiographs, after reconstruction through a bone resection of the tibia and distal fibula with acute shortening of the limb and tibiototalcalcaneal arthrodesis with a long nail. **E.** Scanogram of both lower limbs at the beginning of the lengthening due to callotasis according to the technique. **F.** Scanogram of both lower limbs. **G.** Anteroposterior leg radiograph. Final outcome.

## FINDINGS

A series of 12 patients (8 men and 4 women) was presented. The average age was 43.7 years (range 27-61); the average age of the patients in group 1 was 40.8 years (range 27-61) and the average age of the patients in group 2 was 47.6 years (range 31-59).

The global follow-up was 43.9 months from September 2009 to June 2019.

Regarding the initial trauma, the exposed fractures of the tibia and fibula and the pilon fractures were the most frequent (4 patients each), followed by the exposed fracture of the femur, ankle fracture, isolated fracture of the fibula and exposed talus dislocation (1 patient each).

Regarding the number of surgeries before entering our institution, three patients did not have surgeries or had up to two previous interventions, the remaining nine patients had more than two interventions in other centers.

Regarding the analysis of the length of the bone defects in centimeters, we observed that, in the group of patients with conservation of limb length, in those who had a segmental defect (subgroup A), the average defect was 6.02 cm. Subgroup B did not have an associated segmental bone defect. Finally, patients without preservation of limb length had an average shortening of 4.07 cm.

The final correction achieved in patients without preservation of limb length was complete in two of the five cases, a residual shortening of 2 cm in one patient and 4 cm in the remaining two.

As seen in **Table 1**, in most cases, the first step was the infectological staging of the patients. 91.6% suffered a concomitant infection, and the most frequent germ was *Staphylococcus aureus* (**Table 2**). For this reason, all the nails used for arthrodesis were coated with antibiotic cement. In addition, all the patients had a multidisciplinary follow-up together with the doctors of the Infectious Diseases Service who determined the indicated antibiotic, according to the results of the cultures. The patients underwent intravenous or oral treatment for at least 6 weeks, depending on the microorganism isolated in surgery, and were periodically monitored with laboratory tests that included white blood cell count, erythrocyte sedimentation and C-reactive protein, as well as a trauma control to assess the evolution of the surgical site.

At the time of surgery, all patients were placed in the dorsal decubitus position on a radiolucent surgical table, and the conventional plantar entry point was used.

Regarding complications, those that required surgical treatment were documented. These complications were mainly associated with an infectious history rather than with the retrograde arthrodesis technique with a tibial nail (**Table 3**).

In the 12 patients, a satisfactory tibiocalcaneal arthrodesis was achieved, confirmed in the anteroposterior and lateral radiographs, and 83.3% recovered their bone stock completely.

**Table 1.** Initial surgery performed at our institution.

Initial surgery	+/N° patients
Puncture biopsy	9/12
External tutor	3/12
Reduction and osteosynthesis	1/12

**Table 2.** Microorganism detected in the samples taken at the initial surgery.

Microorganism	Number of patients
<i>Staphylococcus aureus</i>	8/12
<i>Enterococcus faecalis</i>	7/12
<i>Pseudomonas aeruginosa</i>	3/12
<i>Staphylococcus epidermidis</i>	3/12

**Table 3.** Complications that required a new procedure.

Complications/Procedure	Number of affected patients
Infection/Surgical debridement	8/12
Infection/Intramedullary nail replacement	
x1	4/12
x2	2/12
several	2/12
Misalignment/Osteotomy	5/12

## DISCUSSION

It is a known fact that, when faced with a tibial shaft fracture, the standard treatment is the intramedullary nail.<sup>4</sup> Regarding tibiototalcalcaneal arthrodesis, although internal fixation with screws and other devices has been described, satisfactory outcomes have been reported with the use of an intramedullary nail to achieve arthrodesis. Biomechanical studies demonstrate superior strength with an intramedullary nail than with screw fixation.<sup>5</sup> Implants up to 465 mm long are marketed for tibia fractures, but not for ankle arthrodesis, where the designed nails do not exceed 300 mm.

The problem arises in patients who need ankle arthrodesis associated with a pathology that requires proximal fixation.

No method has been published to solve both pathologies simultaneously with the same implant, nor have we found implants designed to treat them together.

Biomechanical studies demonstrate that an area susceptible to stress is located immediately proximal to fixation with short nails. This occurs because after the arthrodesis of the tibio-calcaneal joint and the subtalar joint, a decrease in the range of motion is generated and, without the ability to accommodate the forces of both joints, a bending moment is generated along the tibia.<sup>6</sup> Another factor that contributes to tibial stress fractures after arthrodesis is the increased flexion forces transmitted to the distal tibia by a longer lever arm in a stiffer foot, associated with a decrease of the mechanical strength of the bone.<sup>6</sup> On the other hand, over the years, it has been shown that the proximal point of the nail coincides with a stress point in the tibia, the isthmus (transition between metaphysis and diaphysis), the place where the proximal locking screw is located, and the site where fatigue fractures occur.<sup>6</sup> Thordarson and Chanq identified a radiolucent area proximal to the tip of the standard retrograde nail, used in ankle arthrodesis, which is correlated with episodes of pain, manifested by patients in this area. Their theory states that this area is the area with the highest concentration of stress.<sup>5</sup>

In a biomechanical study, Noonan et al.<sup>6</sup> stated that, compared to the standard 15 cm nail, a longer nail would bring the stress concentration to the proximal tibia, thus avoiding potential fatigue. Other authors suggest that the nail should reach the anterior tibial tuberosity.<sup>8</sup> Burns and Dunse<sup>9</sup> found that the standard length of the short nail increases the force in the posterior cortex of the tibia at the proximal lock by 5.3 times more than a long locking nail. For this reason, many use a long intramedullary nail for better fixation and stability in the shaft, reducing stress and the possibility of fracture.

Another potential benefit of the retrograde intramedullary nail is the early weight-bearing, this becomes a fundamental aspect when performing an arthrodesis in elderly patients with low functional demand, since it has been demonstrated that early mobility reduces mortality in this age group.<sup>8</sup> According to the literature, long femoral nails have been used in a retrograde manner, but in scenarios different from ours, as well as tibia nails in a retrograde manner, but in patients who only presented a defect secondary to oncological disease. Baker et al.<sup>8</sup> studied the use of a long retrograde femoral nail for unstable ankle fractures in 16 elderly patients (average age 73 years). With an average follow-up of 21 months, they demonstrated that the use of the retrograde femoral intramedullary nail is a safe and effective option, there were no cases of osteosynthesis failure, no fractures around the implant or wound infections. Pinzur et al.<sup>7</sup> evaluated nine patients with type 2 diabetes plus Charcot arthropathy who underwent ankle arthrodesis using a retrograde femoral nail. The average age was 52 years. Consolidation was confirmed on radiographs, in all patients, in an average time of 10.5 weeks. No patient sustained a fracture or had evidence of stress. With an average follow-up of 32 months, all patients walked wearing orthopedic shoes. Xu et al.<sup>10</sup> evaluated five patients with tibial osteosarcoma who underwent resection plus allograft in addition to arthrodesis with a retrograde tibial intramedullary nail. With a 42-month follow-up, four of the five patients were satisfied with the results. By the sixth month of follow-up, all had radiographic signs of consolidation.

One strength of our work is that we present a novel way to resolve multiple concomitant conditions in the same bone segment, with the same implant and in a single surgical time. Our case series had a follow-up time similar to that of the published series, with the exception that none of those described is the same as the one we present here.

As for weaknesses, we mention its retrospective nature, with a series of heterogeneous cases.

## CONCLUSIONS

In our series of cases, the retrograde tibial nail has not only achieved its main objective (the tibiototalcaneal arthrodesis), but has also made it possible to treat a wide range of associated conditions, which demonstrates the great versatility of this technique. As we reported, the same osteosynthesis allowed, in turn, to carry out bone transport, to be a guide for lengthening, and to help local infectological control, as has been presented in the different cases.

We consider that, in the future, it would be necessary to develop an osteosynthesis designed specifically for this type of technique. Given the current absence in the market, we suggest the use of tibia nails placed in a retrograde manner, with which, in our cases, we have obtained good results, safely and with minimal complications.

Conflict of interests: The authors declare they do not have any conflict of interests.

G. Carabelli ORCID ID: <http://orcid.org/0000-0002-7049-0688>

J. Verbner ORCID ID: <https://orcid.org/0000-0001-7040-2097>

D. Taype Zamboni ORCID ID: <https://orcid.org/0000-0001-8293-9879>

J. D. Barla ORCID ID: <https://orcid.org/0000-0001-9233-5278>

C. F. Sancineto ORCID ID: <https://orcid.org/0000-0002-5190-4312>

## REFERENCES

1. Caixeta TB, Oliveira Calabria C Jr, de Castro RV, Martins JS, Costa EN, Albieri AD, et al. Tibiototalcaneal arthrodesis with retrograde intramedullary nailing: 29 patients clinical and functional evaluation. *Rev Bras Ortop* 2014;49(1):56-61. <https://doi.org/10.1016/j.rbo.2013.11.002>
2. Hsu AR, Ellington JK, Adams SB. Tibiototalcaneal arthrodesis using a nitinol intramedullary hindfoot nail. *Foot Ankle Spec* 2015;8(5):389-96. <https://doi.org/10.1177/1938640015598838>
3. Francesch F, Franceschetti E, Torre G, Papalia R, Samuelsson K, Karlsson J, et al. Tibiototalcaneal arthrodesis using an intramedullary nail: a systematic review. *Knee Surg Sports Traumatol Arthrosc* 2016;24(4):1316-25. <https://doi.org/10.1111/os.12171>
4. Aggerwal S, Soni A, Saini UC, Gahlot N. Removal of a bent tibial intramedullary nail: a rare case report and review of the literature. *Chin J Traumatol* 2011;14(2):107-10. <https://doi.org/10.3760/cma.j.issn.1008-1275.2011.02.009>
5. Thordarson DB, Chang D. Stress fractures and tibial cortical hypertrophy after tibiototalcaneal arthrodesis with an intramedullary nail. *Foot Ankle Int* 1999;20(8):497-500. <https://doi.org/10.1177/107110079902000806>
6. Noonan T, Pinzur M, Paxinos O, Havey R, Patwardhin A. Tibiototalcaneal arthrodesis with a retrograde intramedullary nail: a biomechanical analysis of the effect of nail length. *Foot Ankle Int* 2005;26(4):304-8. <https://doi.org/10.1177/107110070502600406>
7. Pinzur MS, Noonan T. Ankle arthrodesis with a retrograde femoral nail for Charcot ankle arthropathy. *Foot Ankle Int* 2005;26(7):545-9. <https://doi.org/10.1177/107110070502600709>
8. Baker G, Mayne AIW, Andrews C. Fixation of unstable ankle fractures using a long hindfoot nail. *Injury* 2018;49(11):2083-6. <https://doi.org/10.1016/j.injury.2018.07.028>
9. Burns PR, Dunse A. Tibiototalcaneal arthrodesis for foot and ankle deformities. *Clin Podiatr Med Surg* 2017;34(3):357-80. <https://doi.org/10.1016/j.cpm.2017.02.007>
10. Xu L, Zhou J, Wang Z, Xiong J, Qiu Y, Wang S. Reconstruction of bone defect with allograft and retrograde intramedullary nail for distal tibia osteosarcoma. *Foot Ankle Surg* 2017;24(2):149-53. <https://doi.org/10.1016/j.fas.2017.01.006>