

# Spinal Needle Removal in the Thoracolumbar Spine. Case Report

Juan Manuel Gonzalez Viescas,<sup>\*</sup> Marcelo Valacco,<sup>\*</sup> Félix Imposti,<sup>\*</sup> Mariano Servidio,<sup>\*</sup> María Laura Barutta<sup>\*\*</sup>

<sup>\*</sup>Orthopedics and Traumatology Service, Hospital Churrucá-Visca (Buenos Aires, Argentina)

<sup>\*\*</sup>Spinal Surgery Unit, Sanatorio Finochietto (Buenos Aires, Argentina)

## ABSTRACT

The presence of foreign elements within the spinal canal is rare and there is no clear consensus regarding its treatment. The publications on intracanal firearm projectile fragments recommend exeresis of the fragments due to the possibility of migration, especially when they are in an area close to the medullary cone. The same procedure should be applied to a needle inside the spinal canal. We present a patient with disabling radicular pain caused by a needle fragment within the spinal canal after cesarean section.

**Key words:** Epidural anesthesia; broken needle; intradural anesthesia.

**Level of Evidence:** IV

## Retiro de aguja intradural en la columna toracolumbar. Reporte de un caso

## RESUMEN

La presencia de elementos extraños dentro del canal raquídeo es infrecuente y no hay claro consenso respecto de su tratamiento. Las publicaciones sobre fragmentos de proyectil de arma de fuego intracanal recomiendan la exéresis de los fragmentos ante la posibilidad de migración, sobre todo, cuando están en una zona próxima al cono medular. Se debería proceder del mismo modo ante una aguja dentro del canal espinal. Presentamos a una paciente con dolor radicular invalidante provocado por un fragmento de aguja dentro del canal espinal luego de una cesárea.

**Palabras clave:** Punción espinal; anestesia epidural; anestesia intradural; rotura de aguja.

**Nivel de Evidencia:** IV

## INTRODUCTION

The anesthesia of choice for a cesarean section is subarachnoid block, for which increasingly fine spinal needles are used to reduce the incidence of postdural puncture headache, the most frequent complication of this type of anesthesia.<sup>1</sup> However, the use of smaller and smaller needles carries the risk of another complication: fracture of the spinal needle, a rare but serious situation.<sup>2</sup> Technique, needle type, and patient characteristics may contribute to the potential risk of needle fracture. There is considerable consensus that broken spinal needle fragments should be removed as soon as possible to prevent serious symptoms or complications. However, few reports focus on the mediate management of this complication and there are even fewer cases that prove the migration of the intracanal fragment.<sup>3</sup>

We present the case of a woman who had undergone a cesarean section under subarachnoid anesthesia and who, months later, began to suffer radicular pain in the right lower limb from a needle fragment lodged within the thoracolumbar spinal canal.

Received on June 30<sup>th</sup>, 2020. Accepted after evaluation on August 16<sup>th</sup>, 2020 • JUAN MANUEL GONZALEZ VIESCAS, MD • gonzalezjuanmanuel@gmail.com  <https://orcid.org/0000-0003-2753-8161>

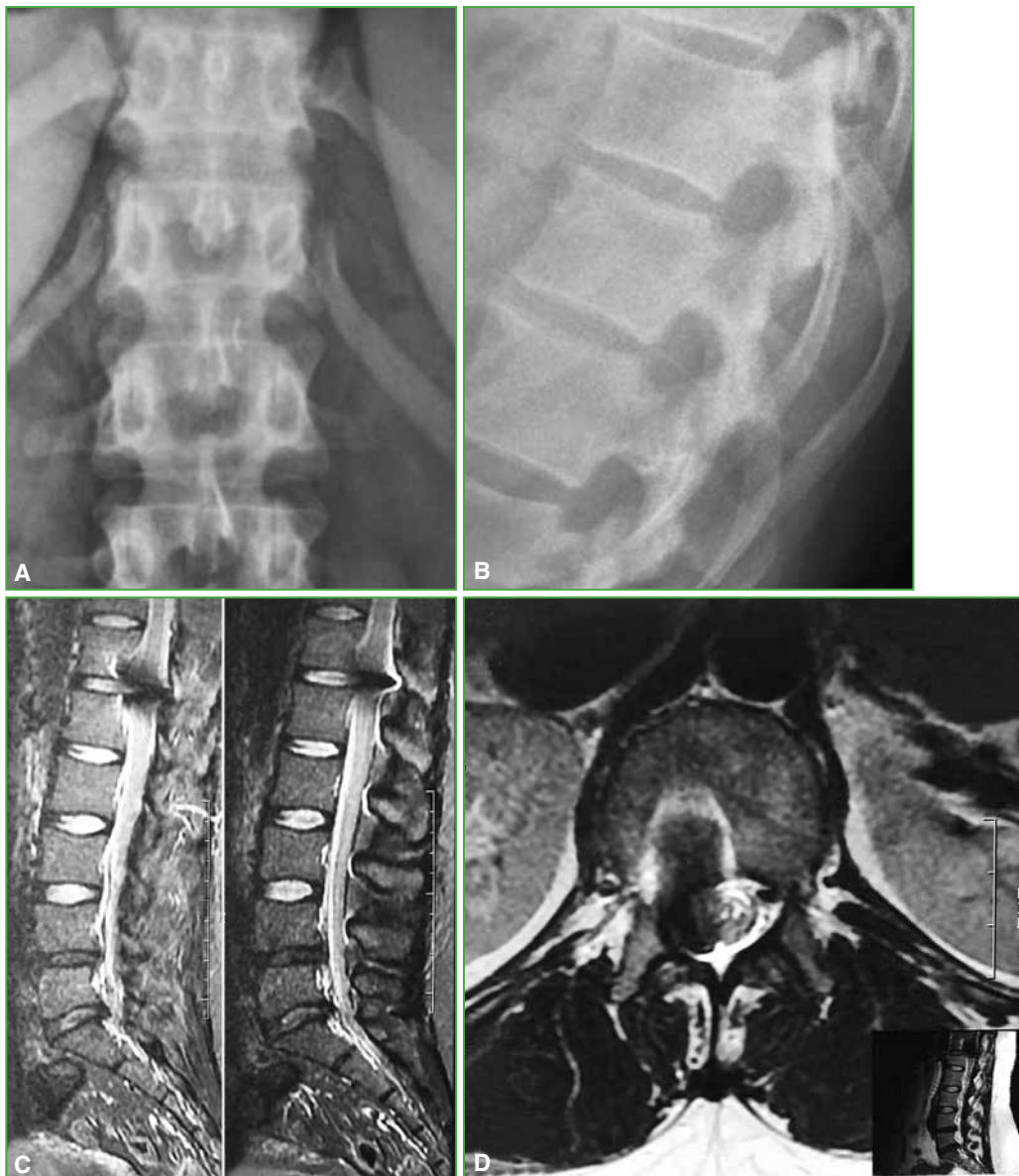
**How to cite this article:** Gonzalez Viescas JM, Valacco M, Imposti F, Servidio M, Barutta ML. Spinal Needle Removal in the Thoracolumbar Spine. Case Report. *Rev Asoc Argent Ortop Traumatol* 2021;86(3):392-397. <https://doi.org/10.15417/issn.1852-7434.2021.86.3.1146>

## CLINICAL CASE

A 36-year-old woman, with a body mass index of 31, who consulted for right radicular pain from a spinal puncture, after a cesarean delivery six months before. She referred that, at the time of anesthesia, she felt severe lacerating pain radiating from the lumbar area to the lower right limb, in the thigh area up to the knee. After that episode, the pain set in, and was more severe during activity and in certain positions. It decreased when resting.

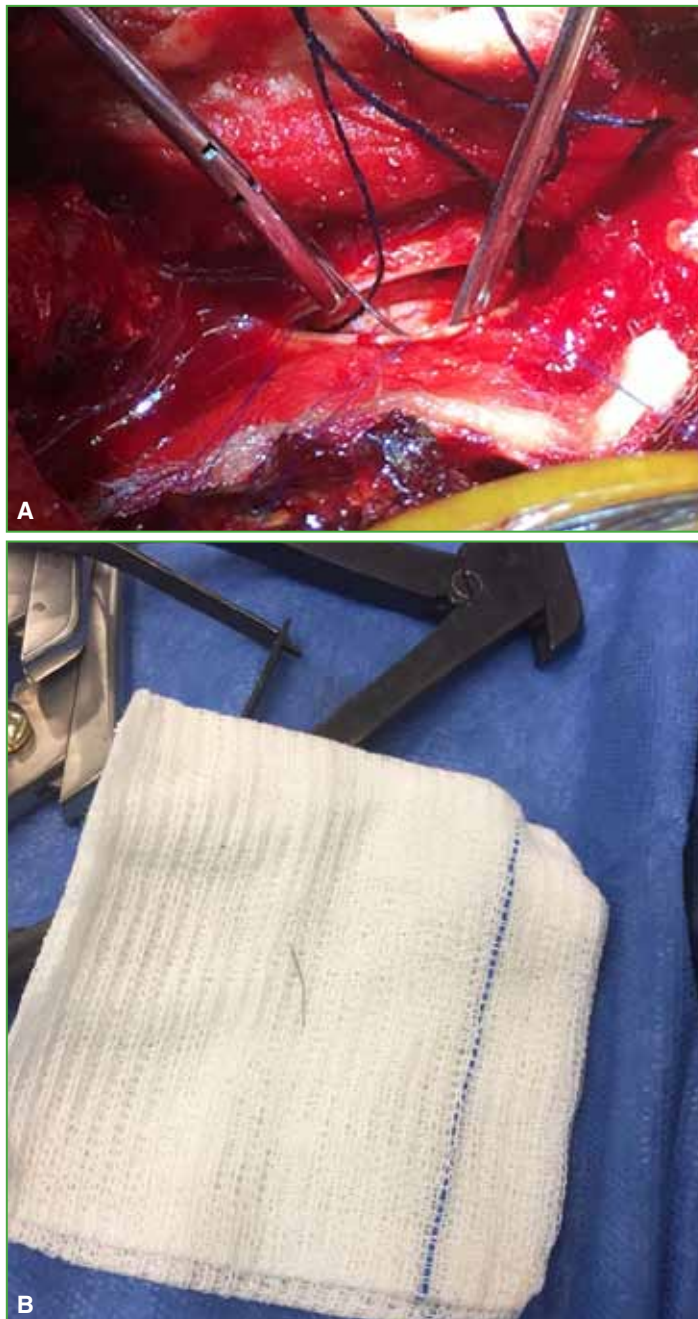During consultation, the patient reported lumbar pain with projection to the right thigh, with a score of 8/10 on the visual analog scale. Sensory compromise was detected in the thigh, without motor compromise.

On radiographs and magnetic resonance imaging (MRI) and three-dimensional computed tomography (3D CT) of the dorsolumbar spine, a foreign body was observed in T12-L1, right paracentral, close to the ipsilateral foramen, which was interpreted as a remnant of the needle that had been broken at the time of the spinal puncture for the cesarean section, six months before (Figure 1).



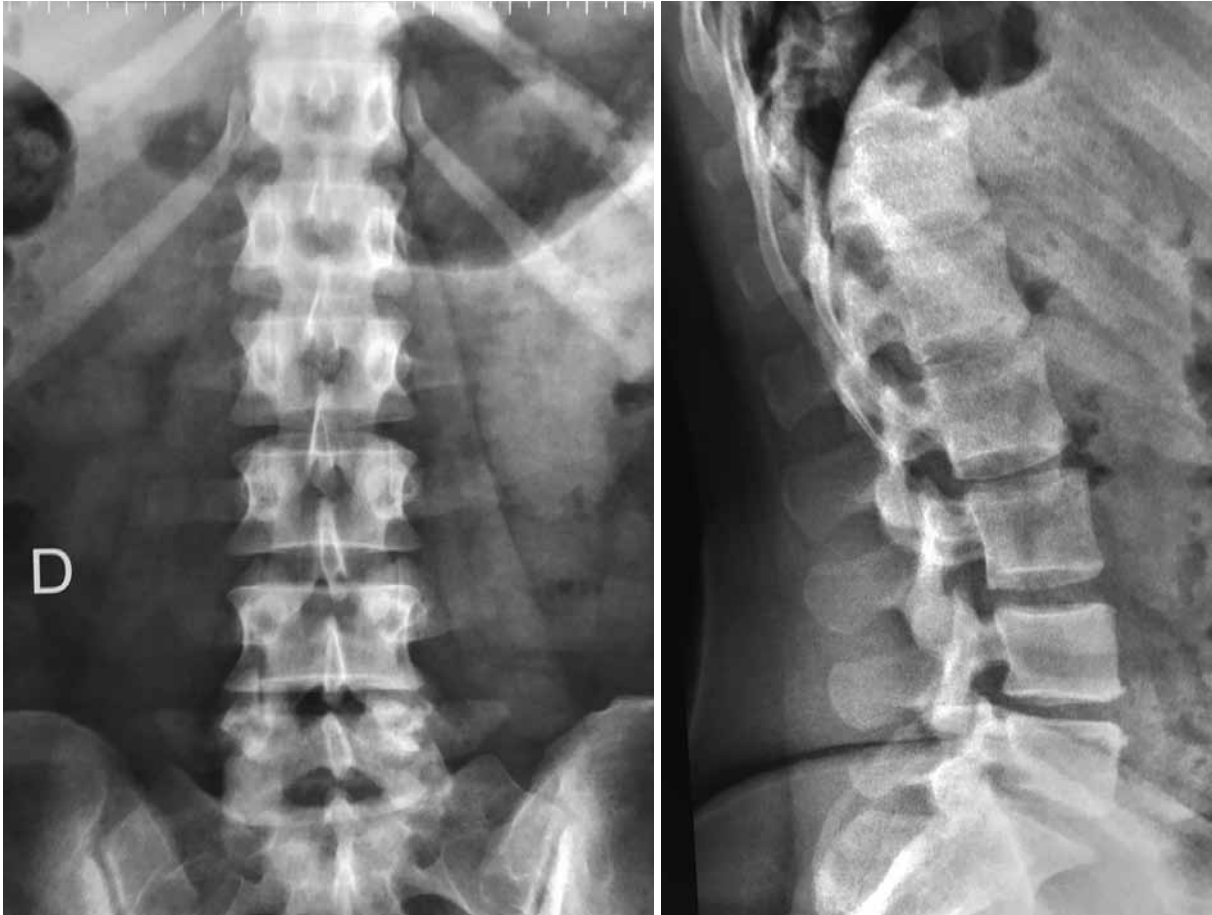**Figure 1.** A and B. Thoracolumbar spine radiograph. An intracanal spinal needle fragment is visualized. C and D. Lumbar spine magnetic resonance, sagittal and axial planes. The artifact generated by the intracanal needle is observed.

Surgical treatment was indicated to remove the needle. Surgery was planned through the posterior dorsolumbar approach, through the midline between T12 and L1, with divulsion of the muscle on the right side. By means of hemilaminectomy, the epidural space was accessed and no element was found compatible with what was visualized in the studies by images. Therefore, we decided to perform a transdural exploration under microscope, and the fragment of the needle was found, fixed in the T12-L1 disc on the right side. The fragment was removed with a pituitary forceps (Figure 2). After the exploration with fluoroscope and verifying that the rest of the needle had been completely extracted, the closure was carried out with 6.0 suture and dural sealant, with a negative Valsalva maneuver. The closure of the wound by planes was completed in a hermetic manner.



**Figure 2.** **A.** Removal of the needle after dural opening. The needle was fixed on the T12-L1 disc. **B.** Broken needle fragment, sent to regulatory authorities.

Surgery was carried out with somatosensory and motor evoked potentials, and no alterations were observed. After extraction, imaging studies were performed in order to verify and document the absence of the needle fragment (Figure 3).



**Figure 3.** Control radiographs. No remains of the intracanal fragment are observed.

At 48 h after surgery, she was allowed to walk. The patient manifested pain in the area of the surgical wound that had a good response to analgesics. She did not have radicular pain radiating to the right as before surgery (score 0/10 on the visual analog scale). On the third postoperative day, she was discharged from the hospital; initial care was indicated during the first week and, after the removal of the stitches, at 10 days, she continued with her normal life. At present, with 24 months of follow-up, the patient has no symptoms.

## DISCUSSION

Subarachnoid anesthesia used for cesarean section is a safe procedure, with a low rate of complications, among them, the most frequent is postdural puncture headache. In order to reduce this complication, small-caliber pencil-point needles are used. However, with their use, the risk of another complication of this technique increases, such as deformity or broken needles.<sup>2,4</sup> This complication, although it occurs and it has been described, is very rare. According to Abou-Shameh et al., the incidence rate is 1/5000.<sup>5</sup>

Various risk factors are mentioned, such as the type of needle, the technique used and factors associated with the patient.<sup>1,6</sup> Regarding the type of needle, the use of fine, long Quincke-type needles and the use of an alternative introducer to that recommended by the manufacturer have an influence on the outcome.<sup>7</sup> Regarding the technique, the most likely practices that can break or cut fragments of the needle are: a) redirecting the needle without withdrawing it to the superficial subcutaneous tissues, b) withdrawing and redirecting the needle while keeping the introducer in place and c) manipulating the needle after removing the stylet. Finally, among the factors associated with the patient and that can generate a difficult puncture—either due to the direction of the needle or the effectiveness of the puncture—we can mention obesity, short stature, severe vertebral deformity or a history of spinal surgeries. In the same way, acting urgently in a cesarean section can involve risks.<sup>2</sup> In our case, when the spinal operation was performed, the patient had a body mass index of 31; this can be considered a risk factor.

From a clinical point of view, the symptoms generated by an intracanal foreign body are usually unusual, with nonspecific pain, with a radicular pattern and without a specific position of relief. Previous studies show unusual pain patterns.<sup>7,8</sup> Our patient remained with insidious right radicular pain for several months after cesarean section, which did not disappear with conservative treatment.

Blanchard et al. mention that the consequences of a broken spinal needle in the spine include its migration as a foreign body, infection or fibrosis of the surrounding tissue, and possible neurological complications. In our patient, the migration of the fragment was verified with subsequent neurological compromise generated by disabling right radicular pain.<sup>7,9</sup>

The most useful diagnostic studies are radiographs and CT scans that show the metal fragment of the needle. Staats et al. published a case of an intracanal needle that had not been clearly observed in the initial magnetic resonance images, so the diagnosis had to be completed with a computed tomography.<sup>9</sup> In our patient, the MRI showed an artifact in the area of the spinal canal, compatible with a foreign body, which was confirmed by the tomographic study.

## Management of spinal needle fracture

### *Immediate diagnosis and management*

There is consensus when the immediate diagnosis is made:

*Continue with the scheduled surgery:* if the patient does not have neurological symptoms associated with the needle fragment, the surgeon can proceed with the scheduled surgery, under spinal or general anesthesia, depending on the type of surgery to be performed. If it ruptures in a cesarean section, most publications recommend proceeding to the lumbar puncture at a higher level (the risk factors for needle fracture are the same as for difficult intubation and general anesthesia should be avoided in these patients).<sup>3,10</sup>

*Plan the extraction of the fragment:* during surgery or immediately afterwards. Intraoperative fluoroscopy can be used to locate the fragment. And, depending on the location and type of surgical procedure being performed, the presence of a general surgeon or a spine specialist should be guaranteed.

*Inform the patient:* the patient should be informed and explained that removal of the fragment does not usually cause long-term neurological sequelae.

*Extract the fragment as soon as possible:* it should be treated immediately, usually in the same surgical shift, although, according to some articles, it has been deferred up to two weeks, without complications.<sup>1,3,11</sup>

*Sending of material to the regulatory authority and control by diagnostic imaging.*

### *Mediate diagnosis*

In cases of mediate diagnosis, there is not enough evidence on how to proceed and we opted for the removal of the needle. This article proves that it can be done without complications, even in symptomatic cases.

In our case, the location of the needle fragment was very striking, since spinal punctures should always be performed below L2, ideally the L3-L4 or L4-L5 spaces. Therefore, we affirm that the needle migrated, which reinforces the indication to extract all fragments, as soon as the diagnosis is confirmed. The needle fragments have stiff, sharp ends and can migrate into the spinal cord.

We also recommend surgery as soon as possible in asymptomatic patients, given the possibility of intracanal migration, something that was verified in this patient.

The patient should always be examined before and after extraction using imaging studies.

## CONCLUSIONS

We believe that the deformity or breakage of the needle in a spinal puncture is a rare complication with a low incidence according to the studies evaluated. We consider that it is essential to perform a subarachnoid puncture with the appropriate technique and, if there are risk factors, such as obesity, consider the use of thicker needles to avoid this complication.

Finally, we believe that, if such a complication occurs, whether it was diagnosed immediately or months later, surgery to remove the broken fragment is the procedure of choice, as it is very effective and very well tolerated.

Conflict of interests: The authors declare they do not have any conflict of interests.

M. Valacco ORCID ID: <https://orcid.org/0000-0002-9697-3856>  
F. Imposti ORCID ID: <https://orcid.org/0000-0001-9827-6985>

M. Servidio ORCID ID: <https://orcid.org/0000-0001-9070-4412>  
M. L. Barutta ORCID ID: <https://orcid.org/0000-0003-2883-1298>

## REFERENCES

1. Collier C. Epidural catheter breakage: a possible mechanism. *Int J Obstet Anesth.* 2000;9(2):87-93. <https://doi.org/10.1054/ijoa.1999.0354>
2. Martinello C, Rubio R, Hurwitz E, Simon M, Vadhera RB. Broken spinal needle: case report and review of the literature. *J Clin Anesth* 2014;26(4):321-4. <https://doi.org/10.1016/j.jclinane.2014.01.008>
3. Moll A, Filippini G. Ruptura de aguja espinal. Reporte de Caso. Tutorial 378. World Federation of Societies of Anesthesiologists. Disponible en: [https://www.wfsahq.org/components/com\\_virtual\\_library/media/7918c4dfe5171561840733c0f305e857-378.pdf](https://www.wfsahq.org/components/com_virtual_library/media/7918c4dfe5171561840733c0f305e857-378.pdf) . (Consulta: 1 de mayo 2018).
4. Cruvinel MG, Andrade AV. Fratura de agulha durante punção subaracnóidea: relato de caso [Needle fracture during spinal puncture: case report.]. *Rev Bras Anesthesiol* 2004;54(6):794-8. <https://doi.org/10.1590/s0034-70942004000600007>
5. Abou-Shameh MA, Lyons G, Roa A, Mushtaque S. Broken needle complicating spinal anaesthesia. *Int J Obstet Anesth* 2006;15(2):178-9. <https://doi.org/10.1016/j.ijoa.2005.10.014>
6. Hobaika AB. Breakage of epidural catheters: etiology, prevention, and management. *Rev Bras Anesthesiol* 2008;58(3):227-33. <https://doi.org/10.1590/s0034-70942008000300005>
7. Blanchard N, Clabeau JJ, Ossart M, Dekens J, Legars D, Tchaoussoff J. Radicular pain due to a retained fragment of epidural catheter. *Anesthesiology* 1997;87(6):1567-9. <https://doi.org/10.1097/00000542-199712000-00036>
8. You JW, Cho YH. Foraminal stenosis complicating retained broken epidural needle tip -A case report-. *Korean J Anesthesiol* 2010;59(Suppl):S69-S72. <https://doi.org/10.4097/kjae.2010.59.S.S69>
9. Staats PS, Stinson MS, Lee RR. Lumbar stenosis complicating retained epidural catheter tip. *Anesthesiology* 1995;83(5):1115-8. <https://doi.org/10.1097/00000542-199511000-00027>
10. Lee YH, Hwang HY, Sim WS, Yang M, Lee CJ. Breakage of a thoracic epidural catheter during its removal -A case report-. *Korean J Anesthesiol* 2010;58(6):569-72. <https://doi.org/10.4097/kjae.2010.58.6.569>
11. Mitra R, Fleischmann K. Management of the sheared epidural catheter: is surgical extraction really necessary? *J Clin Anesth* 2007;19(4):310-4. <https://doi.org/10.1016/j.jclinane.2006.11.005>