

# Hemicorporectomy and Prosthetic Equipment. Report of a Case at 15 Years of Follow-up

Walter Cerrutti,\* Gerardo L. Gallucci,\*\* José D. Freire\*\*†

\*Centro de Ortopedia y Traumatología Quilmes, Buenos Aires, Argentina

\*\*Orthopedics and Traumatology Service, Hospital Italiano de Buenos Aires, Autonomous City of Buenos Aires, Argentina

†Deceased

## ABSTRACT

Hemicorporectomy or translumbar amputation is a radical surgery indicated in localized pelvic tumors, chronic osteomyelitis, severe trauma, and intractable decubitus ulcers in paraplegic patients. It has a death rate of about 50% and most of the patients are confined to a wheelchair. The equipment of the entire lower body is extremely complex. We report a case of a patient with a hemicorporectomy, sequel to pelvic osteomyelitis, his subsequent complete equipment, and his evolution after 15 years of follow-up.

**Key words:** Hemicorporectomy; translumbar amputation; prosthesis; pelvic osteomyelitis.

**Level of Evidence:** IV

## Hemicorporectomía y equipamiento protésico. Reporte de un caso a los 15 años de seguimiento

## RESUMEN

La hemicorporectomía o amputación translumbar es una cirugía radical indicada en casos de tumores, osteomielitis crónicas y traumas graves de la pelvis, y también, en pacientes parapléjicos con úlceras por decúbito intratables. La tasa de mortalidad por este procedimiento es del 50% y la gran mayoría de los pacientes que sobreviven quedan confinados a una silla de ruedas. El equipamiento de todo el hemicuerpo inferior es sumamente complejo. Comunicamos el caso de un paciente con una hemicorporectomía, secuela de una osteomielitis pelviana, su equipamiento completo posterior y su evolución a los 15 años de seguimiento.

**Palabras clave:** Hemicorporectomía; amputación translumbar; prótesis; osteomielitis pelviana.

**Nivel de Evidencia:** IV

## INTRODUCTION


Hemicorporectomy or translumbar amputation includes the amputation of the pelvis and lower extremities through the lumbar spine with concomitant transection of the aorta, inferior vena cava, and spinal cord. It is also accompanied by the corresponding urinary and intestinal diversion.

It was originally proposed by Kredel in 1950,<sup>1</sup> and Kennedy et al. carried it out successfully for the first time in 1960.<sup>2</sup>

Hemicorporectomy was initially proposed for severe invasive pelvic tumors, although it has also been indicated for severe trauma to the pelvis and lower extremities,<sup>3</sup> vascular malformations,<sup>4</sup> acute aortic occlusion,<sup>5</sup> recurrent perianal and scrotal fistulas,<sup>6</sup> and terminal pelvic osteomyelitis.<sup>7,8</sup>

Hemicorporectomy is a very high-risk surgery, the perioperative mortality rate exceeds 50%.<sup>9</sup> This risk is due to the length of surgery, blood loss, and cardiovascular failure after the separation of the torso from the pelvis. To date, 66 hemicorporectomies have been published.<sup>10</sup> The most frequent indication has been a tumor, and the least frequent, terminal pelvic sepsis or osteomyelitis.

Received on June 14<sup>th</sup>, 2020. Accepted after evaluation on October 21<sup>st</sup>, 2020 • Dr. WALTER CERRUTTI • cerruttiwalter@gmail.com

 <https://orcid.org/0000-0001-9280-2999>

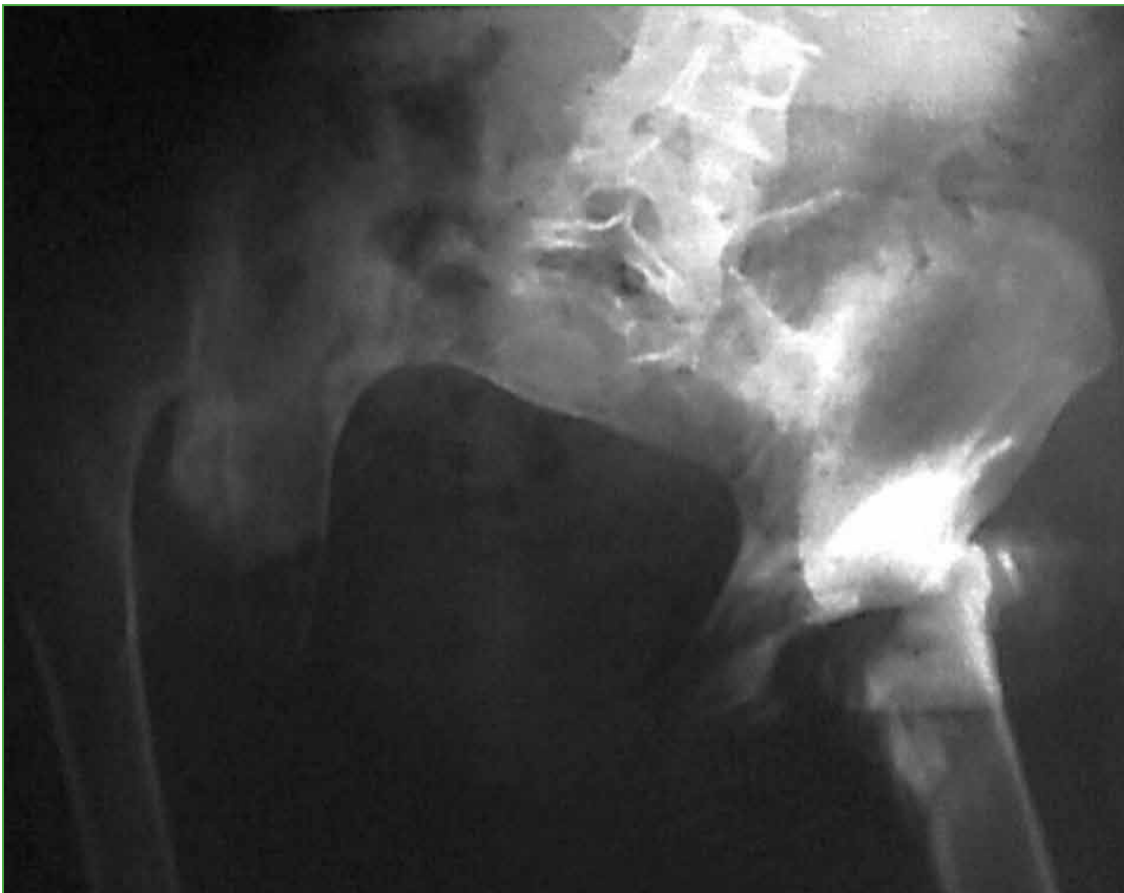**How to cite this article:** Cerrutti W, Gallucci GL, Freire JD. Hemicorporectomy and Prosthetic Equipment. Report of a Case at 15 Years of Follow-up. *Rev Asoc Argent Ortop Traumatol* 2021;86(6):790-801. <https://doi.org/10.15417/issn.1852-7434.2021.86.6.1135>

Most surviving hemicorporectomy patients are confined to wheelchairs with partial inclusion in activities of daily living. The equipment of the lower limbs in these patients is very complex and, in general, poorly tolerated.

The objective of this article is to report the case of a patient who underwent hemicorporectomy due to pelvic osteomyelitis, the equipment used, and the evolution at 15 years of follow-up.

## CLINICAL CASE

A 25-year-old man who had suffered a motorcycle accident five years before. The injury produced a fracture at the D10 level and a condition of paraplegia with a sensitive level compatible with the injury. His neurological status was classified as Frankel A. Poor hygienic care caused multiple bedsores on his legs, sacrum, and trochanters, which forced him to undergo several surgical procedures, including infrapatellar amputation of both legs (Figure 1). This irreversible condition continued to evolve and ended with the development of massive pelvic osteomyelitis that required a permanent suprapubic cystostomy and Hartman surgery (colostomy).

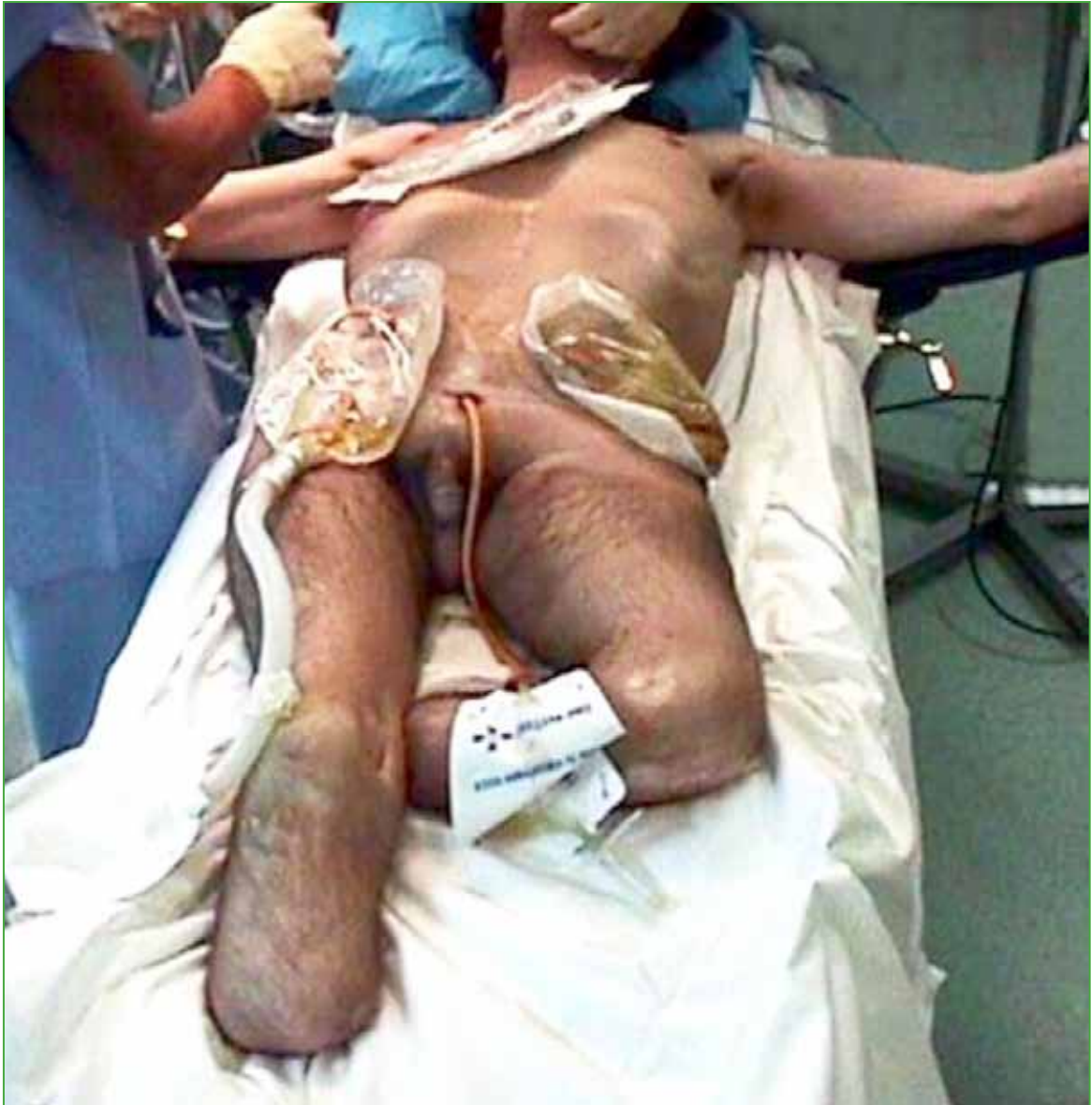

**Figure 1.** Anteroposterior pelvic radiographs showing osteomyelitis.

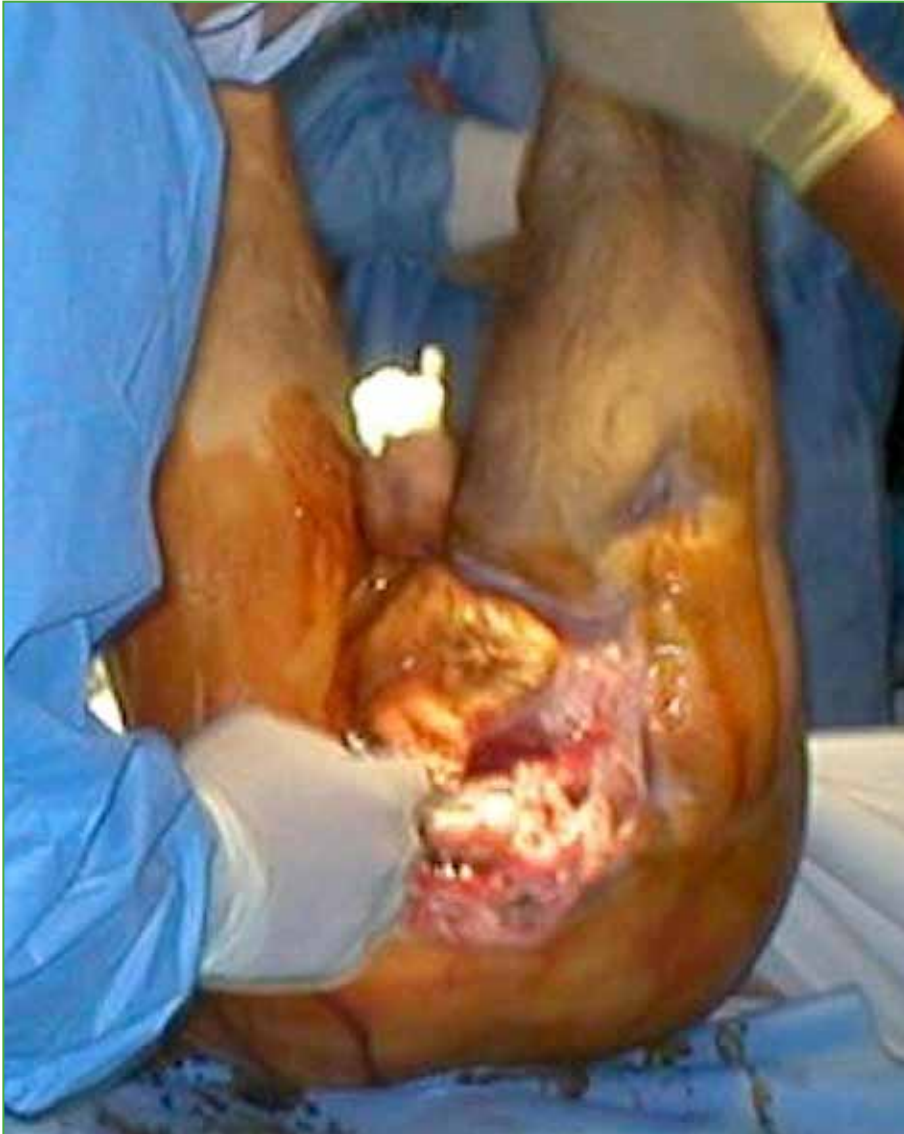Over the last years, the purulent discharge from his cystostomy was permanent and he had numerous hospitalizations to receive antibiotic treatments, have cystostomy changes and drainage of pelvic empyemas. He had also developed a large sacral ulcer. The preoperative nutritional status, according to Gomez's classification,<sup>11</sup> was 58%, which corresponds to severe malnutrition, with a body mass index of 16. His quality of life was determined with the Short Form-36 Health Survey,<sup>12</sup> which assesses disability from 0 (maximum disability) to 100 (minimum disability). The result obtained was 15 points.

In this terminal situation, he consulted our Department and the possibility of performing a hemicorporectomy emerged as a valid therapeutic alternative. A psychological consultation was requested and the procedure was explained to the patient in detail. After obtaining acceptance and informed consent, he was admitted.

The procedure was carried out by a multidisciplinary team (traumatology, general surgery, and urology) headed by one of the authors (JF), in a single surgical stage under general anesthesia (Figures 2 and 3).

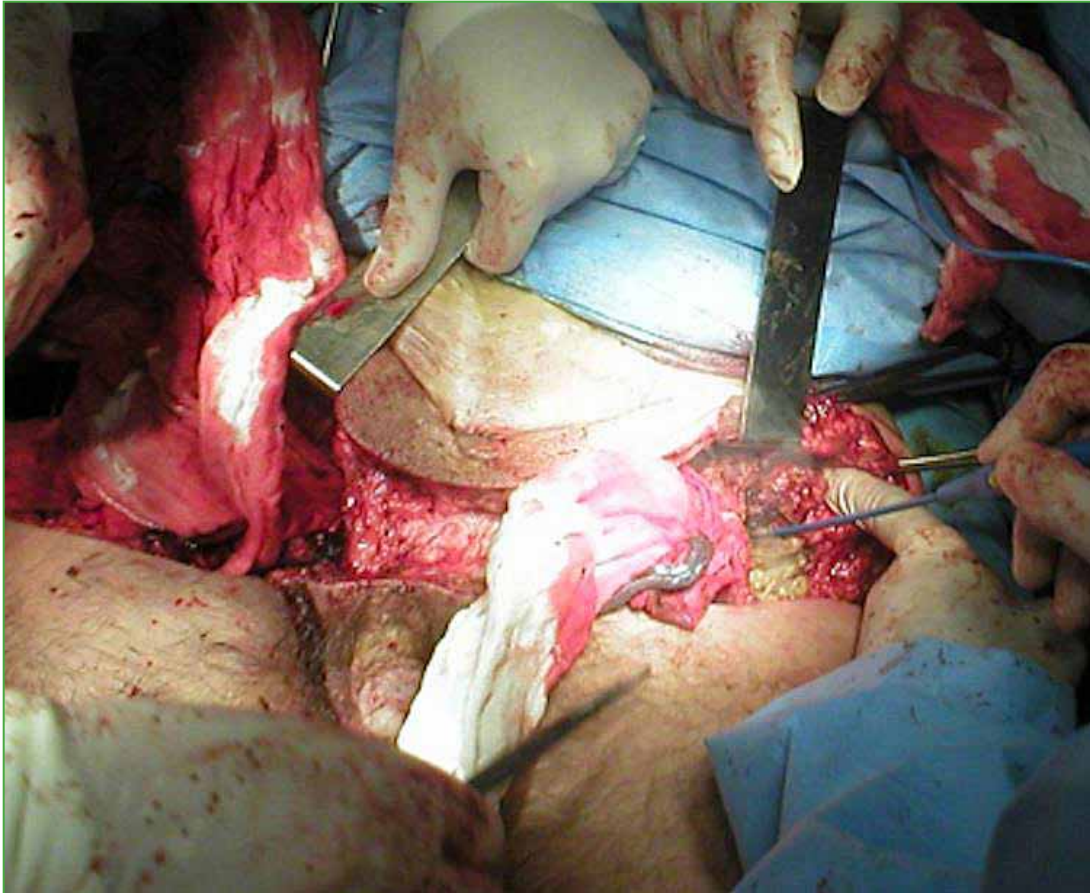


**Figure 2.** Condition of the patient at the time of surgery.



**Figure 3.** Sacral ulcer.

The surgery began with the patient in the dorsal decubitus position. A bilateral ilioinguinal approach extended to proximal was used to create an anterior flap that later covered the posterior defect (Figure 4). It included a colostomy and a ureteroileostomy. The vena cava and both common iliac arteries were ligated. Batson's plexus was dissected and ligated and disarticulation was performed at L3-L4. 1% lidocaine was administered intraneurally to avoid neurogenic shock and the roots were resected with a bipolar electro-surgical unit. The dura mater was closed with 6-0 Prolene and this closure was confirmed by Valsalva maneuvers.



**Figure 4.** Bilateral ilioinguinal approach.

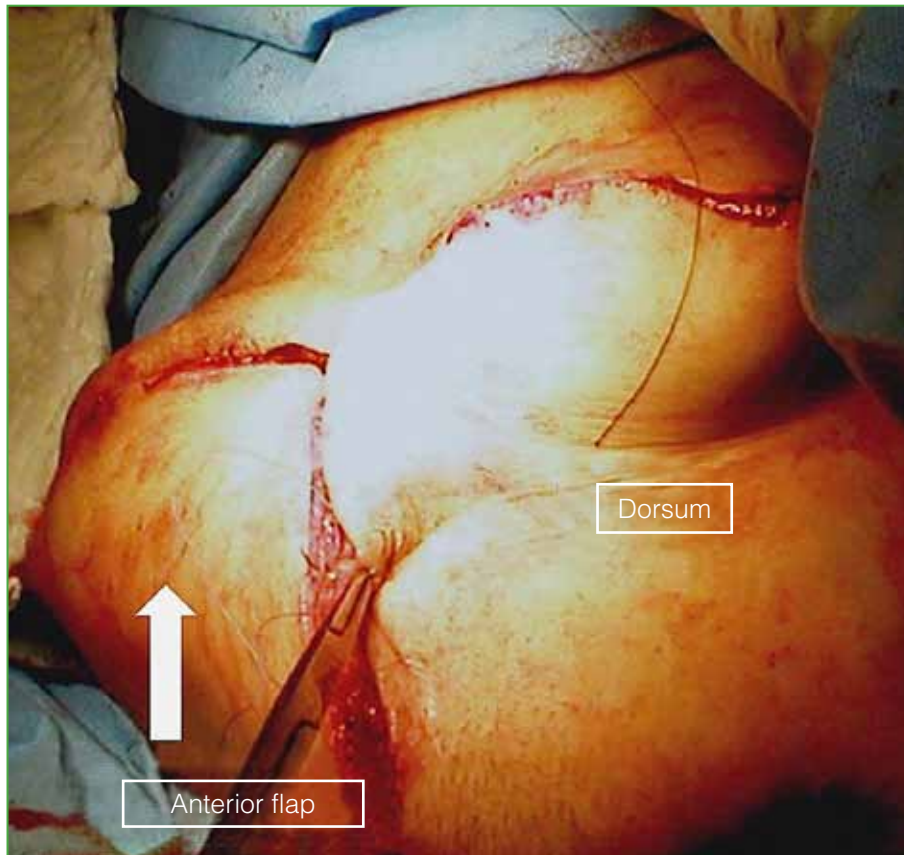The patient was then placed in the ventral decubitus position and the posterior flap was closed (Figure 5).

The surgery lasted 11 hours and it was necessary to administer 11 units of red blood cells.

The patient was taken to the Intensive Care Unit where he stayed for five days, after which he was transferred to the general ward where he spent six days. Antibiotics were administered intravenously: vancomycin 1 g every 12 h and imipenem 500 mg every 12 h. He then maintained an antibiotic plan for six weeks with amoxicillin/clavulanic acid 250 mg and 500 mg, respectively, every 12 hours.

Six days after surgery, he presented wound dehiscence that required multiple dressing changes.

His initial septic picture improved markedly and, five months after the operation, a neobladder was performed with the Bricker technique and, in the same surgical stage, a local flap was carved to cover the residual defect.

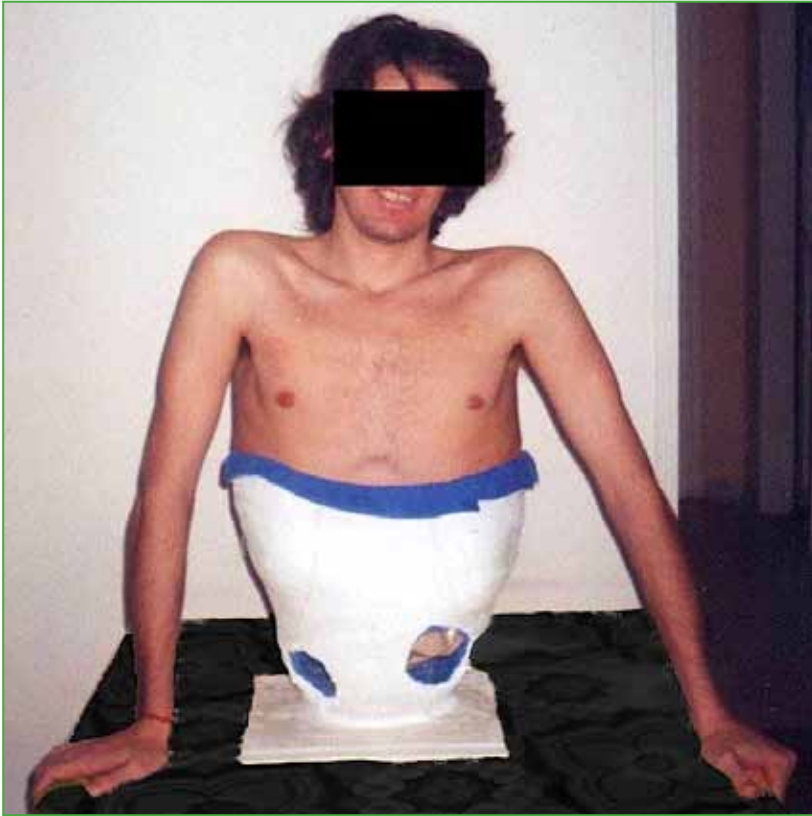

**Figure 5.** Flap for posterior coverage.

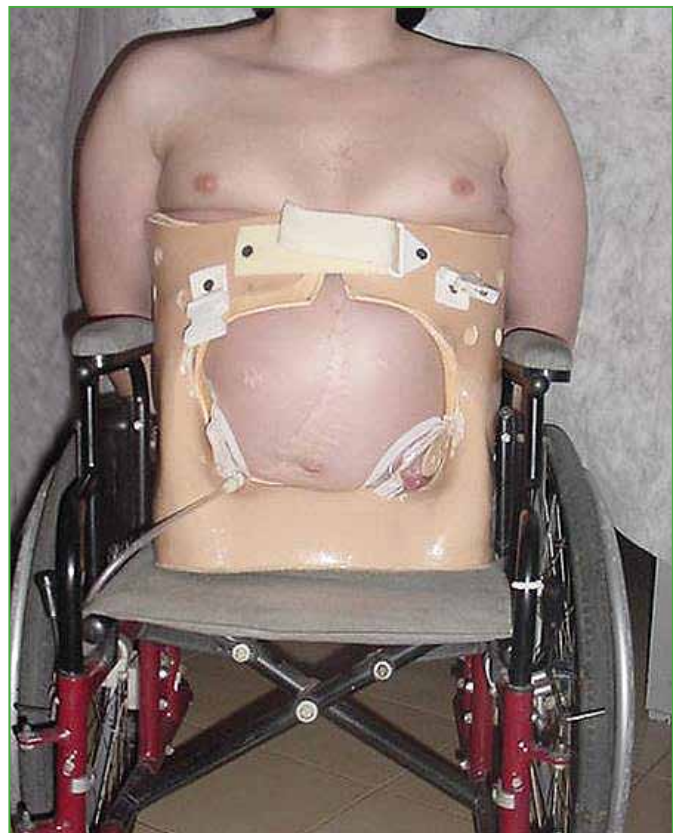### Equipment

During the first months and while waiting for the wound to heal, a plan to strengthen the upper limbs was started, assisted by therapists. The pre-prosthetic equipment stage started once complete healing of the wound was achieved. At this stage, a plaster bucket with rib support was made, covered inside with Polyform. Then a flat wooden base covered with plaster was attached, allowing the patient to remain upright for hourly intervals. Then, the bucket was removed, the areas of rib pressure were evaluated and the necessary corrections were made. The progressively increased use of the bucket continued during the following two months, until the patient achieved a permanent use of 6 h, with good tolerance (Figure 6).

After the third month of use, a bucket corset was made of an acrylic and carbon laminate, with Polyform inner padding, rib support, and a method of suspension using velcro buckle straps (Figure 7).



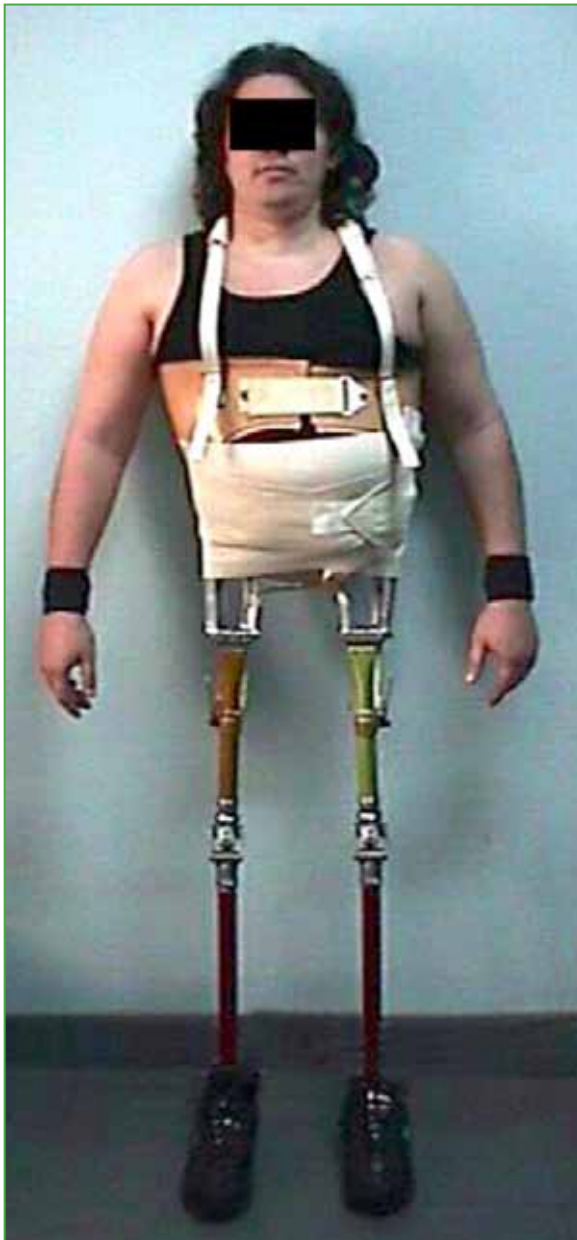**Figure 6.** Preparation of the plaster bucket with flat support.



**Figure 7.** Manufacture of the bucket corset from an acrylic and carbon laminate, with Polyform inner padding and rib support.

After this stage, the rest of the prostheses were attached to the corset. Anthropometric measurements were taken to return its original size. For the hip joints, an Ottobock 7E5 prosthesis (Ottobock SE & Co. KGaA) with a manual locking system was used, which allowed locking the hip in extension to walk and unlocking it to sit. An Ottobock 3R20 mechanical polycentric prosthesis (Ottobock SE & Co. KGaA) with titanium attachment modules was used for the knee joints and, for the feet, a SACH + Ottobock dynamic prosthesis (Ottobock SE & Co. KGaA) with a wood core was used (Figure 8).

Once the prosthesis was assembled, the learning process for its use began. Achieving standing was the initial goal of treatment, then ambulation (in a pendulous way with a walker), and finally sitting up and going up and down steps. This entire process lasted approximately six months until the patient achieved independence. Subsequently, he managed to drive adapted vehicles. Finally, the prosthesis was covered with plastic foam to improve its aesthetics (Figure 9).



**Figure 8.** Patient with full equipment.



**Figure 9.** Aesthetic appearance of the implant.



## RESULTS

Fifteen years after surgery, the patient was called for control. A generic functional assessment was performed with the Barthel Index<sup>13</sup> and a specific one with the Locomotor Capabilities Index.<sup>14</sup>

The Barthel Index, also known as the Maryland Disability Index, assesses the patient's level of independence in some basic activities of daily living. The interpretation suggested by Shah et al.<sup>15</sup> on the Barthel Index score is: 0-20: total dependence, 21-60: severe dependence, 61-90: moderate dependence, 91-99: little dependence, and 100: independence. Our patient's score was 80 (moderate dependence).

The Locomotor Capabilities Index is an evaluation composed of 14 questions that determine the patient's ability to perform certain activities with the use of a prosthesis. The variation of the score ranges from 0 (lowest score) to 56 (highest score). The patient obtained a score of 31. The Short Form-36 Health Survey yielded 74 points.

An echocardiogram was requested to assess cardiac function at 14 years of follow-up. The ejection fraction was 70 mmHg with a heart rate of 60 beats/minute. At that time, he was also subjected to a stress test by walking 100 m with the walker. The heart rate rose to 96 beats/min, representing a 60% increase in cardiac output with ambulation.

From the social point of view, the patient achieved a total reincorporation. The gait he has achieved is of the pendulum type with the help of the walker. He lives with his partner, works in a workshop, drives an adapted car, engages in daily physical activity, and is a car racer (Figure 10).

He refers to being extremely grateful and satisfied with the procedure and does not hesitate to recommend it to patients who are in the same terminal situation.

## DISCUSSION

Although hemipelvectomy was originally proposed for the treatment of invasive pelvic tumors, improvements in cancer surgery and advances in chemotherapy and radiotherapy have made this indication less frequent today. Most of the latest published studies include patients with severe traumatic pathology, large chronic decubitus ulcers, or pelvic osteomyelitis who do not respond to any type of treatment.<sup>9,16,17</sup>

To achieve successful results with low morbidity and mortality, it is essential to use a multidisciplinary approach. This involves the coordination of various surgical services, such as general surgery, orthopedics, plastic surgery, neurosurgery, urology, and rehabilitation.

In addition, perioperative clinical management is essential, especially the knowledge of changes in acid-base balance, cardiovascular function, and respiratory function.


Comorbidities associated with hemipelvectomy may include paralytic ileus, intestinal obstruction, gastroduodenal stress ulcers, urinary tract infections, meningitis, metabolic disorders, and wound dehiscence.<sup>7,8,18</sup> In the first reports of hemipelvectomy, death after surgery was largely attributed to the tumor, in addition to the great loss of body surface area. The effects of heat dissipation and temperature regulation cause these patients to have a decreased ability to regulate body temperature, especially during physical activity. Ligation of the common femoral vessels and nerves causes a sharp increase in systemic vascular resistance and cardiac afterload, which can precipitate heart failure and pulmonary edema.

Finally, meticulous wound care, pressure ulcer prevention, extensive rehabilitation, and psychological and emotional support are critical in the postoperative period.

The high rate of complications is also due to the poor nutritional status of these patients. In patients with terminal pelvic osteomyelitis, chronically exudative wounds, and great imbalances of the internal environment, improving nutrition in the preoperative period is very complex, despite supplementation and aggressive nutritional treatment by nutritionists.

Janis et al.<sup>16</sup> published their experience with 11 patients who underwent hemipelvectomy for sequelae of pelvic osteomyelitis and reported a survival rate of 53% at the end of follow-up.

In a review of 14 hemipelvectomies for refractory osteomyelitis, Barnett et al.<sup>19</sup> reported only two deaths at the end of follow-up, but an extended hospital stay (an average of 127 days), with blood loss ranging from 2 to 12 liters.



**Figure 10.** A. Current state of the patient with a walker. B. In automobile competitions. C. Working in his workshop. D. At the gym.

Our patient had complications in the wound possibly related to the infection and his poor nutritional status. As soon as his condition improved, the wound healing evolved favorably.

The goal of rehabilitation after hemipelvectomy is to restore the patient's independence and mobility. But this is not easy to achieve, since approximately 40% of the patients eventually do not tolerate the prosthesis.

Most of the patients described in the literature are equipped with a rib support bucket and are able to move in a wheelchair.<sup>16,20</sup> The equipment of the lower limbs is associated with many complications. The slow gait speed allowed by the prosthesis and the need for a walker are frequent reasons for rejection. It has been recognized that the complex physiological and psychological sequelae of this procedure also complicate the prosthetic management of this group of patients.

A prosthesis must meet certain functional and psychosocial rehabilitation needs as well as certain criteria: allowing an upright and stable posture with maximum freedom of the upper limb, maintaining body support without exerting excessive intra-abdominal pressure, and allowing free breathing and unobstructed access to urological and intestinal drains. Manufacturing a total lower body prosthesis poses great challenges.<sup>21,22</sup>

To our knowledge, no long-term reports have been published on the complete equipment of a hemipelvectomy patient.

Reaching a good tolerance of the prosthesis significantly increases the acceptance and independence of the patient.<sup>23</sup> Thanks to his equipment, our patient achieved an almost complete social incorporation and high scores in the functional outcomes tests.

Finally, in situations as drastic as hemipelvectomy, the need for teamwork to keep the patient motivated is essential to achieve good results.

## CONCLUSIONS

Hemipelvectomy is a radical surgery reserved for certain terminal cases. The use of a multidisciplinary team is essential to achieve the objectives. In motivated patients and with adequate rehabilitation, it is possible to achieve complete equipment that allows adequate social incorporation.

Conflict of interest: The authors have no conflicts of interest to declare.

G. L. Gallucci ORCID ID: <https://orcid.org/0000-0002-0612-320X>

## REFERENCES

1. Kredel FE. The role of pelvic evisceration in surgery (Discussion). *Surgery* 1951;30:76-94. PMID: 14845996
2. Kennedy CS, Miller EB, Mc Lean DS, Perlis MS, Dion RN, Horvitz VS. Lumbar amputation or hemipelvectomy for advanced malignancy of the lower half of the body. *Surgery* 1960;48:357-65. PMID: 14845996
3. Baker TC, Berkowitz T, Lord GB, Hankins HV. Hemipelvectomy. *Br J Surg* 1970;57(6):471-6. <https://doi.org/10.1002/bjs.1800570617>
4. Terz JJ, Schaffner MJ, Goodkin R, Beatty JD, Razor B, Weliky A, et al. Translumbar amputation. *Cancer* 1990;65:2668-75. [https://doi.org/10.1002/1097-0142\(19900615\)65:12<2668::aid-cnrc2820651212>3.0.co;2-i](https://doi.org/10.1002/1097-0142(19900615)65:12<2668::aid-cnrc2820651212>3.0.co;2-i)
5. Abrams J, Hulbert J, Thompson R, Cerra F, Delaney J. Hemipelvectomy for acute aortic occlusion: A case study. *Am Surgeon* 1992;58:509-12. PMID: 1642392
6. Friedmann LW, Marin EL, Park YS. Hemipelvectomy for functional rehabilitation. *Arch Phys Med Rehabil* 1981;62:83-6. PMID: 7235890
7. Aust JB, Page CP. Hemipelvectomy. *J Surg Oncol* 1985;30(4):226-30. <https://doi.org/10.1002/jso.2930300408>
8. Miller TR. Translumbar amputation (hemipelvectomy). *Prog Clin Cancer* 1982;8:227-36. PMID: 7156403
9. Miller TR, Mackenzie AR, Randall HT, Tigner SP. Hemipelvectomy. *Surgery* 1966;59(6):988-93. PMID: 5937972

10. Richt P, Hoch J, Svobodová K, Jech Z. Hemicorporectomy - the ultimate solution of terminal pelvic sepsis. *Acta Chir Belg* 2020;1-5. <https://doi.org/10.1080/00015458.2020.1722930>
11. Gómez F, Ramos Galvan R, Frenk S, Cravioto Muñoz J, Chávez R, Vázquez J. Mortality in second and third degree malnutrition. *J Trop Ped (Lond)* 1956;2:77-83. <https://doi.org/10.1093/oxfordjournals.tropej.a057419>
12. Ware JE Jr, Sherbourne CD. The MOS 36-item short-form health survey (SF-36) (I). Conceptual framework and item selection. *Med Care* 1992;30:473-83. PMID: 1593914
13. Mahoney FI, Barthel DW. Functional evaluation: the Barthel Index. *Md State Med J* 1965;13:61-5. PMID: 14258950
14. Grise MC, Gauthier-Gagnon C, Martineau GG. Prosthetic profile of people with lower extremity amputation: conception and design of a follow-up questionnaire. *Arch Phys Med Rehabil* 1993;74:862-70. [https://doi.org/10.1016/0003-9993\(93\)90014-2](https://doi.org/10.1016/0003-9993(93)90014-2)
15. Shah S, Vanclay F, Cooper B. Improving the sensitivity of the Barthel Index for stroke rehabilitation. *J Clin Epidemiol* 1989;42:703-9. [https://doi.org/10.1016/0895-4356\(89\)90065-6](https://doi.org/10.1016/0895-4356(89)90065-6)
16. Janis JE, Ahmad J, Lemmon JA, Barnett CC Jr, Morrill KC, Mc Clelland RN. A 25-year experience with hemicorporectomy for terminal pelvic osteomyelitis. *Plast Reconstr Surg* 2009;124(4):1165-76. <https://doi.org/10.1097/PRS.0b013e3181b61169>
17. Warr SP, Jaramillo PM, Franco ST, Valderrama-Molina CO, Franco AC. Hemicorporectomy as a life-saving strategy for severe pelvic ring crush injury: a case report. *Eur J Orthop Surg Traumatol* 2018;28(4):735-9. <https://doi.org/10.1007/s00590-018-2140-z>
18. Ferrara BE. Hemicorporectomy: a collective review. *J Surg Oncol* 1990;45(4):270-8. <https://doi.org/10.1002/jso.2930450412>
19. Barnett CC Jr, Ahmad J, Janis JE, Lemmon JA, Morrill KC, McClelland RN. Hemicorporectomy: back to front. *Am J Surg* 2008;196(6):1000-2. <https://doi.org/10.1016/j.amjsurg.2008.08.009>
20. Shields RK, Dudley-Javoroski S. Musculoskeletal deterioration and hemicorporectomy after spinal cord injury. *Phys Ther* 2003;83(3):263-75. PMID: 12620090
21. Smith J, Tuel SM, Meythaler JM, Cross LL, Schuch JZ. Prosthetic management of hemicorporectomy patients: new approaches. *Arch Phys Med Rehabil* 1992;73(5):493-7. <https://doi.org/10.5555/uri:pii:000399939290>
22. Simons BC, Lehman JF, Taylor N, De Lateur BJ. Prosthetic management of hemicorporectomy. *Orthotics and Prosthetics* 1968;22(2):63-8. Disponible en: [http://www.oandplibrary.org/op/pdf/1968\\_02\\_063.pdf](http://www.oandplibrary.org/op/pdf/1968_02_063.pdf)
23. Ludwigs, E, Kannenberg A, Wüstefeld D. Evaluation of the benefits of a new prosthetic hip joint system in activities of daily function in patients after hip disarticulation or hemipelvectomy. *JPO Journal of Prosthetics and Orthotics* 2013;25(3):118-26. <https://doi.org/10.1097/JPO.0b013e31829afc1c>