

# Bone Marrow Edema Following Ankle Ligament Injuries: an MRI Imaging Evaluation

Manel Ballester-Alomar,<sup>\*</sup> Gustavo Lucar-López,<sup>\*</sup> Federico Bugallo,<sup>\*\*</sup> Griselda March-Sorribes,<sup>#</sup> Praneeth Revuri,<sup>##</sup> Kerbi A. Guevara Noriega<sup>\*†</sup>

<sup>\*</sup>Foot and Ankle Unit, Orthopedics and Traumatology Service, Hospital de Mataró (Barcelona, Spain)

<sup>\*\*</sup>Lower Limb Team, Orthopedics and Traumatology Division, Hospital General de Agudos "Dr. Juan A. Fernández" (Buenos Aires, Argentina)

<sup>#</sup>Podology Unit, Clínica Creu Blanca (Barcelona, Spain)

<sup>##</sup>Ankle Surgery, Mlathi Manipal Hospitals (Jayanagar, Bangalore, India)

<sup>\*†</sup>General Surgery, Jackson Memorial Hospital (Miami, United States of America)

## ABSTRACT

**Introduction:** Acute ankle sprains are a common type of musculoskeletal injury. With the increased popularity of MRI post-ankle sprain, more cases of bone marrow edema or bone bruise are detected. This is a subchondral osseous fracture of the cancellous microarchitecture with accompanied local hemorrhage and edema. This study aims to analyze if the presence of ankle ligament injury presents any significant statistical relation with the specific location. **Materials and Methods:** We reviewed 50 MRI performed during 2015-2018 for patients who reported ankle pain and signs of instability. Two different radiologists evaluated the series. Bone marrow edema location and specific ligament lesions were contrasted to find possible associations. Chi-Square was used to analyze the differences. **Results:** The anterior talofibular ligament was the most commonly injured ligament (84%). CFL injury occurred in 27 cases (54%). There were no differences between the presence of bone marrow edema and the ligament injured after an ankle sprain ( $p > 0.05$ ). Overall, the most common location of bone marrow edema was the head and neck of the talus (64%). There was no statistical relationship between bone marrow edema location and the injured ligament ( $p > 0.05$ ). **Conclusion:** Bone marrow edema is a frequent finding after a ligament injury following ankle sprains. However, this finding is not directly related to a specific location of the injured ligament. The location of bone marrow edema is not related to specific ligament injuries. MRI findings of bone marrow edema must not change the management of patients with acute ankle sprains.

**Key words:** MRI; ankle sprain; bone marrow.

**Level of Evidence:** II

## Edema óseo secundario a lesiones ligamentarias de tobillo. Hallazgos en las imágenes de resonancia magnética

## RESUMEN

**Introducción:** El esguince agudo de tobillo es una de las lesiones musculoesqueléticas más frecuentes. Su creciente estudio con resonancia magnética ha llevado a una mayor detección de edema óseo. El edema óseo por contusión consiste en una fractura ósea subcondral microtrabecular del hueso esponjoso junto con hemorragia local y edema. El objetivo de este estudio fue analizar una posible relación estadística entre la lesión ligamentaria de tobillo y la localización del edema óseo. **Materiales y Métodos:** Entre 2016, 2018, se analizaron 50 resonancias de pacientes con diagnóstico clínico de esguince sin lesión ósea en la radiografía. Dos radiólogos independientes analizaron las secuencias T1 y T2 en los planos coronal, axial y sagital. Se comparó la localización del edema óseo y las lesiones ligamentarias con el fin de encontrar posibles asociaciones. **Resultados:** No hubo diferencias en la presencia del edema óseo en relación con el ligamento lesionado como consecuencia de un esguince de tobillo ( $p > 0,05$ ). En general, el edema óseo fue más frecuente en la cabeza y el cuello del astrágalo (64%). No se halló una relación estadística entre la localización del edema óseo y el ligamento lesionado ( $p > 0,05$ ). **Conclusiones:** El edema óseo es un hallazgo frecuente en la resonancia magnética después de una lesión ligamentaria a causa de esguinces de tobillo; sin embargo, no hay evidencia de una relación entre la localización del edema y el ligamento lesionado.

**Palabras clave:** Resonancia magnética; esguince; tobillo; edema óseo.

**Nivel de Evidencia:** II

Received on May 21<sup>st</sup>, 2020. Accepted after evaluation on July 20<sup>th</sup>, 2020 • Dr. MANEL BALLESTER-ALOMAR • manel.ballester@gmail.com  <https://orcid.org/0000-0001-5351-605X>

**How to cite this paper:** Ballester-Alomar M, Lucar-López G, Bugallo F, March-Sorribes G, Revuri P, Guevara Noriega KA. Bone Marrow Edema Following Ankle Ligament Injuries: an MRI Imaging Evaluation. *Rev Asoc Argent Ortop Traumatol* 2021;86(1):17-22. <https://doi.org/10.15417/issn.1852-7434.2021.86.1.1724>

## INTRODUCTION

Ankle sprain is a very frequent injury, which is observed in the daily traumatology practice, both in the ER and in outpatient appointments. Different studies in the United States and in Europe have found that 30% of injuries in athletes are ankle sprains. The most common clinical picture is pain in the lateral part of the ankle and instability after plantar flexion and inversion.<sup>1</sup> There is consensus on the description of ankle sprain as the injury of the ligaments that are part of said joint. It can range from a contusion, in which case the signs and symptoms can be simply limited to pain and regional edema, to a total rupture of one or more components, which causes a more varied symptomatology in the acute phase.

The lateral ligamentous complex of the ankle is formed by the anterior talofibular ligament (ATFL), the calcaneofibular ligament (CFL) and the posterior talofibular ligament (PTFL). Generally, there is a 120° angle between the ATFL and the CFL. In an acute ankle sprain, the ATFL tends to be the most affected, followed by the CFL. The PTFL is the strongest and, consequently, the one less likely to rupture. Moreover, this ligament is favored by the kinematics of trauma, which is directed from the anterior side to the posterior side. Therefore, the isolated lesion of this ligament in ankle sprains is rare.

Systematic reviews have shown persistence of pain and instability in 5-33% of patients after conservative treatment. 34% of patients indicated at least one recurrent sprain and 15-64%, only partial recovery of the primary lesion.<sup>2</sup>

Likewise, it is fundamental to note the lesions that are associated with lateral ankle sprain, such as peroneal tendon tearing, osteochondral lesions or intra-articular loose bodies, which can cause chronic manifestations if not treated appropriately. Although an occult osteochondral defect can be detected in a magnetic resonance (MRI), its size and extension can be overestimated due to the amount of bone marrow edema surrounding the injury. For this reason, this study must be complemented by computed tomography (CT scan). These lesions can be identified in the MRI, but this is a less available type of study, due to its cost and lack of accessibility, or due to administrative reasons; for example, the fact that it is not covered under many health insurance plans.

It is a known fact that most of these patients obtain good results with strong physical therapy protocols, adequately implemented with aggressive proprioceptive training.

One of the issues to be considered is that immobilization lasting 4-6 weeks may cause rigidity in the ankle joint, thus aggravating the situation.

Frey et al. have shown that an adequate physical examination can diagnose grade III injuries with 100% precision. This percentage is significantly lower for grade I and II injuries.<sup>3</sup> Moreover, associated conditions are underdiagnosed.

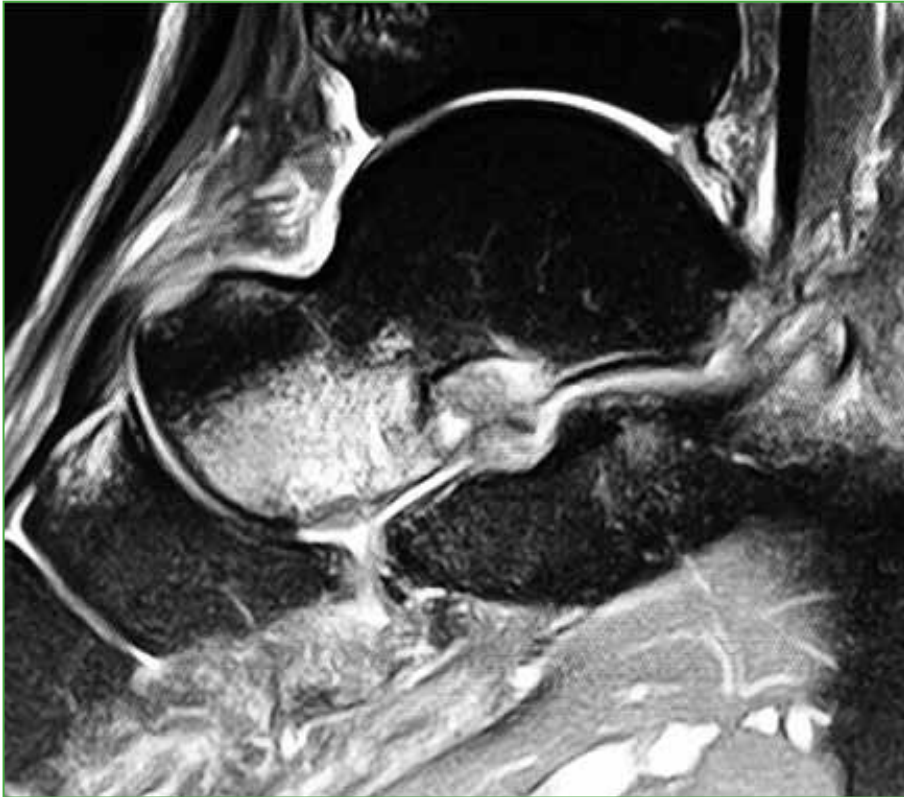
For this reason, varus-valgus stress radiographs and drawer tests in 20° and 0° of plantar flexion are fundamental for the functional evaluation of the ATFL and the CFL, respectively.

In some cases, there may be deltoid ligament attenuation. It is also very important to perform the talar tilt test during physical examination, even though it is less frequent in patients with lateral ankle sprain.

Ramsey and Hamilton have found that, with a lateral displacement of 2 mm, tibiofibular contact is reduced by 42%. This can explain post-traumatic arthritis and highlights the importance of a prompt diagnosis in order to prevent possible complications. When the physical examination is not enough to diagnose an acute lateral ankle sprain, the most frequent option is the MRI. Diagnostic accuracy of ATFL tearing was 91.7%; of CFL tearing, 87.5% and of osteochondral lesions, 83.3%. Sensitivity was low, especially for CFL tears; thus, the false negative rate is high.<sup>4,5</sup>

A literature analysis reveals a controversial issue surrounding the finding of bone marrow edema in MRI at the insertion sites of the lateral ankle ligaments (ATFL, CFL, PTFL), and its role as an additional diagnostic indicator to start an appropriate treatment of acute ankle sprains (Figura 1). Likewise, it is important to pay attention to false negatives in MRI; however, if bone marrow edema is present, this must be considered a red flag for ATFL and CFL attenuation.<sup>6</sup>

For this reason, it is of utmost importance to find if there is a clinical/radiological correlation and, consequently, conduct therapeutic management accordingly. The aim of this study was to evaluate the relationship between the presence of bone marrow edema and specific ligament lesions after an ankle sprain. We attempted to analyze the connection between bone marrow edema, identified by MRI, and ankle ligament lesions in specific locations.



**Figure 1.** Post-traumatic bone marrow edema in the talar neck and head.

## MATERIALS AND METHODS

50 magnetic resonances were analyzed. They had been performed between 2016 and 2018 in patients with a clinical diagnosis of ankle sprain, with pain or signs of instability, without bone injury present in radiographs. Average age was  $24 \pm 10.7$  years (15-64 range). Ten patients were women and 20, men.

The MRIs were performed, on average,  $23 \pm 39.8$  days after trauma (3-210 range). Two independent radiologists evaluated the T1-weighted and T2-weighted images in the coronal, axial and sagittal planes, in search of characteristics of: 1) ATFL, 2) CFL, 3) PTFL and 4) deltoid ligament (DL). The presence of bone marrow edema was also evaluated, and its location was defined according to the following areas: a) medial talar dome, b) lateral talar dome, c) talar body, d) talar neck and head, e) medial malleolus, f) lateral malleolus, g) posterior malleolus, h) calcaneus. With these data, an analysis of these parameters was conducted.

Patients with a history of ligament or osteochondral lesions or those with chronic ligamentous laxity were excluded.

SPSS 20 software was used for the statistical analysis. A significant statistical relation between bone marrow edema and a specific ligament lesion location was analyzed. Chi-square test was conducted.

## RESULTS

According to the 50 analyzed MRI, the ATFL was the most affected by injuries (42 cases, 84%). In 55%, the lesion was total and, in 26%, partial. ATFL lesion was frequently associated with a simultaneous lesion in another ligament. In only five cases the lesion was isolated and, in three of them (60%), the edema was on the talar head and neck, without a clearly defined pattern.

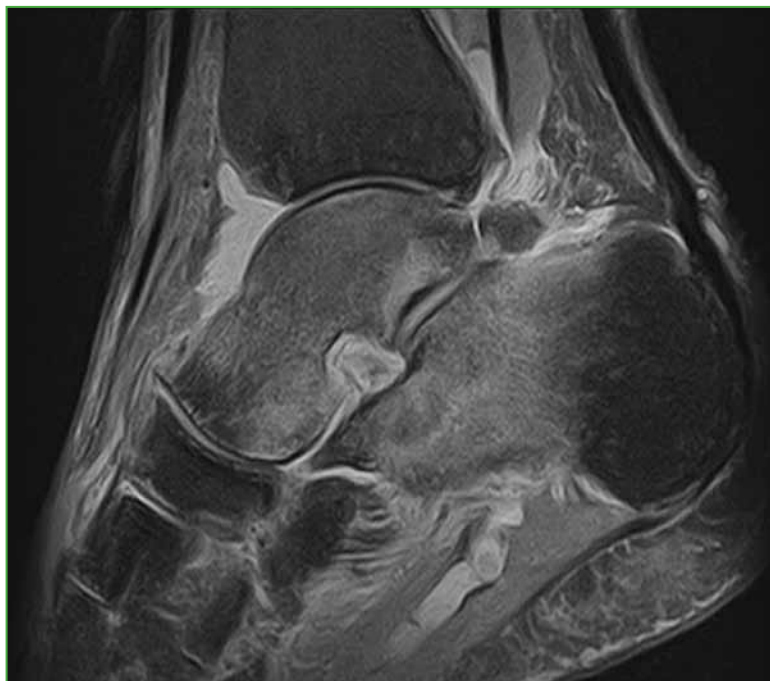A lesion of the CFL was observed in 27 cases (54%); in 63% it was partial and, in 37%, total. There were no detected cases of isolated lesions of the CFL. In 14 of the cases (52%), the lesion of the CFL was associated with a lesion of the DL. When the lesion was double (CFL plus ATFL), bone marrow edema appeared in the talar body

(12 patients, 24%) and in the talar head and neck (9 patients, 18%). However, there were eight cases of triple ligament lesion (CFL plus ATFL plus DL); bone marrow edema was very frequently detected in the talar body, head or neck, but also in the medial (4 cases) and lateral (2 cases) malleolus.

Only one patient had a complete lesion of the lateral ligament complex (ATFL plus CFL plus PTFL plus DL). In this case, bone marrow edema was detected in the talar head and medial malleolus.

Twenty-five patients (50%) had a lesion of the DL. There was only one case of total lesion. 24 partial lesions were detected: 18 occurred with the lesions of the ATFL and the CFL and, in the six remaining cases, only with the ATFL.

The most frequent location of bone marrow edema was the talar neck and head (32 patients, 64%), commonly when MRI showed a lateral or medial injury (15 cases, 30%). The second most frequent location was the talar body (20 patients, 40%) (Figure 2).



**Figure 2.** Post-traumatic bone marrow edema in the talar body and the calcaneus.

30% and 40% of the cases had edema in the medial or lateral malleolus, respectively, and it was even more frequent when two or more ligaments were injured.

Talar dome edema was detected in 15 cases (30%), it was more frequent in the medial area (13 cases, 26%); and lateral talar dome edema was detected in four cases. The talar dome edema did not develop with a clearly defined pattern according to the type of injury.

No statistical relation was found between the location of bone marrow edema and the injured ligament ( $p > 0,05$ ).

## DISCUSSION

This study mainly included patients who suffered ankle sprains as a consequence of contact sports, especially basketball. The most commonly observed injury mechanism is the combination of plantar flexion and inversion, although other combinations are also detected, which provoke combined injuries of the medial complex, the syndesmosis and the subtalar joint. Partial injury tends to be the most common and, in all cases, associated with

traumatic bone marrow edema. It is important to highlight that, as it was expected, our study detected more cases of bone marrow edema by MRI than by the sole use of radiography. Even more relevant was the finding of cases of bone marrow edema without ligament lesion. All of this leads to the conclusion that MRI is a more sensitive technique and allows to detect bone marrow edema even if there is no ligament lesion, something worth noting, for it can justify pain even if there is no fracture or sprain.

It is important to highlight that there are different ways of visualizing alterations in the MRI. Bone injuries appear hypointense in the T1-weighted sequence, whereas edema or hemorrhage are detected as isointense images. In the T2-weighted sequence, bone injuries are visualized as areas of heterogeneous signal intensity, whereas edema or hemorrhages appear as hyperintense images. This enables the confirmation of the presence of bone marrow edema and its possible association to fractures without further difficulty.<sup>7</sup>

In the MRI, the presence of linear and geographical lesions suggests a more localized injury, which can even compromise the adjacent cartilage. Occult injuries of the cartilage cannot be detected by MRI. This could be the reason behind pain in a patient without ligament injury or fracture. More studies are needed to clarify this topic.

Mink and Deutsch divide occult bone injuries into four categories: traumatic bone marrow edema, fatigue fracture, tibial and femoral fractures, and osteochondral fractures.<sup>8</sup> For future research, the association of this classification to clinical variables would be useful.

For our aim in particular, when we analyzed the relation between the pattern of ligament lesions and traumatic bone marrow edema, we did not find a clear pattern or a specific constant in the distribution of bone marrow edema in ankle sprains. The results confirm the conclusions of Labovitz et al., who published similar results and concluded that it is not easy to establish a relation between ligament lesions of the ankle and the presence of traumatic bone marrow edema. Likewise, traumatic bone marrow edema without ligament lesions or fractures leads us to think it is a poorly specific radiological sign.<sup>9</sup>

The literature supports conservative management as the first choice for grade I and II ankle sprains. If our results are taken into account, this management still stands, and, in this type of injury, detecting bone marrow edema in MRI is of no use.

This treatment is associated with good outcomes; however, if it is not properly done, sequelae may appear in the long term. The RICE (*Rest, Ice, Compression, Elevation*) method seems to be enough until inflammation and soft tissue edema diminish, followed by deambulation with total or partial body weight bearing, according to the patient's tolerance to pain. In this context, it would be advisable to associate rehabilitation with a physiotherapist to diminish the possibility of sequelae.<sup>10</sup>

The most frequent cause of the injuries is forced inversion during sporting activities, falls or traffic accidents. Moreover, the eversion and abduction of the foot are usually associated to another injury in another ligament or tendon, and traumatic bone edema has been described as an indirect sign of the ligament lesion.<sup>4,11-14</sup>

This study has certain limitations, for it is a retrospective analysis, exclusively centered on ligament lesions and traumatic bone marrow edema; that is, caused by rotation, varus, valgus or combined impacts. Follow-up was adequate and superior to 90%. Some patients underwent a second MRI in order to analyze the traumatic bone marrow edema. Since a limited number of patients were evaluated and the primary analysis did not show any usefulness, it is not correct or useful to draw conclusions on this second study.

## CONCLUSIONS

Bone marrow edema is common after a ligament lesion following an ankle sprain. However, the anatomical location of bone marrow edema is not directly related to a specific location of the injured ligament. The presence of bone marrow edema in an MRI must not imply a change in the treatment of patients with acute ankle sprain. Nevertheless, MRI is still an extremely useful tool to detect related injuries.

---

Conflict of interests: Authors claim they do not have any conflict of interest.



## REFERENCES

1. Saxena A, Luhadiya A, Ewen B, Goumas C. Magnetic resonance imaging and incidental findings of lateral ankle pathologic features with asymptomatic ankles. *J Foot Ankle Surg* 2011;50:413-5. <https://doi.org/10.1053/j.jfas.2011.03.011>
2. Van Rijn RM, van Os AG, Bernsen RM, Luijsterburg PA, Koes BW, Bierma-Zeinstra SM. What is the clinical course of acute ankle sprains? A systematic literature review. *Am J Med* 2008;121:324-31. <https://doi.org/10.1016/j.amjmed.2007.11.018>
3. Frey C, Bell J, Teresi L, Kerr R, Feder K. A comparison of MRI and clinical examination of acute lateral ankle sprains. *Foot Ankle Int* 1996;17:533-7. <https://doi.org/10.1177/107110079601700904>
4. Park H-J, Cha S-D, Kim SS, Rho M-H, Kwag H-J, Park N-H, Lee S-Y. Accuracy of MRI findings in chronic lateral ankle ligament injury: comparison with surgical findings. *Clin Radiol* 2012;67:313-8. <https://doi.org/10.1016/j.crad.2011.08.025>
5. Ramsey PL, Hamilton W. Changes in tibiotalar area of contact caused by lateral talar shift. *J Bone Joint Surg Am* 1976;58:356-7. PMID: 1262367
6. van Putte-Katier N, van Ochten JM, van Middelkoop M, Bierma-Zeinstra SM, Oei EH. Magnetic resonance imaging abnormalities after lateral ankle trauma in injured and contralateral ankles. *Eur J Radiol* 2015;84:2586-92. <https://doi.org/10.1016/j.ejrad.2015.09.028>
7. Lee JK, Yao L. Occult intraosseous fracture: magnetic resonance appearance versus age of injury. *Am J Sports Med* 1989;17:620-3. <https://doi.org/10.1177/036354658901700505>
8. Deutsch AL, Coel MN, Mink JH. Imaging of stress injuries to bone. Radiography, scintigraphy, and MR imaging. *Clin Sports Med* 1997;16:275-90. [https://doi.org/10.1016/S0278-5919\(05\)70022-3](https://doi.org/10.1016/S0278-5919(05)70022-3)
9. Labovitz JM, Schweitzer ME. Occult osseous injuries after ankle sprains: incidence, location, pattern, and age. *Foot Ankle Int* 1998;19:661-7. <https://doi.org/10.1177/107110079801901003>
10. Saxena A, Eakin C. Articular talar injuries in athletes: results of microfracture and autogenous bone graft. *Am J Sports Med* 2007;35:1680-7. <https://doi.org/10.1177/0363546507303561>
11. Harmon KG. The ankle examination. *Prim Care* 2004;31:1025-37. <https://doi.org/10.1016/j.pop.2004.07.008>
12. Konradsen L, Voigt M, Højsgaard C. Ankle inversion injuries. The role of the dynamic defense mechanism. *Am J Sports Med* 1997;25:54-8. <https://doi.org/10.1177/036354659702500110>
13. Longo UG, Loppini M, Berton A, Marinozzi A, Maffulli N, Denaro V. The FIFA 11+ program is effective in preventing injuries in elite male basketball players: a cluster randomized controlled trial. *Am J Sports Med* 2012;40(5):996-1005. <https://doi.org/10.1177/0363546512438761>
14. Nishimura G, Yamato M, Togawa M. Trabecular trauma of the talus and medial malleolus concurrent with lateral collateral ligamentous injuries of the ankle: evaluation with MR imaging. *Skeletal Radiol* 1996;25:49-54. <https://doi.org/10.1007/s002560050031>